

Use of an Osteoplastic Flap for the Prevention of Mastoidectomy Retroauricular Defects

Ricardo Ferreira Bento¹ Robinson Koji Tsuji¹ Anna Carolina de Oliveira Fonseca¹ Ricardo Dourado Alves¹

¹Department of Otolaryngology, Universidade de São Paulo, São Paulo, São Paulo, Brazil

Address for correspondence Ricardo Dourado Alves, MD, Department of Otolaryngology, Universidade de São Paulo, Av Dr Enéas de Carvalho Aguiar, 255, sala 6167, São Paulo, SP, 05403-0000, Brazil (e-mail: otorrinorcarvalho@gmail.com).

Int Arch Otorhinolaryngol 2017;21:151–155.

Abstract

Introduction After mastoidectomy, patients usually complain of bone depressions in the retroauricular region in the surgical site, especially in procedures that require extensive cortical resections. This causes inconveniences such as difficulty wearing glasses, cleaning, and aesthetics complaints.

Objective This study aims to describe a vascularized flap surgical technique that uses the mastoid cortical bone adhered to the periosteum, which is pedicled on the anterior portion and repositioned at the end of the surgery. This ensures the coverage of the mastoid cavity generated by surgery and prevents ear retraction into the cavity. This preliminary report describes the technique and intraoperative and immediate postoperative complications.

Methods After retroauricular incision, periosteal exposure is performed. A U-shaped incision is required for the procedure and delimits a periosteum area appropriate to the size of the mastoidectomy. The cortical bone is opened using a 2.5 mm drill around the perimeter of the “U,” at a 3 mm depth. A chisel is introduced through the surface cells of the mastoid, and a hammer evolves into the anterior direction. The flap is lifted, leaving the periosteum adhered to it and forming a cap. The flap is anteriorly fixed to not hinder the surgery, and repositioned at the end. The periosteum is then sutured to the adjacent periosteum.

Results The first 14 cases had no intraoperative complications and were firm and stable when digital pressure was applied during the intraoperative and immediate postoperative periods.

Conclusion The osteoplastic flap pedicle is a safe and simple procedure, with good results in the immediate postoperative period.

Keywords

- ▶ mastoid
- ▶ ear deformities
- ▶ acquired
- ▶ otologic surgical procedures
- ▶ vascularized bone flap
- ▶ wound closure techniques

Introduction

A most common complaint of patients after mastoidectomy is depressions in the mastoid cortical bone in the retroauricular region, which is the surgical site (▶ Fig. 1). This depression occurs mainly in procedures that require wide openings on the mastoid, such as: open or closed mastoidectomy for chronic ear and cholesteatoma; translabyrinthine approach for tumors of the acoustic nerve; congenital cholesteatomas;

decompression of the facial nerve; approaches to endolymphatic sac; and cochlear implants, among others.

For closing the cavity resulting from cell removal, most surgeons simply overlay the cavity with connective tissue and skin, and then suture it in two layers, while some overlay it with a muscle periosteal flap.¹

Invariable retractions arise after surgery, with more or less intensity in all patients and remain even after years of surgery, even when using materials such as muscle or fat

received
January 5, 2016
accepted
April 12, 2016
published online
May 30, 2016

DOI <http://dx.doi.org/10.1055/s-0036-1584266>.
ISSN 1809-9777.

Copyright © 2017 by Thieme-Revinter Publicações Ltda, Rio de Janeiro, Brazil

License terms



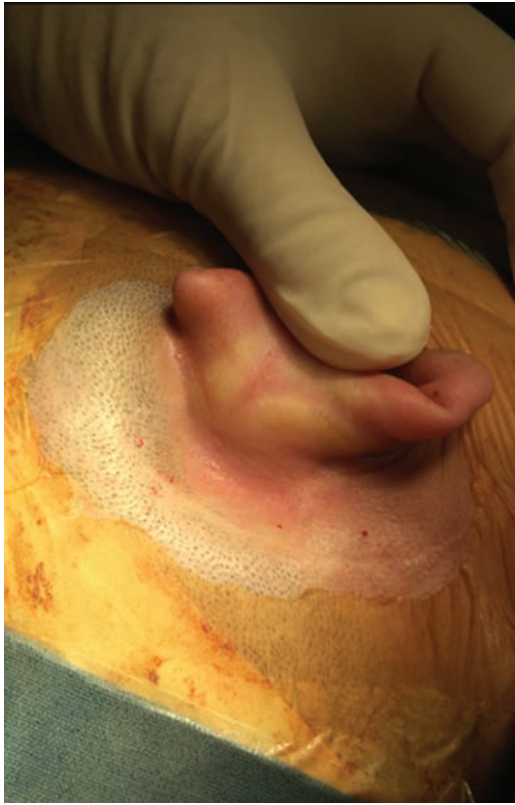

Fig. 1 Late retroauricular depression in a patient who underwent schwannoma resection via the presigmoid approach.

underneath the muscle periosteal flap to obliterate the cavity and close dura mater defects or prevent cerebrospinal fluid leaks.

The most common complaints of patients include pain and discomfort to the touch, uncomfortable feeling while wearing glasses because of the contact of the temple tips with the depression caused by the surgery, accumulation of skin peeling, difficulty of dirt removal, and aesthetic problems. It is common to find dirt accumulation in bone depressions when examining patients who underwent mastoidectomy surgery (→ Fig. 2).

In addition to these complaints and aesthetic problems, we know that the mastoid cavity maintains the middle ear

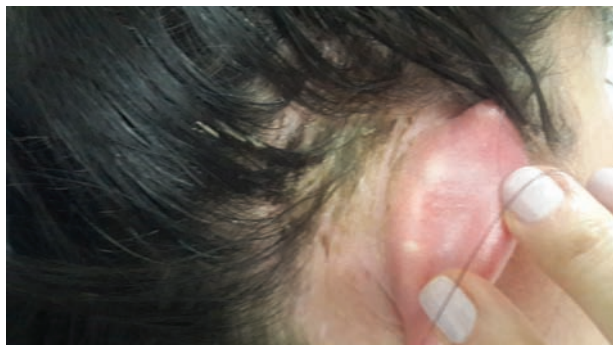

Fig. 2 Dirt accumulated in the retroauricular depression in a late-postoperative patient.

pressure, acting as a reservoir of air, and aids in the effective conduction of sound as a sound box.¹ Reconstruction of the mastoid defect is desirable to maintain the mastoid cavity closest to its physiological function, preventing the growth of fibrous tissue into the surgical cavity.

Several types of flaps have been described to minimize depression, as reported by Yanagihara et al² who found good results with mastoid cortical bone reconstructions using bone pate. Muscular or periosteal flaps were also used, but favor the formation and invasion of the cavity by fibrosis and do not prevent depression.¹

Yuen and Chen³ synthesized the main reconstruction options available for the correction of bone defects in schwannoma resection surgeries via the presigmoid approach to prevent further depression of the region. These options are divided between endogenous and allogeneic materials. For the allogeneic materials, Jung and Park⁴ describe the correction of these depressions in revision surgeries after complaints from patients on whom they used a titanium mesh to close the resulting bone cavity. Another option is allogeneic hydroxyapatite cements, which can be prepared and molded intraoperatively. These favor osseointegration and do not cause foreign body reaction, but entail a high cost and hamper revision surgeries.³ The following are endogenous options: local muscle flaps, which also exhibit volumetric shrinkage over time,⁵ and vascularized and non-vascularized bone grafts.³

Couldwell and Fukushima⁶ and Rica et al⁷ described local non-vascularized bone graft techniques. In their cases, the whole periosteum was peeled off, exposing the cortical bone to be removed. The cortical bone was removed with the aid of craniotomy blades, kept in saline solution outside the body during surgery, and repositioned and fixed with titanium plates and screws at the end of the surgery. Yuen et al⁸ described a cranioplasty technique in schwannoma surgeries via the presigmoid approach by using an inferior pedicle osteomuscular flap, with the periosteum and sternocleidomastoid muscle preserved, and the flap attached to bone cortical mastoid. The flap was folded inferiorly to the tip of mastoid process and repositioned at the end of the surgery without fixation by plates and screws, just suturing the periosteal flap to the periosteum around it.

The aim of this study was to describe the surgical technique of using a pedicle osteoperiosteal flap in the anterior region of the mastoid approach to prevent retroauricular depression and evaluate the intraoperative and immediate postoperative outcomes.

Methods

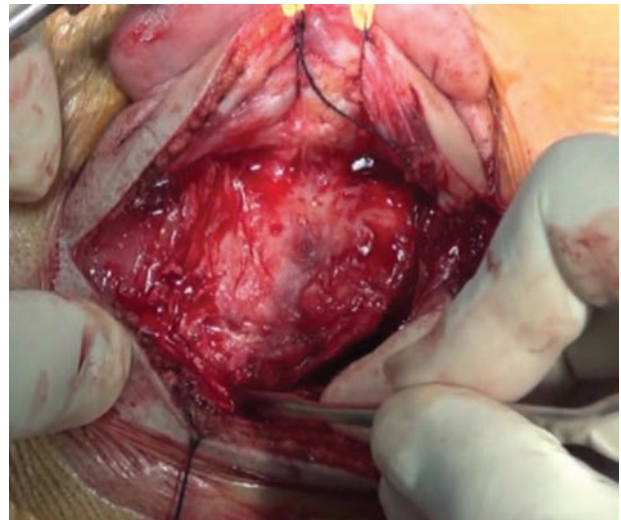
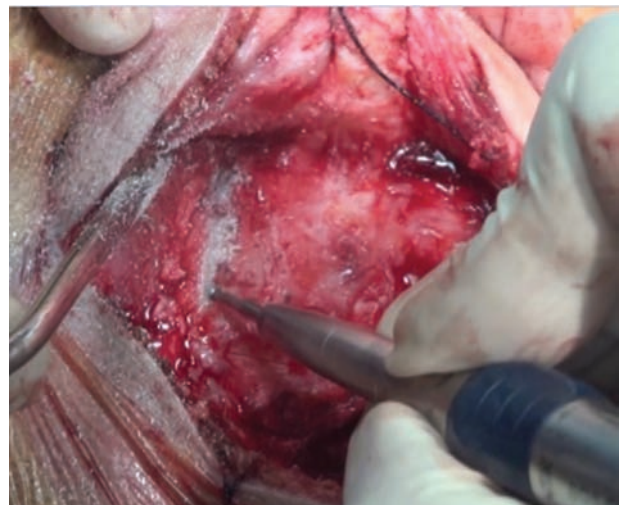
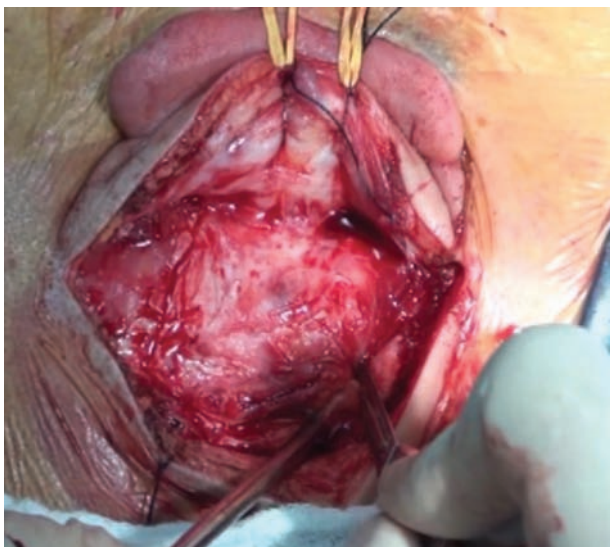
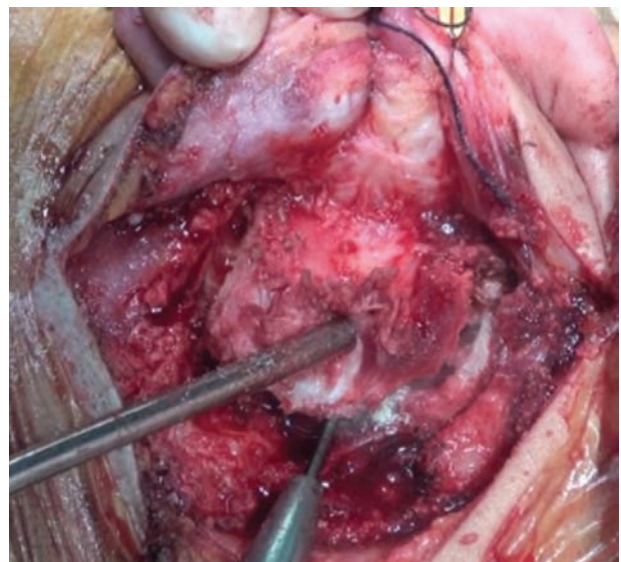
This technique was performed to date in 14 patients, of whom 5 underwent primary surgery for schwannoma vestibular resection via the pre-sigmoid approach and 9 underwent cochlear implant surgery (→ Table 1). All the patients underwent computed tomography (CT) of the temporal bones for surgical planning and preoperative evaluation of the position of the sigmoid sinus. We excluded patients with sigmoid sinuses that were lateralized and prominent due to the risk of injury during flap creation.

Table 1 Patients already subjected to the osteoplastic flap technique

Patient	Surgery Type	Age (years)	Sex
1	Schwannoma excision	31	Female
2	Schwannoma excision	35	Male
3	Schwannoma excision	54	Female
4	Cochlear Implant	29	Male
5	Cochlear Implant	4	Male
6	Cochlear Implant	46	Male
7	Cochlear Implant	52	Male
8	Schwannoma excision	66	Male
9	Schwannoma excision	62	Male
10	Cochlear Implant	38	Male
11	Cochlear Implant	26	Female
12	Cochlear Implant	56	Female
13	Cochlear Implant	5	Male
14	Cochlear Implant	72	Female

After retroauricular incision, the periosteum of the retroauricular region was exposed. We performed a U-shaped incision, delimiting the periosteum area appropriate to the size of the mastoidectomy to be achieved (► Fig. 3). With a small elevator, the periosteum was deviated from the entire incision to expose the mastoid cortical bone to achieve drilling (► Fig. 4).

We opened the cortical bone with a 2.5-mm drill around the perimeter of the “U,” at a depth of ~3mm (► Fig. 5). Then, with the drill acting at an angle of ~20 degrees to the cortical bone, a bone flap ~3 mm thick was created around, deepening to ~1 cm parallel to the cortical bone (► Fig. 6). We gently introduced a chisel through the surface cells of the mastoid

**Fig. 4** Exposure of the cortical bone with the aid of a curette, removing the periosteum.**Fig. 5** Boring of the mastoid cortical bone in the “U” region.**Fig. 3** U-shaped incision of the periosteum.**Fig. 6** Deepening and anteriorization of the drilling.

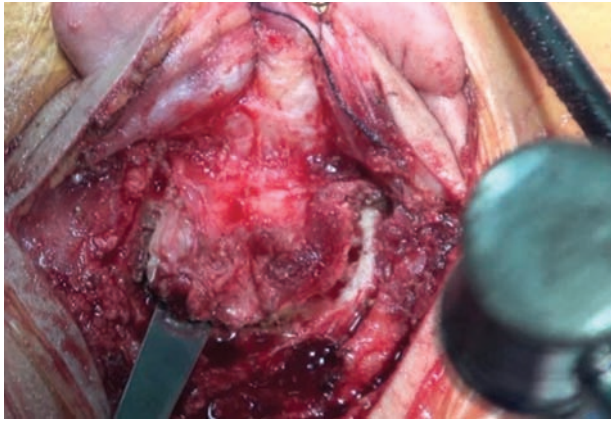


Fig. 7 Separation of the mastoid osteoperiosteal flap with the aid of a chisel and hammer.

and hammered to an anterior direction until it got close to the ear canal (►Fig. 7).

When the entire length of the osteoperiosteal flap detached from the cortical bone, it was lifted, leaving the periosteum adhered to it and forming a “cap” of bone, with the periosteum pedicled on the anterior portion (►Fig. 8). The flap was fixed anteriorly to not hinder the surgical procedure (►Fig. 9), and the mastoid drilling was performed normally.

After the procedure, the flap was folded over the cavity and the periosteum edges were sutured to the corresponding periosteum (►Fig. 10). The subcutaneous and skin sutures were performed normally, in two layers.

Results

The first 14 cases had no intraoperative complications, and their appearances in the intraoperative and immediate post-operative periods were adequate, staying firm and stable upon digital pressure. CT performed in the immediate post-operative period (the day after the procedure) revealed the bone flap in position and the aerated aspect of the mastoid

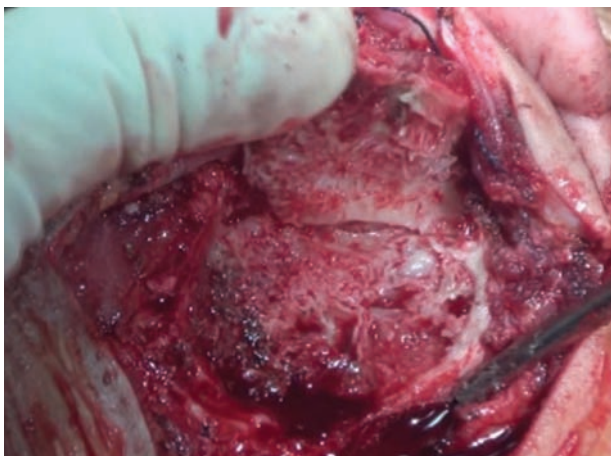

Fig. 8 Lifting of the osteoperiosteal flap.

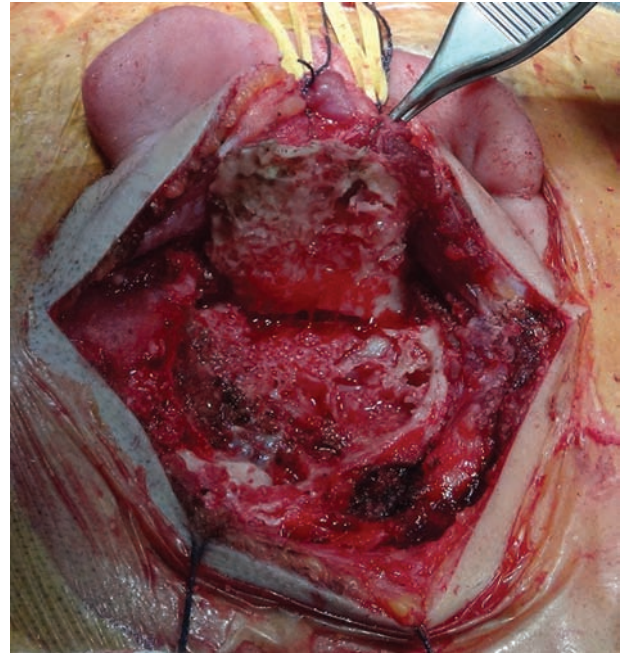


Fig. 9 Flap anterior fixation with suture to protect it and not hinder surgery.

(►Fig. 11). The average time added to the surgical duration for obtaining this flap was ~10 minutes.

Discussion

Post-mastoidectomy retroauricular depressions are extremely common and cause inconvenience to many patients. It is desirable to keep the aeration of the mastoid as close to normal so that the cavity is not filled with fibrosis, which alters its natural function of volume balance and the gas pressure of the middle ear, as well as their compositions.⁹

The use of synthetic materials such as titanium meshes to cover the cavity has been successful. However, these materials can cause foreign body reaction, entail high costs, and require availability of different sizes during surgery.

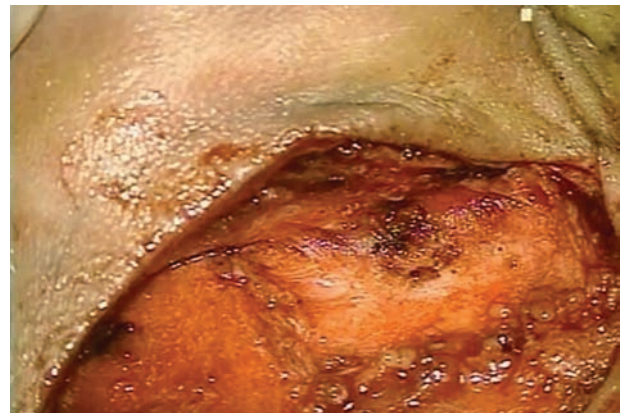


Fig. 10 Flap repositioning and suturing of the periosteum with the adjacent periosteum by using absorbable suture at the end of surgery.

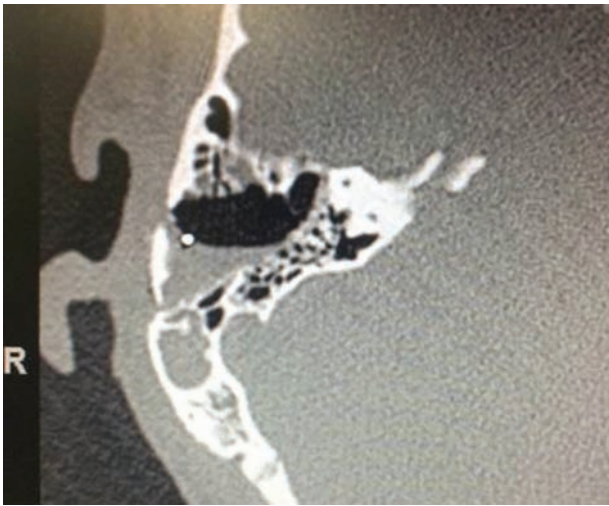


Fig. 11 Bone axial computed tomographic image obtained immediately after surgery in a patient who underwent cochlear implant surgery with a flap.

Moreover, their management in revision surgery can pose a great difficulty and their reuse is not always possible. Moreover, these materials are not recommended for use in surgeries for infections such as chronic otitis media, as they may evolve with biofilm and need future removal for complete control of the infection.

The use of free grafts, bone pate, or even bone plates from bone stock has the disadvantage of not being pedicled and, therefore, non-vascularized. This makes their nutrition difficult and facilitates resorption with time, becoming necrotic and easily infected.

The flap described by Yuen et al⁸ is also vascularized. However, unlike our proposed flap, it is inferiorly pedicled in the sternocleidomastoid muscle region. Because of this feature, this technique cannot be used with minor flaps, which always require a flap that goes near the dura mater of the middle fossa to the tip of the mastoid, as this is unnecessary for most non-tumor ear surgeries. Another drawback of this technique is the handling of the sternocleidomastoid muscle, which can increase postoperative pain.

The flap we proposed has the advantage of being obtainable from the patient. It can be made to the size appropriate

for the intended procedure. Being pedicled, it allows for irrigation and thus minimizes the risk of infection and necrosis.

The risk of complications is minimal. The major one is the possible exposure of the sigmoid sinus when it is elevated and lateralized. Thorough evaluation of preoperative CT scans can prevent this exposure and aid in flap planning and selection of patients for whom it can be performed safely. Another advantage is that if found during surgery that it cannot be used, the flap can be converted to a periosteal flap, as it has always been used.

Conclusion

The osteoplastic flap pedicle is a safe, fast, and simple procedure, presenting good results in the immediate postoperative period. Several cases are being followed up so that results from at least 1 year of follow-up can be reported in future publications.

References

- 1 Bento RF, Pinna MH, Martins G. *Tratado de Otologia*. 2nd edition. São Paulo, Brazil: Editora Atheneu; 2013
- 2 Yanagihara N, Hinohira Y, Sato H. Mastoid cortex plasty using bone pate. *Otol Neurotol* 2002;23(4):422-424
- 3 Yuen H-W, Chen JM. Reconstructive options for skull defects following translabyrinthine surgery for vestibular schwannomas. *Curr Opin Otolaryngol Head Neck Surg* 2008;16(4):318-324
- 4 Jung TT, Park SK. Reconstruction of mastoidectomy defect with titanium mesh. *Acta Otolaryngol* 2004;124(4):440-442
- 5 Mehta RP, Harris JP. Mastoid obliteration. *Otolaryngol Clin North Am* 2006;39(6):1129-1142
- 6 Couldwell WT, Fukushima T. Cosmetic mastoidectomy for the combined supra/infratentorial transtemporal approach. Technical note. *J Neurosurg* 1993;79(3):460-461
- 7 Rica CM, D'Osvaldo DH, Buchfelder M, Oviedo JD. En-bloc craniotomy for the pre-sigmoid infra- and supratentorial approach: technical note. *Acta Neurochir (Wien)* 2011;153(12):2473-2478, discussion 2478
- 8 Yuen H-W, Thompson AL, Symons SP, Pirouzmand F, Chen JM. Vascularized mastoid bone flap cranioplasty after translabyrinthine vestibular schwannoma surgery. *Skull Base* 2009;19(3):193-201
- 9 Austin DF. On the function of the mastoid. *Otolaryngol Clin North Am* 1977;10(3):541-547