

CASE REPORT

 OPEN ACCESS

## A new modified Pudendal Thigh Flap of vaginoplasty including reconstruction of vaginal vestibule

Youkou Ohmaru, Kensuke Sakata, Shin-ichiro Hashiguchi, Hiroaki Tanaka, Hideaki Rikimaru and Kensuke Kiyokawa

Department of Plastic and Reconstructive Surgery and Maxillofacial Surgery, Kurume University, Fukuoka, Japan

### ABSTRACT

We modified the conventional Pudendal Thigh Flap (PTF) on the vaginoplasty including reconstruction of vaginal vestibule. After the operation, no stenosis of the vaginal vestibule and opening of the vagina was observed. It is believed that our technique is cosmetically and functionally possible and a useful method.

### ARTICLE HISTORY

Received 17 August 2016  
Accepted 12 February 2017

### KEYWORDS

Vaginoplasty; vaginal vestibule; modified Pudendal Thigh Flap

### Introduction

There have been many reports with respect to vaginoplasty, including those involving skin grafting, the intestinal tract and skin flaps, since this surgery was first carried out by Dupuytren [1–8]. However, these methods involved forming the lumen of the vagina, with no reports to date on vaginoplasty including the vaginal vestibule reconstruction. We report on a new method for performing vaginoplasty, including the vaginal vestibule reconstruction with respect to a case of congenital absence of a vagina.

### Case report

Twenty-one-year-old female had been undergoing treatment with respect to primary amenorrhea from the age of 16. At 20 years old, she underwent a laparoscopic gonadectomy with a diagnosis of testicular feminisation syndrome. She requested vaginoplasty with respect to the vaginal caecum.



*Findings:* Although there were no problems with the shape of the labia majora, labia minora, and clitoris, no pubic hair was observed. The vagina measured 3 cm and there was a coecum, while the vaginal vestibule narrowed on the anal side (Figure 1).

*Transvaginal ultrasonography:* The uterus was absent and the distance from the tip of the vaginal caecum to the retroperitoneum was 2.7 cm (Figure 2).

*Surgical findings:* The posterior labial arteries of both sides were confirmed by Doppler prior to surgery and vaginoplasty using a bilateral Pudendal Thigh Flap (PTF) was planned. First, in order to ensure space for inserting the skin flap, an obstetrics and gynaecology specialist made a transverse incision at the tip where the vaginal caecum was observed, then exfoliated the connective tissue between the bladder and the rectum to create space.

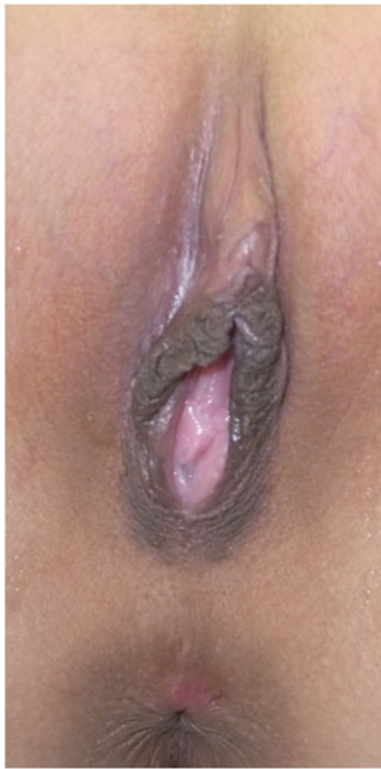
Next, the procedure was taken over by a plastic surgeon to design the PTF. It was designed such that the donor scar matched the contour line of the inner proximal region of the thigh within a range in which sufficient reefing is possible without including the skin of the outer labia. Moreover, the bilateral skin flaps were extended towards the anal side, thereby reconstructing the vaginal vestibule using these parts (Figure 3). The bilateral PTFs were elevated under the fascia (Figure 4), a tunnel was made underneath the skin of the outer labia, and subsequently, these skin flaps were moved to the centre (Figure 5).

Next, the skin flaps were sutured together from the distal part of the skin flap in the shape of a lumen, thereby creating an intravaginal cavity (Figure 6). This was then inserted into the space between the bladder and the rectum that was made prior to lifting the skin flap, and the remaining vaginal mucous membrane in the urethra was sutured together with the skin flap.

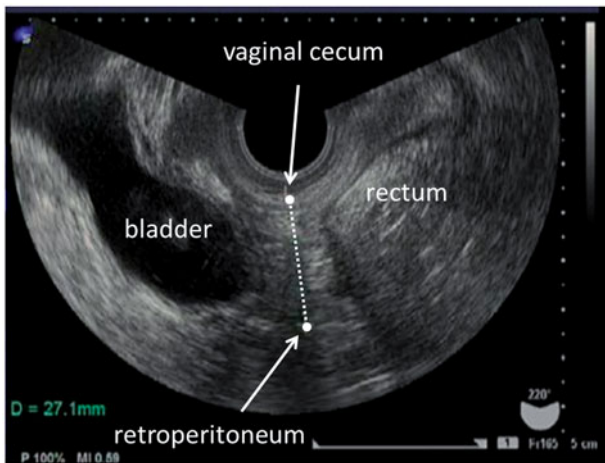
**CONTACT** Youkou Ohmaru  [ohmaru\\_youkou@yahoo.co.jp](mailto:ohmaru_youkou@yahoo.co.jp)  Department of Plastic and Reconstructive Surgery and Maxillofacial Surgery, Kurume University School of Medicine, 67 Asahi-machi Kurume-city, Fukuoka-prefecture, Japan

© 2017 The Author(s). Published by Informa UK Limited, trading as Taylor & Francis Group.

This is an Open Access article distributed under the terms of the Creative Commons Attribution-NonCommercial License (<http://creativecommons.org/licenses/by-nc/4.0/>), which permits unrestricted non-commercial use, distribution, and reproduction in any medium, provided the original work is properly cited.

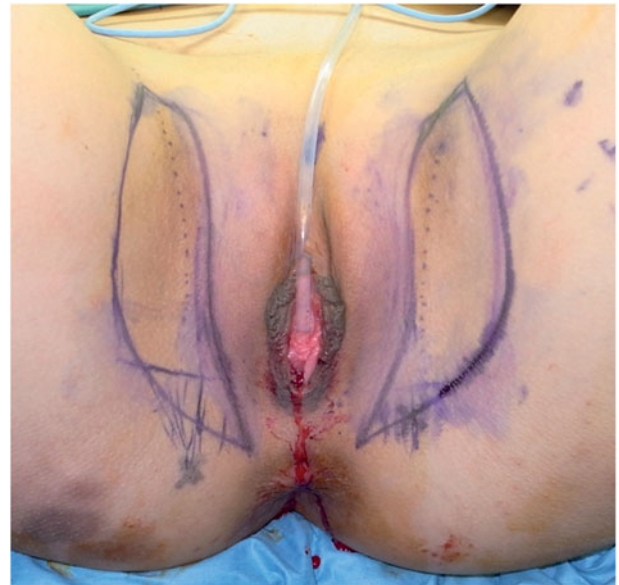

**Figure 1.** Findings before the operation no pubic hair was observed and the vagina measured 3 cm. The vaginal vestibule narrowed on the anal side.

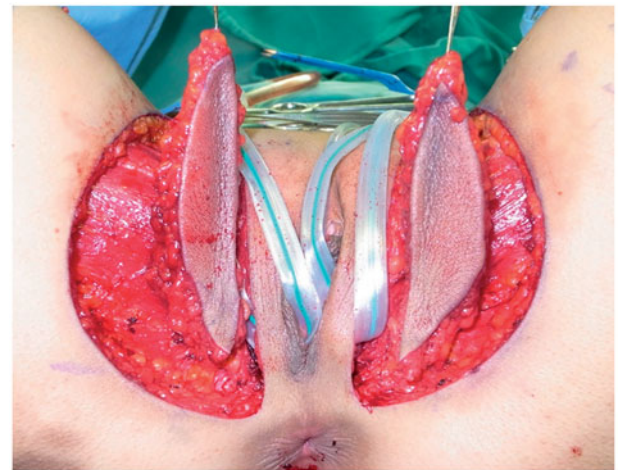


**Figure 2.** Findings of transvaginal ultrasonography the uterus was absent and the distance from the tip of the vaginal caecum to the retroperitoneum was 2.7 cm.

Moreover, in order to make the vaginal vestibule, a vertical incision was made in the narrowed vaginal vestibule of the anal side along with the remaining vaginal mucous membrane and subsequently, part of the anal side of the skin flap was inserted (Figure 7(a)). The donor site was temporarily reefed along the contour line of the inner proximal region of the thigh (Figure 7(b)).



**Figure 3.** Design of PTF the bilateral skin flaps were extended towards the anal side, thereby reconstructing the vaginal vestibule using these parts.



**Figure 4.** Harvesting PTF.

Postoperative prognosis: The skin flap was completely engrafted and the insertion of the silicon prosthesis inside the vagina was commenced for preventing stenosis of the intravaginal cavity two weeks following surgery. Subsequently, the prosthesis was inserted for three months and the length of the vagina was maintained at 8 cm when examined at two years and four months following surgery. No stenosis of the vaginal vestibule or opening of the vagina was observed (Figure 8(a)) and a substantially satisfactory vulva shape was thereby acquired (Figure 8(b)).

### Discussion

Vaginoplasty with respect to the absence of a vagina is classified into nonsurgical method and a surgical

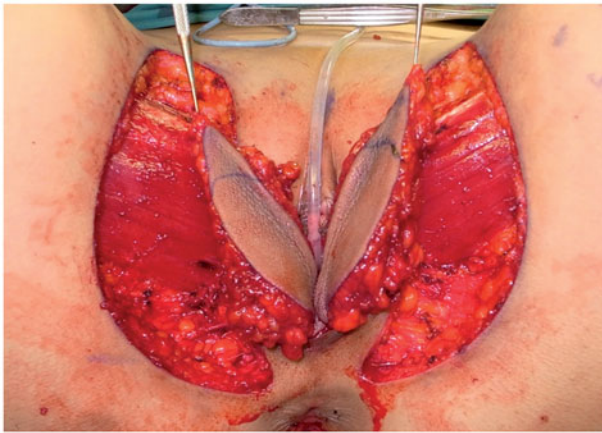


Figure 5. Moving PTF to the centre.

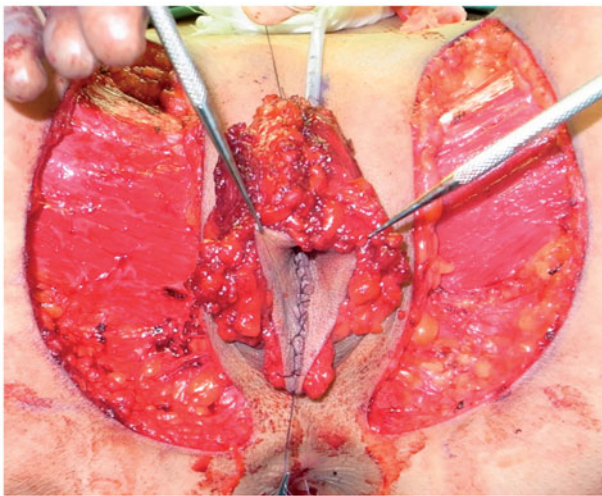


Figure 6. Creating an intravaginal cavity.

method. Regarding the nonsurgical method, the Frank method has been reported, which uses a prosthesis for continuously extending the vaginal vestibule mucous membrane and making an intravaginal cavity [9]. However, this method is accompanied by pain and the lumen of the vagina is often found to be insufficient, so the surgical method is currently carried out in most cases.

Regarding the surgical method, the McIndoe method has been reported, wherein the connective tissue between the bladder and the rectum is exfoliated to create space and skin grafting is carried out in the inner wall of the space [1]. Although this method is only slightly invasive, in many cases, stenosis is caused due to postoperative scar contracture, thereby making it difficult to maintain an intravaginal cavity of sufficient width and length. With methods that use the intestinal tract such as the Ruge method, which uses a sigmoid colon [2], the intravaginal cavity is the intestinal tract mucous membrane, thus making it less prone to cause stenosis. However, it has some problems in that the surgery becomes highly invasive due to a laparotomy and an odour as well as contamination on the underwear due to the secretion of intestinal tract fluids. In the method using skin flaps, many reports exist including the Gracilis Myocutaneous Flap [5], PTF [6], Labia Minora Flap [7] and so on. The shape of the lumen may be maintained regardless of being configured from skin tissues of the intravaginal cavity, and it is a method that is less invasive compared to those using the intestinal tract. Currently, PTF using

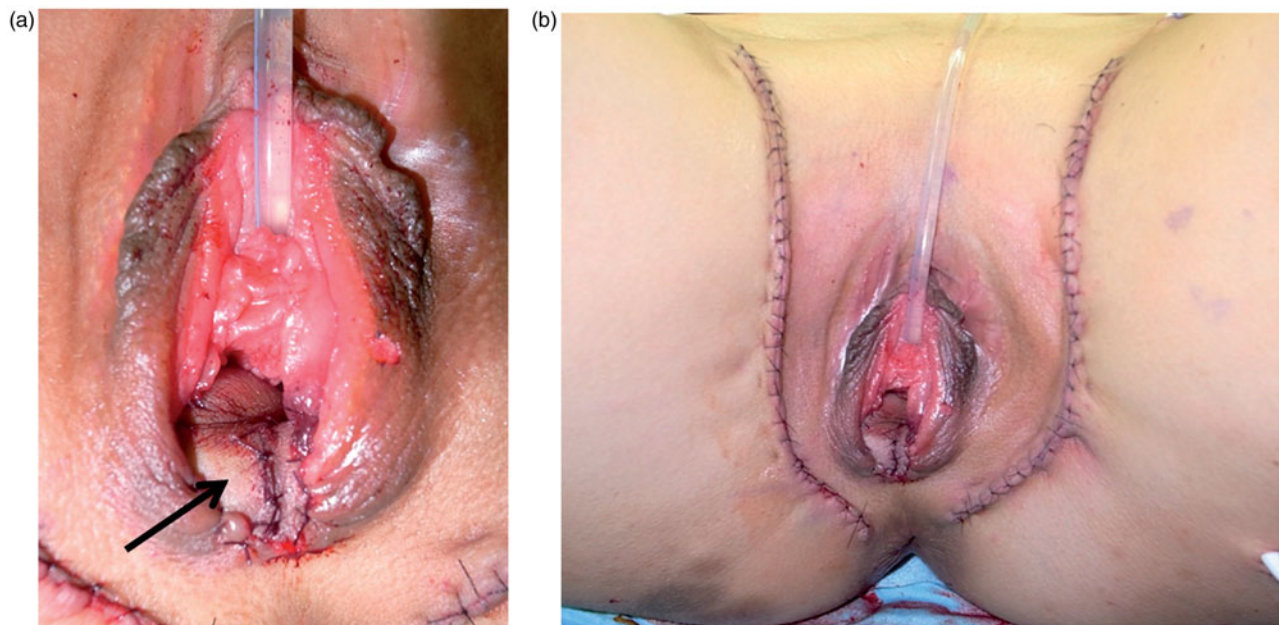
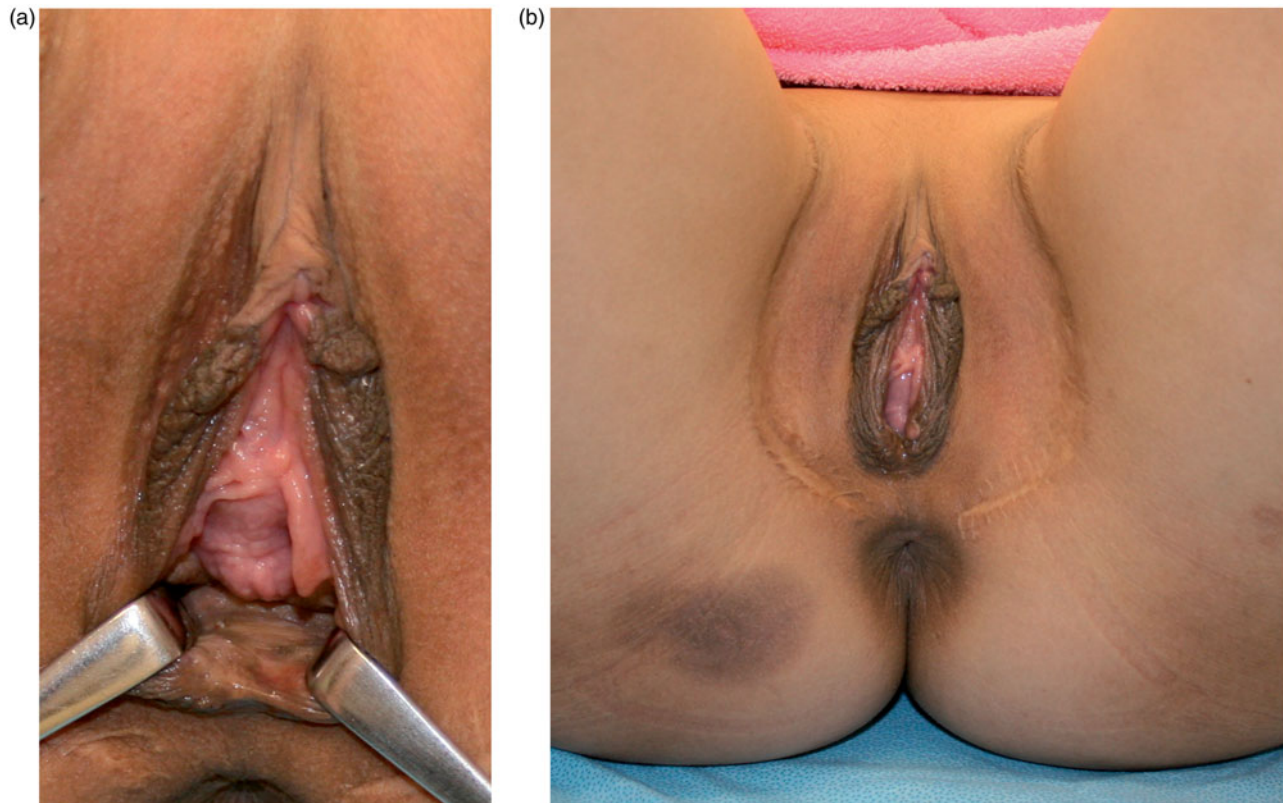


Figure 7. Post operation (a) a vertical incision was made in the narrowed vaginal vestibule of the anal side and part of the anal side of PTF was inserted. (b) The donor site was temporarily reefed along the contour line of the inner proximal region of the thigh.



**Figure 8.** (a) Two years and four months following surgery. No stenosis of the vaginal vestibule or opening of the vagina was observed. (b) Two years and four months following surgery. No stenosis of the vaginal vestibule or opening of the vagina was observed.

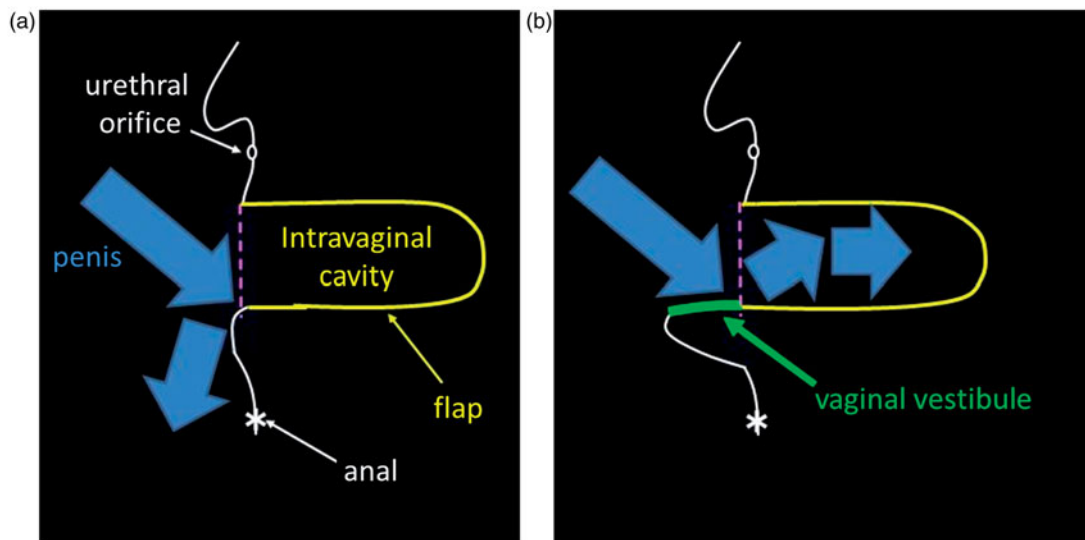
skin flaps are commonly carried out with respect to vaginoplasty, allowing stable blood circulation and non-exposed donors. PTF has a problem that dysfunction may occur during sexual intercourse due to pubic hair in the vicinity of the vulva [10]. However, no pubic hair was congenitally observed in the present case, so vaginoplasty by PTF was thus selected.

PTF is also referred to as a Singapore flap and it was first reported in 1989 by Wee et al. [6] for use with respect to vaginoplasty. PTF is a fascial skin flap which uses the posterior labial artery as the feeding vessel. Wee et al. carried out an anatomical study with respect to PTF and reported that the posterior labial artery dominates the skin from the perineum to the proximal part of the thigh in the vicinity of the femoral triangle for nourishment, with the range of sampling skin flap potentially being safely harvested, and thus having a size of  $15 \times 6$  cm in adults. Moreover, they mention that PTF becomes the sensory skin flap because the posterior labial nerve branching from the perineal nerve is the dominant nerve of PTF.

However, there are several problems associated with the original method reported by Wee et al. First, the vagina is an organ shaped with a lumen structure, so it is designed to have a cylindrical shape in the

original method. Accordingly, a disordered natural skin line of the inner proximal region of the thigh and deformation of the perineum may be caused due to unreasonable reefing when closing the donor following sampling of the skin flap. Second, the skin suture line of the opening of the vagina may become round in shape, causing scar contracture to the entire circumference and leading to stenosis of the opening of the vagina. Third, in the original method, wherein reconstruction of the intravaginal cavity was the main purpose, reconstruction of the vaginal vestibule was not carried out. It is believed that these facts may cause some dysfunction during sexual intercourse in addition to cosmetic problems of the perineum.

Accordingly, when designing the skin flap, the following three ingenuities were contrived: (1) When the outer labia skin is included in the skin flap, the shape of the outer labia becomes greatly distorted, so the skin flap outside the outer labia (mainly above the thigh) was redesigned. (2) The width of the wound border of the skin flap was made to be a width allowing sufficient reefing by drawing the wound border of the femoral part, and was designed such that the suture wound matches the natural skin line of the inner proximal region of the thigh. (3) It was designed



**Figure 9.** Scheme of sexual intercourse. (a) No reconstruction of the vaginal vestibule. (b) Reconstruction of the vaginal vestibule.

such that the skin suture line of the opening of the vagina does not become round by extending the skin flap to the anal side, and such that the vaginal vestibule may be created at that site. Due to these procedures, the shape of the outer labia was maintained and a cosmetically satisfying result was thus achieved by making the suture scar along the natural skin line of the inner proximal region of the thigh. Moreover, due to the part of the skin flap on the anal side becoming sandwiched in the opening of the vagina, it was possible to prevent scar contracture (stenosis in the opening of the vagina) over the entire circumference. The disadvantage of this method is a limitation of the length of harvested PTF.

Regarding the vaginal vestibule, the part in between the bilateral labia minora is anatomically defined as the vaginal vestibule. The vaginal vestibule has a function of reacting to the glans of the penis during sexual intercourse and leading it to the vagina. Accordingly, when there is no vaginal vestibule due to vaginoplasty, the penis cannot be smoothly inserted during sexual intercourse, thereby causing functional disabilities (Figure 9(a)). It is believed that reconstructing the vaginal vestibule with a part of the skin flap in this study was very important to achieve smooth sexual intercourse (Figure 9(b)).

Although the patient has not experienced sexual intercourse to date following the surgery, sexual intercourse is cosmetically and functionally possible, and it is believed that our techniques for performing vaginoplasty is therefore a useful method.

In this study, vaginoplasty including the vaginal vestibule was carried out with respect to vaginal aplasia cases with a narrowing of the vaginal vestibule

using PTF. In this case, the vagina was reconstructed using a skin flap while the vaginal vestibule of the anal side was simultaneously reconstructed. Taking into consideration the fact that the vaginal vestibule plays a major role in sexual intercourse, it is believed that this new method is therefore useful and satisfactory in terms of functional reconstruction.

### Disclosure statement

The authors declare that there is no conflict of interest regarding the publication of this paper.

### References

1. McIndoe A. The treatment of congenital absence and obliterative conditions of the vagina. *Br J Plast Surg.* 1950;2:254–267.
2. Ruge E. Ersatz der Vagina durch die Flexur mittele Laparotomie. *Deut Med Wschr.* 1914;40:120–122.
3. Davydov SN. Colpopoiesis from the peritoneum of the utero-rectal space. *Obstet Gynecol.* 1969;12:55–57.
4. Vecchiotti G. Le neo-vagina dans le syndrome de Rokitansky–Kuster–Hauser. *Rev Med Suisse Romande.* 1979;99:593–601.
5. McCraw JB, Massey FM, Shanklin KD, et al. Vaginal reconstruction with gracilis myocutaneous flaps. *Plast Reconstr Surg.* 1976;58:176–183.
6. Wee JT, Joseph VT. A new technique of vaginal reconstruction using neurovascular pudendal-thigh flaps: a preliminary report. *Plast Reconstr Surg.* 1992;90:270–274.
7. Flack CE, Barraza MA, Stevens PS. Vaginoplasty: combination therapy using labia minora flaps and lucite dilators-preliminary report. *J Urol.* 1993;150:654–656.
8. Lilford RJ, Sharpe DT, Thomas DF. Use of tissue expansion techniques to create skin flaps for

- vaginoplasty. Case report. *Br J Obstet Gynaecol.* 1988;95:402–407.
9. Frank R. The formation of an artificial vagina without operation. *Am J Obstet Gynecol.* 1938;35:1053–1055.
  10. Monstrey S, Blondeel P, van Landuyt K, et al. The versatility of the pudendal thigh fasciocutaneous flap used as an island flap. *Plast Reconstr Surg.* 2001;107:719–725.