

Primary pancreatic lymphoma camouflaged under the umbrella of spectrum of neuroendocrine tumors in somatostatin receptor imaging

ABSTRACT

Primary pancreatic lymphomas are very rare as compared to other pancreatic neoplasms. However, unlike carcinomas, pancreatic lymphoma is treatable with satisfactory cure rates. Somatostatin receptor (SSTR) positron emission tomography/computed tomography (PET/CT) with ⁶⁸Ga-DOTANOC is a well-established diagnostic modality in the management of neuroendocrine tumors (NETs). Over the years, it has been evident that any neoplasm with SSTR expression shows increased tracer uptake, lymphoma, being the most prominent one. Herein, we report a case of pancreatic mass, suggested as NET on fine-needle aspiration cytology referred to us for staging. Whole-body ⁶⁸Ga-DOTANOC PET/CT scan showed a large pancreatic mass with peripancreatic nodes, level I cervical nodes, cardiac, and left testicular masses which were initially thought to be possibly metastatic from pancreatic NET. However, immunohistochemistry (IHC) of the specimen was suggestive of B-cell Non-Hodgkin's Lymphoma. The present case emphasizes that pancreatic lymphoma is one of the potential differentials for pancreatic masses apart from NET on SSTR imaging. Noteworthy is the fact, that IHC plays a poignant role in the evaluation and is a mandatory tool for the management of tumors. Moreover, the whole imaging picture and clinical scenario ought to be given utmost importance for giving an affirmative diagnosis on imaging. SSTR expression in lymphomas may further obviate a remote fact that peptide receptor radionuclide therapy can be considered as an end of the line treatment for refractory lymphomas.

Keywords: Pancreatic neuroendocrine tumors, primary pancreatic lymphoma, somatostatin receptor expression in lymphoma, somatostatin receptor imaging

INTRODUCTION

Gastrointestinal lymphoma constitutes about 15%–20% of all extranodal non-Hodgkin's lymphoma (NHL). Primary pancreatic lymphoma (PPL) is a very rare tumor that may impersonate pancreatic carcinoma. Its incidence is <2% of all extranodal malignant lymphomas, and 0.5% of all pancreatic masses are PPLs.^[1] Unlike adenocarcinoma, PPL is treatable with acceptable cure rates of 30%. The treatment consists of radiotherapy and chemotherapy with best results when both are given concurrently.^[1]

Somatostatin receptor (SSTR) positron emission tomography/computed tomography (PET/CT) with ⁶⁸Ga-DOTANOC is a well-established diagnostic modality in the management of neuroendocrine tumors (NETs).

Ga68-DOTANOC binds to SSTR subtypes 2, 3, and 5 with high affinity and is also known as a pansomatostatin receptor imaging agent. Over the years, it has been evident that any neoplasm with SSTR expression shows increased tracer uptake, lymphoma, being the most prominent one. Both low grade and malignant lymphomas with increased

NIKITA SAMPATHIRAO, M. INDIRANI, S. SHELLEY

Department of Nuclear Medicine and PET/CT, Apollo Hospitals, Chennai, Tamil Nadu, India


Address for correspondence: Dr. Nikita Sampathirao, Department of Nuclear Medicine and PET/CT, Apollo Hospitals, 21 Greams Lane, Off Greams Road, Chennai - 600 006, Tamil Nadu, India. E-mail: drnikitasrao@outlook.com

Submission: 28-Dec-19, **Accepted:** 29-Jan-20, **Published:** 22-Jul-20

This is an open access journal, and articles are distributed under the terms of the Creative Commons Attribution-NonCommercial-ShareAlike 4.0 License, which allows others to remix, tweak, and build upon the work non-commercially, as long as appropriate credit is given and the new creations are licensed under the identical terms.

For reprints contact: WKHLRPMedknow_reprints@wolterskluwer.com

How to cite this article: Sampathirao N, Indirani M, Shelley S. Primary pancreatic lymphoma camouflaged under the umbrella of spectrum of neuroendocrine tumors in somatostatin receptor imaging. World J Nucl Med 2020;19:306-9.

Access this article online	
Website: www.wjnm.org	Quick Response Code 
DOI: 10.4103/wjnm.WJNM_96_19	

SSTR expression have been described, but at a much lower level compared to NETs.^[2]

CASE REPORT

A 53-years-old male, suspected case of pancreatic NET, was referred to the Department of Nuclear Medicine and PET/CT for SSTR imaging. On review of history, he had presented with a progressively increasing epigastric pain associated with belching of 1-month duration. During clinical assessment at a local place, an epigastric mass was noted. Endoscopic ultrasound (EUS) elucidated a large mass arising from the body of pancreas. EUS-guided fine-needle aspiration cytology (FNAC) was done which showed clusters of cells in organoid pattern with stripped nuclear chromatin, suggestive of organoid neoplasm, possibly NET [Figure 1a and b]. 5 mCi of ⁶⁸Ga-DOTANOC was injected intravenously and PET/CT imaging was performed 45 min later from the vertex of skull till mid-thigh.

Maximum intensity projection images [Figure 2] demonstrated SSTR overexpressing abnormal lesions in the neck, mediastinum, abdomen, and testes. A large mass arising from the body of pancreas with increased ⁶⁸Ga-DOTANOC uptake was seen, measuring 10 cm × 14 cm × 14.6 cm in size, encasing and occluding the porto-mesenteric confluence and a standardized uptake value (SUV_{max}) of 16.8 [Figure 3].

⁶⁸Ga-DOTANOC avid left testicular mass measuring 11.7 cm × 8.1 cm × 11.0 cm with SUV_{max} of 6.5 [Figure 4] and poorly enhancing lesion along the inferior wall of the right atrium with size of 4.3 cm × 2.5 cm and SUV_{max} 5.8 [Figure 5a] were seen. Prominent peripancreatic nodes were seen which did not show any SSTR expression. However, enlarged level I cervical nodes were noted with increased ⁶⁸Ga-DOTANOC uptake (SUV_{max} 4.9) [Figure 5b]. No significant mediastinal lymph nodes were seen. Overall imaging features were suggestive of pancreatic NET with nodal metastases and possibly cardiac and testicular deposits

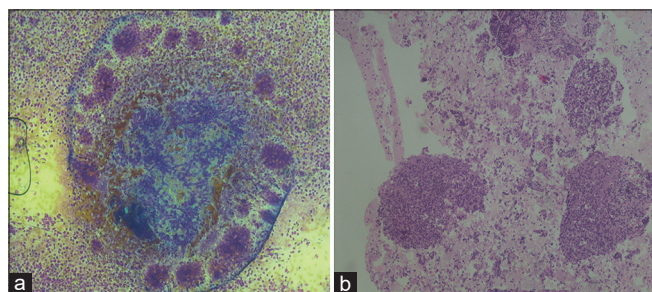


Figure 1: (a) Fine-needle aspiration cytology slide of pancreatic mass showing clusters of cells in organoid pattern (b) dyscohesive cells with darkly staining nuclei and scanty cytoplasm with many cells entrapped in fibrin and stripped nuclear chromatin

However, immunohistochemistry (IHC) was suggestive of B-cell NHL. The cells stained positive for leukocyte common antigen, CD3 and CD20 positive and negative for chromogranin A and synaptophysin.

DISCUSSION

PPL are extremely rare tumors as compared to other pancreatic malignancies. They account for fewer than 2% of extranodal malignant lymphomas and 0.5% of all pancreatic masses.^[1] It shows a male predominance (male-female ratio is 7:1).^[3] Clinical spectrum includes abdominal pain (83%), abdominal mass (58%), weight loss (50%), jaundice (37%), acute pancreatitis (12%), small-bowel obstruction (12%), and diarrhea (12%).^[1] Classic symptoms of NHL are present in <2% of patients.^[3]

⁶⁸Ga-DOTA SSTR PET/CT has become the mainstay in the management of NETs over the years. However, with time, it became evident that false positives are common on SSTR imaging, such as tracer uptake in uncinate process of pancreas, inflammatory cells, meningioma, and other cancers such as renal cell carcinoma, primitive neuroectodermal tumor, and lymphoma.

Increased ⁶⁸Ga-DOTANOC uptake is known to occur in all the malignant lymphomas, in particular, diffuse large B-cell and Hodgkin's Lymphoma.^[2] Even indolent lymphomas such as mucosa-associated lymphatic tissue (MALT) expressed SSTRs. Previously, SSTR imaging was considered an imaging modality to distinguish between gastric and extragastric MALT.^[4]

The pancreatic mass in our case was suspicious for a NET based on FNAC, for which the ⁶⁸Ga-DOTANOC PET/CT was performed.

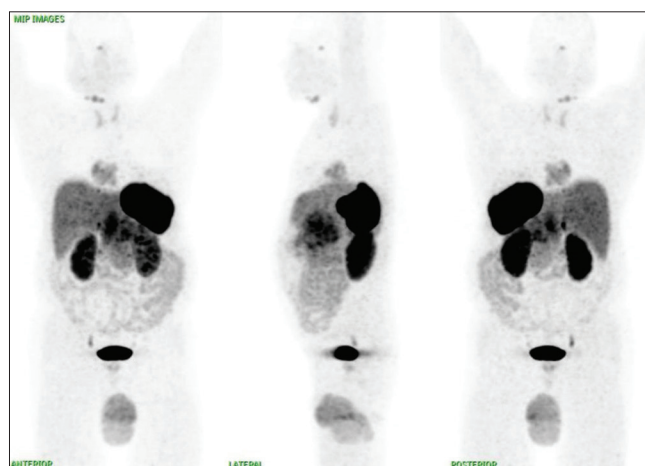


Figure 2: Maximum intensity projection of ⁶⁸Ga-DOTANOC positron emission tomography/computed tomography scan showing abnormal increased tracer uptake in the neck, mediastinum, abdomen, and testicular region

PPL is a potential differential for pancreatic NET. Two morphologic patterns of PPL are noted,^[5] well-circumscribed tumor predominantly in the head of pancreas or diffuse enlargement of the pancreas. Imperative findings to distinguish a PPL from other tumors would be a bulky, well-circumscribed mass, noninfiltrating, no duct dilatation, and no nodes below the level of renal veins.^[5] On the other hand, NETs are usually small, well-circumscribed or large masses, hyperenhancing on arterial phase, located within the pancreas displacing surrounding structures with or without nodes. Frequently liver metastases are identified prior to the primary NET.^[6]

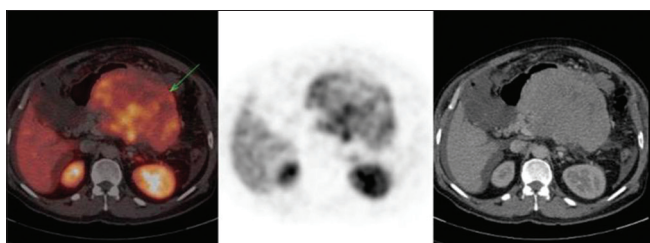


Figure 3: Axial positron emission tomography/computed tomography images of the abdomen showing large well-circumscribed poorly enhancing pancreatic mass arising from the body of the pancreas

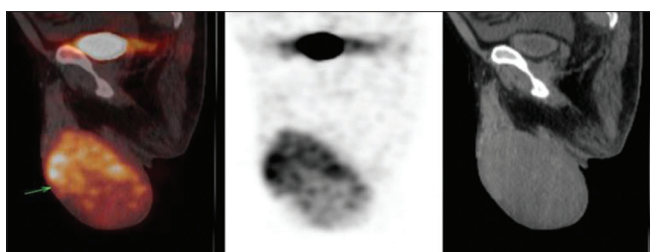


Figure 4: Sagittal section of genitalia showing a large testicular mass with increased ⁶⁸Ga-DOTANOC uptake

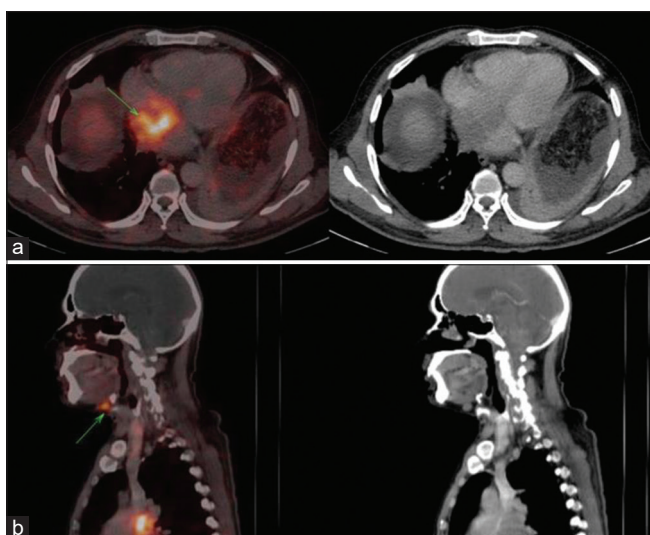


Figure 5: (a) Axial section of mediastinum showing ill-defined soft-tissue lesion involving the right atrium with increased somatostatin receptor expression. (b) Sagittal section of head-and-neck region showing ⁶⁸Ga-DOTANOC avid enlarged level IA cervical nodes

Testicular metastases in a pancreatic cancer are very rare with very few cases reported in literature with pancreatic adenocarcinoma.^[7] The whole testis can be involved diffusely causing pain. Cardiac metastasis is infrequent for any type of malignancy. Since the deposits were on the right side of the heart, metastases could not be ruled out in our case. The involvement of cervical nodes should have raised a possibility of different pathology but giving poignance to the cytology findings, it was considered metastatic.

PPL is an unavoidable differential for pancreatic NETs on SSTR imaging. Distinguishing PPL from pancreatic NET is necessary as both have contrasting management plans and carry different prognoses. It is also necessary to have a proper biopsy correlation with IHC which should be a prerequisite for performing an SSTR imaging. IHC is of the utmost value as it is well known that ⁶⁸Ga-DOTA-SST uptake is indirectly proportional to the proliferative index of the NET. This case emphasizes that the overall picture of disease should be considered for arriving at a diagnosis, especially in SSTR PET/CT where false-positive uptake is common.

Owing to the findings that lymphomas express SSTRs, there have been multiple studies evaluating SSTR imaging in diagnosis and therapy of lymphomas. It was noted that the density of SSTR expression in lymphomas was inferior to NETs and might not be sufficient for a therapeutic effect. However, lymphomas are radiosensitive tumors and SSTR expression established by an SSTR PET/CT widens horizons for peptide receptor radionuclide therapy (PRRT), which is well known for its palliative effect.^[8] Hence, more prospective clinical trials have to be encouraged to assess the therapeutic effect of PRRT with Lu177-DOTATATE for refractory lymphomas.

CONCLUSION

PPL, though a rare entity, is a probable differential for suspected pancreatic NETs on SSTR imaging. Differentiating both the tumors is necessary as the management differs. ⁶⁸Ga-DOTANOC SSTR PET/CT should be performed after a thorough confirmation with tissue biopsy and IHC. False positives are common in SSTR imaging and the total scan findings as a whole and clinical scenario should be kept in mind before arriving at a diagnosis.

Declaration of patient consent

The authors certify that they have obtained all appropriate patient consent forms. In the form the patient(s) has/have given his/her/their consent for his/her/their images and other clinical information to be reported in the journal. The patients

understand that their names and initials will not be published and due efforts will be made to conceal their identity, but anonymity cannot be guaranteed.

Financial support and sponsorship

Nil.

Conflicts of interest

There are no conflicts of interest.

REFERENCES

1. Baysal B, Kayar Y, Ince AT, Arici S, Türkmen I, Şentürk H. Primary pancreatic lymphoma: A rare cause of pancreatic mass. *Oncol Lett* 2015;10:1701-3.
2. Ruuska T, Ramírez Escalante Y, Vaitinen S, Gardberg M, Kiviniemi A, Marjamäki P, *et al.* Somatostatin receptor expression in lymphomas: A source of false diagnosis of neuroendocrine tumor at 68 Ga-DOTANOC PET/CT imaging. *Acta Oncol* 2018;57:283-9.
3. Saif MW. Primary pancreatic lymphomas. *JOP* 2006;7:262-73.
4. Raderer M, Traub T, Formanek M, Virgolini I, Osterreicher C, Fiebiger W, *et al.* Somatostatin-receptor scintigraphy for staging and follow-up of patients with extraintestinal marginal zone B-cell lymphoma of the mucosa associated lymphoid tissue (MALT)-type. *Br J Cancer* 2001;85:1462-6.
5. Merkle EM, Bender GN, Brambs HJ. Imaging findings in pancreatic lymphoma: Differential aspects. *AJR Am J Roentgenol* 2000;174:671-5.
6. Lewis RB, Lattin GE Jr., Paal E. Pancreatic endocrine tumors: Radiologic-clinicopathologic correlation. *Radiographics* 2010;30:1445-64.
7. Cormio L, Sanguedolce F, Massenio P, Di Fino G, Bruno M. Testicular metastasis as the first clinical manifestation of pancreatic adenocarcinoma: A case report. *J Med Case Rep* 2015;2015:139-41.
8. Dalm VA, Hofland LJ, Mooy CM, Waaijers MA. Somatostatin Receptors in Malignant Lymphomas: Targets for Radiotherapy?. *J Nucl Med* 2004;45:8-16.