

Received: 2015.01.29
Accepted: 2015.02.08
Published: 2015.06.03

ISSN 1941-5923
© Am J Case Rep, 2015; 16: 338-340
DOI: 10.12659/AJCR.893719

Rhabdomyomatous Mesenchymal Hamartoma of the Face Causing Trigeminal Neuralgia

Authors' Contribution:
Study Design A
Data Collection B
Statistical Analysis C
Data Interpretation D
Manuscript Preparation E
Literature Search F
Funds Collection G

CDEF 1 **Leon Ray White, Jr**
ABCDEF 2 **Vaidehi Agrawal**
BCDE 3 **Lisa Sutton**
ABCDEF 4 **Aiysha C. Balbosa**

1 Texas College of Osteopathic Medicine, University of North Texas Health Science Center, Fort Worth, TX, U.S.A.
2 Department of Surgery, Driscoll Children's Hospital, Corpus Christi, TX, U.S.A.
3 Department of Pathology, Driscoll Children's Hospital, Corpus Christi, TX, U.S.A.
4 Department of Otolaryngology, Driscoll Children's Hospital, Corpus Christi, TX

Corresponding Author: Aiysha C. Balbosa, e-mail: aiysha.balbosa@dchstx.org
Conflict of interest: None declared

Patient: Female, 14
Final Diagnosis: Rhabdomyomatous mesenchymal hamartoma (RMH) presenting with trigeminal neuralgia (TN)
Symptoms: Facial Swelling • numbness • pain
Medication: —
Clinical Procedure: Surgical removal of RMH
Specialty: Otolaryngology

Objective: Unusual clinical course

Background: Rhabdomyomatous mesenchymal hamartoma (RMH) is a benign, potentially pigmented lesion that occurs in the head and neck region. It generally consists of haphazardly arranged skeletal muscle with adipose tissue, blood vessels, collagen and nerve fibers and is largely asymptomatic. Trigeminal neuralgia is pain due to compression of the trigeminal nerve. TN may be idiopathic or associated with lesion-mediated compression.

Case Report: We describe the case of a 14-year-old female presenting with trigeminal neuralgia (TN) associated with RMH. On initial consultation, the patient presented with a history of right-sided lower facial swelling, numbness, and pain. Evaluation by various specialists confirmed TN. Surgical resection of the lesion resolved the condition and pathology confirmed RMH.

Conclusions: This is the first case report demonstrating RMH-mediated TN. Surgical resection of the RMH is a safe management approach for this diagnosis.

MeSH Keywords: Acute Pain • Craniofacial Abnormalities • Pediatrics • Trigeminal Nerve

Abbreviations: RMH – rhabdomyomatous mesenchymal hamartoma; TN – trigeminal neuralgia

Full-text PDF: <http://www.amjcaserep.com/abstract/index/idArt/893719>



989



—



1



10



Background

RMH has been described as a congenital lesion of the dermis consisting of haphazardly arranged skeletal muscle with adipose tissue, blood vessels, collagen, and nerve fibers [1]. The lesion classically presents in the head and neck region as a palpable mass ranging anywhere from a few millimeters to 2 centimeters in length [2]. With the exception of 20.8% of congenital abnormalities associated with RMH, RMH is largely asymptomatic and are removed for aesthetic reasons [1–4].

Here, we present the case of a 14-year-old girl with a history of intermittent right-sided lower facial swelling, numbness, and pain congruent with TN aggravated by manipulation of a facial lesion. No additional craniofacial abnormalities, hearing, or balance disturbances were noted. The pathology report confirmed the lesion as RMH. This represents a rare case of RMH causing TN.

Trigeminal neuralgia or tic douloureux is primarily a clinical diagnosis and is often confused with other disease processes, such as migraine, pain secondary to dental caries, sinusitis, referred pain from impacted teeth, Costen's syndrome, and traumatic or senile paresthesia [3]. The etiology of TN may be either idiopathic or associated with lesion-mediated compression of the trigeminal nerve [3–5]. TN is associated with a sharp pain on 1 side of the face, produced when a “trigger point” is manipulated. The pain radiates in a similar pattern every time upon manipulation of the trigger point [3,4]. The pain may be distributed to any anatomical location around the trigger point [4]. Our case represents the first reported case of RMH associated with TN.

Case Report

A 14-year-old girl was referred by her primary care physician for a 5-month history of intermittent right ear and facial pain. There was associated right-sided facial pain, swelling, numbness, and tingling. Her medical history was significant for asthma, gastroesophageal reflux, and several visits to the Emergency Department. In the Emergency Department, she presented with right facial pain, swelling, dysphagia,odynophagia, and difficulty speaking due to pain. The pain was described as sharp with radiation down to her jaw. The pain was made worse after she manipulated a small bump under the right side of her bottom lip. A non-contrast CT of her head and neck with soft tissues was performed, which was negative for any significant findings. Tegretol was prescribed for pain management and neurology consultation was recommended. Neurological evaluation diagnosed the patient with trigeminal neuralgia and dermatology evaluation was recommended for evaluation of the painful lesion. The patient was subsequently referred to our Pediatric Otolaryngology Department for further evaluation.

Upon our initial evaluation, an 8-mm subcutaneous lesion was noted on the right lower lip inferior to the vermilion border. The lesion was firm, tender on palpation, and without overlying skin discoloration. No pathological features were noted and the patient was asymptomatic; therefore, continued medical management was recommended and the patient was advised to follow-up in 6 weeks for re-evaluation. Upon follow-up, the patient had persistent intermittent right facial pain, numbness, and swelling. On physical exam, the facial lesion had increased in size; therefore, surgical excision of the lesion was recommended.

The procedure was performed in the operating room under general anesthesia. The lesion was removed en block and send to pathology for further evaluation. Upon palpitation, no additional lesions were noted. The pathology report indicated a 0.8×0.6-cm lesion with histologic features diagnostic of RMH. Microscopic examination of the skin showed normal epidermis with disorganized bundles of skeletal muscle in the lower dermis (Figure 1A) and extending into the subcutaneous fibroadipose tissue (Figure 1B). A haphazard arrangement of skeletal muscle bundles could be seen adjacent to adnexal structures in the reticular dermis (Figure 1C). The skeletal muscle bundles retained normal striations (Figure 1D). At the 2-week and 3-month follow-up visits, the patient reported complete resolution of all symptoms.

Discussion

The first reported case of RMH dates back to 1986. The etiology of RMH continues to be elusive but recent literature indicates an association of RMH with abnormal migration of embryonic mesodermal tissue [6]. RMH is frequently associated with congenital abnormalities, such as craniofacial defects, Goldenhar syndrome, Dellemane syndrome, and amniotic band syndrome [6,7]. RMH may also present as nodules in the absence of congenital abnormalities. However, even in conjunction with craniofacial defects, RMH are largely asymptomatic. Similar to RMH, the etiology of TN is also largely ambiguous. Multiple sclerosis, vascular or lesions causing nerve compression, are associated with 50% of TN cases. The remaining 50% of TN cases are idiopathic [8,9].

Our case was due to an extra-cranial, benign lesion compressing the lower division of the trigeminal nerve. Further pain was localized to the upper and lower face and included the skin and soft tissues, the maxilla, mandible, teeth, tongue, and the eye and thus involved the lower division of the trigeminal nerve on the right side of the face. One previous study reported an intracranial rhabdomyoma – specifically, a choristoma – in association with TN. The choristoma does not have the characteristic aberrantly arranged skeletal muscle fibers with fibrocartilage and nervous tissue [8].

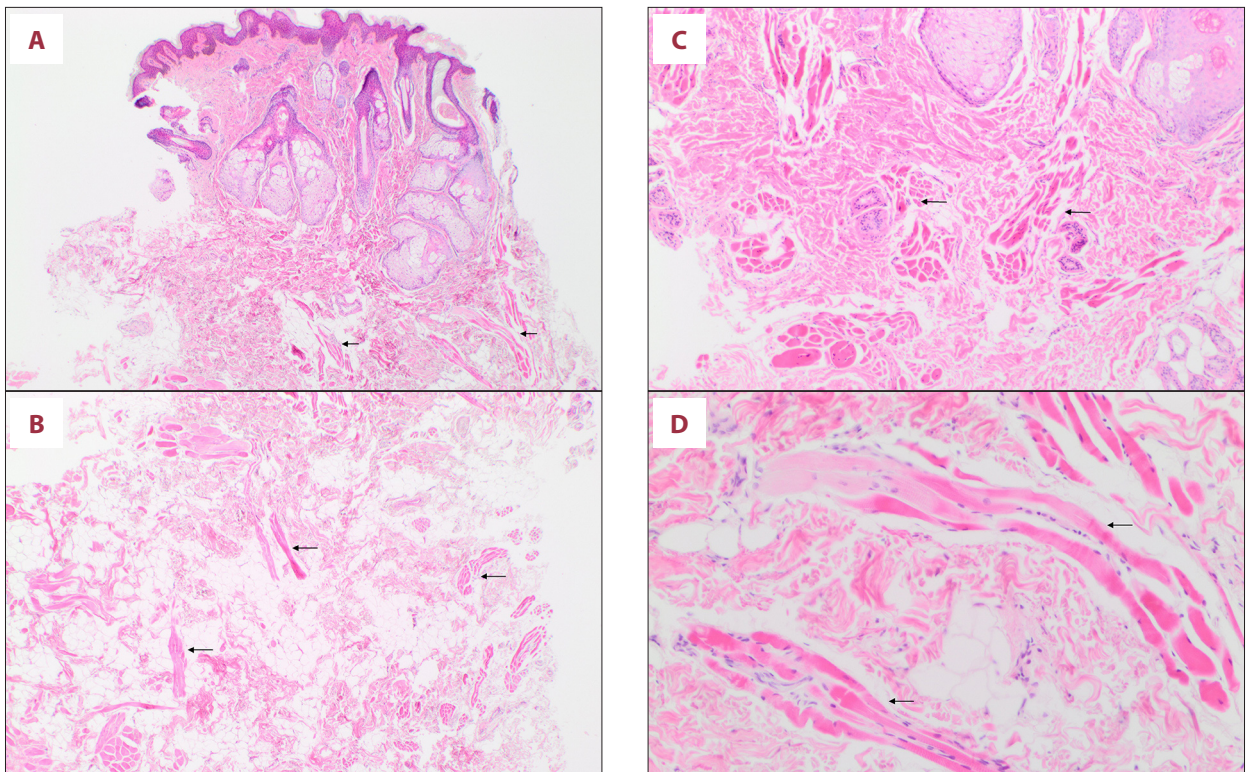


Figure 1. Biopsy of the skin lesion stained with H&E demonstrates disorganized bundles of skeletal muscle (arrows) in the (A) epidermis and lower dermis at 20x, in the (B) subcutaneous tissue at 20x, (C) adjacent to adnexal structures at 40x, and with (D) normal striations of skeletal muscle at 100x.

Pathology reports of the RMH indicated aberrantly arranged skeletal muscle, as in our resected nodule. However, it is important to note that there are other benign intracranial lesions that are sometimes associated with TN, including acoustic neuromas, cerebellopontine angle meningiomas, and sphenopetrosal meningiomas [9]. Schwannomas are the most commonly reported primary tumor associated with cranial nerves. Schwannomas have been reported to be associated with the cranial nerves III, V, VIII, and XII. Other tumors have also been reported to exist with cranial nerves VII and X [2,10]. These lesions are, however, rare [10]. Unlike other tumors, which represent a small subset of TN cases, our lesion was extra-cranial

and was benign [7,9]. This is the first reported case of a RMH associated with TN.

Conclusions

This is the first case of RMH-mediated TN in a patient. Clinicians should be aware of this association for managing future patients.

Conflict of interest

The authors have no conflict of interest of declare.

References:

1. Vechio AD, Nakajima E, Pinto D et al: Rhabdomyomatous mesenchymal hamartoma presenting as haemangioma on the upper lip: A case report with immunohistochemical analysis and treatment with high-power lasers. *Case Rep Dent*, 2013; 2013: 943953
2. Enzinger FM, Weiss SW: *Soft Tissue Tumors*. Mosby 1995. St Louis, MO. 535
3. Bourgoyne JR: Trifacial Neuralgia: Treatments, history, and observations. *Oral Surg Oral Med Oral Pathol*, 1948; 8: 689-705
4. Munro D: Trigeminal Neuralgia. *The Apollonian*, 1940; 15: 605-11
5. Dandy WE: An operation for the cure of tic douloureux. *Arch Surg*, 1925; 18: 687
6. Saliba J, Razaghi F, Nguyen VH et al: Rhabdomyomatous mesenchymal hamartoma in the head and neck region: Case reports and literature review of a rare occurrence. *Int J of Pediatr Otorhinolaryngol Extra*, 2012; 7: 149-53
7. Rosenberg AS, Kirk J, Morgan MB: Rhabdomyomatous mesenchymal hamartoma: an unusual dermal entity with a report of two cases and review of the literature. *J Cutan Pathol*, 2002; 29: 238-43
8. Zwick DL, Livingston K, Clapp L et al: Intracranial trigeminal nerve rhabdomyoma/choristoma in a Child: A case report and discussion of possible histogenesis. *Human Pathol*, 1989; 20: 390-92
9. Scheithauer B, Erdogan S, Rodriguez F et al: Malignant Peripheral nerve sheath tumors of cranial nerves and intracranial contents: A clinicopathologica study of 17 cases. *Am J Surg Pathol*, 2009; 33: 325-38
10. Puca A, Meglio M, Tamburrini G, Vari R: Trigeminal involvement in intracranial tumours: Anatomical and clinical observations on 73 Patients. *Acta Neurochir*, 1993; 125: 47-51