


Application and Development of Minimally Invasive Techniques in the Treatment of Spinal Metastases

Technology in Cancer Research & Treatment
Volume 21: 1–7
© The Author(s) 2022
Article reuse guidelines:
sagepub.com/journals-permissions
DOI: 10.1177/15330338221142160
journals.sagepub.com/home/tct


Lu Hao, PhD¹ , Xi Chen, MD², Qiuyan Chen¹, Yuzhong Xu, MD³, Baozhu Zhang, MD⁴, Zhe Yang⁵, Junxin Zhong⁶, and Qing Zhou, PhD² 

Abstract

With the improvement of medical technology, the quality of life and prognosis of patients with malignant tumors have been greatly improved, and surgical treatment strategies for patients with spinal metastatic tumors have received extensive attention. Traditional open surgery for spinal metastases has problems such as large trauma, slow recovery, and influence on subsequent systemic treatment. Minimally invasive spine surgery has similar clinical outcomes to traditional open surgery, but minimally invasive spine surgery is less invasive and has a shorter recovery time. Minimally invasive spine surgery was initially applied to non-neoplastic diseases such as spinal degeneration and trauma, and was gradually applied to the treatment of spinal metastatic tumors and spinal deformities. For patients with spinal metastases, a shorter recovery time is helpful for early postoperative radiotherapy, thereby achieving a more satisfactory tumor control effect. This review discusses the application of minimally invasive spine surgery in the treatment of spinal metastatic tumors from the concept, surgical purpose, indications, and surgical selection, so as to provide reference for clinical practice.

Keywords

spinal metastases, minimally invasive, percutaneous vertebroplasty, decompression, internal fixation

Abbreviations

MISS, minimally invasive spinal surgery; PKP, percutaneous kyphoplasty; PVP, percutaneous vertebroplasty.

Introduction

In patients with malignant tumors, about 20% to 40% of patients will develop spinal metastases, and 10% to 20% of them have clinical symptoms related to spinal metastases.¹ With the wide application of targeted therapy, chemotherapy, immunotherapy, stereotactic radiotherapy, and other technologies, the prognosis of patients with malignant tumors has been significantly improved, which makes more patients with spinal metastases need surgical treatment.

Traditional open surgery for spinal metastases has problems such as large trauma, slow recovery, and influence on subsequent systemic treatment. In recent years, some scholars have proposed new strategies for the treatment of spinal metastatic tumors, emphasizing the role of minimally invasive spinal surgery (MISS) in the treatment of metastatic tumors.^{2–4} Minimally invasive spine surgery can achieve similar therapeutic effects as traditional open surgery while reducing surgical trauma. In addition, a study found that compared with

traditional open surgery, minimally invasive techniques have fewer complications and better efficacy when applied to the treatment of special types of vertebral metastases (involving

¹ Science and Education Department, Shenzhen Baoan Shiyuan People's Hospital, Shenzhen, China

² Central Laboratory, The People's Hospital of Baoan Shenzhen, The Second Affiliated Hospital of Shenzhen University, Shenzhen, China

³ Department of Clinical Laboratory, The People's Hospital of Baoan Shenzhen, The Second Affiliated Hospital of Shenzhen University, Shenzhen, China

⁴ Department of Radiotherapy, The People's Hospital of Baoan Shenzhen, The Second Affiliated Hospital of Shenzhen University, Shenzhen, China

⁵ The First Clinical Medical School, Southern Medical University, Guangzhou, China

⁶ The Second Clinical Medical School, Southern Medical University, Guangzhou, China

Corresponding Author:

Qing Zhou, Central Laboratory, The People's Hospital of Baoan Shenzhen, The Second Affiliated Hospital of Shenzhen University, Shenzhen, China.
Email: bayzq@sina.com



the posterior edge of the vertebral body).⁵ The following is a summary of several interventional methods commonly used in the treatment of spinal metastases in recent years.

In addition, spinal orthoses can reduce musculoskeletal dysfunction. It has been widely used all over the world. The orthosis is to install orthoses on the limbs and trunk of the human body to prevent or correct the injury of the human spine and provide functional assistance, so that the patient can lose the double cane and walk like a normal person.

Concept of MISS

MISS is a surgical strategy aimed at reducing operative approach-related injuries, emphasizing the integrity and functionality of the spine and reducing the iatrogenic effects of surgery on normal spinal structures (paravertebral muscles, ligaments, bony structures, etc.).⁶ Compared with traditional open surgery, any improvement in reducing operative approach-related injuries can be referred to as MISS. MISS was initially applied to non-neoplastic diseases such as spinal degeneration and trauma, and was gradually applied to the treatment of spinal metastatic tumors and spinal deformities.^{7,8}

For the treatment of spinal metastatic tumors, the common MISS procedures mainly include: (1) small incision decompression: by using minimally invasive channels, dilators and other instruments, the length of the incision is shortened and the length of dissection of the paravertebral muscles is reduced. At the same time, the same surgical operation as traditional open surgery can be completed; (2) percutaneous pedicle screw fixation: percutaneous pedicle screw placement under fluoroscopic guidance can reduce the impact on the paraspinal muscles; (3) percutaneous vertebroplasty (PVP) and percutaneous kyphoplasty (PKP): are relatively mature percutaneous surgical techniques, mainly used to increase the strength of the vertebral body; (4) endoscopy-assisted spine surgery: including a variety of complete endoscopy, minimally invasive endoscopy, and dual-channel endoscopy; (5) radiofrequency ablation: the mechanism is that the heat destroys the periosteum, bone cortex and nerve endings in the tumor tissue, and the heat effect causes the tumor cells to undergo degeneration and necrosis; and (6) radioactive seeds implantation: the radioactive source implanted in the tumor can continuously release radiation to kill the tumor.

Timing and Indications for MISS

The main purposes of MISS for spinal metastases are: (1) to restore the stability of the spine and decompress the spinal cord and nerve roots under the premise of small surgical trauma; (2) to create a certain safety distance between the lesion and the spinal cord for subsequent stereotactic radiotherapy treatment.⁹ MISS is mostly palliative surgery, and curing the tumor is not the goal, so solitary spinal metastases should be regarded as a relative contraindication to surgery.

Patients with spinal metastases who receive MISS should first have indications for open surgery: (1) radiotherapy-resistant

tumors; (2) severe spinal cord compression, with epidural spinal cord compression graded as grade 2–3¹⁰; (3) spinal instability, Spine Instability Neoplastic Score > 7 points¹¹; (4) life expectancy > 3 months. Due to the limited space available to the operator for small incision decompression surgery, the surgical field is generally limited to a single segment; due to the screw diameter of percutaneous pedicle screw fixation is large, so it is generally suitable for the lower thoracic and lumbar spine. The following conditions should also be met^{12–14}: (1) the main lesion is located in the lower thoracic and lumbar spine; (2) the main lesion is a single segment.

Surgical Strategies for MISS

With the development of radiotherapy technology, orthopedic physicians need to pay attention to the important role of radiotherapy when formulating treatment plans for spinal metastatic tumors, and distinguish between radiosensitive and radioresistant tumors. Common radiation-sensitive tumors include lymphoma, myeloma, small cell lung cancer, and seminoma; radiation-resistant tumors include gastrointestinal tumors, melanoma, non-small cell lung cancer, renal cancer, and most sarcomas.^{15,16}

It should be noted that the standard of radiosensitivity classification is the sensitivity to traditional external beam radiation, and stereotactic radiosurgery can also achieve good results in the treatment of traditional radiation-resistant tumors.^{17,18} Therefore, for radiation-resistant tumors, stereotactic radiosurgery is feasible after MISS to further control the tumor. For radiation-sensitive tumors, radiotherapy should be selected as far as possible even if there is dural compression (except acute paraplegia)¹⁹ (Figure 1).

Small Incision Decompression

When radiation-resistant tumors metastasize to the spine and severely compress the spinal cord and nerve roots, open surgery must be performed to open the spinal canal and/or nerve root canal in the diseased segment, remove the lamina and facet joints, and clean up the tumor tissue around the spinal cord and nerves. If possible, the tumor on the ventral side of the dura should also be removed as much as possible, that is, “separation surgery”—creating a safe space around the dura.⁹

For spinal instability caused by resection of spinous processes, facet joints, and lamina, percutaneous pedicle screw fixation should be used for fixation. Because the operation of percutaneous pedicle screw fixation is done percutaneously, and there is no need to strip the paraspinal muscles, the surgical incision is limited to a single segment, and there is no need to extend the incision to both sides for screw placement. Compared with traditional open surgery, the incision of percutaneous pedicle screw fixation is greatly shortened, and the postoperative drainage volume and hospitalization time are also shortened accordingly, which is conducive to the rapid recovery of patients and the early implementation of adjuvant therapy.^{20,21}

Small incision decompression can choose the posterior median approach or the paramedian approach. The posterior median approach is the same as the approach of traditional

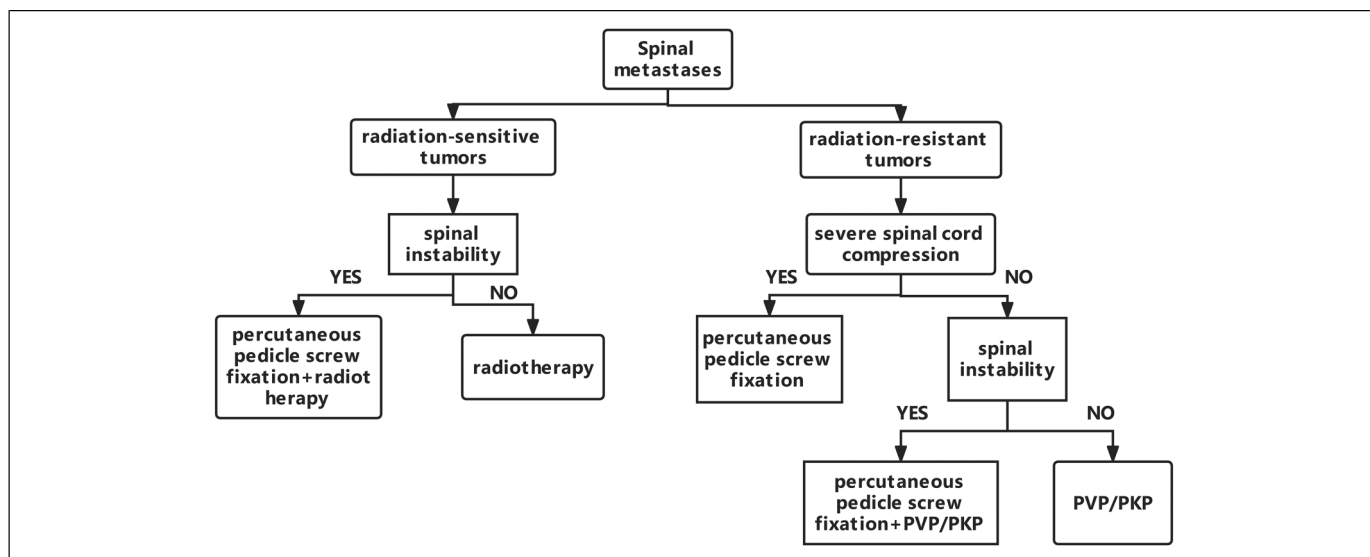


Figure 1. Strategies for selecting minimally invasive spinal surgery for spinal metastatic tumors.

open surgery, and the paramedian approach can be used to resect the facet joints. Since the operation of bone grafting may have the risk of residual tumor tissue, so generally only decompression is performed without fusion.

Small incision decompression also has certain limitations. First, shortening the length of the incision will inevitably reduce the exposure of the operative field, resulting in a relatively deeper exposure and affecting intraoperative observation. This requires the operator to be very familiar with the spinal anatomy and the distribution of lesions. Second, when a relatively bulky instrument such as a rongeur is used, the obstructed view by the instrument may interfere with the operator's operation. The use of long and thin endoscopic instruments can help to improve this problem. Third, intraoperative bleeding may make the narrow operative field less clear. It is very important to judge the blood supply of the tumor before surgery (the enhancement degree of contrast-enhanced CT and angiography, etc.), and preoperative vascular embolization is recommended for tumors that are expected to bleed more. If hemostasis is difficult due to the exposure problem during the operation, the incision should be resolutely extended to improve the exposure, and serious intraoperative complications caused by the pursuit of "minimally invasive" must be avoided.

Percutaneous Pedicle Screw Fixation

Percutaneous pedicle screw fixation is generally used to treat patients with destabilization of the spine, especially posterior column injuries. If the patient's life expectancy is relatively long, long-segment fixation can be selected; if the patient's life expectancy is relatively short, short-segment fixation can be selected, and cemented pedicle screws can be used for further reinforcement. There are a large number of screws (six or eight screws) for long-segment fixation, and it is difficult to control and adjust the curvature and length of the connecting

rods when connecting bilateral connecting rods. When placing the connecting rod into the screw tail cap, it needs to penetrate the paravertebral muscle longitudinally and accurately place it into the tail cap. This step is sometimes particularly difficult and takes a lot of time. When it is particularly difficult to place the connecting rod, operator can choose to extend the incision to increase the exposure of the operative field, or directly change two to four of the screws into ordinary pedicle screws, and place the rod under the direct vision of the operator.

There are also some drawbacks to this technique. The screws used in percutaneous pedicle screw fixation are cannulated screws, which are generally thicker in diameter and can only be used for the lower thoracic and lumbar vertebrae, and generally cannot be used for the upper thoracic and cervical vertebrae. Due to the use of percutaneous screw placement, it is impossible to refer to the bony anatomical landmarks under direct vision like traditional open surgery during the operation. The screw must be placed under fluoroscopic guidance, which will inevitably bring more radiation exposure. At the same time, repeated adjustment and finding the nail entry point will prolong the operation time.

PVP and PKP

Pure PVP and PKP are mainly used in cases where the anterior vertebral body is involved but the posterior attachment is not seriously involved, and can effectively enhance the strength of the anterior vertebral body. For lesions involving the posterior column, a combination of pedicle screws is required to increase the stability. When performing small incision decompression, it is sometimes impossible and unnecessary to clear the lesions in the anterior vertebral body. In this case, PVP and PKP can be used in combination to enhance the strength of the anterior column, and the puncture needle is placed into the vertebral body under direct vision.

The advantage of combining PVP, PKP with small incision decompression is that in addition to observing fluoroscopic images during the injection of bone cement, it is also possible to check whether there is leakage of bone cement in the spinal canal under direct vision. Once a leak occurs, it can be cleaned and remedied immediately. When the posterior wall of the vertebral body is excised more or is severely damaged, the use of a syringe to inject cement has a greater risk of spinal canal leakage. In this case, the dough-phase bone cement can be directly placed into the vertebral body defect under direct vision. If the fixation of cement mass is unsatisfactory, a pedicle screw can be screwed inward to fix it on the connecting rod before the cement solidifies to further fix the cement and prevent postoperative bone cement from damaging the spinal cord.

For patients with unclear pathological diagnosis, biopsy of the lesion can be performed before PVP or PKP. In addition, ablation can be flexibly selected according to the condition of the lesion, and attention should be paid to cooling the lesion after ablation to avoid the rapid solidification of cement due to excessive temperature.

Endoscopy-Assisted Spine Surgery

Currently, endoscopy-assisted spinal surgery is rarely used for spinal metastatic tumors. Small incision decompression surgery has a narrow operative field, which is extremely inconvenient to observe the pedicle and vertebral body with deep anatomical positions; while endoscopy can provide a clear and wide-angle field of view, but the operating space under endoscopy is more limited. If the two are combined, that is, endoscopy-assisted small incision decompression combined with percutaneous pedicle screw fixation, it may be the development direction of MISS in the future. In recent years, there have been some case reports of the application of endoscopic technique and percutaneous endoscopic interlaminar decompression in the treatment of spinal metastatic tumors.^{22,23} The authors pointed out that the narrow operation space, difficult hemostasis, and long learning curve are the shortcomings of simple endoscopic techniques. There are literature of endoscopy-assisted thoracic vertebral tumor resection using the posterolateral approach, and successful reconstruction of the anterior column, but all of them are open operations.²⁴⁻²⁶

Radiofrequency Ablation

Radiofrequency ablation treatment refers to the use of bone puncture needles and other equipment under the guidance of imaging equipment (such as DSA or CT) to extend the radiofrequency electrode needle into the tumor, causing coagulation necrosis of the tumor through high temperature. Radiofrequency ablation can quickly kill malignant tumor cells, relieve pain, and improve the quality of life of patients. It has been widely used in the treatment of benign and malignant bone tumors.^{27,28}

Indications of radiofrequency ablation for spinal metastatic tumors: patients with long expected survival (>6 months) are not suitable for open surgery due to various reasons; no

spinal cord, nerve root compression or there are symptoms of nerve root compression but refuse to undergo open surgery; no more than three vertebrae treated at one time.

Callstrom et al.²⁹ determined the safety and efficacy of radiofrequency ablation in reducing pain, improving quality of life, and reducing analgesic use in patients with bone metastases. Results showed that radiofrequency ablation was effective and safe for the relief of severe pain from spinal metastases, with 8 of 10 patients using analgesics reporting a decrease in analgesic use sometime after radiofrequency ablation, no serious complications were observed. Kashima et al.³⁰ retrospectively evaluated the clinical application of radiofrequency ablation in patients with bone metastases from hepatocellular carcinoma. Pain was relieved in all but one patient with bone metastases. The 1-, 2-, and 3-year survival rates were 34.2%, 19.9%, and 10.0%, respectively, and the median survival time was 7.1 months. The authors believed that radiofrequency ablation is a safe, useful, and feasible treatment option for pain relief in patients with bone metastases from hepatocellular carcinoma. Ha et al.³¹ describe 4 cases of metastatic spinal lesions (2 hepatomas, 1 lung cancer, 1 breast cancer) treated with intraoperative radiofrequency ablation following decompression fusion and internal fixation to control the lesions and limit tumor recurrence. At the 3-month follow-up, most patients experienced effective pain relief and improved functional status. There were no complications associated with this procedure, and the patients were doing well with no progressive deterioration of the vertebral lesions.

However, in the treatment of vertebral metastases with altered vertebral mechanics, although radiofrequency ablation can quickly kill the tumor, it cannot fundamentally solve the problem of poor spinal stability in patients with metastases. In addition, Pezeshki et al.³² found that the use of radiofrequency ablation alone in the treatment of vertebral metastases resulted in a decrease in the stability of the posterior vertebral wall, increasing the risk of posterior vertebral bulge and vertebral pathological fractures. In addition, due to the thermal conductivity of bone tissue, when radiofrequency ablation is used alone in the treatment of vertebral metastases without additional protective measures, the thermal effect produced by it can also increase the risk of damage to adjacent important neurovascular vessels. Currently, there is low level of evidence for the superiority of stereotactic radiosurgery over conventional fractionated radiation or decompressive surgery. Nevertheless, it should be mentioned that stereotactic radiosurgery and stereotactic body radiotherapy of metastases in the spine, are considerably safe with reported low risk of grade 3 toxicity, including nausea, vomiting, diarrhea, fatigue, trismus and pain.

Radioactive Seeds Implantation

Radioactive seed implantation is a treatment method in which a radioactive source is implanted into the tumor, and the radiation is continuously released to kill the tumor. In the past 10 years, the role of radiation therapy combined with surgery in the treatment of spinal metastases has become increasingly obvious. This technology can provide the best clinical radiation dose

without damage to the spinal cord and nerve tissue. After radio-surgery, pedicle screw fixation and PKP can be performed.³³ As a synthetic radioactive iodine particle, ¹²⁵I is usually used in brachytherapy, which can carry enough radiation dose to accurately reach the lesion, produce good therapeutic effect and cause little damage to normal tissue. In the initial half-life, radioactive iodine particle can destroy most tumor cells, which is beneficial to delay the progression of spinal lesions and facilitate subsequent clinical operations.

Yang et al.³³ investigated the clinical efficacy of digital subtraction angiography-guided PVP combined with ¹²⁵I seed implantation in the treatment of spinal bone metastases. During the follow-up period, 98.0% of the patients had significant relief of back pain. Postoperative VAS scores and Karnofsky performance scores were significantly different from preoperative scores. Compared with the conventional treatment group, the clinical efficacy of PVP combined with ¹²⁵I seed implantation was significantly improved ($p < 0.05$). The authors believe that PVP combined with ¹²⁵I seed implantation can effectively relieve pain, restore the stability of the spine, improve the quality of life of patients, and reduce the incidence of paraplegia in patients with spinal bone metastases. The study also pointed out that although osteogenic spinal metastatic tumor lesions obstruct the needle insertion route and high intravertebral pressure can increase the risk of bone cement leakage, the results of this study showed that osteogenic spinal metastatic tumors are not a contraindication to PVP.

Wang et al.³⁴ retrospectively evaluated the safety and efficacy of ¹²⁵I seed implantation in the treatment of spinal metastases. The minimum peripheral dose of ¹²⁵I seed was 90–140 Gy with a median of 120 Gy. Follow-up showed that the local control rates at 1, 2, 3, and 5 years were 63%, 47%, 31%, and 3%, respectively; the 1-, 2-, 3-, and 5-year survival rates were 74%, 56%, 43%, and 43%, respectively, with a median of 33 months. They pointed out that determining the dose of ¹²⁵I seed implantation through the treatment plan can ensure the exact therapeutic effect in the half-life of the radioactive seed, and reduce the discomfort and life inconvenience of patients. Although patients still developed tumor recurrence and metastasis during the follow-up, the local control effect of this technique was satisfactory.

It is worth noting that Yang et al.³³ pointed out that excessive implantation of seeds may lead to myopathy, and radiation toxicity and injury can occur immediately or delayed postoperatively. Although this technology has good local control effect, how to avoid late tumor recurrence and metastasis still needs further research and improvement.

MISS vs. Traditional Open Surgery

Several studies have compared MISS with traditional open surgery to explore the benefits of MISS in patients with spinal metastases. Pennington et al.¹⁴ conducted a systematic review of 346 patients in 9 literatures published before 2017, including 183 patients in the MISS group and 163 in the traditional open surgery group. Results showed that the surgical outcomes were comparable between the two groups, but the MISS

procedure resulted in less blood loss, shorter hospital stays, and lower complication rates. Due to the large heterogeneity of the included literature, the authors were unable to perform a meta-analysis. Hansen-Algenstaedt et al.²⁰ conducted a prospective matching study to match 30 patients in the MISS group and 30 patients in the traditional open surgery group by age, tumor type, Tokuhashi score, Tomita score. The results showed that the postoperative visual analog scale, Frankel score and Karnofsky score of the two groups were significantly improved compared with those before the operation, but there was no difference between the groups. The average blood loss and average hospital stay in the MISS group were significantly lower than those in the traditional open surgery group, but the fluoroscopy time was longer. There was no significant difference in the operative time and complication rate.

Zhu et al.²¹ retrospectively analyzed the clinical data of 154 patients, including 49 patients in the MISS group and 105 in the traditional open surgery group. The results showed that the average bleeding volume, drainage volume, and hospital stay in the MISS group were lower than those in the traditional open surgery group; the operation time, neurological function and perioperative complication rates were not significantly different between the two groups.

Based on the above results, it can be known that for patients with spinal metastases, MISS is comparable to traditional open surgery in terms of improving neurological function, relieving pain symptoms, and improving patients' quality of life, and has advantages in reducing blood loss and shortening hospitalization time. MISS may have a lower complication rate than traditional open surgery, but is non-inferior to traditional open surgery in terms of operative time. But these views still need high-quality evidence to support.

At the same time, chemotherapy may also be an effective initial treatment option, even in the presence of severe and relatively acute spinal cord compression. Taking Ewing's sarcoma of spine as an example, adjuvant treatment after spinal resection and reconstruction can reduce the risk of local recurrence and improve the long-term survival rate. In this case, surgery or radiotherapy combined with high-intensity chemotherapy is considered effective.³⁵

Summary and Outlook

With the maturity and improvement of surgical techniques, the application scope of MISS has expanded from simple degenerative diseases and traumatic diseases to the field of spinal tumors, and it has obvious advantages over traditional open surgery in terms of reducing surgical trauma and shortening recovery time. Without affecting the effect of surgery, a shorter recovery time can help to carry out postoperative radiotherapy earlier, so as to achieve a more satisfactory tumor control effect. Therefore, orthopedic physicians should choose a less invasive method for suitable patients. Computer navigation and robot-assisted surgery may also be applied to MISS in patients with spinal metastases in the future, to further reduce surgical trauma and improve patient prognosis.

Acknowledgments

None.

Declaration of Conflicting Interests

The author(s) declared no potential conflicts of interest with respect to the research, authorship, and/or publication of this article.

Ethics Statement for Animal and Human Studies


None.

Funding

This work was supported by Science and Technology Bureau of Baoan (2021JD067), Natural Science Foundation of Guangdong Province of China (2022A1515012438), Shenzhen Foundation of Science and Technology (RCBS20200714114918239).

ORCID iDs

Lu Hao  <https://orcid.org/0000-0002-4305-7766>

Qing Zhou  <https://orcid.org/0000-0002-8721-1534>

References

- Galgano M, Fridley J, Oyelese A, et al. Surgical management of spinal metastases. *Expert Rev Anticancer Ther.* 2018;18(5):463-472.
- Barzilai O, Fisher CG, Bilsky MH. State of the art treatment of spinal metastatic disease. *Neurosurgery.* 2018;82(6):757-769.
- Gasbarrini A, Li H, Cappuccio M, et al. Efficacy evaluation of a new treatment algorithm for spinal metastases. *Spine.* 2010;35(15):1466-1470.
- Quraishi NA, Gokaslan ZL, Boriani S. The surgical management of metastatic epidural compression of the spinal cord. *J Bone Jt Surg Br Vol.* 2010;92(8):1054-1060.
- Donnelly DJ, Abd-El-Barr MM, Lu Y. Minimally invasive muscle sparing posterior-only approach for lumbar circumferential decompression and stabilization to treat spine metastasis—technical report. *World Neurosurg.* 2015;84(5):1484-1490.
- Kanehira E, Lirici MM, Melzer A, et al. 25 years of SMIT: the past, the present, and the future of minimally invasive therapy. *Minim Invasive Ther Allied Technol.* 2013;22(4):194-199.
- Park J, Ham DW, Kwon BT, et al. Minimally invasive spine surgery: techniques, technologies, and indications. *Asian Spine J.* 2020;14(5):694-701.
- Vaishnav AS, Othman YA, Virk SS, et al. Current state of minimally invasive spine surgery. *J Spine Surg (Hong Kong).* 2019;5(Suppl 1):S2-s10.
- Moussazadeh N, Laufer I, Yamada Y, Bilsky MH. Separation surgery for spinal metastases: effect of spinal radiosurgery on surgical treatment goals. *Cancer Control.* 2014;21(2):168-174.
- Bilsky MH, Laufer I, Fourny DR, et al. Reliability analysis of the epidural spinal cord compression scale. *J Neurosurg Spine.* 2010;13(3):324-328.
- Fisher CG, DiPaola CP, Ryken TC, et al. A novel classification system for spinal instability in neoplastic disease: an evidence-based approach and expert consensus from the Spine Oncology Study Group. *Spine.* 2010;35(22):E1221-E1229.
- Barzilai O, McLaughlin L, Amato MK, et al. Minimal access surgery for spinal metastases: prospective evaluation of a treatment algorithm using patient-reported outcomes. *World Neurosurg.* 2018;120:e889-e901.
- Molina CA, Gokaslan ZL, Sciubba DM. A systematic review of the current role of minimally invasive spine surgery in the management of metastatic spine disease. *Int J Surg Oncol.* 2011;2011:598148.
- Pennington Z, Ahmed AK, Molina CA, et al. Minimally invasive versus conventional spine surgery for vertebral metastases: a systematic review of the evidence. *Ann Transl Med.* 2018;6(6):103.
- Zhang HR, Li JK, Yang XG, et al. Conventional radiotherapy and stereotactic radiosurgery in the management of metastatic spine disease. *Technol Cancer Res Treat.* 2020;19:1533033820945798.
- Maranzano E, Bellavita R, Rossi R, et al. Short-course versus split-course radiotherapy in metastatic spinal cord compression: results of a phase III, randomized, multicenter trial. *J Clin Oncol.* 2005;23(15):3358-3365.
- Chang UK, Cho WI, Lee DH, et al. Stereotactic radiosurgery for primary and metastatic sarcomas involving the spine. *J Neuro-Oncol.* 2012;107(3):551-557.
- Gerszten PC, Burton SA, Quinn AE, et al. Radiosurgery for the treatment of spinal melanoma metastases. *Stereotact Funct Neurosurg.* 2005;83(5-6):213-221.
- Gerszten PC, Mendel E, Yamada Y. Radiotherapy and radiosurgery for metastatic spine disease: what are the options, indications, and outcomes? *Spine.* 2009;34(22 Suppl):S78-S92.
- Hansen-Algenstaedt N, Kwan MK, Algenstaedt P, et al. Comparison between minimally invasive surgery and conventional open surgery for patients with spinal metastasis: a prospective propensity score-matched study. *Spine.* 2017;42(10):789-797.
- Zhu X, Lu J, Xu H, et al. A comparative study between minimally invasive spine surgery and traditional open surgery for patients with spinal metastasis. *Spine.* 2021;46(1):62-68.
- Henderson FJr, Hubbard ZS, Jones S, et al. Endoscopic decompression of epidural spinal metastasis causing lumbar radiculopathy through a transforaminal approach: report of two cases. *AME Case Reports.* 2020;4:2.
- Şentürk S, Ünsal Ü. Percutaneous endoscopic interlaminar decompression of hypervascular spinal metastases. *World Neurosurg.* 2020;134:182-186.
- McLain RF. Video-assisted spinal cord decompression reduces surgical morbidity and speeds recovery in patients with metastasis. *J Surg Oncol.* 2005;91(3):212-216.
- Mobbs RJ, Nakaji P, Szkandera BJ, Teo C. Endoscopic assisted posterior decompression for spinal neoplasms. *J Clin Neurosci.* 2002;9(4):437-439.
- St Clair SF, McLain RF. Posterolateral spinal cord decompression in patients with metastasis: an endoscopic assisted approach. *Surg Technol Int.* 2006;15:257-263.
- Knudsen M, Riishede A, Lücke A, et al. Computed tomography-guided radiofrequency ablation is a safe and effective treatment of osteoid osteoma located outside the spine. *Dan Med J.* 2015;62(5):A5059.
- Greenwood TJ, Wallace A, Friedman MV, et al. Combined ablation and radiation therapy of spinal metastases: a novel multimodality treatment approach. *Pain Physician.* 2015;18(6):573-581.

29. Callstrom MR, Charboneau JW, Goetz MP, et al. Painful metastases involving bone: feasibility of percutaneous CT- and US-guided radiofrequency ablation. *Radiology*. 2002;224(1):87-97.
30. Kashima M, Yamakado K, Takaki H, et al. Radiofrequency ablation for the treatment of bone metastases from hepatocellular carcinoma. *AJR Am J Roentgenol*. 2010;194(2):536-541.
31. Ha KY, Kim YH, Yoo TW. Intraoperative radiofrequency ablation for metastatic spine disease: report of 4 cases and review. *Eur J Orthop Surg Traumatol: Orthop Traumatol*. 2013;23(Suppl 2): S129-S134.
32. Pezeshki PS, Davidson S, Murphy K, et al. Comparison of the effect of two different bone-targeted radiofrequency ablation (RFA) systems alone and in combination with percutaneous vertebroplasty (PVP) on the biomechanical stability of the metastatic spine. *Eur Spine J*. 2016;25(12):3990-3996.
33. Yang Z, Tan J, Zhao R, et al. Clinical investigations on the spinal osteoblastic metastasis treated by combination of percutaneous vertebroplasty and (125)I seeds implantation versus radiotherapy. *Cancer Biother Radiopharm*. 2013; 28(1):58-64.
34. Wang J, Yuan H, Ma Q, et al. Interstitial 125I seeds implantation to treat spinal metastatic and primary paraspinal malignancies. *Med Oncol*. 2010;27(2):319-326.
35. Boussios S, Hayward C, Cooke D, et al. Spinal ewing sarcoma debuting with cord compression: have we discovered the thread of ariadne? *Anticancer Res*. 2018;38(10):5589-5597.