

# The effect of physician experience on the measurement reliability of the Reimers' hip migration percentage in children with cerebral palsy

PINAR DORUK ANALAN, MD<sup>1)\*</sup>, EMINE ECE YILMAZ, MD<sup>1)</sup>, MEHMET ADAM, MD<sup>1)</sup>,  
BERRIN LEBLEBICI, MD<sup>1)</sup>

<sup>1)</sup> Department of Physical Medicine and Rehabilitation, Faculty of Medicine, Baskent University Adana Research and Education Center: Kazım Karabekir Cad. 4227. Sok. No 37 Yüreğir, Adana, Turkey

**Abstract.** [Purpose] Reimers' hip migration percentage (MP) is commonly used to document the extent of hip displacement in children with cerebral palsy (CP). However, factors such as poor administration of pelvic radiographs, a lack of concentration, inexperience, or a busy clinical environment may result in variations in the MP measurements. The aim of this study was to compare the differences in the MP results of two physiatrists with varying levels of experience to determine the role of experience in the measurement's accuracy. [Subjects and Methods] This retrospective study included 62 hip radiographs of 31 children with spastic CP. Two physiatrists with different experience levels calculated the baseline MP on two occasions six weeks apart. Correlations, intra- and inter-rater reliabilities, and differences in the MPs were compared. [Results] Correlations and inter- and intra-rater reliabilities of the measurements were excellent. There were no statistically significant intra- or inter-rater differences for either of the two measurement points. Inter-rater correlations for each session were 0.94. [Conclusion] Experience does not appear to be a factor in the evaluation of MP, and inter-rater differences do not cause problems regarding patient follow-up. Therefore, repeated pelvic radiographs are not necessary in the evaluation of MP in children with CP unless indicated.

**Key words:** Reimers' hip migration index, Cerebral palsy, Experience

(This article was submitted Jun. 11, 2015, and was accepted Jul. 23, 2015)

## INTRODUCTION

Cerebral palsy (CP) is the most common cause of physical disability in children in developed countries<sup>1)</sup>. CP is a group of disorders associated with the development of movement and posture that can cause activity limitations attributed to non-progressive disturbances that may occur in the development of the fetal or infant brain<sup>1)</sup>. Hip displacement is a common, severe problem in children with CP, and its development is thought to be related to age, Gross Motor Function Classification System (GMFCS) level, or CP subtype<sup>2-5)</sup>. Unfortunately, hip displacement in children with CP is silent in the initial stages and is difficult to detect via physical examination alone. However, detection is possible with repeated radiographic evaluations in conjunction with regular physical examinations.

To optimize the screening procedure, knowledge of the

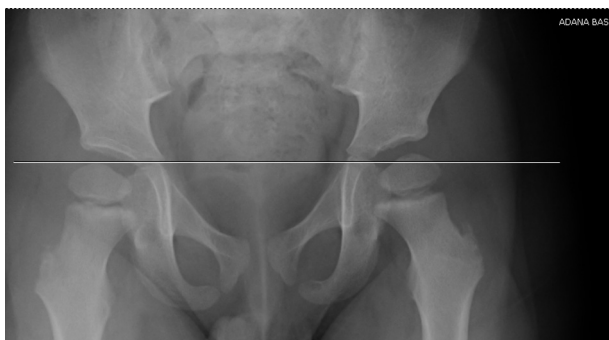characteristics of children who are at risk for displacement is important<sup>1, 5, 6)</sup>. In 1980, Reimers developed a measurement to document the extent of hip subluxation lateral to the acetabulum called the migration percentage (MP), which is still used as the key tool to help prevent hip dislocation, monitor its effects, make decisions regarding the most appropriate type of interventions (e.g., a selective dorsal rhizotomy, hip abduction braces, or surgery), and determine the progression of subluxation<sup>1, 3, 7)</sup>. An MP of  $\geq 33\%$  is considered a reaction threshold, and intensified observation is recommended. In children with an MP of  $\geq 40\%$ , the lateral displacement of the hip increases over time, indicating the need for surgical intervention. For children with an MP between 33% and 40%, it is recommended that treatment be based on other clinical signs as well as the progression of the MP over time as evaluated through repeat examinations performed by the same examiner<sup>5)</sup>. The current study aimed to compare the differences in the MP calculated by two physiatrists with different levels of experience in order to determine if experience plays a role in the accuracy of the results.

## SUBJECTS AND METHODS

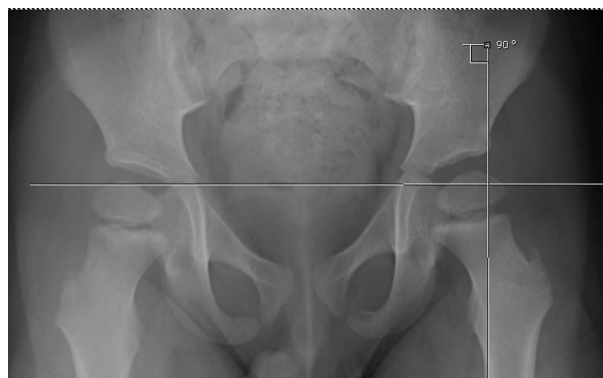The study protocol conforms to the ethical guidelines of the 1975 Declaration of Helsinki and was approved by

\*Corresponding author. Pınar Doruk Analan (E-mail: pdoruk@baskent-adn.edu.tr; doruk.pinar@gmail.com)

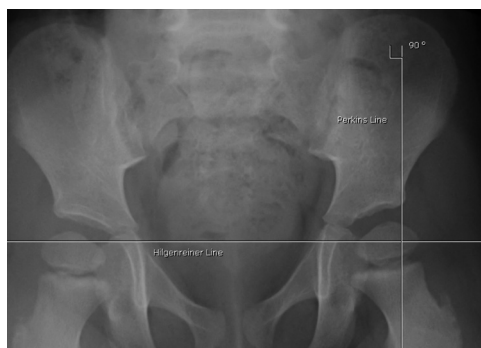©2015 The Society of Physical Therapy Science. Published by IPEC Inc. This is an open-access article distributed under the terms of the Creative Commons Attribution Non-Commercial No Derivatives (by-nc-nd) License <<http://creativecommons.org/licenses/by-nc-nd/3.0/>>.



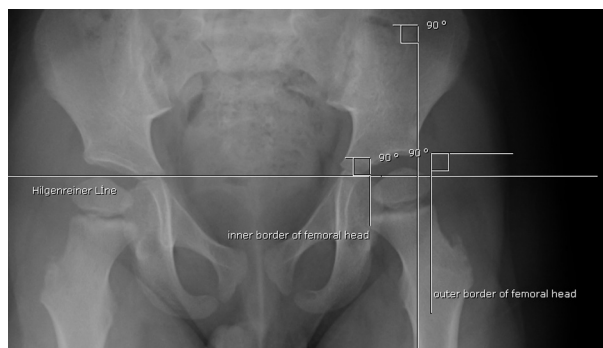**Fig. 1a.** Hilgenreiner line (H) is a line between the Y-cartilages of both sides



**Fig. 1b.** The Perkins' line is perpendicular to Hilgenreiner's line at the lateral margin of the acetabulum



**Fig. 1c.** The Perkins' line is perpendicular to Hilgenreiner's line at the lateral margin of the acetabulum



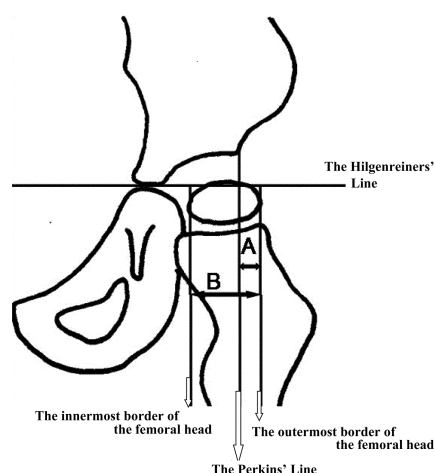
**Fig. 1d.** The innermost and the outermost border of femoral head's lines of perpendicular to Hilgenreiner's line

the local Ethics Committee. Written informed consent was obtained from all participants. This retrospective study included 62 anteroposterior pelvic radiographs of 31 children (20 boys and 11 girls; mean age 4.2; range 1–14) with spastic CP followed up at our clinic between 2011 and 2013. Patients with CP who had been followed up in our clinic and had radiographs taken were identified using a data search, and those with pelvic radiographs in the hospital's electronic medical records were included in our study. Radiographs were taken with the patient in the supine position, the pelvis symmetric with respect to rotation, and the femurs in the neutral abduction/adduction position relative to the pelvis.

Radiographs were examined by an independent physiatrist. Radiographs classified as GMFCS level I–II and those taken after previous reconstructive and salvage surgeries of the hip or pelvis were excluded from the study. MPs were then measured by two raters, a physiatrist with five years of experience and a second-year psychiatry resident, blinded to each other. All measurements were recorded by the independent physiatrist. Measurements were repeated six weeks later by the same raters and recorded by the same independent physiatrist. Any MP results recorded previously in the patient's history by their follow-up physician were not included in our study. Only images stored in the computer system were used for the MP measurements. All radiographs were recorded electronically. Measurements were calculated

using the images on the computer screen and were then recorded confidentially in a location known only to the independent physiatrist.

The hospital's computer software for storing patient radiographic records was used to measure and calculate different angles and distances to minimize measurement errors. To evaluate the MP, the Hilgenreiner line (H) was determined by drawing a line between the Y-cartilages of both sides using the software's angle measurement option, which allows for precise on-screen measurement of the angle under consideration (Fig. 1a). A second line, known as the Perkins' line (P), perpendicular to the first one, was drawn through the upper outer side of the acetabulum (Fig. 1b and 1c). Next, the innermost and outermost borders of the femoral head were defined, and two lines were drawn from those inner and outer lines intercepting at an angle of 90° to the H line (Fig. 1d). Finally, using the length measurement option in the software, the length of the acetabular part of the femoral head remaining outside the lines and the total diameter of the femoral head were measured in millimeters. The ratio of these two measurements was then calculated as the ratio of the outer acetabular part of the femoral head to the total diameter of the femoral head. The ratio was then multiplied by 100 to calculate the MP (Fig. 2). Each rater's own calculations were compared first with each other and then with those of the other rater. The MP results were clas-



**Fig. 2.** Reimers' migration percentage values (MP)

The Hilgenreiner's line is the horizontal line between the triradiate cartilage of both hips. The Perkins' line is perpendicular to Hilgenreiner's line at the lateral margin of the acetabulum. A line is without the acetabulum part of the femoral head. B line is the total diameter of the femoral head.

$$MP = A/B \times 100\%$$

sified into three stages:  $\leq 33\%$ , between 33% and 40%, and  $\geq 40\%$ <sup>5)</sup>. Correlations and intra- and inter-rater differences in the reliability of the recorded MPs were also evaluated according to dislocation severity.

The SPSS Statistics version 17.0 for Windows software package (SPSS Inc., Chicago, IL, USA) was used to perform all statistical analyses in this study. Categorical measurements were given as numbers and percentages and continuous measurements as averages and standard deviations, along with the mean and range when needed. The compatibility between raters was tested using a reliability analysis and evaluated using Cronbach's alpha value. The reliability of the inter-rater concordance correlation was evaluated using the kappa coefficient, and MP values were classified as  $\leq 33\%$ , between 33% and 40%, and  $\geq 40\%$ <sup>5)</sup>. The kappa coefficient strength of agreement was determined as follows:  $\geq 0.91$  very good; 0.90 to 0.71 good; 0.70 to 0.51 moderate; 0.50 and 0.31 fair; and  $\leq 0.30$  poor. Distributions were controlled for continuous measurements. As parameters were not normally distributed, the Wilcoxon test was used to compare the measurements, and the inter-rater correlation method was used to compare the two raters' results. Differences between measurements were evaluated using McNemar's test. For all tests, a p-value of  $< 0.05$  was considered statistically significant.

## RESULTS

There were no statistically significant intra- or inter-rater differences for either of the two measurement points ( $p > 0.05$ ). Inter-rater correlations were 0.94 for each session. In addition, there were no significant intra- or inter-rater differences in the reliability of the MP for different dislocation severity levels. The results are shown in Table 1.

In the reliability analysis test, Cronbach's alpha correlation coefficient values of 0.966 and 0.971 were obtained in

**Table 1.** Reimers' hip migration percentage values

MP Values	Rater 1	Rater 2	r
	Median (range)	Median (range)	
1st evaluation (week 0)	21.2 (0–100)	19.4 (0–100)	0.94 *
2nd evaluation (week 6)	19.3 (0–100)	17.3 (0–100)	0.94 *

MP: Migration percentage

\*  $p > 0.05$

**Table 2.** Correlation between MP measurements

Values	Kappa coefficient	
Intra-rater (Rater 1)	0.69	*
Intra-rater (Rater 2)	0.66	*
Inter-rater 1st evaluation (week 0)	0.51	*
Inter-rater 2nd evaluation (week 6)	0.58	*

\*  $p > 0.05$  with McNemar's test

the first and second evaluations, respectively. In the kappa coefficient evaluation, all agreements were classified as moderate. There were no statistically significant differences between the measurements ( $p > 0.05$ ) (Table 2). Similar reliability results were found when evaluating the different dislocation severity groups.

## DISCUSSION

Hip displacement has a reported prevalence rate of up to 35% and is the second most common deformity in patients with spastic CP<sup>1)</sup>. Increased femoral anteversion and neck-shaft angle along with the presence of powerful spastic hip adductors and flexors accentuate forces that displace the femoral heads in CP patients<sup>1, 7–10)</sup>. This condition may also result in secondary acetabular dysplasia and degenerative joint disease, femoral head or windswept hip deformities, scoliosis, severe contractures, pressure ulcers, pain, or a decrease in quality of life as well as difficult nursing and perineal care, problems with positioning while sitting and standing, and ambulation<sup>1, 4–11)</sup>. Early identification and intervention of hip displacement has been shown to improve treatment outcomes, reduce the number of required reconstructive surgeries, and avoid the need for salvage surgery<sup>1)</sup>.

For children with CP, MP is the most commonly used measurement of lateral displacement due to its predictability and reproducibility. Moreover, it has been accepted as the most valid and reliable technique<sup>1, 4–6, 9, 12, 13)</sup>. However, mismeasurement can occur as the result of poor patient positioning, a lack of attention to detail when taking the pelvic radiographs, or limited physician experience. In addition, defining the placement of the landmarks may be difficult, particularly when significant acetabular dysplasia is present. Furthermore, a temporary lapse in concentration can lead to an isolated incorrect measurement or the incorrect recording of an accurate measurement, and a busy clinical setting may cause distractions and stress<sup>3, 6, 7, 11)</sup>.

Reimers reported a standard error of  $\pm 10\%$  for the MP based on an estimate of the errors involved in the measure-

ment of the line to the nearest millimeter<sup>3</sup>), while Parrot et al. reported a lower margin of error<sup>11</sup>). The errors of measurement calculated in our study seem to be acceptable based on Reimers' estimates.

In a study by Faraj et al.<sup>3</sup>), two raters with six months of pediatric orthopedic experience measured the MP at six-week intervals using the same radiographs. They determined that the upper 95% confidence interval for the intra-rater measurements was 13% and for the inter-rater values was 22%. This rather large difference can be interpreted as either a significant improvement or a deterioration, depending on whether the 95th percentile is accepted as the indicator of change<sup>3</sup>). A subsequent study by Cliffe et al.<sup>7</sup>) questioned the reliability of the hip radiographs used in the Faraj et al. study because they believed that the orthopedic trainees did not have sufficient experience and that the results may have been different if other specialists had performed the measurements. Cliffe et al.<sup>7</sup>) studied 40 hip radiographs taken in the standard position and read by a trained pediatric radiographer; they reported excellent intra- and inter-rater reliabilities. In the current study, 62 hips were evaluated on standardized pelvic radiographs, and the intra- and inter-rater reliabilities were also determined to be excellent and the measurements to have acceptable margins of error. In addition, all MP measurements in the current study were consistent with each other and yielded no statistically significant differences. However, due to the retrospective nature of the current study, technical problems affecting the MP measurements may possibly have occurred when the radiographs were taken (i.e., an increased incline of the pelvis), particularly when they were not clear.

Parrot et al.<sup>11</sup>) suggested that in the measurement of changes in the MP over time, the expected number of errors increases when raters with varied levels of experience are used instead of the same rater. For this reason, inter- and intra-rater reliability must be taken into account. Furthermore, other studies have determined that the MP measurements should be performed and compared by the same experienced examiner<sup>3, 11, 14</sup>). However, our results did not lead to the same conclusion. Although our raters had different levels of experience in performing MP evaluations, this did not appear to have any bearing on either the intra- and inter-rater reliability or the variations in the measurements.

While Faraj et al.<sup>3</sup>) suggested that averaging repeated MP measurements could theoretically reduce the margin of error, our results did not show that repeated measurements were necessary for the routine evaluation of hip displacement. When radiographs are performed under the recommended conditions, the margin of error of a single MP measurement is approximately 10%, and clear decisions can be made when this rate is kept in mind<sup>7</sup>).

Kim et al.<sup>15</sup>) analyzed the reliability of different methods of measuring MP in children with CP via both the classic method (with or without acetabular hip dysplasia), which utilizes the lateral margin of the acetabular roof as the land-

mark for the evaluation of P, and the modified method, in which the lateral margin of the acetabular sourcil is used as the landmark. They found that both methods showed excellent intra-rater reliability, but the inter-rater reliability was higher with the classic method. Because the classic method was used for evaluating the MP in our study and as the presence of acetabular hip dysplasia was not taken into account, our intra- and inter-rater reliabilities may have been higher.

In conclusion, our results indicated that the use of physiatrists with varied experience levels does not affect MP results and that inter-rater variations in the measurements do not cause problems related to patient follow-up. For this reason, repeated pelvic radiographs are not necessary for evaluating the MP in children with CP, particularly when there is no indication that the radiographs were improperly performed.

## REFERENCES

- 1) Shore B, Spence D, Graham H: The role for hip surveillance in children with cerebral palsy. *Curr Rev Musculoskelet Med*, 2012, 5: 126–134. [[Medline](#)] [[CrossRef](#)]
- 2) Lee CW, Kim SG, Na SS: The effects of hippotherapy and a horse riding simulator on the balance of children with cerebral palsy. *J Phys Ther Sci*, 2014, 26: 423–425. [[Medline](#)] [[CrossRef](#)]
- 3) Faraj S, Atherton WG, Stott NS: Inter- and intra-measurer error in the measurement of Reimers' hip migration percentage. *J Bone Joint Surg Br*, 2004, 86: 434–437. [[Medline](#)] [[CrossRef](#)]
- 4) Hägglund G, Lauge-Pedersen H, Wagner P: Characteristics of children with hip displacement in cerebral palsy. *BMC Musculoskelet Disord*, 2007, 8: 101. [[Medline](#)] [[CrossRef](#)]
- 5) Hägglund G, Lauge-Pedersen H, Persson M: Radiographic threshold values for hip screening in cerebral palsy. *J Child Orthop*, 2007, 1: 43–47. [[Medline](#)] [[CrossRef](#)]
- 6) Dobson F, Boyd RN, Parrott J, et al.: Hip surveillance in children with cerebral palsy. Impact on the surgical management of spastic hip disease. *J Bone Joint Surg Br*, 2002, 84: 720–726. [[Medline](#)] [[CrossRef](#)]
- 7) Cliffe L, Sharkey D, Charlesworth G, et al.: Correct positioning for hip radiographs allows reliable measurement of hip displacement in cerebral palsy. *Dev Med Child Neurol*, 2011, 53: 549–552. [[Medline](#)] [[CrossRef](#)]
- 8) Morrell DS, Pearson JM, Sauser DD: Progressive bone and joint abnormalities of the spine and lower extremities in cerebral palsy. *Radiographics*, 2002, 22: 257–268. [[Medline](#)] [[CrossRef](#)]
- 9) Divecha A, Bhaskar A: Utility of combined hip abduction angle for hip surveillance in children with cerebral palsy. *Indian J Orthop*, 2011, 45: 548–552. [[Medline](#)] [[CrossRef](#)]
- 10) Morton RE, Scott B, McClelland V, et al.: Dislocation of the hips in children with bilateral spastic cerebral palsy, 1985–2000. *Dev Med Child Neurol*, 2006, 48: 555–558. [[Medline](#)] [[CrossRef](#)]
- 11) Parrott J, Boyd RN, Dobson F, et al.: Hip displacement in spastic cerebral palsy: repeatability of radiologic measurement. *J Pediatr Orthop*, 2002, 22: 660–667. [[Medline](#)] [[CrossRef](#)]
- 12) Scrutton D, Baird G: Surveillance measures of the hips of children with bilateral cerebral palsy. *Arch Dis Child*, 1997, 76: 381–384. [[Medline](#)] [[CrossRef](#)]
- 13) Pons C, Rémy-Néris O, Médée B, et al.: Validity and reliability of radiological methods to assess proximal hip geometry in children with cerebral palsy: a systematic review. *Dev Med Child Neurol*, 2013, 55: 1089–1102. [[Medline](#)] [[CrossRef](#)]
- 14) Hägglund G, Andersson S, Döppe H, et al.: Prevention of dislocation of the hip in children with cerebral palsy. The first ten years of a population-based prevention programme. *J Bone Joint Surg Br*, 2005, 87: 95–101. [[Medline](#)]
- 15) Kim SM, Sim EG, Lim SG, et al.: Reliability of hip migration index in children with cerebral palsy: the classic and modified methods. *Ann Rehabil Med*, 2012, 36: 33–38. [[Medline](#)] [[CrossRef](#)]