



## Epilepsy and the gut: Perpetrator or victim?

Mohammed Al-Beltagi, Nermin Kamal Saeed

**Specialty type:** Gastroenterology and hepatology

**Provenance and peer review:** Invited article; Externally peer reviewed.

**Peer-review model:** Single blind

**Peer-review report's scientific quality classification**

Grade A (Excellent): A  
Grade B (Very good): B  
Grade C (Good): 0  
Grade D (Fair): D  
Grade E (Poor): 0

**P-Reviewer:** Liao JX, China;  
Shiraishi W, Japan; Wen XL, China

**Received:** May 16, 2022

**Peer-review started:** May 16, 2022

**First decision:** June 8, 2022

**Revised:** June 8, 2022

**Accepted:** August 25, 2022

**Article in press:** August 25, 2022

**Published online:** September 22, 2022



**Mohammed Al-Beltagi**, Department of Pediatrics, Faculty of Medicine, Tanta University, Tanta 31527, Algharbia, Egypt

**Mohammed Al-Beltagi**, Department of Pediatrics, University Medical Center, King Abdulla Medica City, Arabian Gulf University, Manama 26671, Bahrain

**Mohammed Al-Beltagi**, Department of Pediatrics, University Medical Center, King Abdulla Medical City, Dr. Sulaiman Al Habib Medical Group, Manama 26671, Bahrain

**Nermin Kamal Saeed**, Medical Microbiology Section, Department of Pathology, Salmaniya Medical Complex, Ministry of Health, Kingdom of Bahrain, Manama 26612, Bahrain

**Nermin Kamal Saeed**, Department of Microbiology, Irish Royal College of Surgeon, Busaiteen 15503, Muharraq, Bahrain

**Corresponding author:** Mohammed Al-Beltagi, MBChB, MD, MSc, PhD, Chairman, Professor, Department of Pediatrics, Faculty of Medicine, Tanta University, Al Bahr Street, Tanta 31527, Algharbia, Egypt. [mbelrem@hotmail.com](mailto:mbelrem@hotmail.com)

### Abstract

The brain and the gut are linked together with a complex, bi-path link known as the gut-brain axis through the central and enteric nervous systems. So, the brain directly affects and controls the gut through various neurocrine and endocrine processes, and the gut impacts the brain *via* different mechanisms. Epilepsy is a central nervous system (CNS) disorder with abnormal brain activity, causing repeated seizures due to a transient excessive or synchronous alteration in the brain's electrical activity. Due to the strong relationship between the enteric and the CNS, gastrointestinal dysfunction may increase the risk of epilepsy. Meanwhile, about 2.5% of patients with epilepsy were misdiagnosed as having gastrointestinal disorders, especially in children below the age of one year. Gut dysbiosis also has a significant role in epileptogenesis. Epilepsy, in turn, affects the gastrointestinal tract in different forms, such as abdominal aura, epilepsy with abdominal pain, and the adverse effects of medications on the gut and the gut microbiota. Epilepsy with abdominal pain, a type of temporal lobe epilepsy, is an uncommon cause of abdominal pain. Epilepsy also can present with postictal states with gastrointestinal manifestations such as postictal hypersalivation, hyperphagia, or compulsive water drinking. At the same time, antiseizure medications have many gastrointestinal side effects. On the other hand, some antiseizure medications may improve some gastrointestinal diseases. Many gut manipulations were used successfully to manage epilepsy. Prebiotics, probiotics, synbiotics, postbiotics, a ketogenic diet, fecal microbiota transplantation, and

vagus nerve stimulation were used successfully to treat some patients with epilepsy. Other manipulations, such as omental transposition, still need more studies. This narrative review will discuss the different ways the gut and epilepsy affect each other.

**Key Words:** Epilepsy; Epilepsy with abdominal pain; Gut; Gastrointestinal diseases; Gut-brain-microbiota axis; Abdominal aura; Ketogenic diet; Abdominal migraine

©The Author(s) 2022. Published by Baishideng Publishing Group Inc. All rights reserved.

**Core Tip:** The brain and the gut have an intense but complex interaction through a strong relationship between the enteric and the central nervous systems. Epilepsy and the gut may affect each other in diverse ways. About 2.5% of patients with epilepsy are misdiagnosed as gastrointestinal disorders, especially at an early age. Gut dysbiosis also has a significant role in epileptogenesis. Epilepsy affects the gastrointestinal tract in different forms, such as abdominal aura, epilepsy with abdominal pain, and the adverse effects of antiseizure medications on the gut and the gut microbiota. Simultaneously, many gut manipulations successfully managed some cases of epilepsy.

**Citation:** Al-Beltagi M, Saeed NK. Epilepsy and the gut: Perpetrator or victim? *World J Gastrointest Pathophysiol* 2022; 13(5): 143-156

**URL:** <https://www.wjgnet.com/2150-5330/full/v13/i5/143.htm>

**DOI:** <https://dx.doi.org/10.4291/wjgp.v13.i5.143>

## INTRODUCTION

The human body organs and systems interact with each other in harmony. However, the interaction between the brain and the gut is overly complex, forming a two-way link known as the gut-brain axis through the central and the enteric nervous system. The enteric nervous system is the most crucial autonomic nervous system component. It has common structural and functional similarities with the brain, consequently named the second brain, forming 90%-95% of total body serotonin[1]. It is uniquely prepared with intrinsic microcircuits to orchestrate the gastrointestinal functions independent of the central nervous system (CNS) control[2]. The brain directly affects the stomach and intestines and controls the gut through various neurocrine and endocrine processes[3].

On the other hand, the gut impacts the brain *via* different mechanisms, including neuropeptide and neurotransmitter release such as leptin and serotonin, vagus nerve activation, immune signaling through controlling the release of secretory IgA, affecting the integrity of mucous membrane barrier through Zonulin protein, and local production of short-chain fatty acids such as butyrate by gut microbiota[4]. The gut-brain axis explains the effects of the emotional and cognitive centers of the brain and its control over peripheral intestinal functions. It also describes how a chronic painful abdominal condition such as irritable bowel syndrome (IBS) can affect the cognitive and psychological function of the body[5]. Many neurological disorders, including hereditary, metabolic, infectious, vascular, inflammatory, and metabolic diseases, may affect the brain and gastrointestinal tract. Consequently, the clinical neurological or gastrointestinal findings may assist in confirming the diagnosis or reducing the differential diagnosis[6]. This review sheds some light on the relationship between epilepsy, a common neurological disorder, and its effects on the abdomen and vice versa.

## EPILEPSY AND SEIZURE DISORDERS IN GASTROINTESTINAL DISORDERS

Epilepsy is a CNS disorder with abnormal brain epileptic activity, causing repeated seizures or periods of sudden abnormal motor or sensory behavior and sometimes impaired or even loss of consciousness due to a transient excessive or synchronous alteration in the brain's electrical activity. Any part of the brain can be affected by epileptic activity, especially the mesial part of the temporal lobes[7]. Epilepsy is a common neurological condition, affecting about 5%-10% of the population at a particular time of their life and about 0.5%-1.0% of children. It can affect any age or sex and all races[8].

According to the etiology, there are four main types of epilepsy, idiopathic, symptomatic, provoked, and cryptogenic, resulting from genetic, structural/metabolic, immunological, infectious, or unknown causes. Idiopathic epilepsy is pure epilepsy resulting from a single gene disorder or complex inheritance. Symptomatic epilepsy has predominately genetic or developmental causation such as childhood epilepsy syndromes, progressive myoclonic epilepsies, neurocutaneous syndromes, other single-gene

neurologic disorders, chromosomal disorders, developmental cerebral structure anomalies, perinatal and infantile causes, cerebral trauma, tumor, or infection, cerebrovascular disorders, cerebral immunologic disorders, or degenerative brain diseases. Provoked epilepsy could arise from provocation factors like fever or menses or reflex epilepsy such as photosensitive or reading epilepsies. Cryptogenic epilepsies are “unknown” and more common in adults than in the pediatric age[9,10]. Due to the strong relationship between the enteric nervous system and the CNS is always single and never be multiple, gastrointestinal dysfunction can be seen in neurological disorders, and neurological dysfunction can be seen in gastrointestinal disorders[11]. About 2.5% of patients with epilepsy were misdiagnosed with gastrointestinal disorders, especially in children below the age of one year[12].

### **Gastroesophageal reflux and gastroesophageal reflux disease**

Gastroesophageal reflux disease (GERD) is a common childhood disorder. It can simulate epileptic seizures and may be misdiagnosed as epilepsy. Sandifer Syndrome is a distinct clinical entity presented with GER, irritability, and abnormal head and body movements with spasmodic contractions of the neck. It may appear as paroxysms with abnormal neurobehavior like crying, irritability, torticollis, head/eye version, and extensor spasm of the neck with dystonic posturing. These paroxysms may simulate epilepsy and can be misdiagnosed with specific types of epilepsy, particularly infantile spasms [13].

On the other hand, epilepsy can be missed as GERD. Sweetman *et al*[14] reported a gelastic seizure due to hypothalamic hamartomas misdiagnosed as GERD[14]. Eating epilepsy is a type of feeding-related reflex focal epilepsy. It may be misdiagnosed as GERD, especially in very young infants[15]. Eating epilepsy should be considered if the history, clinical examination, and investigations for GER and apparent life-threatening events are absent[16].

Meanwhile, GERD is a common comorbidity in children with neurological problems such as cerebral palsy, frequently complicated with epilepsy. Early-onset neurological disease, abnormal electroencephalogram (EEG), and the presence of mitochondrial disorder are significant risk factors for severe GERD [17]. The presence of GERD in such patients may jeopardize their management and mimic refractory seizures[18]. Asymptomatic gastroesophageal reflux can induce laryngospasm during sleep. This nocturnal laryngospasm causes non-rapid eye movement parasomnias, which clinically simulate sleep-related hypermotor epilepsy. Video-EEG can differentiate between the two conditions[19]. The nocturnal choking sensation is a scary condition that may complicate insular epilepsy, nocturnal laryngospasm, and gastroesophageal reflux[20]. Acid reflux can induce obstructive laryngospasm and subsequent respiratory arrest, a probable mechanism of sudden unexpected death in epileptic patients. Proper GERD management and antiseizure medication significantly improve the prognosis[21].

### **Peptic ulcer**

Peptic ulcers are up to eight times more prevalent in patients with epilepsy than in the general population[22]. At the same time, epilepsy can be misdiagnosed as a peptic ulcer, as reported by Magon [23]. At the same time, a perforated peptic ulcer may provoke or complicate a generalized tonic-clonic seizure. Consequently, we should carefully consider the vital signs during seizure episodes. Omeprazole is a proton pump inhibitor effectively used to treat peptic ulcers. It has effective anticonvulsant activity through carbonic anhydrase inhibition but with rapid tolerance[24].

### **Celiac disease**

Celiac disease is a well-known systemic autoimmune disease characterized by gluten-induced autoimmune intestinal villous atrophy, malabsorption, and various systemic and gastrointestinal symptoms. The older the patient with celiac disease is, the more the prevalence of systemic symptoms not related to the gastrointestinal tract, including neurological symptoms[25]. About 10% of patients with celiac disease develop neurological complications, including seizures. At the same time, about 0.78% to 9.10% of patients with epilepsy develop celiac disease[26,27]. The exact mechanism of neurological manifestations is poorly understood, probably related to immune mechanisms. This hypothesis is advocated by the presence of anti-Purkinje cells and anti-ganglioside antibodies in patients with celiac disease who developed neurological manifestations[28]. Another possible hypothesis is neurological damage due to deficiencies of the neurotrophic and neuroprotective vitamins (*e.g.*, vitamin D, vitamin E, thiamine, and vitamin B12) resulting from the malabsorption associated with celiac disease[29]. The prevalence of drug-resistant epilepsy is more common in children who have celiac disease as a comorbidity. Most patients with celiac disease and epilepsy have been cured with adherence to a gluten-free diet. Adherence to a gluten-free diet and adequate antiseizure medications can also reduce the seizure frequency and severity in patients with celiac disease and drug-resistant epilepsy[30].

### **Gut dysbiosis**

Gut dysbiosis strongly relates to autoimmune diseases, which are closely linked with epilepsy, suggesting an association between epilepsy and gut dysbiosis[3]. Huang *et al*[31] showed that mild gastroenteritis precedes the development of benign infantile convulsions. This temporal relation links

the infection-induced gut dysbiosis with epileptogenesis[31]. Şafak *et al*[32] found a significant increase in *Fusobacteria* prevalence in patients with epilepsy (10.6%) but not in the healthy control. This considerable shift and drift in the intestinal microbiota and the subsequent gut dysbiosis may be present in certain epilepsy types[32]. Meanwhile, the gut microbiome differs in patients with drug-resistant epilepsy (e.g., *Cronobacter*, *Bacteroides*, *Bifidobacterium*, and *Erysipelatoclostridium*) from patients with drug-sensitive epilepsy with an abnormally increased richness of rare flora. On the other hand, patients with drug-sensitive epilepsy have a gut microbiome composition like the healthy controls, enforcing the evidence of the effects of gut dysbiosis in the development of epilepsy and drug-resistant epilepsy[33, 34].

## IBS

IBS is a constellation of symptoms occurring together, such as repeated abdominal pain and changes in bowel habits, such as diarrhea, constipation, or both. It affects about 7%-21% of the population[35]. IBS is associated with increasing the incidence of epilepsy, particularly temporal lobe epilepsy. A large population-based cohort study by Chen *et al*[36] showed that IBS increased the epilepsy risk with a cumulative incidence of epilepsy of 2.54/1000 person-years *vs* 1.86/1000 person-years in the cohort without IBS with an adjusted hazard ratio of 1.30[36]. Studies also showed that the incidence of IBS increases five times in patients with epilepsy than in controls[37]. There is also an increased incidence of functional gastrointestinal disorders, including IBS, in children with epilepsy than in matching controls[38]. Epilepsy with abdominal pain could also be misdiagnosed as IBS[39]. The cumulative data from these studies showed the bidirectional link between IBS and epilepsy. The exact cause of this increase in epilepsy risk is not known. It is probably related to the shared pathophysiological mechanisms and risk factors such as disturbed brain-gut axis, microbiota imbalance of the gastrointestinal tract, increased incidence of dietary allergies, neuroimmune interactions, and mucosal inflammatory mediator deregulation in the gastrointestinal tract[40-42]. Patients with epilepsy with IBS as a comorbidity have an increased rate of depressive and anxiety disorders[43]. If IBS is present in patients with drug-resistant epilepsy, most of the seizures occur during the period of altered bowel movements[44].

## Inflammatory bowel diseases

Inflammatory bowel diseases (IBD) are chronic autoimmune and immune-mediated inflammatory disorders affecting the digestive system with gastrointestinal and systemic manifestations, including the central and peripheral nervous systems. IBDs include ulcerative colitis, Crohn's disease, and unclassified IBD[45]. Neurological complications occur in 0.25% to 47.50% of patients with IBDs. Seizures of all types, including status epilepticus, can be observed during the clinical course of IBDs, especially in severe cases[46]. Many underlying mechanisms explain the occurrence of seizures in IBDs. These mechanisms include autoimmune-mediated neuroinflammation, gut dysbiosis with brain-gut-microbiota axis dysfunction, the associated nutritional deficiencies, especially thiamine and vitamin B12, increased incidence of infections, arterial and venous thromboembolism, and possible side effects of medications especially sulfasalazine, metronidazole, steroids, tumor necrosis factor- $\alpha$  inhibitors, and anti-integrin antibodies[47]. Seizures in patients with IBDs indicate the need to rule out a cranial thromboembolic event[48].

## Gastrointestinal disorders in children with autism

Gastrointestinal disorders occur in 46%-84% of children with autism. The most common gastrointestinal problems observed in children with autism are motility disorders such as chronic constipation or diarrhea, nausea, vomiting, gastroesophageal reflux or disease, chronic flatulence, abdominal discomfort, ulcers, inflammatory bowel disease, colitis, food allergies or intolerance, and failure to thrive. The severity of autism strongly correlates positively with gastrointestinal symptoms[49]. Meanwhile, abnormal EEG is present in 60% of children with autism (compared to 6%-7% of typically developed children), while epilepsy is present in 10% to 30% of children with autism. Children with autism have a high rate of celiac disease and gut dysbiosis, which increases the incidence of epilepsy[50].

## Situation-related seizures (Convulsions associated with gastrointestinal infections CwG)

Gastrointestinal infections were first reported to cause epileptiform activity development by Japanese researcher Morooka in 1982 and were called "situation-related seizures"[51]. It occurred in a previously healthy child who developed nonfebrile convulsions following mild gastroenteritis and mild dehydration for 1-5 d without apparent acid intoxication or electrolyte imbalance. It usually occurs during the winter, mainly by the rotavirus, which can reach the brain and cause encephalitis, cerebropathy, or convulsions[52]. The convulsions may present as single or multiple attacks of generalized tonic-clonic or focal seizure with characteristic normal interictal EEG, normal electrolytes, serum glucose, and cerebrospinal fluid. Stool analysis may test positive for rotavirus, norovirus, adenovirus, sapovirus, and coxsackievirus. It occurs in young children with an immature nervous system, like febrile convulsions[53]. Unfortunately, the prevalence of this type of convulsion is on the rise and has not been affected by the introduction of the rotavirus vaccination[54]. The etiology and pathophysiology are not yet thoroughly explained. However, it could be related to direct microbial invasion of the CNS



due to the indirect effects of specific mediators triggered by gastrointestinal infections[55]. This type of seizure has a favorable prognosis with infrequent relapse and typically normal development without the need for long-term antiseizure therapy[56].

## EFFECTS OF EPILEPSY ON THE GUT

As the brain has a bidirectional relationship with the gut, neurological disorders may impact the gastrointestinal tract. Examples of this impact include the occurrence of sialorrhea, anorexia, dysphagia, gastroparesis, and motility disorders such as diarrhea, intestinal pseudo-obstruction, constipation, and fecal incontinence[57]. Hence, epilepsy, in turn, affects the gastrointestinal tract in different forms, such as abdominal aura, epilepsy with abdominal pain, and the adverse effects of medications on the gut and the gut microbiota.

### **Abdominal aura**

An 'aura' is subjective warning feelings, experiences, movements, or events (*e.g.*, specific memory, music, song, or swirling colors) some people with epilepsy may experience, usually before or at the onset of a tonic-clonic seizure. Auras occur in about 70% of patients with generalized epilepsy[58]. Auras arise due to the activation of a functional cortex by aberrant, unilateral, focal, and short neuronal discharge[59]. It is a form of an aware focal seizure that develops into another type of seizure. It usually occurs at the seizure onset before impairment or loss of consciousness and is usually memorized afterward. We should differentiate auras from the premonitory or prodromal sensations, which occur at least 30 min before the seizures[60]. There are different forms of auras depending on the epileptogenic zone. Auras could be visual, auditory, olfactory, gustatory, somatosensory, psychic, autonomic, or even sexual. Hence, auras are accurate anatomical markers of the epileptogenic zone[61]. However, auras could be multiple, as reported in 6% of patients with epilepsy. Multiple auras are associated with multifocal epilepsy or activation of a neural network that involves more than one functional region. The presence of aura has an essential role in diagnosing, localization, and classification of epilepsy. Epileptic aura could assist in differentiating partial from generalized seizures[62].

Gustatory aura or gustatory hallucination epilepsy are a type of simple partial seizures. They are characterized by taste sensations, including sweet, bitter, acidic, salty, or metallic tastes, as the first clinical manifestation of the seizure. It is one of the parietal, temporal, or temporoparietal seizure manifestations and often evolves into complex partial seizures[59]. It occurs in the form of a sudden taste sensation of short duration, primarily seconds, that usually follow or is accompanied by the olfactory hallucination that resembles the perceived taste in the absence of an actual stimulus of the sensation. Both gustatory and olfactory auras are often linked together and are difficult to differentiate [63]. Gustatory auras arise from the mesial temporal region, particularly the left side, and are a manifestation of mesial temporal sclerosis or tumors[64].

An epigastric aura (visceral aura) is a somatosensory (*e.g.*, pain) aura that typically demonstrates an increasing epigastric sensation. It may appear as visceral sensations (*e.g.*, abdominal discomfort), visceromotor symptoms (*e.g.*, vomiting, borborygmi, or tachycardia), or vegetative symptoms (*e.g.*, blushing or sweating). Epigastric aura occurs due to abnormal neuronal activation and discharges in the sensory cortex representing the abdominal viscera[65]. This type of aura is frequently seen in migraine or epilepsy. Epigastric auras are the most prevalent aura in medial temporal lobe epilepsy. It also may have an insular origin[66]. The presence, type, and severity of epigastric aura and other forms of autonomic manifestations depend on the seizure onset location and timing, propagation pathway, lateralization, and the persistence of interictal autonomic dysfunction. The presence of a severe autonomic aura can expect the occurrence of sudden death[67].

### **Abdominal skin temperature in focal epilepsy**

Thermographic studies showed that the abdominal wall has colder spots and areas in patients with focal-onset epilepsy than in controls. It could be related to the visceral-somatic and somatic-visceral neurological interactions[68]. We can use infrared thermography mapping and thermochromic/thermo-sensitive silicone to locate the irritative epileptogenic areas in patients with focal epilepsy. Their accuracy and safety are like electrocorticography. This thermographic localization of the epileptogenic activity can be used to locate the irritative zones in neurosurgery, particularly epilepsy surgery[69].

### **Epilepsy with abdominal pain (abdominal epilepsy)**

Abdominal pain is one of the most frequent complaints, especially in pediatric age. It may result from a wide range of causes, both intra- and extra-abdominal. Systemic causes of abdominal pain may include hereditary, infectious, inflammatory, metabolic diseases, and neurologic disorders[70]. Many neurologic diseases can cause abdominal pain. For example, abdominal migraine, epilepsy, peripheral neuropathy, or even cerebral tumors can present with abdominal pain[71,72]. Occasionally the cause of the abdominal pain is ill-defined, making the diagnosis of abdominal pain without evident abdominal abnormality a puzzle for most physicians.

Epilepsy with abdominal pain is an uncommon condition of abdominal pain. It is a type of temporal lobe epilepsy that usually presents with abdominal auras and is characterized by recurrent episodic paroxysms of abdominal and periumbilical pain with various abdominal symptoms (*e.g.*, nausea and vomiting) accompanied or followed by disturbed brain functions. Epilepsy with abdominal pain usually occurs in childhood, but it is also reported in adults[73]. The characteristic postictal manifestations (such as lethargy, drowsiness, headache, blindness, paraesthesia, or even convulsions) help to differentiate it from the abdominal migraine[74].

The exact mechanism of epilepsy with abdominal pain is not fully understood but could be related to abnormal neuronal activation of the temporal lobe involving the amygdala. Amygdala then serves as a signal conductor to the gut through direct projections to the dorsal motor part of the vagus nerve nucleus. The vagus nerve then transmits the electrical activity to the target organs causing different gastrointestinal symptoms, especially abdominal pain (Figure 1)[75]. It is usually idiopathic; however, it may manifest temporal lobe lesions such as prematurity, febrile seizures, neuronal migration defects, cortical malformations, arterio-venous malformations, neuroendocrine dysfunction, mesial temporal lobe sclerosis, gliotic damage resulting from encephalitis, or brain tumors such as dysembryoplastic neuroepithelial tumors, benign tumors, cerebral astrocytoma, or gliomas[76,77].

Epilepsy with abdominal pain has a characteristic tetrad[78]: (1) Paroxysmal gastrointestinal and autonomic complaints (abdominal pain, vomiting, nausea, flushing, palpitation, and stuttering) of unapparent cause; (2) CNS disturbance symptoms (*e.g.*, alteration of mental status, headache, dizziness, and convulsions); (3) Abnormal EEG findings characteristic of epileptic activity; and (4) Improvement of the symptoms with antiseizure medications.

The diagnosis of epilepsy with abdominal pain is essentially clinical. To properly diagnose epilepsy with abdominal pain, we should rule out organic causes in the gastrointestinal tract and the nervous system. Other causes of recurrent abdominal pain should also be ruled out, such as porphyria, familial Mediterranean fever, abdominal migraine, and cyclic vomiting[79]. Describing the abdominal attacks by emphasizing the presence or absence of aura and postictal events may help reach the diagnosis. Complete physical, abdominal, and neurological examinations should be performed in suspected patients. Serum prolactin could increase within 20 min of the attack in epilepsy with abdominal pain. The sample should be taken within two hours. Presumably, the prolactin release is due to the propagation of epileptic activity from the temporal lobe spreading to the hypothalamic-pituitary axis. High serum prolactin could help to differentiate epilepsy with abdominal pain from psychogenic or functional causes of abdominal pain[80]. The presence of abnormal epileptogenic activity by EEG accompanying the pain paroxysm or between the attack confirms the diagnosis. Computed tomography or magnetic resonance imaging of the brain may be needed to rule out neurologic diseases or tumors. Other laboratory tests to rule out the gastrointestinal causes of abdominal pain are tailored according to the clinical finding. Abdominal ultrasound could also help[77].

Epilepsy and migraine are frequent comorbid conditions and shared genetic susceptibility[81]. Abdominal migraine has many shared features with epilepsy with abdominal pain: Auras, abdominal pain, nausea, vomiting, and headache. So, when a patient with epilepsy with abdominal pain presents with a headache, it will be challenging to differentiate it from abdominal migraine (Table 1). The duration of the symptoms could help in diagnosis, as headache is usually prolonged in abdominal migraine rather than in abdominal epilepsy. Postictal manifestations, abnormal EEG, and high postictal serum prolactin could help confirm epilepsy with abdominal pain[79]. Treatment of epilepsy with abdominal pain with antiseizure medications is usually successful, with very few relapse rates. There are no current recommendations on the type of antiseizure medications, but many studies recommend using oxcarbazepine[82].

### **Postictal abdominal manifestations**

Postictal states are transient brain conditions following seizures (most common complex partial and tonic-clonic seizures), manifested as neurological deficits (confusion, weakness, memory impairment, and headache) with/without psychiatric manifestations of variable severity and duration, frequently associated with EEG slowing or suppression, and persist for minutes to days[83]. The duration of these symptoms usually corresponds to the intensity and duration of the ictal period. The mechanism of postictal states is related to robust cortical inhibitory mechanisms that try to inhibit and terminate the seizures, producing changes in membrane receptors and alteration of neurotransmitter release together with cerebrovascular changes, contributing to the development of these postictal events. Postictal event type depends on the type of epilepsy, the location of the epileptogenic activity, and the severity of the seizure[84,85]. Sometimes it is challenging to differentiate between ictal and postictal events, especially in nonconvulsive seizures[86]. The EEG and magnetic resonance imaging brain changes usually relate to the postictal manifestations with characteristic slowing and temporary signal increases[87].

Postictal hypersalivation is rare but occurs entirely in seizures of mesial origin in temporal lobe epilepsy, mainly from the left side[88]. Hypersalivation reflects a purposeful response to hypersecretion following regaining consciousness after a complex partial seizure. It is prevalent in patients with temporal lobe epilepsy, especially mesial temporal lobe epilepsy[89]. This postictal event is more common in females than males supporting the sex differences in epilepsy[90]. Postictal hyperphagia and compulsive water drinking were reported in a few case reports in patients with secondary epilepsy due

**Table 1 Differences between epilepsy with abdominal pain and abdominal migraine**

Parameter	Epilepsy with abdominal pain	Abdominal migraine
Age	Mainly pediatric age (4-9 yr), scarce in adults	It starts in childhood (3-10 yr with a peak at 7), though it may occur in adults
Sex	More in males during childhood, more in females in adulthood	More in females
Prevalence	Very rare	More common affect 2% to 4% of children
Etiology	Focal partial temporal lobe epilepsy due to idiopathic or secondary causes	Food allergy, Mitochondrial DNA mutation (cytopathy), Corticotropin-releasing factors abnormalities, Endogenous prostaglandin release
Family history		Strong family history of migraine
Duration of episodes	Usually 10-30 min, 4-5 times/month	Usually, more than an hour (3-4 h), at least twice/6 mo
Aura	May present	May present
Headache if present	Short duration	Long duration
Consciousness	May be altered	Not affected
Postictal tiredness or confusion	May present	absent
EEG	Abnormal epileptogenic electrical activity of focal temporal epilepsy	Usually, normal
Postictal serum Prolactin	Usually, high	Usually normal, it may be high, especially in females
Prevention	Prevention and treatment of the cause in secondary cases and sleep hygiene in idiopathic cases	Good sleep hygiene, hydration, stress reduction, and avoiding dietary triggers
Prophylaxis therapy	Antiseizure medications	Amyltryptine, propranolol, cryoheptadine, pizotifen

EEG: Electroencephalogram.

to temporal lobe lesions. It showed a dramatic response to carbamazepine[91]. It was also reported in secondary epilepsy due to frontal lobe lesions[92]. Remick *et al*[93] described three patients who experienced postictal hyperphagia[93].

### **Effects of antiseizure medications on the gastrointestinal tract**

Antiseizure medications generally have a narrow therapeutic window with many adverse effects, especially on the gastrointestinal tract. According to the reporting method, the prevalence of the antiseizure side effects ranges between 10%-90% of the patients[94]. Over the last one and half centuries, the adverse effects of antiseizure medications remain the primary cause of treatment failure. About 10%-30% of the patients with epilepsy did not tolerate these side effects and stopped the drugs, especially with polytherapy[95]. Gastrointestinal side effects were observed in many antiseizure medications. Table 2 summarizes the common gastrointestinal side effects of the commonly used antiseizure medications.

On the other side, some antiseizure medications can improve some gastrointestinal manifestations. For example, gabapentin can improve functional dyspepsia, which is resistant to other conventional therapies[96]. Gabapentin also decreases rectal mechanosensitivity and enhances rectal compliance in patients suffering from diarrhea-predominant IBS[97]. Another interesting finding by Liu *et al*[98] is the ability of valproate to prevent peritoneal adhesion following abdominal injury through chymase inhibition[98]. Valproate also decreased intestinal inflammation in inflammatory bowel disease[99].

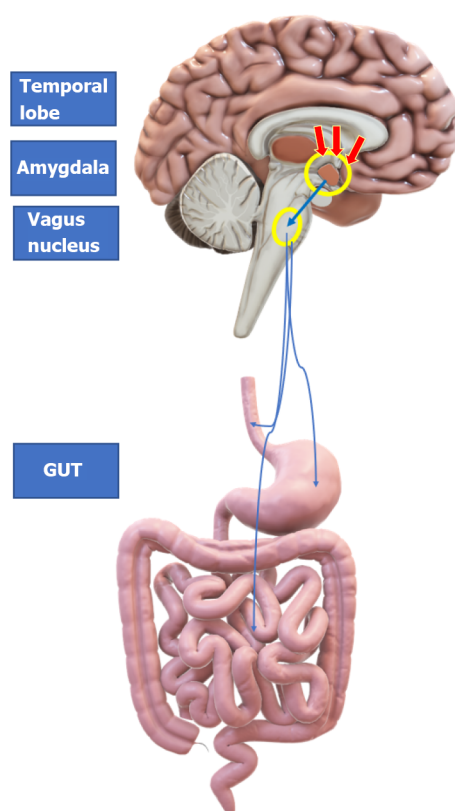
Meanwhile, Patel and Patel[100] showed that sodium valproate could experimentally inhibit the proliferation of carcinogenic cells in colon cancer associated with diabetes mellitus[100]. As valproate is a GABA agonist, it can modulate gastrointestinal motility and the anal sphincter. Valproate can normalize the activity of the human lower esophageal sphincter and reduces the number of reflux episodes in health and GERD[101]. Phenobarbital is effective and safe for preventing prenatal and treating postnatal hyperbilirubinemia through its effects on the hepatic enzymatic elimination of bilirubin[102,103].

## **ABDOMINAL MANIPULATIONS TO MANAGE EPILEPSY**

As the gut-brain axis has a bidirectional effect on both gut and brain, modulation of the gut microbiota

**Table 2 Common gastrointestinal side effects of antiseizure medications[122-129]**

Antiseizure medications	Common gastrointestinal side effects
Carbamazepine	Dry mouth, mouth sores, glossitis, loss of appetite, dysphagia, nausea, vomiting, hurt burn, gastritis, stomach/abdominal pain, constipation, diarrhea, abnormal liver functions, cholestatic and/or hepatocellular jaundice, hepatitis; hepatic failure (very rare), and pancreatitis (rare), eosinophilic colitis
Ethosuximide	Anorexia, nausea, vomiting, gastric pain, diarrhea, gastric and intestinal atony with decreased peristaltic activity
Phenobarbital	Diarrhea, sore throat, swelling of the tongue/throat, nausea, vomiting, constipation, dysphagia, and heartburn. As it is a cytochrome P450 hepatic enzyme inducer, it can cause abnormal hepatic function, hepatitis, liver damage, cholestasis, toxic hepatitis, and jaundice
Phenytoin	Changes in taste sensation, gingival overgrowth, sore throat, mouth ulcers, diarrhea, nausea, vomiting, constipation, dysphagia, heartburn, idiosyncratic hepatotoxicity (< 1% of the patients), reduced gastrointestinal absorption of calcium, reduced hepatic synthesis of 25-hydroxycholecalciferol, cause a relative vitamin K deficiency
Valproate	Diarrhea, nausea, vomiting, constipation, dysphagia, gastritis with heartburn, several distinctive forms of acute and chronic liver injury, and vitamin D deficiency
Gabapentin	Vomiting, constipation, gastritis, pancreatitis
Topiramate	Taste perversion, anorexia, nausea, abdominal pain, indigestion, diarrhea, constipation
Lamotrigine	Dry mouth, nausea, vomiting, gastritis, diarrhea, or constipation



DOI: 10.4291/wjgp.v13.i5.143 Copyright ©The Author(s) 2022.

**Figure 1 Mechanism of epilepsy with abdominal pain.**

could positively impact managing diverse types of epilepsy. The gut microbiota may influence brain functions in several ways, including the CNS, the hypothalamic-pituitary-adrenal axis, immune and inflammation modulation, and neuromodulators. Therefore, gut microbiota modulation could exert a beneficial role in epilepsy management. Prebiotics, probiotics, synbiotics, postbiotics, a ketogenic diet, and fecal microbiota transplantation are probable methods to treat epilepsy *via* modulation of the microbiota-gut-brain axis[104]. Probiotics are living organisms able to provide the host with health benefits when supplied in an appropriate dose. At the same time, prebiotics is selective nutritious substrates for specific types of host microorganisms to confer health benefits to the host. Synbiotics are a mixture of both pre- and probiotics. Postbiotics are the metabolic end products of the probiotic



organisms that can confer health benefits to the host[105].

Gómez-Eguílaz *et al*[106] found a reduction in seizure frequency by 50% in about 28.9% of patients with drug-resistant epilepsy when supplied with a probiotic mixture as adjuvant therapy for four months. This effect persisted for another 4 mo after probiotic discontinuation in 78.9% of those who showed improvement[106]. The gut microbiota can modulate brain activity by the peripheral production of GABA, metabolizing serotonin precursors, and modulating brain-derived neurotrophic factors that correlate with epilepsy severity. The bacterial production of short-chain fatty acids, which have anti-inflammatory effects, is another factor explaining the probiotic effects in treating epilepsy. Gut microbiota also modulates the endocannabinoid system with its inflammatory suppressor effects on seizure events[107]. At the same time, some gut microbiota strains can metabolize anticonvulsants affecting their antiseizure effect. For example, the gut microbiota can metabolize the antiseizure zonisamide into pharmacologically inactive 2-sulfamoyl-acetyl-phenol[108]. Fecal microbiota transplantation is a promising approach to reconstructing the gut microbiota. It is successfully used to treat various diseases, including neurological disorders. He *et al*[109] successfully treated a girl with long-term Crohn's disease and epilepsy for 17 years with fecal microbiota transplantation, which could prevent seizure relapse during 20 mo of follow-up[109]. However, we need more time to have a valuable experience with the efficacy of fecal microbiota transplantation in treating epilepsy.

The ketogenic diet is an old modality used to treat drug-resistant epilepsy and metabolic diseases since 1920. Though the precise mode of action is not well known, its activity could be related to modifying the gut microbiota composition and function. The gut microbiota modification causes alteration of beta-hydroxybutyrate levels and elevates the hippocampal GABA compared to the glutamate content[110]. In addition, the ketogenic diet modification of the gut microbiota reduces the alpha diversity and increases proposed beneficial bacteria like *Akkermansia muciniphila* and *Parabacteroides spp.* This microbiota modulation changes the colonic luminal metabolome, with a decrease in gamma-glutamyl amino acids and an increase in the brain GABA/glutamate content by reducing the blood gamma-glutamyl amino acids[111]. A ketogenic diet also alters neuronal metabolism by reducing cerebrospinal fluid glucose levels, increasing ketone bodies, and reducing cortical hyperexcitability with reduced seizure frequency[112]. Ketone bodies such as acetoacetate exerted a broad-spectrum anticonvulsant effect through modulation of neurotransmitter release and modification of ATP-sensitive potassium channels[113]. Additionally, ketone bodies have a direct inhibitory influence on the vesicular glutamate transport[114].

Vagus nerve stimulation was approved by the Food and Drug Administration in 1997 as adjuvant treatment in patients with multidrug resistant epilepsy who are not fit for epilepsy surgery. The vagus nerve is a vital brain-gut axis component and plays an essential role in inflammation modulation, intestinal homeostasis maintenance, food intake, satiety regulation, and energy homeostasis[115]. Vagus nerve stimulation leads to electrical energy discharge into a wide brain area, disturbing the unusual brain activity that produces seizures[116]. At the same time, vagal stimulation has anti-inflammatory properties affecting the gastrointestinal tract through hypothalamic-pituitary-adrenal axis activation and vasovagal reflex-induced cortisol release, which has an anti-tumor necrosis factor effect[117]. Consequently, vagus nerve stimulation can be used to treat multidrug resistant epilepsy and at the same time can treat gut inflammatory disorders such as IBD, which at the same time is a risk factor to increase the incidence of epilepsy[118].

Omentum is a large double peritoneal flat sheet of fatty tissue that hangs from the greater and the lesser gastric curvature to float on the intraperitoneal organs, including large and small intestines. It has many functions: Fat storage, immune regulation, neovascularization, tissue regeneration, and healing. Omental transposition or graft was used in various surgeries, including abdominal, cardiac, thoracic, orthopedic, plastic, vascular, urogenital, gynecological, and neurosurgeries[119]. Omental transposition on the brain surface enhances neoangiogenesis by generating plentiful new vessel connections between the omentum and the brain, which induces healing of neural injury by increasing the cerebral blood flow and the available oxygen to the neural tissues, releasing omental neurotransmitters, such as acetylcholine, dopamine, and noradrenaline. It also releases neurotrophic factors such as gangliosides and nerve growth factors that help to restore neurologic functions[120]. Rafael *et al*[121] used omental transplantation to treat two patients with uncontrolled temporal lobe epilepsy. They transplanted the omental tissues directly upon the epileptic focus on the left temporal lobe and the anterior perforated space. One patient showed complete recovery, while the other showed about 85% improvement in seizure frequency and severity[121]. However, there are few reported cases, and there is a need for long-term follow-up to have a better experience with omental transplantation to treat epilepsy.

## CONCLUSION

There is a strong interaction between the gut and the brain. This interaction forms the typical gut-brain axis. Consequently, gastrointestinal dysfunction can be seen in neurological disorders, and neurological dysfunction can be seen in gastrointestinal disorders. There is an increase in epilepsy incidence in various gastrointestinal diseases. On the other hand, epilepsy, in turn, affects the gastrointestinal tract in

different forms, such as abdominal aura, epilepsy with abdominal pain, and the adverse effects of antiseizure medications on the gut and the gut microbiota. Various gut manipulations could help manage epilepsy, such as gut microbiota modification, fecal microbiota transplantation, ketogenic diet, vagus nerve stimulation, and omentum transplant. Understanding the strong relationship between epilepsy and the gut could help alleviate epileptic and gastrointestinal disorders.

## ACKNOWLEDGEMENTS

We thank the editors and the anonymous referees for their positive, precise, and valuable suggestions.

## FOOTNOTES

**Author contributions:** Al-Beltagi M and Saeed NK collected the data and wrote and revised the manuscript.

**Conflict-of-interest statement:** All the authors report no relevant conflicts of interest for this article.

**Open-Access:** This article is an open-access article that was selected by an in-house editor and fully peer-reviewed by external reviewers. It is distributed in accordance with the Creative Commons Attribution NonCommercial (CC BY-NC 4.0) license, which permits others to distribute, remix, adapt, build upon this work non-commercially, and license their derivative works on different terms, provided the original work is properly cited and the use is non-commercial. See: <https://creativecommons.org/licenses/by-nc/4.0/>

**Country/Territory of origin:** Bahrain

**ORCID number:** Mohammed Al-Beltagi 0000-0002-7761-9536; Nermin Kamal Saeed 0000-0001-7875-8207.

**S-Editor:** Fan JR

**L-Editor:** Filipodia

**P-Editor:** Fan JR

## REFERENCES

- 1 Gershon MD. The enteric nervous system: a second brain. *Hosp Pract (1995)* 1999; **34**: 31-32, 35 [PMID: 10418549 DOI: 10.3810/hp.1999.07.153]
- 2 Rao M, Gershon MD. The bowel and beyond: the enteric nervous system in neurological disorders. *Nat Rev Gastroenterol Hepatol* 2016; **13**: 517-528 [PMID: 27435372 DOI: 10.1038/nrgastro.2016.107]
- 3 Saeed NK, Al-Beltagi M, Bediwy AS, El-Sawaf Y, Toema O. Gut microbiota in various childhood disorders: Implication and indications. *World J Gastroenterol* 2022; **28**: 1875-1901 [PMID: 35664966 DOI: 10.3748/wjg.v28.i18.1875]
- 4 Strandwitz P. Neurotransmitter modulation by the gut microbiota. *Brain Res* 2018; **1693**: 128-133 [PMID: 29903615 DOI: 10.1016/j.brainres.2018.03.015]
- 5 Osadchiy V, Martin CR, Mayer EA. The Gut-Brain Axis and the Microbiome: Mechanisms and Clinical Implications. *Clin Gastroenterol Hepatol* 2019; **17**: 322-332 [PMID: 30292888 DOI: 10.1016/j.cgh.2018.10.002]
- 6 Mayer EA, Tillisch K. The brain-gut axis in abdominal pain syndromes. *Annu Rev Med* 2011; **62**: 381-396 [PMID: 21090962 DOI: 10.1146/annurev-med-012309-103958]
- 7 Fisher RS, van Emde Boas W, Blume W, Elger C, Genton P, Lee P, Engel J Jr. Epileptic seizures and epilepsy: definitions proposed by the International League Against Epilepsy (ILAE) and the International Bureau for Epilepsy (IBE). *Epilepsia* 2005; **46**: 470-472 [PMID: 15816939 DOI: 10.1111/j.0013-9580.2005.66104.x]
- 8 Nickels KC, Grossardt BR, Wirrell EC. Epilepsy-related mortality is low in children: a 30-year population-based study in Olmsted County, MN. *Epilepsia* 2012; **53**: 2164-2171 [PMID: 22989286 DOI: 10.1111/j.1528-1167.2012.03661.x]
- 9 Shorvon SD. The etiologic classification of epilepsy. *Epilepsia* 2011; **52**: 1052-1057 [PMID: 21449936 DOI: 10.1111/j.1528-1167.2011.03041.x]
- 10 Shorvon SD, Guerrini R, Andermann D. Introduction to the concept of provoked epilepsy. In Shorvon SD, Andermann F, Guerrini R (Eds) *The Causes of Epilepsy. Common and uncommon causes in adults and children*. Cambridge University Press, Cambridge, 2011: 625-630
- 11 Pfeiffer RF. Gastroenterology and Neurology. *Continuum (Minneapolis)* 2017; **23**: 744-761 [PMID: 28570327 DOI: 10.1212/CON.0000000000000484]
- 12 Carbonari G, Tonti G, Di Pisa V, Franzoni E, Cordelli DM. Pediatric epilepsies misdiagnosed as gastrointestinal disorders. *Epilepsy Behav* 2018; **83**: 137-139 [PMID: 29705623 DOI: 10.1016/j.yebeh.2018.03.034]
- 13 Kabakus N, Kurt A. Sandifer Syndrome: a continuing problem of misdiagnosis. *Pediatr Int* 2006; **48**: 622-625 [PMID: 17168985 DOI: 10.1111/j.1442-200X.2006.02280.x]
- 14 Sweetman LL, Ng YT, Kerrigan JF. Gelastic seizures misdiagnosed as gastroesophageal reflux disease. *Clin Pediatr (Phila)* 2007; **46**: 325-328 [PMID: 17475990 DOI: 10.1177/0009922806295400]

- 15 **Domizio R**, Conte E, Puglielli C, Domizio S, Maragni S, Pollice R, Casacchia M, Sabatino G. Neonatal eating epilepsy: pathophysiological and pharmacologic aspects. *Int J Immunopathol Pharmacol* 2006; **19**: 697-702 [PMID: [17026854](#) DOI: [10.1177/039463200601900325](#)]
- 16 **Koul R**, Alshihi A, Mani R, Javad H, AlFutaisi A. Eating epilepsy or feeding epilepsy in an infant. *Eur J Paediatr Neurol* 2014; **18**: 409-412 [PMID: [24238820](#) DOI: [10.1016/j.ejpn.2013.10.004](#)]
- 17 **Kim S**, Koh H, Lee JS. Gastroesophageal Reflux in Neurologically Impaired Children: What Are the Risk Factors? *Gut Liver* 2017; **11**: 232-236 [PMID: [27840365](#) DOI: [10.5009/gnl16150](#)]
- 18 **Bayram AK**, Canpolat M, Karacabey N, Gumus H, Kumandas S, Doğanay S, Arslan D, Per H. Misdiagnosis of gastroesophageal reflux disease as epileptic seizures in children. *Brain Dev* 2016; **38**: 274-279 [PMID: [26443628](#) DOI: [10.1016/j.braindev.2015.09.009](#)]
- 19 **Pushkar T**, Attarian H, Belyakova-Bodina A, Broutian A. Gastroesophageal reflux-related Non-Rapid Eye Movement parasomnia mimicking sleep-related hypermotor epilepsy. *Sleep Med* 2021; **84**: 154-157 [PMID: [34153797](#) DOI: [10.1016/j.sleep.2021.05.035](#)]
- 20 **Busger op Vollenbroek RJ**, de Weerd AW. [Nocturnal choking sensation]. *Ned Tijdschr Geneesk* 2013; **157**: A6204 [PMID: [24020623](#)]
- 21 **Budde RB**, Arafat MA, Pederson DJ, Lovick TA, Jefferys JGR, Irazoqui PP. Acid reflux induced laryngospasm as a potential mechanism of sudden death in epilepsy. *Epilepsy Res* 2018; **148**: 23-31 [PMID: [30336367](#) DOI: [10.1016/j.eplepsyres.2018.10.003](#)]
- 22 **Keezer MR**, Sisodiya SM, Sander JW. Comorbidities of epilepsy: current concepts and future perspectives. *Lancet Neurol* 2016; **15**: 106-115 [PMID: [26549780](#) DOI: [10.1016/S1474-4422\(15\)00225-2](#)]
- 23 **Magon P**. Abdominal epilepsy misdiagnosed as peptic ulcer pain. *Indian J Pediatr* 2010; **77**: 916 [PMID: [20721702](#) DOI: [10.1007/s12098-010-0141-y](#)]
- 24 **Watari T**, Tokuda Y. Bleeding from a gut lesion as a cause of seizure. *BMJ Case Rep* 2015; **2015** [PMID: [25976184](#) DOI: [10.1136/bcr-2014-205619](#)]
- 25 **Ribaldone DG**, Astegiano M, Fagoonee S, Rizzetto M, Pellicano R. Epilepsy and celiac disease: review of literature. *Panminerva Med* 2011; **53**: 213-216 [PMID: [22146418](#)]
- 26 **İşıkay S**, Kocamaz H. Prevalence of celiac disease in children with idiopathic epilepsy in southeast Turkey. *Pediatr Neurol* 2014; **50**: 479-481 [PMID: [24656466](#) DOI: [10.1016/j.pediatrneurol.2014.01.021](#)]
- 27 **Djurić Z**, Nagorni A, Jocić-Jakubi B, Dimić M, Novak M, Miličević R, Radenković G. Celiac disease prevalence in epileptic children from Serbia. *Turk J Pediatr* 2012; **54**: 247-250 [PMID: [23094534](#)]
- 28 **Pratesi R**, Modelli IC, Martins RC, Almeida PL, Gandolfi L. Celiac disease and epilepsy: favorable outcome in a child with difficult to control seizures. *Acta Neurol Scand* 2003; **108**: 290-293 [PMID: [12956865](#) DOI: [10.1034/j.1600-0404.2003.00082.x](#)]
- 29 **Hadjivassiliou M**, Gibson A, Davies-Jones GA, Lobo AJ, Stephenson TJ, Milford-Ward A. Does cryptic gluten sensitivity play a part in neurological illness? *Lancet* 1996; **347**: 369-371 [PMID: [8598704](#) DOI: [10.1016/s0140-6736\(96\)90540-1](#)]
- 30 **Swartwood S**, Wilkes J, Bonkowski JL, Trandafir CC. Celiac Disease in Children: An Association With Drug-Resistant Epilepsy. *Pediatr Neurol* 2021; **120**: 12-17 [PMID: [33962344](#) DOI: [10.1016/j.pediatrneurol.2021.03.003](#)]
- 31 **Huang TS**, Lu XG, Li B, Chen Y, Wen JL, Hu Y, Chen L, Xiao YH, Zhang J, Liao JX. [Benign infantile convulsions with mild gastroenteritis: clinical analysis of 40 cases]. *Zhongguo Dang Dai Er Ke Za Zhi* 2010; **12**: 533-535 [PMID: [20637150](#)]
- 32 **Şafak B**, Altunhan B, Topçu B, Eren Topkaya A. The gut microbiome in epilepsy. *Microb Pathog* 2020; **139**: 103853 [PMID: [31730997](#) DOI: [10.1016/j.micpath.2019.103853](#)]
- 33 **Peng A**, Qiu X, Lai W, Li W, Zhang L, Zhu X, He S, Duan J, Chen L. Altered composition of the gut microbiome in patients with drug-resistant epilepsy. *Epilepsy Res* 2018; **147**: 102-107 [PMID: [30291996](#) DOI: [10.1016/j.eplepsyres.2018.09.013](#)]
- 34 **Xie G**, Zhou Q, Qiu CZ, Dai WK, Wang HP, Li YH, Liao JX, Lu XG, Lin SF, Ye JH, Ma ZY, Wang WJ. Ketogenic diet poses a significant effect on imbalanced gut microbiota in infants with refractory epilepsy. *World J Gastroenterol* 2017; **23**: 6164-6171 [PMID: [28970732](#) DOI: [10.3748/wjg.v23.i33.6164](#)]
- 35 **Chey WD**, Kurlander J, Eswaran S. Irritable bowel syndrome: a clinical review. *JAMA* 2015; **313**: 949-958 [PMID: [25734736](#) DOI: [10.1001/jama.2015.0954](#)]
- 36 **Chen CH**, Lin CL, Kao CH. Irritable Bowel Syndrome Increases the Risk of Epilepsy: A Population-Based Study. *Medicine (Baltimore)* 2015; **94**: e1497 [PMID: [26356716](#) DOI: [10.1097/MD.0000000000001497](#)]
- 37 **Camara-Lemarroy CR**, Escobedo-Zúñiga N, Ortiz-Zacarias D, Peña-Avendaño J, Villarreal-Garza E, Díaz-Torres MA. Prevalence and impact of irritable bowel syndrome in people with epilepsy. *Epilepsy Behav* 2016; **63**: 29-33 [PMID: [27552483](#) DOI: [10.1016/j.yebeh.2016.05.041](#)]
- 38 **Aydemir Y**, Carman KB, Yazar C. Screening for functional gastrointestinal disorders in children with epilepsy. *Epilepsy Behav* 2020; **111**: 107267 [PMID: [32629413](#) DOI: [10.1016/j.yebeh.2020.107267](#)]
- 39 **Mendler MH**, Sautereau D, Pillegand B, Ravon R. [A case of digestive epilepsy with late diagnosis: a disease not to be disregarded]. *Gastroenterol Clin Biol* 1998; **22**: 235-239 [PMID: [9762197](#)]
- 40 **Jones MP**, Dilley JB, Drossman D, Crowell MD. Brain-gut connections in functional GI disorders: anatomic and physiologic relationships. *Neurogastroenterol Motil* 2006; **18**: 91-103 [PMID: [16420287](#) DOI: [10.1111/j.1365-2982.2005.00730.x](#)]
- 41 **Verdu EF**, Collins SM. Microbial-gut interactions in health and disease. Irritable bowel syndrome. *Best Pract Res Clin Gastroenterol* 2004; **18**: 315-321 [PMID: [15123072](#) DOI: [10.1016/j.bpg.2003.11.003](#)]
- 42 **Ohman L**, Simrén M. Pathogenesis of IBS: role of inflammation, immunity and neuroimmune interactions. *Nat Rev Gastroenterol Hepatol* 2010; **7**: 163-173 [PMID: [20101257](#) DOI: [10.1038/nrgastro.2010.4](#)]
- 43 **Ashrafi-Asgarabad A**, Ayubi E, Safiri S. Prevalence and impact of irritable bowel syndrome in people with epilepsy: Methodological issues. *Epilepsy Behav* 2017; **69**: 223-224 [PMID: [28242310](#) DOI: [10.1016/j.yebeh.2016.11.030](#)]

- 44 **Avorio F**, Cerulli Irelli E, Morano A, Fanella M, Orlando B, Albini M, Basili LM, Ruffolo G, Fattouch J, Manfredi M, Russo E, Striano P, Carabotti M, Giallardo AT, Severi C, Di Bonaventura C. Functional Gastrointestinal Disorders in Patients With Epilepsy: Reciprocal Influence and Impact on Seizure Occurrence. *Front Neurol* 2021; **12**: 705126 [PMID: 34421803 DOI: 10.3389/fneur.2021.705126]
- 45 **Wen Z**, Fiocchi C. Inflammatory bowel disease: autoimmune or immune-mediated pathogenesis? *Clin Dev Immunol* 2004; **11**: 195-204 [PMID: 15559364 DOI: 10.1080/17402520400004201]
- 46 **Ferro JM**, Oliveira Santos M. Neurology of inflammatory bowel disease. *J Neurol Sci* 2021; **424**: 117426 [PMID: 33810878 DOI: 10.1016/j.jns.2021.117426]
- 47 **Casella G**, Tontini GE, Bassotti G, Pastorelli L, Villanacci V, Spina L, Baldini V, Vecchi M. Neurological disorders and inflammatory bowel diseases. *World J Gastroenterol* 2014; **20**: 8764-8782 [PMID: 25083051 DOI: 10.3748/wjg.v20.i27.8764]
- 48 **Cheng K**, Faye AS. Venous thromboembolism in inflammatory bowel disease. *World J Gastroenterol* 2020; **26**: 1231-1241 [PMID: 32256013 DOI: 10.3748/wjg.v26.i12.1231]
- 49 **Al-Biltagi M**, Saeed NK, Qaraghuli S. Gastrointestinal disorders in children with autism: Could artificial intelligence help? *Artif Intell Gastroenterol* 2022; **3**: 1-12 [DOI: 10.35712/aig.v3.i1.1]
- 50 **Al-Beltagi M**. Autism medical comorbidities. *World J Clin Pediatr* 2021; **10**: 15-28 [PMID: 33972922 DOI: 10.5409/wjcp.v10.i3.15]
- 51 **Castellazzi L**, Principi N, Agostoni C, Esposito S. Benign convulsions in children with mild gastroenteritis. *Eur J Paediatr Neurol* 2016; **20**: 690-695 [PMID: 27292317 DOI: 10.1016/j.ejpn.2016.05.014]
- 52 **Khosroshahi N**, Rahbarimanesh A, Boroujeni FA, Eskandarizadeh Z, Zoham MH. Afebrile Benign Convulsion Associated With Mild Gastroenteritis: A Cohort Study in a Tertiary Children Hospital. *Child Neurol Open* 2018; **5**: 2329048X18773498 [PMID: 29881767 DOI: 10.1177/2329048X18773498]
- 53 **Hartmann H**. Benign Convulsions with Mild Gastroenteritis-An Underestimated Phenomenon? *Neuropediatrics* 2020; **51**: 313-314 [PMID: 32818968 DOI: 10.1055/s-0040-1715624]
- 54 **Lee YS**, Lee GH, Kwon YS. Update on benign convulsions with mild gastroenteritis. *Clin Exp Pediatr* 2021 [PMID: 34961297 DOI: 10.3345/cep.2021.00997]
- 55 **Kang B**, Kwon YS. Benign convulsion with mild gastroenteritis. *Korean J Pediatr* 2014; **57**: 304-309 [PMID: 25114690 DOI: 10.3345/kjp.2014.57.7.304]
- 56 **Ma X**, Luan S, Zhao Y, Lv X, Zhang R. Clinical characteristics and follow-up of benign convulsions with mild gastroenteritis among children. *Medicine (Baltimore)* 2019; **98**: e14082 [PMID: 30633216 DOI: 10.1097/MD.00000000000014082]
- 57 **Camilleri M**. Gastrointestinal motility disorders in neurologic disease. *J Clin Invest* 2021; **131** [PMID: 33586685 DOI: 10.1172/JCI143771]
- 58 **Spencer D**. Auras Are Frequent in Patients With Generalized Epilepsy. *Epilepsy Curr* 2015; **15**: 75-77 [PMID: 26251645 DOI: 10.5698/1535-7597-15.2.75]
- 59 **Fernández-Torre JL**. [Epileptic auras: classification, pathophysiology, practical usefulness, differential diagnosis and controversies]. *Rev Neurol* 2002; **34**: 977-983 [PMID: 12134331]
- 60 **Russo A**, Arbune AA, Bansal L, Mindruta I, Gobbi G, Duchowny M. The localizing value of epileptic auras: pitfalls in semiology and involved networks. *Epileptic Disord* 2019; **21**: 519-528 [PMID: 31823838 DOI: 10.1684/epd.2019.1106]
- 61 **Nakken KO**, Solaas MH, Kjeldsen MJ, Friis ML, Pellock JM, Corey LA. The occurrence and characteristics of auras in a large epilepsy cohort. *Acta Neurol Scand* 2009; **119**: 88-93 [PMID: 18638041 DOI: 10.1111/j.1600-0404.2008.01069.x]
- 62 **Liu Y**, Guo XM, Wu X, Li P, Wang WW. Clinical Analysis of Partial Epilepsy with Auras. *Chin Med J (Engl)* 2017; **130**: 318-322 [PMID: 28139515 DOI: 10.4103/0366-6999.198918]
- 63 **Stern JM**. Focal Seizures with Gustatory Hallucinations. In: Panayiotopoulos C.P. (eds) Atlas of Epilepsies. London: Springer, 2010
- 64 **Acharya V**, Acharya J, Lüders H. Study of epileptic seizures with gustatory auras. *J Clin Neurophysiol* 1996; **13**: 442-443
- 65 **Blom JD**. A. In: A Dictionary of Hallucinations. New York, NY: Springer, 2010
- 66 **Schmitt JJ**, Ebner A. [Anatomic substrate of epigastric aura: case report]. *Nervenarzt* 2000; **71**: 485-488 [PMID: 10919145 DOI: 10.1007/s001150050612]
- 67 **Thijs RD**, Ryvlin P, Surges R. Autonomic manifestations of epilepsy: emerging pathways to sudden death? *Nat Rev Neurol* 2021; **17**: 774-788 [PMID: 34716432 DOI: 10.1038/s41582-021-00574-w]
- 68 **King HH**, Cayce CT, Herrin J. Thermography Examination of Abdominal Area Skin Temperatures in Individuals With and Without Focal-Onset Epilepsy. *Explore (NY)* 2017; **13**: 46-52 [PMID: 27876238 DOI: 10.1016/j.explore.2016.10.003]
- 69 **de Font-Réaulx E**, Terrazo-Lluch J, Díaz-López LG, Collado-Corona MÁ, Shkurovich-Bialik P, González-Astiazarán A. Localization of irritative zones in epilepsy with thermochromic silicone. *Surg Neurol Int* 2022; **13**: 14 [PMID: 35127214 DOI: 10.25259/SNI\_1169\_2021]
- 70 **Gschossmann JM**, Holtmann G, Netzer P, Essig M, Balsiger BM, Scheurer U. [Abdominal pain]. *Internist (Berl)* 2005; **46**: 1096-1104 [PMID: 15990989 DOI: 10.1007/s00108-005-1457-y]
- 71 **Frumkin K**, Delahanty LF. Peripheral neuropathic mimics of visceral abdominal pain: Can physical examination limit diagnostic testing? *Am J Emerg Med* 2018; **36**: 2279-2285 [PMID: 30170933 DOI: 10.1016/j.ajem.2018.08.042]
- 72 **Palmer J**, Pontius E. Abdominal Pain Mimics. *Emerg Med Clin North Am* 2016; **34**: 409-423 [PMID: 27133252 DOI: 10.1016/j.emc.2015.12.007]
- 73 **Kshirsagar VY**, Nagarsenkar S, Ahmed M, Colaco S, Wingkar KC. Abdominal epilepsy in chronic recurrent abdominal pain. *J Pediatr Neurosci* 2012; **7**: 163-166 [PMID: 23559997 DOI: 10.4103/1817-1745.106468]
- 74 **Tiamkao S**, Pratipanawatr T, Jitpimolnart S. Abdominal epilepsy: an uncommon of non-convulsive status epilepticus. *J Med Assoc Thai* 2011; **94**: 998-1001 [PMID: 21863684]
- 75 **Siegel AM**, Williamson PD, Roberts DW, Thadani VM, Darcey TM. Localized pain associated with seizures originating



- in the parietal lobe. *Epilepsia* 1999; **40**: 845-855 [PMID: [10403207](#) DOI: [10.1111/j.1528-1157.1999.tb00790.x](#)]
- 76 **Topno N**, Gopasetty MS, Kudva A, B L. Abdominal epilepsy and foreign body in the abdomen--dilemma in diagnosis of abdominal pain. *Yonsei Med J* 2005; **46**: 870-873 [PMID: [16385668](#) DOI: [10.3349/ymj.2005.46.6.870](#)]
  - 77 **Franzon RC**, Lopes CF, Schmutzler KM, Morais MI, Guerreiro MM. Recurrent abdominal pain: when should an epileptic seizure be suspected? *Arq Neuropsiquiatr* 2002; **60**: 628-630 [PMID: [12244404](#) DOI: [10.1590/s0004-282x2002000400021](#)]
  - 78 **Yunus Y**, Sefer U, Dondu UU, Ismail O, Yusuf E. Abdominal epilepsy as an unusual cause of abdominal pain: a case report. *Afr Health Sci* 2016; **16**: 877-879 [PMID: [27917225](#) DOI: [10.4314/ahs.v16i3.32](#)]
  - 79 **Zinkin NT**, Peppercorn MA. Abdominal epilepsy. *Best Pract Res Clin Gastroenterol* 2005; **19**: 263-274 [PMID: [15833692](#) DOI: [10.1016/j.bpg.2004.10.001](#)]
  - 80 **Lusić I**, Pintarić I, Hozo I, Boić L, Capkun V. Serum prolactin levels after seizure and syncopal attacks. *Seizure* 1999; **8**: 218-222 [PMID: [10452919](#) DOI: [10.1053/seiz.1999.0284](#)]
  - 81 **Winawer MR**, Connors R; EPGP Investigators. Evidence for a shared genetic susceptibility to migraine and epilepsy. *Epilepsia* 2013; **54**: 288-295 [PMID: [23294289](#) DOI: [10.1111/epi.12072](#)]
  - 82 **Dutta SR**, Hazarika I, Chakravarty BP. Abdominal epilepsy, an uncommon cause of recurrent abdominal pain: a brief report. *Gut* 2007; **56**: 439-441 [PMID: [17339252](#) DOI: [10.1136/gut.2006.094250](#)]
  - 83 **Pottkämper JCM**, Hofmeijer J, van Waarde JA, van Putten MJAM. The postictal state - What do we know? *Epilepsia* 2020; **61**: 1045-1061 [PMID: [32396219](#) DOI: [10.1111/epi.16519](#)]
  - 84 **Löscher W**, Köhling R. Functional, metabolic, and synaptic changes after seizures as potential targets for antiepileptic therapy. *Epilepsy Behav* 2010; **19**: 105-113 [PMID: [20705520](#) DOI: [10.1016/j.yebeh.2010.06.035](#)]
  - 85 **Prager O**, Kamintsky L, Hasam-Henderson LA, Schoknecht K, Wuntke V, Papageorgiou I, Swolinsky J, Muoio V, Bar-Klein G, Vazana U, Heinemann U, Friedman A, Kovács R. Seizure-induced microvascular injury is associated with impaired neurovascular coupling and blood-brain barrier dysfunction. *Epilepsia* 2019; **60**: 322-336 [PMID: [30609012](#) DOI: [10.1111/epi.14631](#)]
  - 86 **Fisher RS**, Scharfman HE, deCurtis M. How can we identify ictal and interictal abnormal activity? *Adv Exp Med Biol* 2014; **813**: 3-23 [PMID: [25012363](#) DOI: [10.1007/978-94-017-8914-1\\_1](#)]
  - 87 **Olejniczak PW**, Mader E, Butterbaugh G, Fisch BJ, Carey M. Postictal EEG suppression and hippocampal atrophy in temporal lobe epilepsy. *J Clin Neurophysiol* 2001; **18**: 2-8 [PMID: [11290932](#) DOI: [10.1097/00004691-200101000-00002](#)]
  - 88 **Hoffmann JM**, Elger CE, Kleefuss-Lie AA. The localizing value of hypersalivation and postictal coughing in temporal lobe epilepsy. *Epilepsy Res* 2009; **87**: 144-147 [PMID: [19748227](#) DOI: [10.1016/j.eplepsyres.2009.08.005](#)]
  - 89 **Caicoya AG**, Serratos JM. Postictal behaviour in temporal lobe epilepsy. *Epileptic Disord* 2006; **8**: 228-231 [PMID: [16987747](#)]
  - 90 **Janszky J**, Fogarasi A, Toth V, Magalova V, Gyimesi C, Kovacs N, Schulz R, Ebner A. Peri-ictal vegetative symptoms in temporal lobe epilepsy. *Epilepsy Behav* 2007; **11**: 125-129 [PMID: [17584534](#) DOI: [10.1016/j.yebeh.2007.04.015](#)]
  - 91 **Ott BR**. Bulimia in a patient with temporal lobe epilepsy. *J Neurol Neurosurg Psychiatry* 1991; **54**: 1020-1021 [PMID: [1800654](#) DOI: [10.1136/jnnp.54.11.1020](#)]
  - 92 **Mittal S**, Farmer JP, Rosenblatt B, Andermann F, Montes JL, Villemure JG. Intractable epilepsy after a functional hemispherectomy: important lessons from an unusual case. Case report. *J Neurosurg* 2001; **94**: 510-514 [PMID: [11235958](#) DOI: [10.3171/jns.2001.94.3.0510](#)]
  - 93 **Remick RA**, Jones MW, Campos PE. Postictal bulimia. *J Clin Psychiatry* 1980; **41**: 256 [PMID: [6930374](#)]
  - 94 **Perucca P**, Gilliam FG. Adverse effects of antiepileptic drugs. *Lancet Neurol* 2012; **11**: 792-802 [PMID: [22832500](#) DOI: [10.1016/S1474-4422\(12\)70153-9](#)]
  - 95 **Wiebe S**, Téllez-Zenteno JF, Shapira M. An evidence-based approach to the first seizure. *Epilepsia* 2008; **49** Suppl 1: 50-57 [PMID: [18184156](#) DOI: [10.1111/j.1528-1167.2008.01451.x](#)]
  - 96 **Shafagh-Ardestani MH**, Karami-Horestani M, Emami B, Arjmandpour A. Evaluating the Effect of Oral Gabapentin on the Improvement of Gastrointestinal Symptoms in Patients with Functional Dyspepsia Resistant to Conventional Treatments. *Adv Biomed Res* 2019; **8**: 53 [PMID: [31516891](#) DOI: [10.4103/abr.abr\\_234\\_18](#)]
  - 97 **Lee KJ**, Kim JH, Cho SW. Gabapentin reduces rectal mechanosensitivity and increases rectal compliance in patients with diarrhoea-predominant irritable bowel syndrome. *Aliment Pharmacol Ther* 2005; **22**: 981-988 [PMID: [16268973](#) DOI: [10.1111/j.1365-2036.2005.02685.x](#)]
  - 98 **Liu S**, Liu L, Jin D, Zhang Q, Takai S. The novel mechanism of valproate to prevent peritoneal adhesion formation. *Surg Today* 2020; **50**: 1091-1098 [PMID: [32239305](#) DOI: [10.1007/s00595-020-01979-8](#)]
  - 99 **Felice C**, Lewis A, Iqbal S, Gordon H, Rigoni A, Colombo MP, Armuzzi A, Feakins R, Lindsay JO, Silver A. Intestinal Inflammation is Linked to Hypoacetylation of Histone 3 Lysine 27 and can be Reversed by Valproic Acid Treatment in Inflammatory Bowel Disease Patients. *Cell Mol Gastroenterol Hepatol* 2021; **11**: 889-891.e6 [PMID: [33232823](#) DOI: [10.1016/j.jcmgh.2020.11.009](#)]
  - 100 **Patel MM**, Patel BM. Repurposing of sodium valproate in colon cancer associated with diabetes mellitus: Role of HDAC inhibition. *Eur J Pharm Sci* 2018; **121**: 188-199 [PMID: [29852291](#) DOI: [10.1016/j.ejps.2018.05.026](#)]
  - 101 **Tzovaras G**, Tsiaoussis J, Athanasakis E, Zoras O, Xynos E, Chrysos E. Effect of sodium valproate on esophageal motility in healthy subjects and patients with gastroesophageal reflux. *Scand J Gastroenterol* 2004; **39**: 521-526 [PMID: [15223674](#) DOI: [10.1080/00365520410004433](#)]
  - 102 **Valaes T**, Kipouros K, Petmezaki S, Solman M, Doxiadis SA. Effectiveness and safety of prenatal phenobarbital for the prevention of neonatal jaundice. *Pediatr Res* 1980; **14**: 947-952 [PMID: [7422399](#) DOI: [10.1203/00006450-198008000-00011](#)]
  - 103 **Chawla D**, Parmar V. Phenobarbitone for prevention and treatment of unconjugated hyperbilirubinemia in preterm neonates: a systematic review and meta-analysis. *Indian Pediatr* 2010; **47**: 401-407 [PMID: [19736369](#) DOI: [10.1007/s13312-010-0075-5](#)]
  - 104 **Ding M**, Lang Y, Shu H, Shao J, Cui L. Microbiota-Gut-Brain Axis and Epilepsy: A Review on Mechanisms and Potential Therapeutics. *Front Immunol* 2021; **12**: 742449 [PMID: [34707612](#) DOI: [10.3389/fimmu.2021.742449](#)]



- 105 **Martyniak A**, Medyńska-Przęczek A, Wędrychowicz A, Skoczeń S, Tomasik PJ. Prebiotics, Probiotics, Synbiotics, Paraprobiotics and Postbiotic Compounds in IBD. *Biomolecules* 2021; **11** [PMID: [34944546](#) DOI: [10.3390/biom11121903](#)]
- 106 **Gómez-Eguílaz M**, Ramón-Trapero JL, Pérez-Martínez L, Blanco JR. The beneficial effect of probiotics as a supplementary treatment in drug-resistant epilepsy: a pilot study. *Benef Microbes* 2018; **9**: 875-881 [PMID: [30198325](#) DOI: [10.3920/BM2018.0018](#)]
- 107 **Boeri L**, Donnalaja F, Campanile M, Sardelli L, Tunesi M, Fusco F, Giordano C, Albani D. Using integrated meta-omics to appreciate the role of the gut microbiota in epilepsy. *Neurobiol Dis* 2022; **164**: 105614 [PMID: [35017031](#) DOI: [10.1016/j.nbd.2022.105614](#)]
- 108 **Kitamura S**, Sugihara K, Kuwasako M, Tatsumi K. The role of mammalian intestinal bacteria in the reductive metabolism of zonisamide. *J Pharm Pharmacol* 1997; **49**: 253-256 [PMID: [9231340](#) DOI: [10.1111/j.2042-7158.1997.tb06790.x](#)]
- 109 **He Z**, Cui BT, Zhang T, Li P, Long CY, Ji GZ, Zhang FM. Fecal microbiota transplantation cured epilepsy in a case with Crohn's disease: The first report. *World J Gastroenterol* 2017; **23**: 3565-3568 [PMID: [28596693](#) DOI: [10.3748/wjg.v23.i19.3565](#)]
- 110 **Dahlin M**, Prast-Nielsen S. The gut microbiome and epilepsy. *EBioMedicine* 2019; **44**: 741-746 [PMID: [31160269](#) DOI: [10.1016/j.ebiom.2019.05.024](#)]
- 111 **Olson CA**, Vuong HE, Yano JM, Liang QY, Nusbaum DJ, Hsiao EY. The Gut Microbiota Mediates the Anti-Seizure Effects of the Ketogenic Diet. *Cell* 2018; **173**: 1728-1741.e13 [PMID: [29804833](#) DOI: [10.1016/j.cell.2018.04.027](#)]
- 112 **D'Andrea Meira I**, Romão TT, Pires do Prado HJ, Krüger LT, Pires MEP, da Conceição PO. Ketogenic Diet and Epilepsy: What We Know So Far. *Front Neurosci* 2019; **13**: 5 [PMID: [30760973](#) DOI: [10.3389/fnins.2019.00005](#)]
- 113 **Rho JM**. How does the ketogenic diet induce antiseizure effects? *Neurosci Lett* 2017; **637**: 4-10 [PMID: [26222258](#) DOI: [10.1016/j.neulet.2015.07.034](#)]
- 114 **Juge N**, Gray JA, Omote H, Miyaji T, Inoue T, Hara C, Uneyama H, Edwards RH, Nicoll RA, Moriyama Y. Metabolic control of vesicular glutamate transport and release. *Neuron* 2010; **68**: 99-112 [PMID: [20920794](#) DOI: [10.1016/j.neuron.2010.09.002](#)]
- 115 **Breit S**, Kupferberg A, Rogler G, Hasler G. Vagus Nerve as Modulator of the Brain-Gut Axis in Psychiatric and Inflammatory Disorders. *Front Psychiatry* 2018; **9**: 44 [PMID: [29593576](#) DOI: [10.3389/fpsy.2018.00044](#)]
- 116 **Shaikh MF**, Lee CY, Chen WN, Shaikh FA. The Gut-Brain-Axis on the Manifestation of Depressive Symptoms in Epilepsy: An Evidence-Driven Hypothesis. *Front Pharmacol* 2020; **11**: 465 [PMID: [32322213](#) DOI: [10.3389/fphar.2020.00465](#)]
- 117 **Bonaz B**, Sinniger V, Pellissier S. Vagus Nerve Stimulation at the Interface of Brain-Gut Interactions. *Cold Spring Harb Perspect Med* 2019; **9** [PMID: [30201788](#) DOI: [10.1101/cshperspect.a034199](#)]
- 118 **Bonaz B**, Sinniger V, Pellissier S. Therapeutic Potential of Vagus Nerve Stimulation for Inflammatory Bowel Diseases. *Front Neurosci* 2021; **15**: 650971 [PMID: [33828455](#) DOI: [10.3389/fnins.2021.650971](#)]
- 119 **Di Nicola V**. Omentum a powerful biological source in regenerative surgery. *Regen Ther* 2019; **11**: 182-191 [PMID: [31453273](#) DOI: [10.1016/j.reth.2019.07.008](#)]
- 120 **Shah S**, Lowery E, Braun RK, Martin A, Huang N, Medina M, Sethupathi P, Seki Y, Takami M, Byrne K, Wigfield C, Love RB, Iwashima M. Cellular basis of tissue regeneration by omentum. *PLoS One* 2012; **7**: e38368 [PMID: [22701632](#) DOI: [10.1371/journal.pone.0038368](#)]
- 121 **Rafael H**, Mego R, Moromizato P, Garcia W. Omental transplantation for temporal lobe epilepsy: report of two cases. *Neurol India* 2002; **50**: 71-74 [PMID: [11960156](#)]
- 122 **Jahromi SR**, Togha M, Fesharaki SH, Najafi M, Moghadam NB, Kheradmand JA, Kazemi H, Gorji A. Gastrointestinal adverse effects of antiepileptic drugs in intractable epileptic patients. *Seizure* 2011; **20**: 343-346 [PMID: [21236703](#) DOI: [10.1016/j.seizure.2010.12.011](#)]
- 123 **Anttila VJ**, Valtonen M. Carbamazepine-induced eosinophilic colitis. *Epilepsia* 1992; **33**: 119-121 [PMID: [1733744](#) DOI: [10.1111/j.1528-1157.1992.tb02293.x](#)]
- 124 **Kristev A**, Sirakov V, Kostadinova I, Lukanov J. The ethosuximide-induced hyperpolarization of smooth muscle tissues--a cause of functional changes in the gastrointestinal tract of rats--is provoked by CA(2+)-dependent K(+)-efflux. *Folia Med (Plovdiv)* 1994; **36**: 13-22 [PMID: [8698280](#)]
- 125 **Zagorchev P**, Sirakov V, Uchikov A, Sirakov N. Ethosuximide induced changes in the gastrointestinal tract. *Folia Med (Plovdiv)* 1998; **40**: 28-33 [PMID: [10205989](#)]
- 126 **Smythe MA**, Umstead GS. Phenytoin hepatotoxicity: a review of the literature. *DICP* 1989; **23**: 13-18 [PMID: [2655293](#) DOI: [10.1177/106002808902300102](#)]
- 127 **Bell RD**, Pak CY, Zerwekh J, Barilla DE, Vasko M. Effect of phenytoin on bone and vitamin D metabolism. *Ann Neurol* 1979; **5**: 374-378 [PMID: [220903](#) DOI: [10.1002/ana.410050411](#)]
- 128 **Abdullah AT**, Mousheer ZT. Vitamin D Status in Epileptic Children on Valproic Acid; a Case-Control Study. *Arch Acad Emerg Med* 2020; **8**: e13 [PMID: [32259112](#)]
- 129 **Minton GC**, Miller AD, Bookstaver PB, Love BL. Topiramate: safety and efficacy of its use in the prevention and treatment of migraine. *J Cent Nerv Syst Dis* 2011; **3**: 155-168 [PMID: [23861645](#) DOI: [10.4137/JCNSD.S4365](#)]



Published by **Baishideng Publishing Group Inc**  
7041 Koll Center Parkway, Suite 160, Pleasanton, CA 94566, USA

**Telephone:** +1-925-3991568

**E-mail:** [bpgoffice@wjgnet.com](mailto:bpgoffice@wjgnet.com)

**Help Desk:** <https://www.f6publishing.com/helpdesk>

<https://www.wjgnet.com>

