









# Surgical Use of Supraclavicular Artery Flap for Head and Neck Cancer Defects Repair: Personal Experience

Luigi Filippo D'Aco<sup>1</sup>  Laura Cagnoni<sup>1</sup>  Carmelo Murè<sup>1</sup>  Alessandro Piazza<sup>1</sup>  Giuseppe Aresi<sup>1</sup>   
Davide Thomas Panciera<sup>1</sup> 

<sup>1</sup> Department of Otorhinolaryngology, Azienda Socio Sanitaria Territoriale (ASST) Bergamo Est, Hospital Bolognini, Seriate (BG), Italy

Address for correspondence Laura Cagnoni, medical doctor, Azienda Socio Sanitaria Territoriale (ASST) Bergamo est – Hospital “Bolognini,” Department of Otorhinolaryngology, Via Paderno 21, 24068, Seriate (BG), Italy (e-mail: laura.cagnoni@asst-bergamoest.it).

Int Arch Otorhinolaryngol 2023;27(1):e117–e122.

## Abstract

**Introduction** For a long time, major surgical defects after oncological surgery have always been challenging cases for surgeons in terms of wound healing and covering technique.

**Objectives** To demonstrate the feasibility of supraclavicular artery flap (SCAF) in the reconstruction of surgical defects in those “fragile” patients undergoing oncological surgery who could not possibly have endured the timeframes involved in using microvascular free flaps.

**Methods** Between January 2018 and January 2019, at the Azienda Socio Sanitaria Territoriale (ASST) Bergamo Est Hospital (Bergamo, Italy), we reported the cases of 11 patients in whom the SCAF was used for surgical reconstruction after oncological surgery in our Otolaryngology Department. The median age of the 11 patients was 68.7 years old.

**Results** The SCAF has proved, in almost all 11 cases in which it was used, to be very reliable and, above all, easy and quick to make in those “fragile” patients without the need for further intervention. There was only one case in which the resection involved the auricle entirely and a small area of perimeatal bone exposure occurred, which, anyway, healed by secondary intention.

**Conclusion** The SCAF is an extremely versatile flap for head and neck surgery to be considered especially for fragile and vulnerable patients who cannot undergo prolonged surgical time. Moreover, this technique has also shown high feasibility in small hospitals where there is not a plastic surgery department and the surgeon may face the difficulty of practicing surgical reconstruction after enlarged resection.

## Keywords

- ▶ surgical flaps
- ▶ reconstructive surgical procedures
- ▶ operative time

## Introduction

Major surgical defects after ear, nose, and throat (ENT) oncological surgery have, for a long time, presented challenges for surgeons.<sup>1</sup> Over the last few decades, the use of

microvascular free flaps has provided a vast range of reconstructive solutions for wound healing and covering techniques following surgical defects in the head and neck area.<sup>2,3</sup>

However, the feasibility of reconstructive surgery with free flaps is affected by local factors related to the surgical

received  
September 25, 2021  
accepted after revision  
January 26, 2022

DOI <https://doi.org/10.1055/s-0042-1744169>.  
ISSN 1809-9777.

© 2023. Fundação Otorrinolaringologia. All rights reserved.  
This is an open access article published by Thieme under the terms of the Creative Commons Attribution-NonDerivative-NonCommercial-License, permitting copying and reproduction so long as the original work is given appropriate credit. Contents may not be used for commercial purposes, or adapted, remixed, transformed or built upon. (<https://creativecommons.org/licenses/by-nc-nd/4.0/>)  
Thieme Revinter Publicações Ltda., Rua do Matoso 170, Rio de Janeiro, RJ, CEP 20270-135, Brazil

site (such as the suitability of the vessels for anastomoses and vasculopathies) and by the condition of the patient (age, a complex history of present illness or past medical history). In some instances, these factors may mean that prolonged intraoperative anesthesiology, often required for reconstructive surgery with free flaps, may not be achievable.<sup>4</sup>

In the present study, we report the cases of 11 patients in whom supraclavicular artery flap (SCAF) was used for surgical reconstruction after oncological surgery between January 2018 and January 2019 in our Otolaryngology Department.<sup>5,6</sup>

## Methods

The medical charts of 11 patients in whom a supraclavicular flap was used for surgical reconstruction after oncological surgery between January 2018 and January 2019 in the Otolaryngology Department of our Hospital were retrospectively reviewed. A supraclavicular flap was used for the reconstruction of large combined defects of the oral cavity in four cases, of the larynx in four cases, and of the skin of the face in three cases.

Male or female patients diagnosed with locally advanced squamous cell carcinoma that required enlarged surgical excision were included in the present study. Patients who had a prior clinical history of other local and laterocervical surgeries or who had undergone any major trauma that could have created defects in the vascular circuit of the SCAF were excluded from the present study. Additionally, any subject who had a history of recreational drug abuse within 6 months prior to the surgery was also excluded.

In one patient, the SCAF was used for the treatment of pharyngocutaneous fistula after a total laryngectomy. In another case, the defect created during the first surgery (pull-through) was repaired with a peltiglossoplasty using a paramedian infrahyoid flap, which in the following days exhibited signs of deterioration. A Thiersch graft obtained at the donor site of the flap was used for reconstruction in 8 patients. The demographic and oncological characteristics of the patients are summarized in ► **Table 1**.

## Anatomical Landmarks

The supraclavicular artery island flap is a fasciocutaneous flap harvested from the supraclavicular and deltoid regions.<sup>7</sup> This flap can be pivoted and transferred to cover many of the postsurgery head and neck defects due to the angle of its rotation and its length.<sup>8</sup> Furthermore, thanks to the skin palette, it offers the opportunity to carry out plastic reconstructive surgery as well as internal reconstructions, including in extensive external areas.<sup>9</sup> The main afferent branch of the supraclavicular flap arises from the transverse cervical artery; the SCAF, specifically, is pedunculated on the supraclavicular artery.<sup>10</sup> The transverse cervical artery can originate from the branches of the thyrocervical trunk or from the first portion of the subclavicular artery. The transverse cervical artery runs posteriorly in the neck and

goes deeper than the posterior belly of the omohyoid muscle. Regarding the supraclavicular artery, it originates from the transverse cervical artery, although it can, less frequently, also originate from the suprascapular artery. The supraclavicular artery then perforates the deep fascia of the deltoid muscle after 2 to 4 cm.<sup>11</sup> Anatomical dissection studies have found that, on average, the diameter of the supraclavicular artery is between 1.1 and 1.5 mm and that its pedicle varies in length between 1 and 7 cm and is present in 80% of cases. Studies based on angiography have shown that the average caliber values are ~ 1.5 mm, with a length of 38 mm.<sup>12</sup>

Regarding skin markers, the supraclavicular artery is located in an ideal triangle consisting of the clavicle at the inferior side, of the posterior margin of the sternocleidomastoid muscle (SCM) medially, and of the jugular vein laterally. Typically, the artery is between 2.5 and 4 cm above the collarbone and 2 cm behind the SCM (► **Fig. 1**). Venous drainage is provided by two “venae comitantes”, which most frequently are tributaries to the transverse cervical vein and, sometimes, drain into the external jugular vein. The tactile sensation of an oral cavity reconstructed with the SCAF recovers to a detectable, though not normal, level within a couple of years. In patients who have already undergone laterocervical neck dissection or other types of local surgery, an ultrasound Doppler or computed tomography (CT) angiography should be performed preoperatively to demonstrate the presence of the vascular peduncle.

## Operative Techniques

The dissection technique was originally described by Lamberty in 1979, was later taken up again and clarified by other authors and standardized by Kokot et al.<sup>13</sup> and, particularly, by Pallua et al.<sup>14–16</sup> The most recent review in the literature is by Chiu et al.:<sup>17</sup> the pedicle is located within a triangular area bounded by the posterior margin of the SCM and by the external jugular vein from the clavicle. The size of the flap is determined by the distance from the “reception” site to be reconstructed and the size of the defect. In addition to an accurate preoperative drawing with a dermatographic pen, we suggest a “template” with gauze to simulate the radius of rotation by moving the gauze around the supraclavicular area. Furthermore, the adequacy of the size necessary to cover the defect should also be verified. The dissection of the flap starts at the distal portion and cautiously moves to the proximal level, where the supraclavicular artery is located. The pedicle is usually covered with fascia and connective tissue.

Surgical positioning for SCAF preparation does not usually involve large movements of the patient. To facilitate dissection, the patient is placed in the supine position, with the shoulder donor site preferably elevated by a pilet. As already mentioned, a preoperative drawing is created (which can be revised during the surgical phases when the resection is well-delineated, to have the actual size): a fusiform-oval island with the proximal portion at the base of the neck, ipsilateral to the defect.

**Table 1** Demographic and oncological characteristics of patients

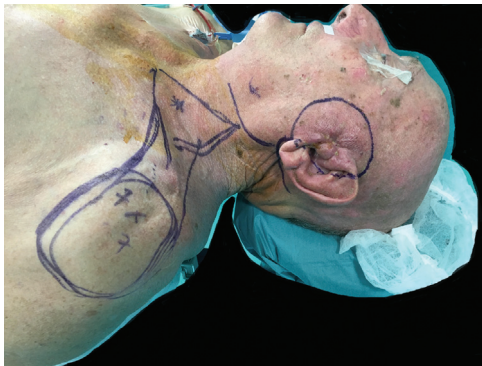
Patients	Age (years old)	Comorbidities	Oncological disease	Surgery
1	48	Psychiatric problems Chronic obstructive pulmonary disease Alveolitis Arthrosis	Laryngeal cancer pT4aN0M0	Total laryngectomy
2	55	Hypertension Thrombocytosis	Laryngeal cancer pT4aN2M0	Total laryngectomy
3	70	Acute myocardial infarction (percutaneous transluminal coronary angioplasty) Hypertension Diabetes Chronic obstructive pulmonary disease Vasculopathy	Laryngeal cancer pT4a N0M0	Pharyngoplasty following total laryngectomy
4	60	Meniscectomy	Oral cavity cancer pT2N0M0	Revision of pelviglossectomy
5	79	Pulmonary edema Hemicolectomy (colon cancer)	Oral cavity cancer pT4aN0M0	Mandibulectomy
6	55	—	Oral cavity cancer pT2N0M0	Mandibulectomy (jawbone interruption)
7	70	Cirrhosis of the liver Erosive gastropathy Hypertension	Oral cavity cancer pT3N2M0	Pull-through mandibulectomy
8	89	Hypertension Acute myocardial infarction Knee prosthesis Chronic venous insufficiency Varicose veins in the lower limb	Skin cancer pT3N0M0	Radical parotidectomy extended to the preparotid skin and the auricle
9	80	Acute myocardial infarction Hypertension Carotid atheroma Cerebral hemorrhage Acute pulmonary edema Deep vein thrombosis Acute myocardial infarction Renal cell carcinoma	Skin cancer pT3N0M0	Auricular parotidectomy, preservation facial n. extended to the pre-parotid skin, to the auricle
10	81	Hypertension Diabetes Aortic valve prosthesis Dyslipidemia	Alveolar ridge cancer pT4aN0M0	Pelvectomy with mandibulectomy
11	69	Acute myocardial infarction (percutaneous transluminal coronary angioplasty)	Laryngeal cancer pT3N2bM0	Salvage total laryngectomy after CTRT failure

Abbreviations: CTRT, chemotherapy and radiotherapy.

Special care must be taken with the collarbone to not remove the periosteum during the harvesting of the SCAF.

To speed up the procedure, the distal portion can only be dissected with an electric scalpel, while the proximal dissection must be performed exclusively with a cold blade and with careful hemostatic control through delicate use of the bipolar forceps on the perimeter of the flap. Once the pedicle has been skeletonized and the flap has been sculpted, it is not difficult to rotate the flap by 180 degrees.

In internal reconstructions,<sup>18</sup> that is, those that require a portion of the flap to penetrate a tunnel, surgical time must be dedicated to the de-epithelialization of the area, which will then be placed internally, replacing the mucosa. This procedure makes possible to obtain free skin graft (exactly as a Thiersch graft), which can be used to cover the supraclavicular donor site when closure is not possible due to the size of the harvested flap. It is recommended to use a cold blade scalpel. (► **Fig. 2**) All surgical procedures have been conducted by otolaryngologists.



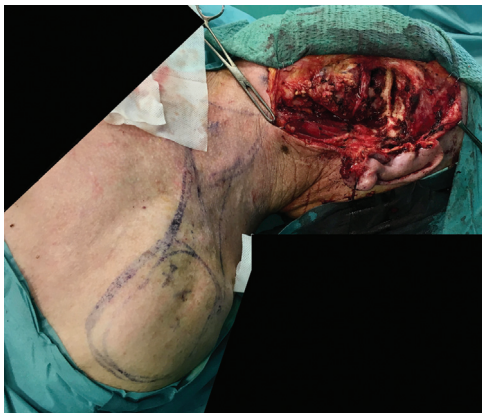**Fig. 1** Preoperative skin markers for the supraclavicular artery flap.

## Results

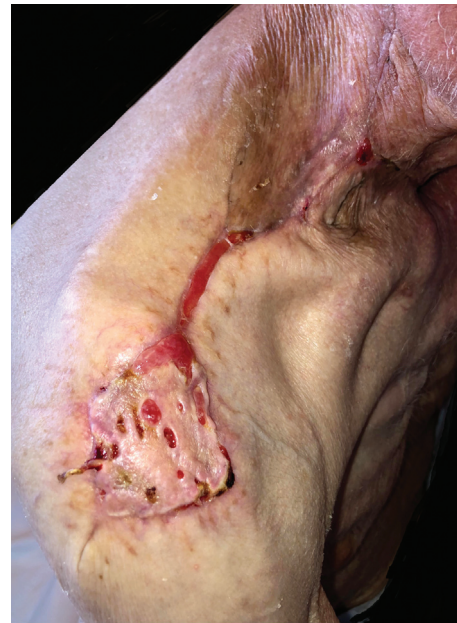The technique has shown highly satisfactory results without the need for further intervention. In particular, in surgical revision, the use of SCAF for closure was essential.

Two patients who underwent surgery for total laryngectomy had complications due to local fistula. In both cases, a revision of the surgical field revealed voluminous pharyngostomas that were completely repaired with SCAF. No further complications were identified. In three cases, however, immediate closure, following a pelvimandibulectomy with SCAF, had already been considered during the planning stage. In these patients, the flap proved to be reliable and did not cause complications, except in one case in which, a few days after surgery, the superficial layer of the flap exhibited some superficial epidermal necrosis, which did not affect the final result. The two cases of skin defects involved extensive epithelial tumors of the face, which involved the surgical excision of large areas of facial skin, as well as parotidectomy and functional neck dissection. (► **Figures 3–6**).

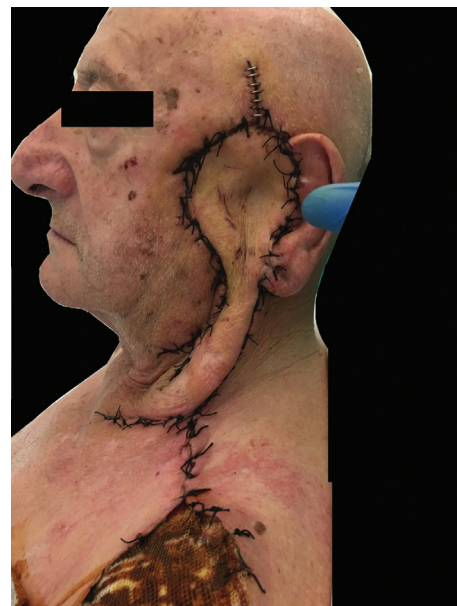In most of these cases, in which the patients were elderly and had significant comorbidities, surgery did not cause complications. However, in one case, the resection involved the auricle entirely and a small area of perimeatal bone



**Fig. 3** Patients with gland metastasis of epithelial skin cancer after total parotidectomy.



**Fig. 2** Free skin flaps (Tiersch flap) used to cover the supraclavicular donor site.

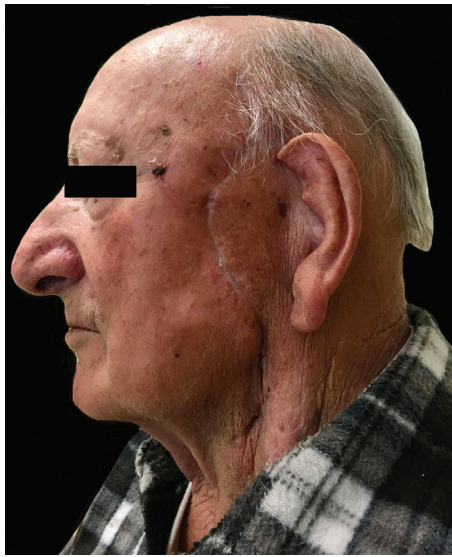

**Fig. 4** Patients with gland metastasis of epithelial skin cancer 10 days after surgery.

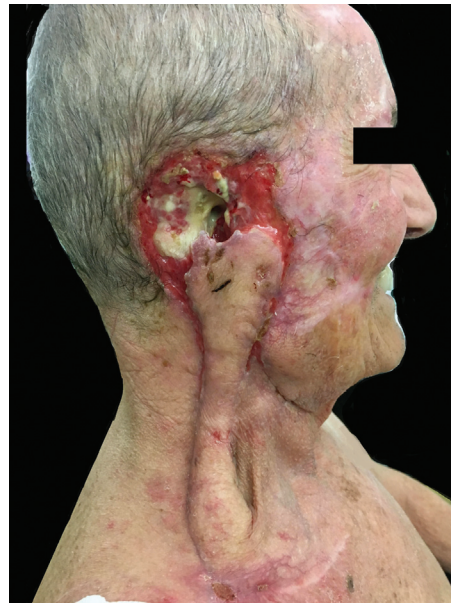exposure occurred, which then healed by secondary intention (► **Fig. 7**).

## Discussion

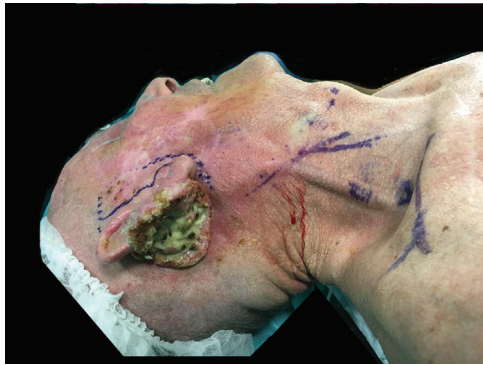In our practice, as reported in the literature,<sup>19</sup> preoperative Doppler was not used to preventively verify the presence of an effective vascular pedicle for the flap. In our experience, the SCAF required an average 40 to 50 minutes of harvesting time, which decreased progressively with practice. Given a



**Fig. 5** Patients with gland metastasis of epithelial skin cancer 2 months after surgery.



**Fig. 7** Postoperative complication.



**Fig. 6** Patient with extensive epithelial tumors of the right auricle before surgery.

net increase in the overall length of the surgery, it was not feasible to create free flaps for patients with comorbidities, and especially for the elderly. In these instances, the SCAF would require different preparation and implementation times. The only part that was a little more challenging, although it was not difficult to perform, was the removal of the skin layer to expose the area of the flap that provides for its internal location. This procedure should always be performed with a cold blade scalpel, as de-epithelialization with an electric scalpel, although apparently faster, inevitably creates damage to the flap itself due to the heat generated by this tool. From our experience, we suggest using the partial-thickness skin graft obtained after de-epithelialization (Thiersch graft) to cover the defect of the supraclavicular donor site where the surgical defect (sometimes even measuring  $8 \times 7$  cm) did not allow, even after mobilizing the surrounding tissues, a first intention closure. The SCAF is extremely effective in treating extensive skin defects, which is in line with the data found in the literature. The presence of the dermal layer has also been found to be useful for the

creation of neopharynx following laryngectomies and for the closure of fistulous passages: the dermal layer increases resistance to erosive salivary phenomena, thus reducing the likelihood of developing postsurgical fistulas.

In oral cavity defects, the capacity and reliability of the flap also proved to be very satisfactory in all cases treated; among these, however, we report only one case in which, as already mentioned, there was an ischemic area of the distal portion of the flap, which was resolved with local dressings and removal of the necrotic area without the need for further surgery.<sup>20</sup> This data, however, correlates with what is reported in the literature. In fact, other authors have reported the possibility of distal partial necrosis, especially in large SCAFs.<sup>21</sup> Compared with, for example, the performance of the pectoral muscle flap, which in some cases has, in our experience, presented partial detachments from the graft site due to its weight, the SCAF did not exhibit this problem.

Almost all patients could feel some kind of tactile sensations in their SCAF flap after surgery. Sometimes, patients have reported a paradoxical hot-cold sensation in the area of the shoulder during meals for a few months after surgery. This is due to normal sensory innervation by the third and fourth cervical nerves originating from the supraclavicular nerve.<sup>22</sup>

Using the SCAF to treat head and neck postoperative defects is an effective choice and offers various advantages. In our experience, it has proved to be reliable and versatile, both in terms of range and applicability. The preparation of the flap itself, both in terms of ease and timing, without demanding a lengthy “learning curve”, deserves a special mention.

In our hands, therefore, and in line with the data in the literature, preparation times have quickly been reduced from  $> 1$  hour to  $\sim 50$  minutes (hence the term in the literature of the “50-minute flap”).

The introduction of the use of the skin graft we obtained after de-epithelialization of the supraclavicular donor site as a Thiersch graft for healing the donor site is recommended to decrease the recovery time and hospitalization. This is also why, in order not to damage the Thiersch graft, it is mandatory to use a cold blade scalpel and not an electric one.

## Conclusion

We conclude that the SCAF is an extremely versatile flap for head and neck surgery and should be considered especially for fragile and vulnerable patients who cannot undergo prolonged surgery. Due to its ease of implementation, the SCAF could also be very useful in hospitals that do not have any plastic surgeons available.

The SCAF significantly shortens the time required for surgery compared with microvascular flaps.

## Conflict of Interests

The authors have no conflict of interests to declare.

## References

- 1 Granzow JW, Suliman A, Roostaeian J, Perry A, Boyd JB. Supraclavicular artery island flap (SCAIF) vs free fasciocutaneous flaps for head and neck reconstruction. *Otolaryngol Head Neck Surg* 2013;148(06):941–948
- 2 Sandu K, Monnier P, Pasche P. Supraclavicular flap in head and neck reconstruction: experience in 50 consecutive patients. *Eur Arch Otorhinolaryngol* 2012;269(04):1261–1267
- 3 Robbins KT, Shaha AR, Medina JE, et al; Committee for Neck Dissection Classification, American Head and Neck Society. Consensus statement on the classification and terminology of neck dissection. *Arch Otolaryngol Head Neck Surg* 2008;134(05):536–538
- 4 Kozin ED, Sethi RK, Herr M, et al. Comparison of perioperative outcomes between the supraclavicular artery island flap and fasciocutaneous free flap. *Otolaryngol Head Neck Surg* 2016;154(01):66–72
- 5 Anand AG, Tran EJ, Hasney CP, Friedlander PL, Chiu ES. Oropharyngeal reconstruction using the supraclavicular artery island flap: a new flap alternative. *Plast Reconstr Surg* 2012;129(02):438–441
- 6 Chu MW, Levy JM, Friedlander PL, Chiu ES. Tracheostoma reconstruction with the supraclavicular artery island flap. *Ann Plast Surg* 2015;74(06):677–679
- 7 Granzow JW, Suliman A, Roostaeian J, Perry A, Boyd JB. The supraclavicular artery island flap (SCAIF) for head and neck reconstruction: surgical technique and refinements. *Otolaryngol Head Neck Surg* 2013;148(06):933–940
- 8 Chen WL, Zhang DM, Yang ZH, et al. Extended supraclavicular fasciocutaneous island flap based on the transverse cervical artery for head and neck reconstruction after cancer ablation. *J Oral Maxillofac Surg* 2010;68(10):2422–2430
- 9 Alves HR, Ishida LC, Ishida LH, et al. A clinical experience of the supraclavicular flap used to reconstruct head and neck defects in late-stage cancer patients. *J Plast Reconstr Aesthet Surg* 2012;65(10):1350–1356
- 10 Giordano L, Di Santo D, Occhini A, et al. Supraclavicular artery island flap (SCAIF): a rising opportunity for head and neck reconstruction. *Eur Arch Otorhinolaryngol* 2016;273(12):4403–4412
- 11 Kim RJT, Izzard ME, Patel RS. Supraclavicular artery island flap for reconstructing defects in the head and neck region. *Curr Opin Otolaryngol Head Neck Surg* 2011;19(04):248–250
- 12 Adams AS, Wright MJ, Johnston S, et al. The use of multislice CT angiography preoperative study for supraclavicular artery island flap harvesting. *Ann Plast Surg* 2012;69(03):312–315
- 13 Kokot N, Mazhar K, Reder LS, Peng GL, Sinha UK. The supraclavicular artery island flap in head and neck reconstruction: applications and limitations. *JAMA Otolaryngol Head Neck Surg* 2013;139(11):1247–1255
- 14 Pallua N, Machens HG, Rennekampff O, Becker M, Berger A. The fasciocutaneous supraclavicular artery island flap for releasing postburn mentosternal contractures. *Plast Reconstr Surg* 1997;99(07):1878–1884, discussion 1885–1886
- 15 Pallua N, Magnus Noah E. The tunneled supraclavicular island flap: an optimized technique for head and neck reconstruction. *Plast Reconstr Surg* 2000;105(03):842–851, discussion 852–854
- 16 Pallua N, Wolter TP. Defect classification and reconstruction algorithm for patients with tracheostomy using the tunneled supraclavicular artery island flap. *Langenbecks Arch Surg* 2010;395(08):1115–1119
- 17 Chiu ES, Liu PH, Friedlander PL. Supraclavicular artery island flap for head and neck oncologic reconstruction: indications, complications, and outcomes. *Plast Reconstr Surg* 2009;124(01):115–123
- 18 Giordano L, Bondi S, Toma S, Biafora M. Versatility of the supraclavicular pedicle flap in head and neck reconstruction. *Acta Otorhinolaryngol Ital* 2014;34(06):394–398
- 19 Emerick KS, Herr MA, Deschler DG. Supraclavicular flap reconstruction following total laryngectomy. *Laryngoscope* 2014;124(08):1777–1782
- 20 Wu H, Chen WL, Yang ZH. Functional reconstruction with an extended supraclavicular fasciocutaneous island flap following ablation of advanced oropharyngeal cancer. *J Craniofac Surg* 2012;23(06):1668–1671
- 21 Goyal N, Emerick KS, Deschler DG, et al. Risk factors for surgical site infection after supraclavicular flap reconstruction in patients undergoing major head and neck surgery. *Head Neck* 2016;38(11):1615–1620
- 22 Sands TT, Martin JB, Simms E, Henderson MM, Friedlander PL, Chiu ES. Supraclavicular artery island flap innervation: anatomical studies and clinical implications. *J Plast Reconstr Aesthet Surg* 2012;65(01):68–71