

## Monitoring follicular dynamics to determine estrus type and timing of ovulation induction in captive brown bears (*Ursus arctos*)

Yoshiko TORII<sup>1)</sup>, Naoya MATSUMOTO<sup>2)</sup>, Hideyuki SAKAMOTO<sup>2)</sup>, Masashi NAGANO<sup>3)</sup>, Seiji KATAGIRI<sup>3)</sup> and Yojiro YANAGAWA<sup>3)</sup>

<sup>1)</sup>Laboratory of Theriogenology, Department of Clinical Sciences, Graduate School of Veterinary Medicine, Hokkaido University, Hokkaido 060-0818, Japan

<sup>2)</sup>Noboribetsu Bear Park, Hokkaido 059-0515, Japan

<sup>3)</sup>Laboratory of Theriogenology, Department of Clinical Sciences, Division of Veterinary Medicine, Faculty of Veterinary Medicine, Hokkaido University, Hokkaido 060-0818, Japan

**Abstract.** It is important to understand ovarian physiology when developing an artificial insemination (AI) protocol. Brown bears (*Ursus arctos*) have a breeding season from May to July, although the type of estrus (polyestrus or monoestrus) is still contested. The present study aimed to define the ovarian dynamics, including follicular waves and ovulatory follicle size, and estrus type in brown bears. Six brown bears were used for ovarian ultrasonography; four were observed between April and October (before the start and after the end of the breeding season) and two in June (breeding season). In addition, we attempted to induce ovulation by administering a gonadotropin releasing hormone (GnRH) agonist. We observed follicular development in April in four bears, but follicles did not develop to greater than 6.0 mm in diameter until May. Thereafter, a group of follicles developed to more than 6.0 mm and grew as dominant follicles, except in one bear. After ovulation and subsequent corpus luteum (CL) formation, the follicular waves disappeared. Furthermore, in three bears treated with GnRH, follicles between 8.2 to 11.2 mm in diameter at the time of treatment ovulated and formed CLs. In two bears, follicles between 5.8 to 8.8 mm ovulated spontaneously within the observation interval. Our results suggest that brown bears may be monoestrus animals. Therefore, AI can only be performed once during the breeding season. Our results also suggest that dominant follicles larger than 8.0 mm are a suitable size for inducing ovulation.

**Key words:** Brown bear, Estrus type, Follicular dynamics, Ovulation induction, Ultrasonography

(J. Reprod. Dev. 66: 563–570, 2020)

Six out of eight bear species are classified as endangered on the IUCN Red List [1]. Brown bears (*Ursus arctos*) are categorized as least concern; however, there are concerns about the extinction of some subpopulations due to their small size [2]. The development of assisted reproductive technology is necessary to promote breeding, and semen preservation for future artificial insemination (AI) has been well documented in brown bears [3–5]. Development of an AI protocol relies on a thorough understanding of female reproductive physiology, especially the follicular development and size of mature follicles for optimal timing of AI.

Brown bears are seasonal breeders with the breeding season from late spring to early summer [6]. They have a polygamous mating system and are assumed to be polyestrus [7, 8]. They are also assumed to be induced ovulators [8], although spontaneous ovulations have been confirmed under the captive condition [9, 10]. Implantation usually occurs after six months of embryonic diapause, then pregnant females give birth during their denning period approximately 60 days

after implantation [11]. Several studies have investigated hormonal changes in brown bears. These have shown that fecal estradiol or urinary estrogen concentrations increase during or after mating [12, 13]. Additionally, serum progesterone (P<sub>4</sub>) is slightly elevated after mating; in captive females, this increase is greater in early winter [9, 11, 12]. Annual progesterone profiles are similar in both unmated and mated females [9]. However, no detailed information about ovarian activity is currently available.

Recently, we reported morphological changes in the ovaries of brown bears using transrectal ultrasonography to investigate follicular development during the breeding season. This study revealed that follicles developed in a wave-like manner [10]. The size of the largest follicles was less than 6.0 mm (minor wave) in the early period (May to mid-June), while one or two follicles were selected as dominant follicles and exceeded 6.0 mm (major wave) late in the breeding season (mid-June to July). Furthermore, we observed only one major wave in each animal between May and July [10].

The type of estrus (polyestrus or monoestrus) in bear species is not well understood. Previous studies have classified bears as monoestrus animals [6, 14]; however, the evidence for this is not clear. Based on behavioral observations of both captive and wild brown bears, they are assumed to be polyestrus animals [15]. In monoestrus animals, the major wave leading to ovulation occurs only once during the breeding season; thus, there is only one chance to perform AI. In polyestrus animals, there are multiple chances

Received: April 18, 2020

Accepted: September 7, 2020

Advanced Epub: October 12, 2020

©2020 by the Society for Reproduction and Development

Correspondence: Y Yanagawa (e-mail: yoji-y@vetmed.hokudai.ac.jp)

This is an open-access article distributed under the terms of the Creative Commons Attribution Non-Commercial No Derivatives (by-nc-nd) License. (CC-BY-NC-ND 4.0: <https://creativecommons.org/licenses/by-nc-nd/4.0/>)

to perform AI in the breeding season. Therefore, it is important to confirm estrus type when developing a breeding plan.

In addition to estrus type, ovulatory follicle size also needs to be determined for AI. Because it is generally assumed that brown bears are induced ovulators, hormonal treatment for ovulation induction is necessary in any AI protocol. At present, the size of mature follicles is undetermined in this species, although our previous study suggested that follicles in the range of 10.0 to 13.0 mm in diameter have the potential for ovulation [10]. For AI preparation, it is desirable to predict when follicles will reach their preovulatory size.

In the present study, to clarify the estrus type in brown bears, we observed follicular development between April and October, before the start and after the end of the breeding season. In the previous study, one bear already had a dominant follicle on the first day of observation in early May [10]; we therefore started observations in April, before the breeding season, in the present study. When a follicle was estimated to have reached 10.0 mm in diameter (the likely mature follicle size in brown bears based on our previous observations [10]), we administered a gonadotropin releasing hormone (GnRH) agonist to induce ovulation

## Materials and Methods

### Animals

Six female Hokkaido brown bears (Bears A to F) housed in the Noboribetsu Bear Park (42° N, 141° E, Noboribetsu, Hokkaido, Japan) were used for the study (Table 1). All animals were fed a diet consisting of vegetables and commercial bear feed (ZOO FOOD: bear; Nosan, Kanagawa, Japan). Water was provided *ad libitum*. All bears were apparently healthy throughout the study period with no abnormal hematological or biochemical values during examinations before and after the study period. All experimental procedures were approved by the Hokkaido University Animal Care and Use Committee (No. 18-0108).

### General anesthesia

For anesthesia, we administered xylazine HCl (0.8 to 1.2 mg/kg; Selactar; Bayer, Tokyo, Japan) and a 1:1 mixture of zolazepam HCl and tiletamine HCl (2.0 to 4.0 mg/kg; Zoletil 100; Virbac,

Carros, France) via intramuscular injection using blow darts. After examination, atipamezole HCl (at the same volume as xylazine; Atipame; Kyoritsu, Tokyo, Japan) was injected and recovery from anesthesia was observed.

### Ultrasonography of the ovaries

Transrectal ultrasonography of the ovaries was performed under anesthesia [10]. A B-mode ultrasonography device (HS-2100V; Honda Electronics, Aichi, Japan) equipped with a linear transducer (5 to 10 MHz; HLV-475; Honda Electronics) was used for all examinations. The transducer was attached to a hand-made carrier (polyvinylchloride pipe, 49 cm long, 2.6 cm outside diameter) to observe the ovaries via the rectal wall. All visible antral follicles (> 1.5 mm) and corpora lutea (CLs) in both ovaries were counted, and the relative positions of follicles and CLs in the ovaries were recorded. The follicle and CL diameters were calculated by averaging the major and minor axes. During each observation, the ultrasonography was recorded using a video recorder (VR570; Toshiba Teli, Tokyo, Japan) to confirm follicle positions over time. Figure 1 shows example ultrasonography pictures from an ovary in Bear C.

### Blood collection

Following ultrasonography examinations, blood samples were collected via the medial saphenous vein into EDTA-loaded vacuum tubes. Blood samples were immediately centrifuged at 1,200 g for 15 min, and plasma was separated in plastic tubes and stored at -20°C until assayed.

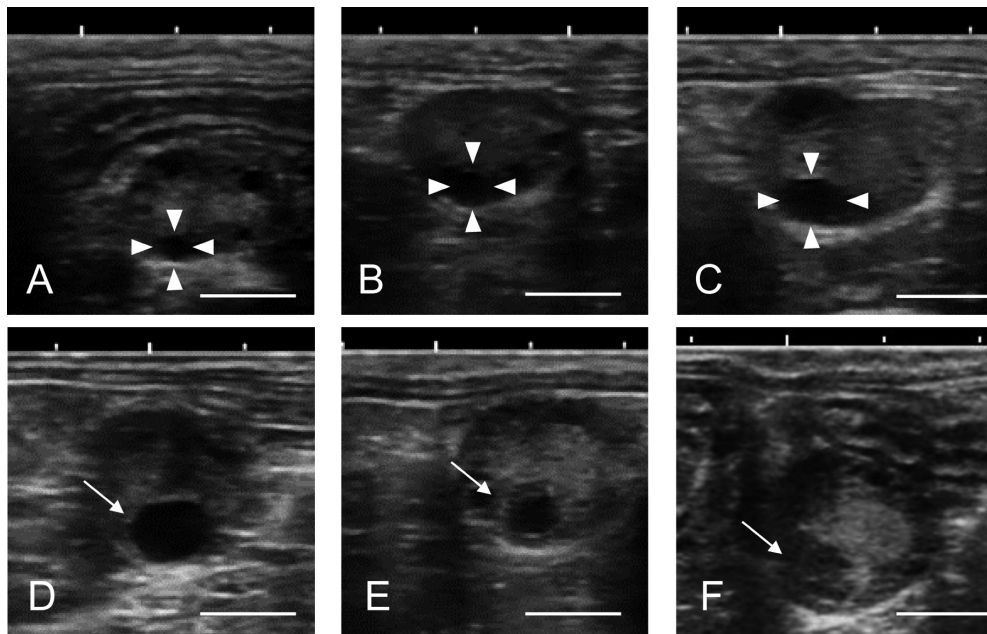
### Steroid hormone concentrations

Plasma estradiol-17 $\beta$  (E<sub>2</sub>) and P<sub>4</sub> concentrations were determined using competitive double-antibody enzyme immunoassays, as described in previous studies [10, 16]. The primary antibodies used for the E<sub>2</sub> and P<sub>4</sub> assays were anti-estradiol-17 $\beta$ -6-carboxymethylxime (CMO)-BSA (FKA204; Cosmo Bio, Tokyo, Japan) and anti-progesterone-3-CMO-BSA (KZ-HS-P13; Cosmo Bio), respectively. Goat anti-rabbit serum (111-005-003; Jackson ImmunoResearch Laboratories, West Grove, PA, USA) was used as the secondary antibody. The inter- and intra-assay coefficients of variation were 7.3 and 4.0% for E<sub>2</sub>, and 8.2 and 2.2% for P<sub>4</sub>, respectively.

**Table 1.** Bears used for observation of follicular dynamics and induction of ovulation

ID	Age (Year)	Parity	Estimated body weight (kg)	Ovarian observation	Type of ovulation	GnRH * dose ( $\mu$ g)	Follicle size before ovulation (mm)	Corpora lutea diameters at the first detection (mm)
				Period (number of observations)				
Bear A	20	0	130	Apr–Oct (17)	–	–	–	–
Bear B	17	2	180	Apr–Oct (13)	Spontaneous	–	7.6, 8.8, 8.8	6.3, 6.6, 6.1
Bear C	6	0	130	Apr–Oct (14)	Induced	40	8.2, 9.9	7.6, 8.4
Bear D	20	1	150	Apr–Oct (13)	Induced	40	9.1	14.3
Bear E	5	0	130	Jun (3)	Induced	20	11.2, 8.5	12.8, 8.7
Bear F	20	1	150	Jun (3)	Spontaneous	–	8.8, 6.6, 5.8	8.4, 8.5, 7.2
Bear 2	19	0	130	May–July (12)	Induced	20	14.0	–
Bear 3	5	0	130	May–July (9)	Induced	20	10.2	8.5

Bear A did not show any major waves during the observation period. Bears 2 and 3: data from the previous study [10]. \* GnRH (gonadotropin releasing hormone): Buserelin acetate.



**Fig. 1.** Images recorded from ultrasonography of an ovary in Bear C. Panels A to C show the same follicle (gradually increasing in size), which was identified and traced by its position in the ovary and location relative to other follicles (arrow head). These observations were done in May, the second and third observations were undertaken four and nine days, respectively, after the first. Panels D to F are images of the same follicle in Panels A to C. The dominant follicle (D) ovulated and a corpus luteum (CL) with cavity was identified in the same location (E; arrow). Later, a CL filled with luteal tissue was identified (F; arrow). Scale bar: 10 mm.

#### *Vaginal cytology and vulva score*

A plastic pipe (17.5 cm long, 1 cm in diameter) was inserted into the vagina, and a sterile cotton swab (4.8 mm in diameter) moistened with physiological saline was inserted through the tube until it stopped. Each cotton swab was gently rotated 360°, then removed and stamped on a glass slide. The slide was stained using a differential quick stain kit (Diff-Quick staining kit; Sysmex Ins., Kobe, Japan). Vaginal cells were classified according to the criteria for domestic dogs [17]. A minimum of 100 cells in at least four fields per slide were counted under a light microscope and classified as parabasal, intermediate, superficial, or anucleate cells. The cornification rate was calculated as the ratio of superficial to anucleate cells.

The vulval appearance (swelling and color) was evaluated by opening the vulva at the time of ultrasonography; longitudinal and transverse lengths were also measured. Vulval changes were scored using a ranking scale of 0–3 based on the vulva score for giant panda [18] and sun bear [19]. This was adapted here for brown bear: 0 = no swelling, pale color; 1 = slight swelling, pale color; 2 = increased swelling, moderate pink color; 3 = swelling, pink color.

#### *Experimental design*

Four bears (Bears A to D; 5 to 20 years old) were monitored for ovarian activity from April to October. Ultrasonography of the ovaries and blood collections were performed every other week in April, and every week from May until ovulation [10]. After confirming CL formation, observations were performed once a month until October. Two bears (Bears E and F; 5 and 20 years old), were used to obtain information on ovulatory follicle size. Their ovarian observations

started from June, when the major wave was expected to appear, until ovulation was confirmed by detecting CLs. Ovulation was induced in three out of six bears by administering 20 or 40 µg of busserelin acetate, a GnRH agonist (Estomal; Intervet, Ibaraki, Japan). The 20 µg GnRH dose is the maximal dose indicated for cattle. Anesthesia for ovulation induction was carried out on the day when the largest follicle was estimated to exceed 10.0 mm in diameter. This was calculated based on the follicular growth rate (0.25 mm/day) reported in our previous study [10]. The terms related to ovarian dynamics are based on this previous study and are defined in Table 2.

#### *Data analysis*

Results are expressed as mean ± SD. Ovulated follicle diameters at the last observation before ovulation were compared between ovulation type (spontaneous and induced) using the Student's *t*-test, as was the CL diameter on the first day we could detect it by ultrasonography. The follicular growth rate was estimated according to a previous study [10]. In brief, the day on which the largest follicle of each follicular wave showed the maximum size was centralized as Day 0, and the previous diameter data for the same follicle were placed before Day 0 on a scatter diagram. To show estimates were reasonable, follicular growth data from the previous study [10] were included in the present analysis. Growth rates of the minor wave and major wave were compared by multiple regression analysis. The study period was divided into three periods: minor wave, major wave, and post-ovulation. The minor wave period was from the beginning of observation to the day prior to when the major wave was first detected. The major wave period began from the day of its first detection to

**Table 2.** Definition of the terms related to ovarian dynamics

Term	Definition
Dominant follicle	Follicle(s) developed more than 6 mm in diameter
Ovulation	Disappearance of the dominant follicle(s) observed in previous examination or dominant follicle filled with fibrins which confirmed by subsequent CL formation
Minor wave	Growth of a group of follicles with none of them becoming dominant follicles
Major wave	Growth of a group of follicles with some of them becoming dominant follicles with < 10 follicles in total follicle number

either the last day an ovulatory follicle was observed prior to CL detection or to the day GnRH treatment began. The post-ovulation period was from the day of CL detection to the end of the study period. Plasma  $E_2$  and  $P_4$  concentrations in the three periods were compared by Kruskal-Wallis one-way analysis of variance, with the Steel-Dwass test used as a post-hoc test.

All statistical analyses were performed using JMP software, version 14 (SAS Institute, Cary, NC, USA). Significant difference was determined at  $P < 0.05$ .

## Results

The changes to the bears' ovarian structures are shown in Fig. 2 (Bears A to D) and Fig. 3 (Bears E and F). Small follicles (range 2.7 to 5.4 mm) were observed in April. From May to June, several wave-like follicles developed; however, they were smaller than 6.0 mm and regressed. Thereafter, follicles developed to more than 6.0 mm and became dominant follicles. In all bears except for Bear A, a major wave was observed once during the breeding season. Bear A repeatedly showed minor waves and did not show dominant follicles throughout the study period. Therefore, Bear A was excluded from further analysis. The total follicle numbers were highest in May, and then decreased sharply at the beginning of the major waves.

The growth rate of the dominant follicles in the major waves (0.19 mm/day,  $n = 9$ ) was greater than that in the minor waves (0.13 mm/day,  $n = 13$ ). Including the results of the previous study [10], the growth rate was 0.13 mm/day in the minor waves ( $n = 21$ ) and 0.21 mm/day in the major waves ( $n = 15$ ; Fig. 4). After CL formation, a few small follicles (2.0 to 3.7 mm) were observed; however, dominant follicles did not appear throughout the study period.

Bears B and F showed spontaneous ovulation before GnRH treatment. However, we did not observe ovulatory signs by ultrasonography, such as dominant follicle disappearance or fibrin-filled follicles [20], in Bears C to E on the day of GnRH treatment; CLs were confirmed in subsequent observations. In Bear B, three out of four dominant follicles disappeared just before the CL was first confirmed. When the CL was first confirmed (June 20), we could only observe the right ovary due to a technical problem (Fig. 2, asterisk). In Bear D, the largest dominant follicle ovulated and formed a CL nine days after GnRH treatment, while an ipsilateral follicle (7.6 mm in diameter) regressed. On the other hand, a contralateral follicle (5.5 mm in diameter) grew to 11.7 mm after nine days of GnRH treatment and CL was confirmed four days later.

Dominant follicle diameter at the last observation before ovulation

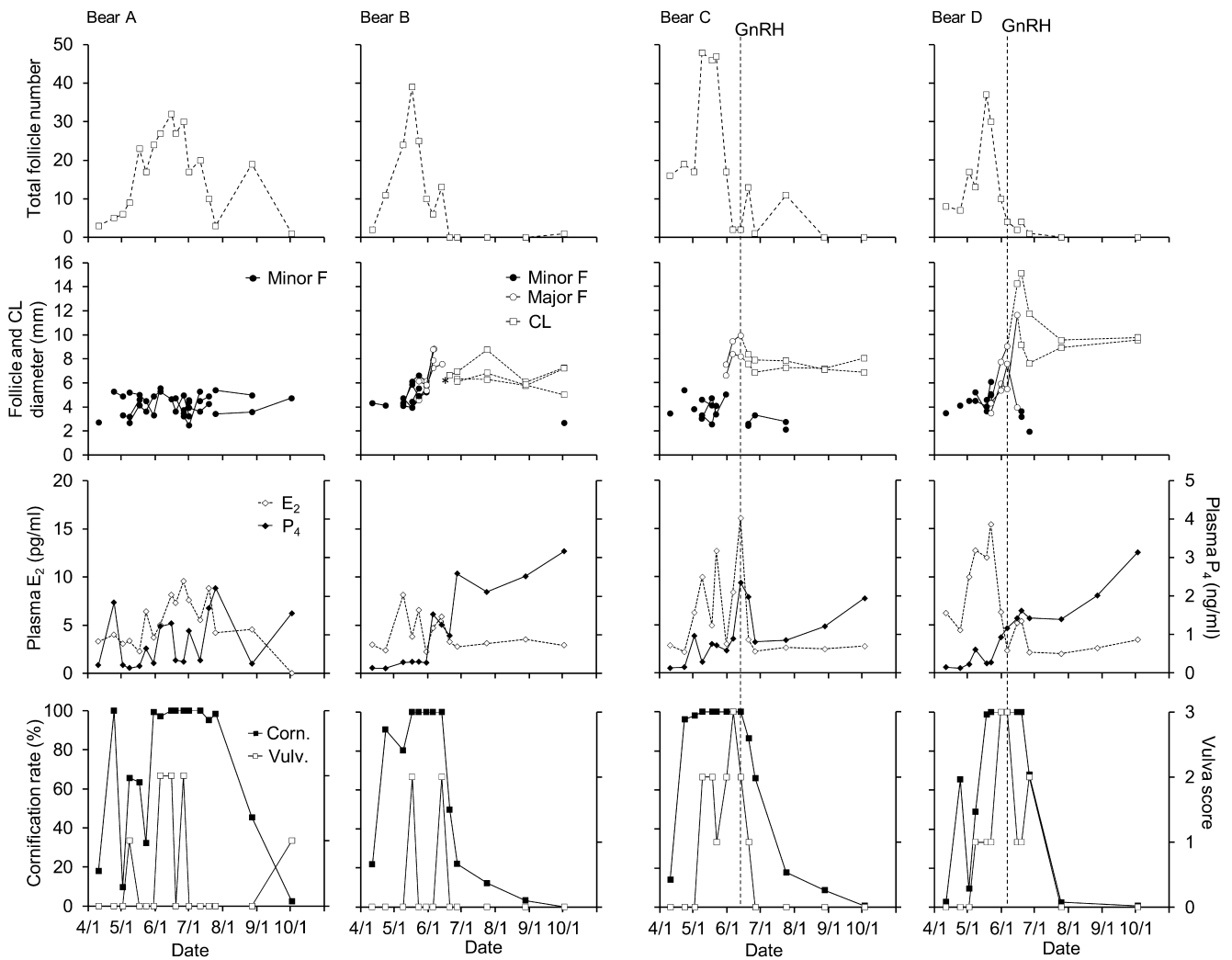
and CL diameter at the first detection by ultrasonography were  $9.4 \pm 1.1$  mm (range: 8.2 to 11.2 mm,  $n = 5$ ) and  $10.3 \pm 2.7$  mm (range: 7.6 to 14.3 mm), respectively, in treated bears (C, D, and E). In contrast, these diameters were  $7.7 \pm 1.2$  mm (range: 5.8 to 8.8 mm,  $n = 6$ ) and  $7.2 \pm 0.9$  mm (range: 6.1 to 8.5 mm), respectively, in spontaneously ovulating bears (B and F). There was no significant difference in the diameters of follicles and CLs between induced and spontaneous ovulation. In Bear D, there were central cavities in the CLs on the first day they were confirmed, and the size of CLs decreased gradually as the central cavities disappeared.

Hormonal changes in the bears are shown in Fig. 2 (Bears A to D) and Fig. 3 (Bears E and F). Additionally, plasma  $E_2$  and  $P_4$  concentrations relative to follicular development in each period are shown in Table 3. Except Bear A,  $E_2$  concentrations fluctuated in the presence of minor waves, and then showed an increase before spontaneous ovulation or on the day of ovulation induction (maximum value:  $11.4 \pm 3.8$  pg/ml; range: 7.0–16.1 pg/ml). After ovulation,  $E_2$  concentrations remained at the baseline levels. Plasma  $E_2$  concentration was higher during follicular development (minor and major wave periods) than post-ovulation ( $P < 0.05$ ). In Bear D,  $E_2$  concentration slightly increased when the CL was first detected after ovulation induction, which coincided with follicle development after GnRH treatment.  $P_4$  concentrations stayed at baseline levels during April, but fluctuated from May onwards, starting to increase before ovulation or on the day of ovulation induction in most cases. Plasma  $P_4$  was higher in the major wave periods than the minor wave periods, but it was the highest in post-ovulation periods (luteal phase,  $P < 0.05$ ). Concentration of  $P_4$  when the CL was first detected was  $1.6 \pm 0.4$  ng/ml (range: 1.0–2.0 ng/ml), increasing gradually from July to October in Bears B to D ( $2.7 \pm 0.6$  ng/ml; range: 2.9–3.5 ng/ml).

The cornification rate showed a similar change to the total follicle number. Although the changes in the cornification rate differed between individuals, it was less than 25% at the beginning of April but increased to more than 75% during follicular development. After CLs formation, the cornification rate dropped to less than 20%. The changes to the vulva score were relatively high from May to June.

## Discussion

The present study showed that brown bears in the present study showed one major follicular wave from which several follicles were selected. Furthermore, one to three follicles could ovulate during the breeding season. This suggests that brown bears are monoestrous animals.



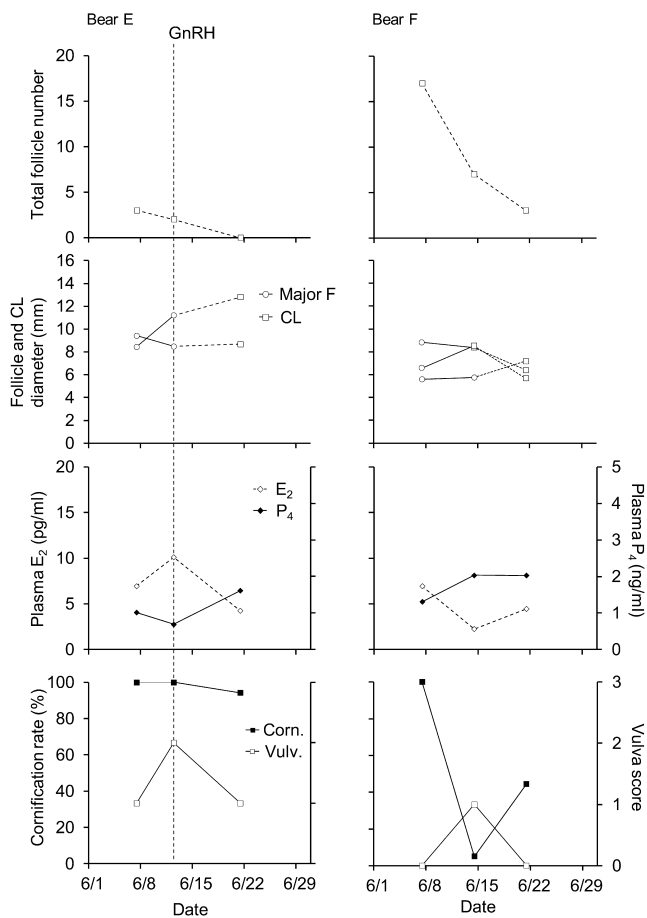
**Fig. 2.** The follicle growth profiles of Bears A to D (those observed from April to October), along with changes in plasma steroid hormones, vaginal cytology, and vulva score. The top panels show the total follicle number in each animal. Follicles and corpora lutea (CLs) diameters that could be traced by ultrasonography are shown in the second row of panels. Minor wave follicles (Minor F) and major wave follicles (Major F) are follicles that developed to less than 6.0 mm in diameter and those that developed to greater than 6.0 mm, respectively. The changes in plasma estradiol-17 $\beta$  ( $E_2$ ) and progesterone ( $P_4$ ) are shown in the third row of panels. The bottom panels show the cornification rate (Corn.) and the vulva score (Vulv.). Bears C and D were administered gonadotropin releasing hormone (GnRH) to induce ovulation. The broken lines indicate the date of GnRH administration. The asterisk for Bear B indicates unilateral (right side) observation of the ovary due to a technical problem.

A few studies have suggested that brown bears are polyestrous animals because of multiple distinct estrous observations and multiple paternities [7, 21]. In captive observations, Some females mate continuously for more than two weeks and the others mate for up to 20 days with 3–20 days interval [15]. Also, during another field observation, males and females remained together for two weeks to allow them a chance to breed [7, 22]. Using GPS location data during the mating season, Stenhouse *et al.* [23] reported that the duration of associations between males and females in the wild ranged from 4 to 468 h. Although they suggested that more than one estrus may have occurred because of this long duration, the mean duration of associations was 59.9 h and 72% of associations were less than 72 h. It is unlikely that brown bears show multiple estrus in such a short

period. Instead, these previous results seem to indicate that brown bears have a long and variable estrus period.

Our results show that it takes about two weeks for follicles to develop to the preovulatory size in the major wave. Considering the field observations, we suggest that females may show receptivity to males when a major wave commences. This is because follicles of 6.0 mm in diameter have aromatase cytochrome P450 activity and sexual receptivity may be related to  $E_2$  synthesis [24]. Therefore, the long and variable period of receptivity to males may correspond to the follicular phase.

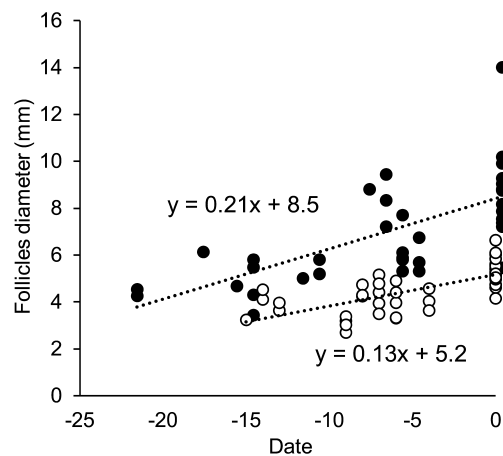
There is further evidence in the literature suggesting that brown bears have multiple estrus. In ursids, inactivation of CLs (low  $P_4$  production) following ovulation is related to delayed implantation



**Fig. 3.** The follicle growth profiles of Bears E and F (those observed in June), along with changes in plasma steroid hormones, vaginal cytology, and vulva score. The top panels show the total follicle number in each animal. Follicles and corpora lutea (CL) diameters that could be traced by ultrasonography are shown in the second row of panels. Major wave follicles (Major F) are those that developed to greater than 6.0 mm in diameter. The changes in plasma estradiol-17 $\beta$  (E<sub>2</sub>) and progesterone (P<sub>4</sub>) are shown in the third row of panels. The bottom panels show the cornification rate (Corn.) and the vulva score (Vulv.). Bear E was administered gonadotropin releasing hormone (GnRH) to induce ovulation. The broken lines indicate the date of GnRH administration.

or embryonic dormancy. It has been suggested that low progesterin during a delayed implantation period may allow females to re-enter estrus [6]. However, the present study indicates that the major wave appears only once during the breeding season, with no other major wave occurring after CL formation and subsequent to ovulation. Therefore, it is considered unlikely that brown bears experience multiple estrus via this mechanism.

The mating system of the brown bear is generally classified as polygamous [8]. One to three cubs are born per litter and multiple paternity in litters has been documented by genetic studies in wild bears [7, 21]. The present study confirmed that two to three follicles ovulate spontaneously within four to seven days after GnRH treatment. In brown bears, estrous females could copulate with a number of



**Fig. 4.** Scatter diagram and linear relationship for follicular diameter in the minor waves (open circles,  $n = 21$ ) and major waves (closed circles,  $n = 15$ ). Data from previous observations ( $n = 3$ ) [10] were combined with those obtained in the present study. The day on which each follicle had the largest diameter was defined as Day 0.

**Table 3.** Comparison of plasma estradiol-17 $\beta$  (E<sub>2</sub>) and progesterone (P<sub>4</sub>) concentrations in three ovarian activity periods

Period	E <sub>2</sub> (pg/ml)	P <sub>4</sub> (ng/ml)
Minor wave	6.8 $\pm$ 3.9 <sup>a</sup> (2.2–12.8)	0.3 $\pm$ 0.3 <sup>c</sup> (0.1–1.0)
Major wave	7.3 $\pm$ 4.4 <sup>a</sup> (2.2–16.1)	1.0 $\pm$ 0.6 <sup>b</sup> (0.3–2.3)
Post-ovulation	3.2 $\pm$ 1.0 <sup>b</sup> (2.0–5.4)	1.8 $\pm$ 0.7 <sup>a</sup> (0.8–3.2)

Values are presented as mean  $\pm$  SD (range). <sup>a, b, c</sup> The values with different superscript differ significantly within a column ( $P < 0.05$ ). The values include data from Bears B to F.

different males until ovulation. In canines, spermatozoa may remain motile while they are stored in the utero-tubal junction and the uterine glands [25]. These numbers noticeably diminished six days after copulation, but motile spermatozoa were found as long as 11 days after copulation [26]. Dogs are monoestrous animals that ovulate spontaneously, but multiple paternity has also been reported in wild dogs [27, 28]. The duration of spermatozoa survival in the female reproductive tract in bears is unknown. Assuming multi-ovulation following a single luteinizing hormone (LH) surge, it is possible that the sperm derived from different males could survive for a certain period, allowing polygamous mating. In Bear B, ovulations were observed over two successive observations within eight days. This ovulation gap may also contribute to multiple paternity.

Bears B and F, kept in a female group without male contact, showed spontaneous ovulation. In brown bears, spontaneous ovulation has previously been reported in captivity [8]. Okano *et al.* [29] showed that female Asian black bears with no male contact did not form CLs, while females with male contact via a fence did form CLs. Domestic cats and some nondomestic felids classified as induced ovulators have also been reported to show spontaneous ovulation in captivity due to female social interaction or the presences of males (domestic cats [30, 31], lions [32], cheetah [33], and clouded leopard [34]).

Given this evidence, the phenomenon of spontaneous ovulation may be easily induced in captivity.

From our results of spontaneous and induced ovulation, follicles with a size between approximately 6.0 to 11.0 mm have the potential to ovulate if a LH surge occurs. In Bear F, a follicle approximately 6.0 mm in size ovulated spontaneously, followed by two 8.8 and 6.6 mm follicles at the next observation seven days later. A follicle about 6.0 mm is possibly responds to the LH surge from dominant follicles, thus 6.0 mm follicles may have acquired LH receptors. However, a 6.0 mm follicle may not induce an LH surge by itself. Additionally, plasma  $P_4$  production increased within nine days prior to ovulation, with the largest follicle size being 8.8–9.9 mm in Bears B to D. An increase in  $P_4$  prior to ovulation is a common phenomenon in animals with a long estrous period, a gradual LH increase, and extended LH surge. In dogs [35], horses [36], and pigs [37], LH concentrations gradually increase over a few to several days and blood  $P_4$  concentrations start to increase after initiation of the LH surge, well in advance of ovulation. In addition,  $P_4$  concentration is an established indicator for determining AI timing in dogs. Generally, it reflects an increase in secretion of LH, the indicator for follicular maturation in animals. Therefore, follicles approximately 6.0 mm in size may be immature. Several reports have revealed hormonal changes without ovarian activity during the breeding season in giant pandas [38], sun bears [39], polar bears [40], and brown bears [12]. However, Kang *et al.* [41], monitored ovaries by ultrasonography in Asian black bears and showed a plasma progesterone increase before ovulation when the follicle size was between 7.0 to 8.8 mm.

The present study performed weekly ovarian observations because follicular growth occurs in three to ten day intervals at a rate of 0.25 mm/day (1.75 mm/week) [10]. Although we focused on the size of largest follicle in the present study, it may be necessary to consider the size of subordinate follicles, since two or three follicles typically ovulate in brown bears. In Bear D, GnRH induced ovulation of the largest follicle, while simultaneously stimulating the development of a 5.5 mm follicle and resulting in ovulation within a week. This ovulation gap occurred due to the exogenous hormonal treatment. Monitoring follicle development in the major wave needs to be undertaken more frequently to confirm the timing of ovulation induction.

Our results suggest that 20  $\mu$ g of GnRH may be sufficient to induce ovulation in brown bears. In the present study, all three bears ovulated successfully when either 20 or 40  $\mu$ g of GnRH was administered. In addition, a 10 mm follicle was induced to ovulate by 20  $\mu$ g of GnRH in the previous study [10]. There was no significant difference in follicle diameters prior to ovulation or CLs at first detection between induced and spontaneous ovulation. Furthermore,  $P_4$  concentrations increased in a similar manner after both induced and spontaneous ovulation.

The vulva score and cornification rate in vaginal cytology have been used as indicators of estrus in giant pandas and sun bears [18, 19]. In the present study, cornification rate was high from early May; it then dropped to the baseline rate when dominant follicles disappeared. Vulva score showed similar changes. In general, the cornification rate and vulva score reflect  $E_2$  concentrations. Our results show a relationship between these indicators and  $E_2$  concentrations similar to that described in previous reports. These features may be used

as indicators of the follicular phase but may be not precise enough to determine the timing of AI.

In conclusion, brown bears may be seasonal monoestrous animals, and follicles greater than 8.0 mm in size are suitable for ovulation induction by hormonal treatment. There appears to be only one opportunity to perform AI in their breeding season. More accurate growth rates and prediction methods for major follicular waves need to be determined in a future study to confirm the optimal timing of AI.

## Acknowledgements

This work was supported by JSPS KAKENHI (Grant Number JP19K06415 to YY). The authors thank the staff of the Noboribetsu Bear Park for animal care and data collection. Additional thanks go to Prof Motozumi Matsui (Obihiro University of Agriculture and Veterinary Medicine) and Prof Toshio Tsubota (Hokkaido University) for advice and suggestions regarding this study.

## References

1. IUCN. 2019. The IUCN Red List of Threatened Species. Version 2019-2. <http://www.iucnredlist.org>. Downloaded on 18 July 2019.
2. McLellan BN, Proctor MF, Huber D, Michel S. Ursus arctos (amended version of 2017 assessment). *The IUCN Red List of Threatened Species* 2017: e.T41688A121229971. [CrossRef]
3. Anel L, Álvarez M, Martínez-Pastor F, Gomes S, Nicolás M, Mata M, Martínez AF, Borragán S, Anel E, de Paz P. Sperm cryopreservation in brown bear (*Ursus arctos*): preliminary aspects. *Reprod Domest Anim* 2008; 43(Suppl 4): 9–17. [Medline] [CrossRef]
4. Anel L, Gomes-Alves S, Alvarez M, Borragan S, Anel E, Nicolas M, Martinez-Pastor F, de Paz P. Effect of basic factors of extender composition on post-thawing quality of brown bear electroejaculated spermatozoa. *Theriogenology* 2010; 74: 643–651. [Medline] [CrossRef]
5. Ishikawa A, Matsui M, Sakamoto H, Katagiri S, Takahashi Y. Cryopreservation of the semen collected by electroejaculation from the Hokkaido brown bear (*Ursus arctos yesoensis*). *J Vet Med Sci* 2002; 64: 373–376. [Medline] [CrossRef]
6. Spady TJ, Lindburg DG, Durrant BS. Evolution of reproductive seasonality in bears. *Mammal Rev* 2007; 37: 21–53. [CrossRef]
7. Craighead L, Paetkau D, Reynolds HV, Vyse ER, Strobeck C. Microsatellite analysis of paternity and reproduction in Arctic grizzly bears. *J Hered* 1995; 86: 255–261. [Medline] [CrossRef]
8. Steyaert SMJG, Endrestol A, Hackländer K, Swenson JE, Zedrosser A. The mating system of the brown bear *Ursus arctos*. *Mammal Rev* 2012; 42: 12–34. [CrossRef]
9. Tsubota T, Kanagawa H, Yamamoto K, Mano T, Yamanaka M, Kita I, Tiba T. Serum progesterone concentrations using P-EIA kit in captive and free-ranging Hokkaido brown bears (*Ursus arctos yesoensis*). *J Vet Med Sci* 1992; 54: 1–5. [Medline] [CrossRef]
10. Torii Y, Matsumoto N, Sakamoto H, Nagano M, Katagiri S, Yanagawa Y. Monitoring follicular dynamics using ultrasonography in captive brown bears (*Ursus arctos*) during the breeding season. *Theriogenology* 2019; 140: 164–170. [Medline] [CrossRef]
11. Tsubota T, Takahashi Y, Kanagawa H. Changes in serum progesterone levels and growth of fetuses in Hokkaido brown bears. *Int Conf Bear Res Manag* 1987:355–358.
12. Ishikawa A, Sakamoto H, Katagiri S, Takahashi Y. Changes in sexual behavior and fecal steroid hormone concentrations during the breeding season in female Hokkaido brown bears (*Ursus arctos yesoensis*) under captive condition. *J Vet Med Sci* 2003; 65: 99–102. [Medline] [CrossRef]
13. Dehnhard M, Hildebrandt TB, Knauf T, Jewgenow K, Kolter L, Göritz F. Comparative endocrine investigations in three bear species based on urinary steroid metabolites and volatiles. *Theriogenology* 2006; 66: 1755–1761. [Medline] [CrossRef]
14. Durrant BS. Reproduction in mammals: captive perspectives. In: Gibbons EF, Durrant BS, Demarest J (eds.), *Conservation of endangered species in captivity: an interdisciplinary approach*, State University of New York Press; 1995, 331–354.
15. Tsubota T, Kanagawa H, Takahashi K, Yasue K, Fukunaga S. Observation of sexual behavior under captive conditions in Hokkaido brown bears (*Ursus arctos yesoensis*). *Jpn J Anim Reprod* 1985; 31: 203–210. (in Japanese with English summary). [CrossRef]
16. Yanagawa Y, Matsuura Y, Suzuki M, Saga S, Okuyama H, Fukui D, Bando G, Nagano M, Katagiri S, Takahashi Y, Tsubota T. Accessory corpora lutea formation in pregnant Hokkaido sika deer (*Cervus nippon yesoensis*) investigated by examination of

- ovarian dynamics and steroid hormone concentrations. *J Reprod Dev* 2015; **61**: 61–66. [Medline] [CrossRef]
17. Johnston SD, Roof Kustritz MV, Olson PNS. Canine and feline theriogenology. 1st ed. New York: Saunders; 2001. Chapter 3. p. 32–40.
  18. Durrant BS, Olson A, Amodeo D, Anderson A, Russ KD, Campos-morales R, Gual-Still F, Garza JR. Vaginal cytology and vulvar swelling as indicators of impending estrus and ovulation in the Giant Panda (*Ailuropoda melanoleuca*). *Zoo Biol* 2003; **22**: 313–321. [CrossRef]
  19. Frederick C, Kyes R, Hunt K, Collins D, Durrant B, Wasser SK. Methods of estrus detection and correlates of the reproductive cycle in the sun bear (*Helarctos malayanus*). *Theriogenology* 2010; **74**: 1121–1135. [Medline] [CrossRef]
  20. Pierson RA, Ginther OJ. Ultrasonic imaging of the ovaries and uterus in cattle. *Theriogenology* 1988; **29**: 21–37. [CrossRef]
  21. Shimozuru M, Shirane Y, Tsuruga H, Yamanaka M, Nakanishi M, Ishinazaka T, Kasai S, Nose T, Masuda Y, Fujimoto Y, Mano T, Tsubota T. Incidence of multiple paternity and inbreeding in high-density brown bear populations on the Shiretoko Peninsula, Hokkaido, Japan. *J Hered* 2019; **110**: 321–331. [Medline] [CrossRef]
  22. Herrero S, Hamer D. Courtship and copulation of a pair of Grizzly bears, with comments on reproductive plasticity and strategy. *J Mammal* 1977; **58**: 441–444. [CrossRef]
  23. Stenhouse G, Boulanger J, Lee J, Graham K, Duval J, Cranston J. Grizzly bear associations along the eastern slopes of Alberta. *Ursus* 2005; **16**: 31–40. [CrossRef]
  24. Araki H, Tsubota T, Maeda N, Harada N, Kominami S, Mason JI, Kita I. Intraovarian immunolocalization of steroidogenic enzymes in a Hokkaido brown bear, *Ursus arctos yesoensis* during the mating season. *J Vet Med Sci* 1996; **58**: 787–790. [Medline] [CrossRef]
  25. England GCW, Burgess CM, Freeman SL, Smith SC, Pacey AA. Relationship between the fertile period and sperm transport in the bitch. *Theriogenology* 2006; **66**: 1410–1418. [Medline] [CrossRef]
  26. Doak RL, Hall A, Dale HE. Longevity of spermatozoa in the reproductive tract of the bitch. *J Reprod Fertil* 1967; **13**: 51–58. [Medline] [CrossRef]
  27. Girman DJ, Mills MGL, Geffen E, Wayne RK. A molecular genetic analysis of social structure, dispersal, and interpack relationships of the African wild dog (*Lycan pictus*). *Behav Ecol Sociobiol* 1997; **40**: 187–198. [CrossRef]
  28. Gottelli D, Sillero-Zubiri C, Applebaum GD, Roy MS, Girman DJ, Garcia-Moreno J, Ostrander EA, Wayne RK. Molecular genetics of the most endangered canid: the Ethiopian wolf *Canis simensis*. *Mol Ecol* 1994; **3**: 301–312. [Medline] [CrossRef]
  29. Okano T, Nakamura S, Nakashita R, Komatsu T, Murase T, Asano M, Tsubota T. Incidence of ovulation without coital stimuli in captive Japanese black bears (*Ursus thibetanus japonicus*) based on serum progesterone profiles. *J Vet Med Sci* 2006; **68**: 1133–1137. [Medline] [CrossRef]
  30. Lawler DF, Johnston SD, Hegstad RL, Keltner DG, Owens SF. Ovulation without cervical stimulation in domestic cats. *J Reprod Fertil Suppl* 1993; **47**: 57–61. [Medline]
  31. Gudermuth DF, Newton L, Daels P, Concannon P. Incidence of spontaneous ovulation in young, group-housed cats based on serum and faecal concentrations of progesterone. *J Reprod Fertil Suppl* 1997; **51**: 177–184. [Medline]
  32. Schramm RD, Briggs MB, Reeves JJ. Spontaneous and induced ovulation in the lion (*Panthera leo*). *Zoo Biol* 1994; **13**: 301–307. [CrossRef]
  33. Brown JL, Wildt DE, Wielebnowski N, Goodrowe KL, Graham LH, Wells S, Howard JG. Reproductive activity in captive female cheetahs (*Acinonyx jubatus*) assessed by faecal steroids. *J Reprod Fertil* 1996; **106**: 337–346. [Medline] [CrossRef]
  34. Brown JL, Wildt DE, Graham LH, Byers AP, Collins L, Barrett S, Howard JG. Natural versus chorionic gonadotropin-induced ovarian responses in the clouded leopard (*Neofelis nebulosa*) assessed by fecal steroid analysis. *Biol Reprod* 1995; **53**: 93–102. [Medline] [CrossRef]
  35. Concannon PW. Endocrinologic control of normal canine ovarian function. *Reprod Domest Anim* 2009; **44**(Suppl 2): 3–15. [Medline] [CrossRef]
  36. Sirois J, Kimmich TL, Fortune JE. Steroidogenesis by equine preovulatory follicles: relative roles of theca interna and granulosa cells. *Endocrinology* 1991; **128**: 1159–1166. [Medline] [CrossRef]
  37. Soede NM, Helmond FA, Kemp B. Periovarial profiles of oestradiol, LH and progesterone in relation to oestrus and embryo mortality in multiparous sows using transrectal ultrasonography to detect ovulation. *J Reprod Fertil* 1994; **101**: 633–641. [Medline] [CrossRef]
  38. Czekala N, McGeehan L, Steinman K, Xuebing L, Gual-Sil F. Endocrine monitoring and its application to the management of the giant panda. *Zoo Biol* 2003; **22**: 389–400. [CrossRef]
  39. Schwarzenberger F, Fredriksson G, Schaller K, Kolter L. Faecal steroid analysis for monitoring reproduction in the sun bear (*Helarctos malayanus*). *Theriogenology* 2004; **62**: 1677–1692. [Medline] [CrossRef]
  40. Stoops MA, MacKinnon KM, Roth TL. Longitudinal fecal hormone analysis for monitoring reproductive activity in the female polar bear (*Ursus maritimus*). *Theriogenology* 2012; **78**: 1977–1986. [Medline] [CrossRef]
  41. Kang HG, Jeong DH, Yang JJ, Lee BK, Kong JK, Lee JW, Kim IH. Serial transrectal ultrasonography for monitoring the reproductive activity of the Asiatic black bear (*Ursus thibetanus ussuricus*). *Reprod Domest Anim* 2015; **50**: 149–158. [Medline] [CrossRef]