



Since January 2020 Elsevier has created a COVID-19 resource centre with free information in English and Mandarin on the novel coronavirus COVID-19. The COVID-19 resource centre is hosted on Elsevier Connect, the company's public news and information website.

Elsevier hereby grants permission to make all its COVID-19-related research that is available on the COVID-19 resource centre - including this research content - immediately available in PubMed Central and other publicly funded repositories, such as the WHO COVID database with rights for unrestricted research re-use and analyses in any form or by any means with acknowledgement of the original source. These permissions are granted for free by Elsevier for as long as the COVID-19 resource centre remains active.



Using Lung Base Covid-19 Findings to Predict Future Disease Trends and New Variant Outbreaks: Study of First New York City (NYC) Outbreak

Paul Smereka, MD, Rebecca Anthopolos, DrPH, Larry A. Latson Jr, MD, Polly Kirsch, MS, Bari Dane, MD

Rationale and Objectives: Asymptomatic COVID-19 carriers and insufficient testing make containment of the virus difficult. The purpose of this study was to determine if unexpected lung base findings on abdominopelvic CTs concerning for COVID-19 infection could serve as a surrogate for the diagnosis of COVID-19 in the community.

Materials and Methods: A database search of abdominopelvic CT reports from March 1, 2020 to May 2, 2020 was performed for keywords suggesting COVID-19 infection by lung base findings. COVID-19 status, respiratory symptoms, laboratory parameters and patient outcomes (hospitalization, ICU admission and/or intubation, and death) were recorded. The trend in cases of unexpected concerning lung base findings on abdominopelvic CT at our institution was compared to the total number of confirmed new cases in NYC over the same time period.

Results: The trend in abnormal lung base findings on abdominopelvic CT at our institution correlated with the citywide number of confirmed new cases, including rise and subsequent fall in total cases. The trend was not mediated by COVID-19 testing status or number of tests performed. Patients with respiratory symptoms had significantly higher ferritin (median = 995ng/ml vs 500ng/ml, $p = 0.027$) and death rate (8/24, 33% vs 4/54, 9%, $p = 0.018$) compared to those without.

Conclusion: The rise and fall of unexpected lung base findings suggestive of COVID-19 infection on abdominopelvic CT in patients without COVID-19 symptoms correlated with the number of confirmed new cases throughout NYC from the same time period. A model using abdominopelvic CT lung base findings can serve as a surrogate for future COVID-19 outbreaks.

© 2021 The Association of University Radiologists. Published by Elsevier Inc. All rights reserved.

INTRODUCTION

Severe acute respiratory syndrome coronavirus 2 (SARS-CoV-2) is a strain of coronavirus causing the severe acute respiratory distress syndrome known as COVID-19 (1). As of August 2021, more than 36 million cases have been reported in the United States, and over 200 million cases worldwide (2,3). Though for a time the infection was thought to be under control due to use of multiple vaccines and preventive measures, the Delta Variant has raised concern for new outbreaks at a time when social restrictions have eased and less people are undergoing routine testing (4–8). Typical COVID-19 symptoms include fever,

cough, and shortness of breath, but numerous other symptoms and medical events have been attributed to the infection, including stroke, cardiac events, pulmonary embolism, bowel inflammation and digestive symptoms (1,9–13). Many infected people are asymptomatic or show atypical symptoms without respiratory manifestations, especially those having previously received the vaccine, which further complicates reliable diagnosis and disease containment (10,14–17). Given the myriad of symptoms associated with the viral infection, infections from new variants, delays in presentation, lower than desired vaccine administration and testing rates, and the number of asymptomatic carriers, the diagnosis, treatment, and prevention of disease remains a challenge (1,4,18–20).

The outbreak of COVID-19 in New York City (NYC) in March and April of 2020 was one of the first in the United States (3,21). The city experienced a rise and fall of cases much earlier than other major United States cities. As such, NYC offered a unique population for the study of disease spread and subsequent abatement. March 1st marked the first case of COVID-19 in New York State (22). On March 20, there were 7,102 total confirmed cases and 46 total deaths in

Acad Radiol 2021; 28:1645–1653

From the Department of Radiology (P.S., R.A., L.L., P.K., B.D.), NYU Langone Health, 660 1st Avenue, New York, NY 10016. Received August 31, 2021; revised September 17, 2021; accepted September 17, 2021. This study was approved by the NYU School of Medicine Institutional Review Board **Address correspondence to:** P.S. e-mail: paul.smereka@nyulangone.org

© 2021 The Association of University Radiologists. Published by Elsevier Inc. All rights reserved.
<https://doi.org/10.1016/j.acra.2021.09.023>

New York, with the majority found in NYC (3,21). The rate of infection continued to rise, reaching a peak during the week March 29, 2020 to April 4, 2020 (35,944 confirmed cases), after which the number of cases began to decline, displaying the effectiveness of safety measures and the willingness of New York residents to adhere to them (3).

As the virus spread and then dissipated, we learned the challenges of diagnosis, containment, and treatment. Evidence arose that COVID-19 asymptomatic carriers can transmit SARS-CoV-2, and its infectivity was shown to be similar to that of symptomatic patients (23,24). Given the relatively high proportion of asymptomatic cases, it became clear that asymptomatic patients could be playing a large role in the transmission of the virus, and thus posed a significant infection control challenge (25,26).

With these factors in mind, our study set out to evaluate the patients who presented to our institution without respiratory symptoms, but were found to have abnormal findings in their lung bases on abdominopelvic CT, and to compare the rate of these findings with patient COVID-19 PCR testing status. Therefore, the overall purpose of this study was to compare the frequency of abnormal lung base findings on abdominopelvic CT at our institution to the total number of confirmed new cases in NYC during the same time period.

MATERIALS AND METHODS

Patients

This retrospective, Health Insurance Portability and Accountability Act-compliant, Institutional Review Board-approved study used a departmental database to search for abdominopelvic CT reports which included the keywords “groundglass,” “atypical agents,” “pneumonia,” and/or “pneumonitis,” from the time period March 1, 2020 to May 2, 2020 (Fig 1), at our academic medical institution in NYC. The inclusion criteria was all outpatient and emergency

department patients older than 18 years of age undergoing abdominopelvic CT during the above dates. The initial database search identified 319 patients. Exclusion criteria included all inpatient CT scans ($n = 68$), patients without lung findings ($n = 27$, i.e., groundglass described in bone findings, or the phrase “no groundglass opacity” included in the report), reports describing a solitary groundglass opacity < 5 mm and reports describing a groundglass or solid “mass” in a patient with biopsy proven lung cancer ($n = 35$). This resulted in a final cohort of 189 patients (113 men and 76 women, mean [SD] age 61.2[17.0] years, range 23–99 years). The departmental database was also searched for all abdominopelvic CTs during the time period March 1, 2020 to May 2, 2020. These results were queried for positive and non-positive COVID-19 PCR tests in the electronic medical record (EMR), regardless of lung base findings.

For comparison, the departmental database was searched for abdominopelvic CTs during the same time period from one year prior (March 1, 2019 to May 2, 2019), and total abdominopelvic CT reports including “groundglass,” “atypical agents,” “pneumonia,” and pneumonitis” were recorded. Patient age, sex, and respiratory symptoms were recorded, as were the same laboratory parameters and additional information as the patients from 2020. The search resulted in 61 cases; 4 with respiratory symptoms and 57 without.

Electronic Medical Record (EMR) Review

A manual review of the EMR was performed for all included patients by an abdominal radiologist. Age, sex, location of scan (Emergency department versus outpatient) and laboratory values (PCR COVID-19 test results, Ferritin, D-dimer, Erythrocyte Sedimentation Rate [ESR], C-Reactive Protein [CRP]) were recorded, as well as patients’ initial presenting symptoms. Patients were separated into groups of having respiratory symptoms (i.e. cough, shortness of breath,

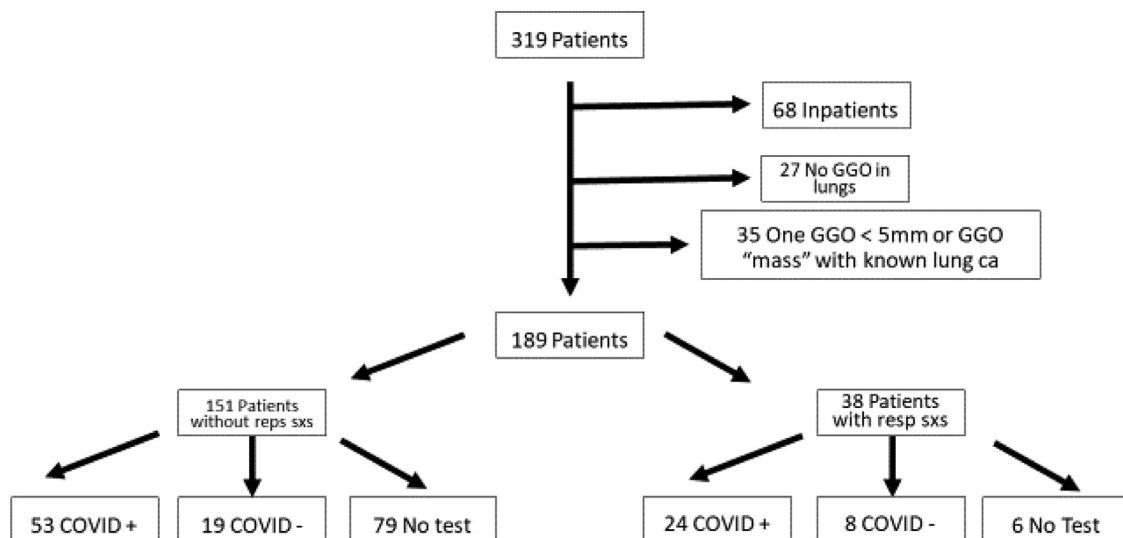


Figure 1. Patients with abnormal findings in lung bases on abdominopelvic CT, March 1, 2020 to May 2, 2020

dyspnea, wheezing, and chest pain/tightness, total 38) versus not having respiratory symptoms (151) on initial presentation. Groups were further divided by COVID-19 test PCR test results (Fig 1). For each of these groups, hospitalization, hospital stay length, intubation or admission to ICU, and death were recorded.

Imaging Review

A cardiothoracic radiologist with seven years post-fellowship experience blinded to initial imaging interpretation recorded whether the findings in the lung bases on abdominopelvic CT were suspicious for COVID-19 infection or not, based on recent clinical experience with chest CT findings of the virus. The chest radiologist described ground-glass opacities (GGO), consolidation, atelectasis, interlobular septal thickening, pleural effusions, tree-in-bud nodularity, and the lobar distribution (one lobe vs. multilobar). Our cardiothoracic radiologist provided an analysis of each case and rationale for characterization as “likely COVID-19 in the appropriate clinical setting”, “possible COVID-19 versus other etiologies,” or “not COVID-19” based on the constellation of imaging findings. The radiologist was blinded to COVID-19 laboratory results and patient respiratory symptoms for each study, as well as the date including year during which the study was performed.

Statistical Analysis

Characteristics of patients with COVID-19 positive laboratory test results were described by respiratory symptom status. Categorical and continuous variables were summarized with frequencies and percentages, median and interquartile range. Association of patient characteristics with respiratory symptoms status was determined using Chi-square (categorical variables) and Kruskal-Wallis tests (continuous variables). For categorical variables, Pearson’s chi-squared test was used. For two-by-two categorical comparisons involving expected cell counts less than five, Fisher’s exact test was used. A p -value less than 0.05 indicated statistical significance (27).

Rate of abnormal lung findings by COVID-19 testing status and date: A multivariable Poisson regression was used to model the rate of abnormal lung findings as a function of week, COVID-19 testing status, and their interaction from March 8, 2020 to May 2, 2020 (for the modeling that included COVID group status, the first week of March yielded no COVID positive results and was not included). COVID-19 testing status was used as a binary indicator (COVID 19-positive versus COVID-19 negative and/or unknown). The rate of abnormal lung base findings on abdominopelvic CT was graphed over time for COVID-19 positive and negative patients. A multivariable Poisson regression model of the count of abnormal lung findings as a function of week and year for 2020 versus 2019 was created. The expected rate of abnormal lung base findings on abdominopelvic CT was graphed over time, comparing March 8, 2020 to May 2, 2020 with March 8, 2019 to May 2, 2019.

Abnormal lung findings at our Institution versus new COVID-19 Positive Cases in NYC: Spearman’s Rank Order Correlation was used to measure the association between patients with abnormal lung base findings on abdominopelvic CT at our institution from March 8, 2020 to May 2, 2020 and the total number of documented cases in NYC during the same time period.

All analyses were performed in R Statistical Software (27).

This study was approved by our Institutional Review Board.

RESULTS

Patients

A total of 151 patients *without* respiratory symptoms were found to have lung base findings on abdominopelvic CT matching the search criteria on reports from March 1, 2020 to April 2, 2020. Fifty three (35.1 %) were found to be COVID-19 positive, 19 were COVID-19 negative (12.6%), and 79 (52.4%) had no recorded COVID-19 test. Thirty eight patients *with* respiratory symptoms matched the search criteria: 24 COVID-19 positive (63.2%), 8 COVID-19 negative (21.1%), and 6 (15.8%) with no COVID-19 laboratory test.

In the same time period from a year prior (March 1, 2019 to May 2, 2019), 61 patients had lung base findings which matched the search criteria: 57 (93.4%) without and 4 (6.6%) with respiratory symptoms

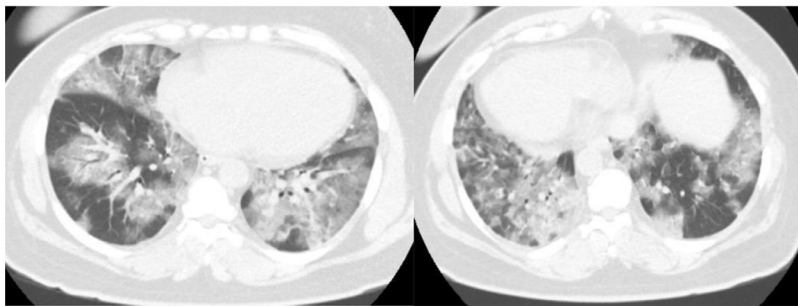
ESR, CRP, and D-dimer levels showed no significant difference between the two groups ($p = .21$ to 0.85) There was also no significant difference in the length of hospital stay or number of intubations and/or ICU admissions.

When comparing COVID-19 positive patients with and without respiratory symptoms, the respiratory symptom group showed a significantly higher ferritin level (995 vs 500ng/ml $p = 0.03$) and death rate (8/24 vs 5/53, $p = 0.02$). There was no significant difference between the groups for age, sex, hospitalizations, length of hospital stay, intubation and/or ICU stay, D-dimer, ESR, or CRP level ($p = 0.21$ to 0.85).

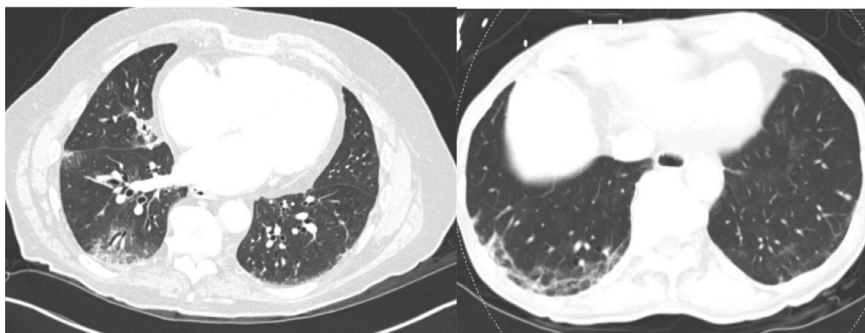
Chest Radiologist Imaging Assessment

Of the 189 included CTs from March 1, 2020 to May 2, 2020, 85 (45.0%) were interpreted as “multifocal GGO, COVID-19 likely in the appropriate setting” by expert chest radiologist review (Fig 2a). 70 (37.0%) were interpreted as “possible COVID-19 infection versus other etiologies”, which included descriptors “very mild GGOs,” “minimal GGO,” “moderate GGO,” and “GGO confined to one lobe” (Fig 2c). 34 (18.0%) cases with descriptors “atelectasis,” “motion,” “scarring,” “aspiration,” “tree-in-bud,” “effusions,” “edema,” “lymphangitic,” “bacterial pneumonia,” or some combination thereof were interpreted as “not COVID-19 infection” by chest radiologist review (Fig 2d).

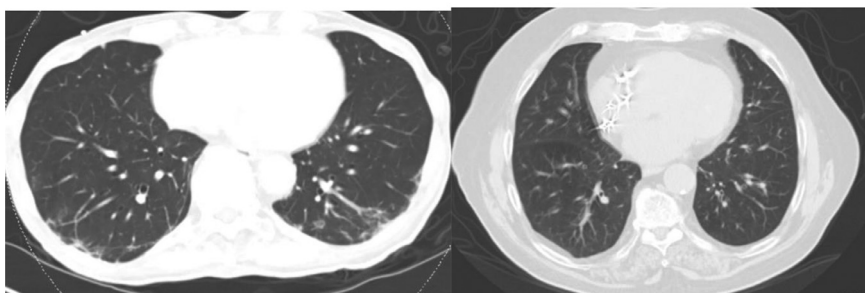
A



B



C



D

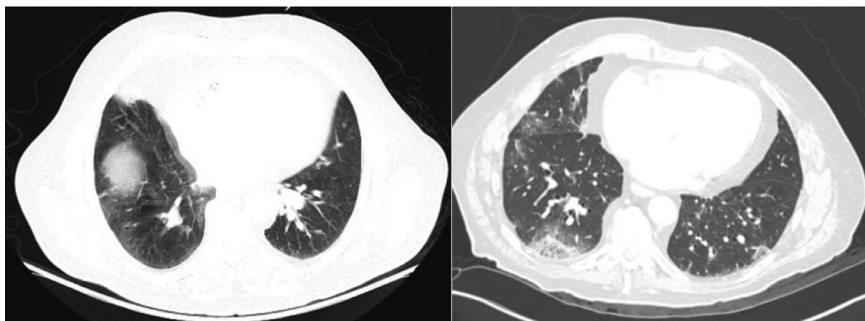


Figure 2a. A 45-year-old woman presenting to the emergency department with abdominal pain and cough. Abdominopelvic CT showed extensive bilateral ground-glass opacities. Chest radiologist confirmed these findings were consistent with COVID-19 infection. Subsequent COVID-19 PCR test was positive, and patient had elevated ferritin, D-dimer, ESR, and CRP. Figure 2b. A 82-year-old male man presenting to emergency department after fall in bathroom, with no respiratory symptoms. Abdominopelvic CT showed patchy peripheral multilobar lung base ground glass opacities. Chest radiologist confirmed these findings were consistent with COVID-19 infection. Subsequent COVID-19 PCR test was positive, and patient had elevated ferritin, D-dimer, ESR, and CRP. Figure 2c. A 80-year-old man presenting to the emergency department with abdominal distention and concern for small bowel obstruction. Abdominopelvic CT showed moderate patch groundglass and atelectasis. Chest radiologist confirmed these findings were possibly consistent COVID-19 infection. Subsequent COVID-19 PCR test was positive. Figure 2d. A 81-year-old-man presenting to the emergency department with cough and abdominal pain, history of right nephrectomy. Abdominopelvic CT showed trace pleural effusion and likely airways inflammation; chest radiologist assessed these findings as not consistent with COVID-19 infection. Subsequent COVID-19 PCR test was negative.

Of the 61 patients with abnormal lung base findings from the year prior (March 1, 2019 to May 2, 2019), 11 (18%) had findings “COVID likely in appropriate setting,” if the CT had been performed during the COVID-19 pandemic. 13 (21%) had “possible COVID versus other etiologies,” and 37 (60.6%) were interpreted as “not consistent with COVID-19”.

Using all patients with PCR COVID-19 tests (and including all 2019 patients as COVID-19 negative), and including interpretation of “Likely COVID” and “COVID possible” in the positive category, resultant sensitivity, specificity, and accuracy of abdominopelvic CT lung base findings was 92%, 59%, and 75%, respectively.

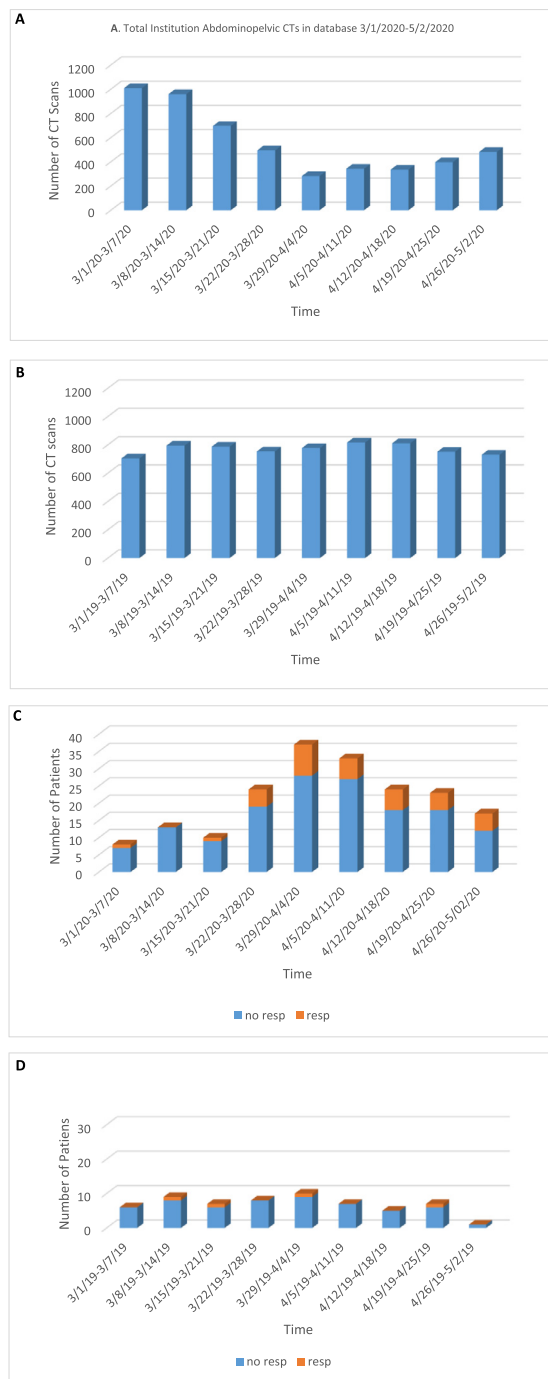


Figure 3. (a and b) Comparison of total abdominopelvic CTs performed at our institution during COVID-19 outbreak (a, March 1, 2020 to May 2, 2020) and the year prior (b, March 1, 2019 to May 2, 2019), showing decline in total CT during the outbreak. (c and d) Total patients with abnormal findings in the lung bases found on abdominopelvic CT over same time periods, increased during the COVID-19 outbreak despite decrease in total CTs performed. (Color version of figure is available online.)

Time Series

From March 1, 2020 to May 2, 2020, total abdominopelvic CTs performed at our institution declined sharply during the

COVID-19 outbreak, as compared to a similar time frame from the year before (March 1, 2019 to May 2, 2019), when they remained steady (Fig 3). Despite the decline in total CTs performed, the number of patients with abnormal lung base findings increased, and peaked in the week of March 29, 2020 (Fig 3). The trend in abnormal lung findings at our institution mirrored the rise in confirmed cases in NYC during the same time, with the same peak in cases during the week of March 29, 2020, and then subsequent decline (Fig 4).

Rate of Abnormal Lung Findings by COVID-19 Testing and Date

An increased rate of abnormal lung findings was seen in both patients with COVID-19 positive results and patients with COVID-19 negative result or no COVID-19 test (Fig 5). The rate of increase in abnormal findings was higher in COVID-19 positive patients. This trend was not mediated by COVID-19 positive laboratory test status. The trend was seen despite a sharp decrease in the number of total abdominopelvic CT scans performed at our institution. The trend in abnormal lung findings in 2020 during the COVID-19 outbreak was distinctive compared to a comparison of the same time period during 2019 (Fig 6).

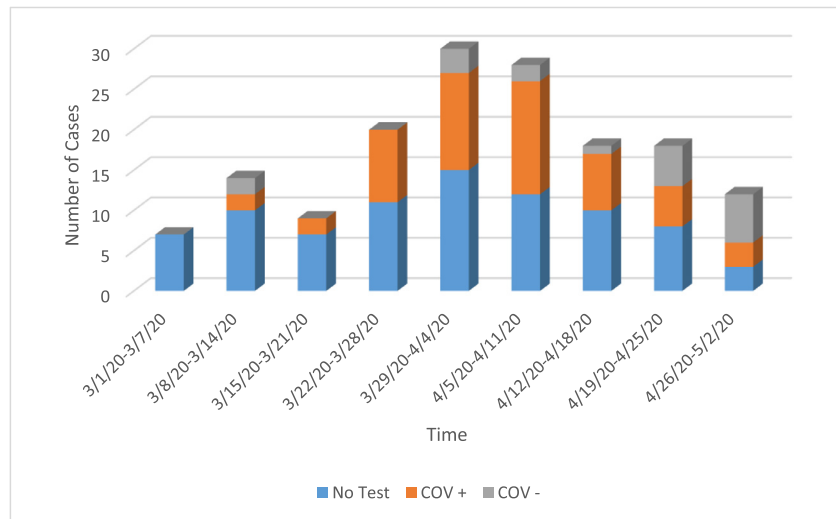
DISCUSSION

Our results show that abnormal lung base findings on abdominopelvic CT during the COVID-19 outbreak in NYC (March 1, 2020 to May 2, 2020) follow a similar trend to total confirmed new cases throughout NYC during the same time period. While these patients cannot be considered “asymptomatic” (as numerous abdominal findings have been attributed to the viral infection), they do represent a “respiratory asymptomatic” patient population (1,28). Consequently, the rise in suspicious lung base findings in “respiratory asymptomatic” patients could stand as a surrogate for COVID-19 community infection rates.

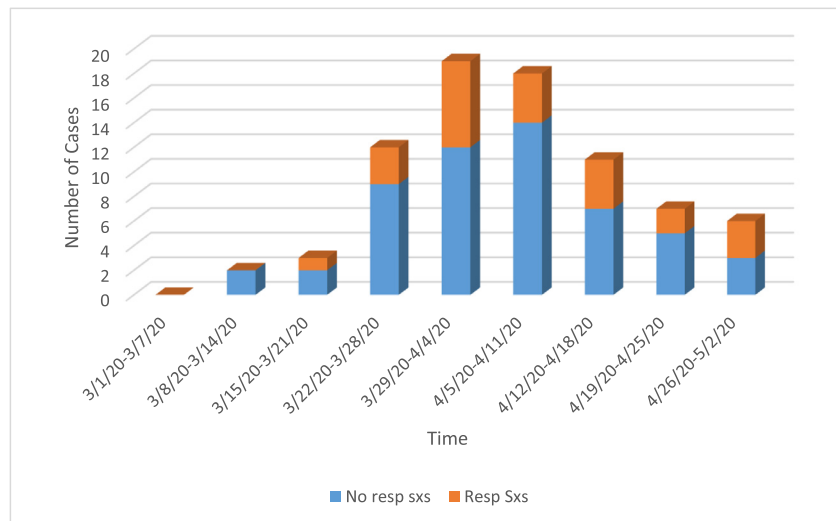
With the rise of new variants, breakthrough infection in vaccinated individuals, spread of COVID-19 infection among “asymptomatic” individuals, reduced COVID-19 testing and contact tracing (2,3,8,29), the ability to provide a surrogate marker of community viral load is essential. Therefore, the ability to model community infection load via unexpected imaging findings on abdominopelvic CT is useful.

The chest radiologist’s assessment confirmed that the original non chest radiologist-trained radiologist’s assessment of the lung bases was highly sensitive for COVID-19 or other atypical infection, and that this original assessment could be used to trend infection rates. High sensitivity is favorable in the evaluation for COVID-19. Our chest Radiologist’s criteria for identifying COVID-19 infection versus other infectious lung diseases agrees with recently published data differentiating the two groups (30). As specific criteria for COVID-19 lung findings become more established, machine-learning algorithms could potentially be used to monitor the rate of such findings in the population, as an early warning or surrogate measure of new or on-going outbreaks (31).

A



B



C

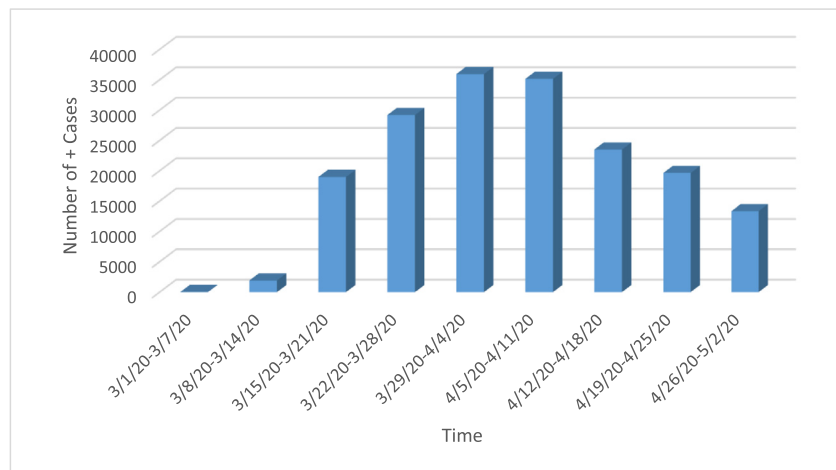


Figure 4. (a) Patients with abnormal findings in lung bases on abdominopelvic CT, 3/1/2020-5/2/2020, without respiratory symptoms; (b) Patients with abnormal findings in lung bases on abdominopelvic CT, March 1, 2020 to May 2, 2020, with and without respiratory symptoms, COVID + PCR; (c) Total confirmed COVID-19 cases in NYC, March 1, 2020 to May 2, 2020 (3). The trend in abnormal lung base findings at our institution correlate with the total confirmed cases in NYC during the same time period. (Color version of figure is available online.)

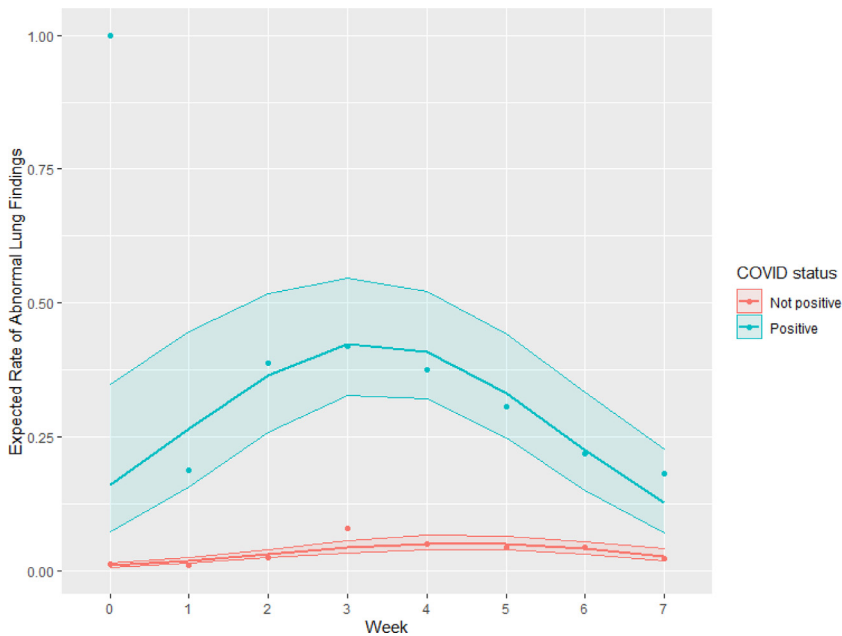


Figure 5. Expected rate of abnormal lung base findings on abdominopelvic CT over time, March 8, 2020 to May 2, 2020, for COVID-19 positive and negative or unknown patients. The rate of increase in abnormal findings was higher in COVID-19 positive patients. This trend was not mediated by COVID-19 positive laboratory test. (Color version of figure is available online.)

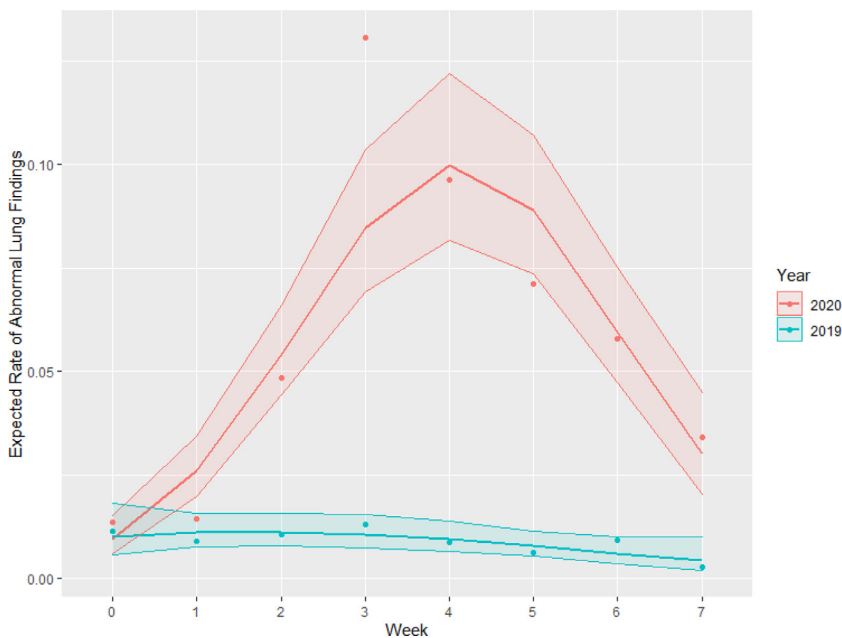


Figure 6. Expected rate of abnormal lung base findings on abdominopelvic CT over time, comparing March 8, 2020 to May 2, 2020 and March 8, 2019 to May 2, 2019, showing distinctive rise during COVID-19 outbreak. (Color version of figure is available online.)

In our study, among patients with positive COVID-19 PCR tests, patients with respiratory symptoms on presentation had significantly elevated ferritin level (995 vs 500ng/ml) and death rate (33% versus 9 %) compared to those without respiratory symptoms (Table 1). Ferritin has been associated with more severely ill patients in a number of diseases, including COVID-19, where it has been shown to be an independent risk factor for disease severity (32-35). While all inflammatory markers and a patient's clinical picture should be assessed when evaluating the severity of a patient's illness, our study suggests that ferritin may be a particularly important marker in predicting the development of respiratory symptoms and more severe cases.

This study had a number of limitations. First, a large number of the respiratory asymptomatic patients (79/151) were untested for COVID-19. Second, the COVID-19 PCR test, our reference standard, is not 100% accurate, with sensitivity ranging from 25% to 97% and specificity from 25% to 70%, based on meta-analysis of multi-test studies (36-39). Third, the NYC database for counting of confirmed COVID-19 cases does not include people with COVID-19 infection who did not access diagnostic testing, tested falsely negative, or became infected after testing negative (36). Finally, the increased rate of atypical lung base findings may also be spuriously elevated, as radiologists at the time were aware of the community COVID-19 infection rates.

TABLE 1. Patient Characteristics by Respiratory Symptoms Status Among Patients With a COVID-19 Positive Lab Test.

Respiratory Symptoms	No (N=53)	Yes (N=24)	p-value
Age [Median (Q1, Q3)]	67(55,78)	70 (54, 82)	0.58
Sex			0.53
Female	23 (43%)	13 (54%)	
Male	30 (57%)	11 (46%)	
Visit type			0.53
Emergency department	52 (98%)	23 (96%)	
Out-patient	1(2%)	1 (4%)	
Hospitalizations	46 (86.8%)	20 (83.3%)	0.73
Days In-Patient [Median (Q1, Q3)]	6(3,13)	13,7)	0.21
Intubation/ICUSSay	9(17%)	6(25%)	0.54
Death	5 (9%)	8 (33%)	0.0184
Ferritin (ng/ml)	n = 42	n = 22	0.0274
Median (Q1, Q3)	500 (260, 850)	995 (393, 1889)	
D-dimer (mg/ml)	n = 38	n = 21	0.29
Median (Q1, Q3)	424 (250, 908)	585 (318, 967)	
ESR (mm/1hr)	n = 27	n = 10	0.58
Median (Q1, Q3)	72 (46, 102)	76 (35, 88)	
CRP (mg/ml)	n = 41	n = 21	0.85
Median (Q1, Q3)	88 (26, 121)	87 (62, 129)	
Chest Radiologist Assessment (findings s/o COVID-19 in lung bases)	49 (92%)	22 (92%)	1

p-values were obtained using the Kruskal-Wallis test for continuous variables. For categorical variables, Pearson's chi-squared test was used. For 2 by 2 comparisons with an expected count less than 5, a Fisher exact test was used.

In conclusion, the rate of abnormal lung base findings on abdominopelvic CT at our institution in NYC was highly correlated with the citywide COVID-19 positive testing rate during the same time period, regardless of patient COVID-19 PCR test result. This suggests that the increasing incidence of abnormal lung base findings on abdominopelvic CT could be used as a surrogate for community COVID-19 infection rates. Future research with larger sample sizes could potentially help to produce a model in which concerning lung base findings on abdominopelvic CT are used to predict future outbreaks of COVID-19, new variant infection outbreaks, and effectiveness of containment and prevention measures.

REFERENCES

- Zhou F, Yu T, Du R, et al. Clinical course and risk factors for mortality of adult inpatients with COVID-19 in Wuhan, China: a retrospective cohort study. *Lancet* (London, England) 2020; 395:1054–1062.
- COVID-19 coronavirus pandemic. Worldometer Website. Available at: www.worldometers.info/coronavirus 2021
- NYC Health Database. Available at: <https://www1.nyc.gov/site/doh/covid/covid-19-data.page>
- Farinholt T, Doddapaneni H, Qin X, et al. Transmission event of SARS-CoV-2 Delta variant reveals multiple vaccine breakthrough infections. *Medrxiv: The Preprint Server for Health Sciences* 2021.
- Lopez Bernal J, Andrews N, Gower C, et al. Effectiveness of Covid-19 Vaccines against the B.1.617.2 (Delta) Variant. *N Engl J Med* 2021; 385 (7):585–594.
- Planas D, Veyer D, Baidaliuk A, et al. Reduced sensitivity of SARS-CoV-2 variant Delta to antibody neutralization. *Nature* 2021; 596:276–280.
- Wilder-Smith A, Freedman DO. Isolation, quarantine, social distancing and community containment: pivotal role for old-style public health measures in the novel coronavirus (2019-nCoV) outbreak. *J Travel Med* 2020; 27(2):1–4.
- Aleem A, Akbar Samad AB, Slenker AK. Emerging Variants of SARS-CoV-2 And Novel Therapeutics Against Coronavirus (COVID-19). *Stat-Pearls. Treasure IslandFL: StatPearls Publishing, 2021 Copyright © 2021, StatPearls Publishing LLC.*
- Avula A, Nalleballe K, Narula N, et al. COVID-19 presenting as stroke. *Brain Behav Immun* 2020; 87:115–119.
- Dane B, Brusca-Augello G, Kim D, et al. Unexpected Findings of Coronavirus Disease (COVID-19) at the Lung Bases on Abdominopelvic CT. *AJR Am J Roentgenol* 2020; 215:603–606.
- Driggin E, Madhavan MV, Bikdeli B, et al. Cardiovascular Considerations for Patients, Health Care Workers, and Health Systems During the Coronavirus Disease 2019 (COVID-19) Pandemic. *J Am Coll Cardiol* 2020; 75 (18):2352–2371.
- King MJ, Lewis S, El Homsy M, et al. Lung base CT findings in COVID-19 adult patients presenting with acute abdominal complaints: case series from a major New York City health system. *Eur Radiol* 2020; 30:6685–6693.
- Capaccione KM, Yang H, West E, et al. Pathophysiology and Imaging Findings of COVID-19 Infection: An Organ-system Based Review. *Acad Radiol* 2021; 28:595–607.
- Qiu C, Deng Z, Xiao Q, et al. Transmission and clinical characteristics of coronavirus disease 2019 in 104 outside-Wuhan patients, China. *J Med Virol* 2020; 92(10):2027–2035.
- Sendi AA, Saggat DF, Alzaharani SJ. Incidental typical COVID-19 appearance on the lung bases, visualized at abdominal CT for a patient that presented with abdominal pain and nausea. *Radiology Case Reports* 2020; 15:1238–1241.
- Cohen JI, Burbelo PD. Reinfection with SARS-CoV-2: Implications for Vaccines. *Clin Infect Dis* 2020; 20:1–6.
- Sharma R, Sardar S, Mohammad Arshad A, et al. A Patient with Asymptomatic SARS-CoV-2 Infection Who Presented 86 Days Later with COVID-19 Pneumonia Possibly Due to Reinfection with SARS-CoV-2. *The American Journal of Case Reports* 2020; 21:e927154.
- Chen N, Zhou M, Dong X, et al. Epidemiological and clinical characteristics of 99 cases of 2019 novel coronavirus pneumonia in Wuhan, China: a descriptive study. *Lancet* (London, England) 2020; 395:507–513.
- Xu G, Yang Y, Du Y, et al. Clinical Pathway for Early Diagnosis of COVID-19: Updates from Experience to Evidence-Based Practice. *Clin Rev Allergy Immunol* 2020; 59:89–100.

20. Reiter PL, Pennell ML, Katz ML. Acceptability of a COVID-19 vaccine among adults in the United States: How many people would get vaccinated? *Vaccine* 2020; 38:6500–6507.
21. Thompson CN, Baumgartner J, Pichardo C, et al. COVID-19 Outbreak - New York City, February 29-June 1, 2020. *MMWR Morb Mortal Wkly Rep* 2020; 69:1725–1729.
22. Goldstein J, McKinley J. Coronavirus in NY: Manhattan woman is first confirmed case in state. *The New York Times* 2020. Available at: <https://www.nytimes.com/2020/03/01/nyregion/new-york-coronavirus-confirmed.html>.
23. Zhao H, Lu X, Deng Y, et al. COVID-19: asymptomatic carrier transmission is an underestimated problem. *Epidemiol Infect* 2020; 148:e116.
24. Bai Y, Yao L, Wei T, et al. Presumed Asymptomatic Carrier Transmission of COVID-19. *JAMA* 2020; 323:1406–1407.
25. Zou L, Ruan F, Huang M, et al. SARS-CoV-2 Viral Load in Upper Respiratory Specimens of Infected Patients. *N Engl J Med* 2020; 382:1177–1179.
26. Al-Tawfiq JA. Asymptomatic coronavirus infection: MERS-CoV and SARS-CoV-2 (COVID-19). *Travel Medicine and Infectious Disease* 2020; 35:101608.
27. R Core Team. R: A language and environment for statistical computing. R Foundation for Statistical Computing, Vienna, Austria 2020. Available at: <https://www.R-project.org/>.
28. Argenziano MG, Bruce SL, Slater CL, et al. Characterization and clinical course of 1000 Patients with COVID-19 in New York: retrospective case series. *Medrxiv: The Preprint Server for Health Sciences* 2020.
29. Wang R, Chen J, Gao K, et al. Vaccine-escape and fast-growing mutations in the United Kingdom, the United States, Singapore, Spain, India, and other COVID-19-devastated countries. *Genomics* 2021; 113:2158–2170.
30. Zarei F, Jalli R, Iranpour P, et al. Differentiation of Chest CT Findings Between Influenza Pneumonia and COVID-19: Interobserver Agreement Between Radiologists. *Acad Radiol* 2021; 28(10):1331–1338.
31. Delli Pizzi A, Chiarelli AM, Chiacchiaretta P, et al. Radiomics-based machine learning differentiates “ground-glass” opacities due to COVID-19 from acute non-COVID-19 lung disease. *Sci Rep* 2021; 11:17237.
32. Lin Z, Long F, Yang Y, et al. Serum ferritin as an independent risk factor for severity in COVID-19 patients. *J Infect* 2020; 81:647–679.
33. Gómez-Pastora J, Weigand M, Kim J, et al. Hyperferritinemia in critically ill COVID-19 patients - Is ferritin the product of inflammation or a pathogenic mediator? *Clin Chim Acta* 2020; 509:249–251.
34. Colafrancesco S, Alessandri C, Conti F, et al. COVID-19 gone bad: A new character in the spectrum of the hyperferritinemic syndrome? *Autoimmun Rev* 2020; 19:102573.
35. Zhou C, Chen Y, Ji Y, et al. Increased Serum Levels of Hecpidin and Ferritin Are Associated with Severity of COVID-19. *Med Sci Monit* 2020; 26:e926178.
36. Olson DR, Huynh M, Fine A, et al. Preliminary Estimate of Excess Mortality During the COVID-19 Outbreak - New York City, March 11-May 2, 2020. *MMWR Morb Mortal Wkly Rep* 2020; 69:603–605.
37. Corman VM, Landt O, Kaiser M, et al. Detection of 2019 novel coronavirus (2019-nCoV) by real-time RT-PCR. *Euro Surveill: Bulletin European Sur Les Maladies Transmissibles = European Communicable Disease Bulletin* 2020; 25.
38. Xiao Y, Shi X, She Q, et al. Exploration of turn-positive RT-PCR results and factors related to treatment outcome in COVID-19: a retrospective cohort study. *Virulence* 2020; 11:1250–1256.
39. Xie X, Zhong Z, Zhao W, et al. Chest CT for Typical Coronavirus Disease 2019 (COVID-19) Pneumonia: Relationship to Negative RT-PCR Testing. *Radiology* 2020; 296:E41–e45.