

Case Report

In situ free-floating craniectomy for traumatic cerebral decompression in an infant: A field hospital solution

Victoria T. Trinh, Edward A. M. Duckworth

Department of Neurosurgery, Baylor College of Medicine, Houston, Texas, USA

E-mail: Victoria T. Trinh - vttrinh@bcm.edu; *Edward A. M. Duckworth - edward.duckworth@bcm.edu

*Corresponding author

Received: 3 August 11

Accepted: 7 October 11

Published: 14 November 11

This article may be cited as:Trinh VT, Duckworth EA. *In situ* free-floating craniectomy for traumatic cerebral decompression in an infant: A field hospital solution. Surg Neurol Int 2011;2:157.Available FREE in open access from: <http://www.surgicalneurologyint.com/text.asp?2011/2/1/157/89855>

Copyright: © 2011 Trinh VT. This is an open-access article distributed under the terms of the Creative Commons Attribution License, which permits unrestricted use, distribution, and reproduction in any medium, provided the original author and source are credited.

Abstract

Background: Despite refinements in neurotrauma care, the morbidity and mortality of severe traumatic brain injury (TBI) in pediatric patients remains high. We report a novel approach to the surgical management of increased intracranial pressure in severe TBI utilizing an *in situ* free-floating craniectomy technique, which was originally devised as a creative solution to the unique challenges in a Haitian field hospital following the 2010 earthquake.

Case Description: A 13-month-old Haitian boy presented to Project Medishare field hospital in Port-au-Prince with left hemiplegia, a bulging fontanelle, and increasing lethargy following a traumatic head injury 4 days prior. An urgent craniectomy was performed based on clinical grounds (no brain imaging was available). A standard trauma flap incision was made, followed by a hemicraniectomy and expansion duraplasty. A small hematoma was evacuated. Frontal, temporal, and parietal bone flaps were placed on the dura in approximation to their normal anatomical configuration, but not affixed, leaving space for further brain edema, and the scalp was closed. The child experienced favorable peri-operative and early postoperative results.

Conclusion: *In situ* free-floating craniectomy, while devised as a creative solution to limited resources in a natural disaster zone, may offer advantages over more traditional techniques.

Key Words: Craniectomy, free-floating craniectomy, intracranial pressure, traumatic brain injury

Access this article online**Website:**www.surgicalneurologyint.com**DOI:**

10.4103/2152-7806.89855

Quick Response Code:

INTRODUCTION

The management of posttraumatic malignant intracranial pressure (ICP) is vexing. In infants, malignant ICP presents as a significant therapeutic challenge. The open space within the cranial vault is already limited, and thus volume increases are poorly tolerated.^[2] Decompressive craniectomy is effective in reducing ICP by increasing

cranial vault volume to accommodate brain swelling, but is associated with postoperative complications and requires potentially morbid follow-up procedures.^[4,9,12] Problems include the necessity for bone flap storage, second stage surgery for cranioplasty, a temporary skull defect, infection, and disturbances of cerebrospinal fluid hemodynamics.^[14]

In this report, we present our experience with a novel

surgical technique for cerebral decompression in an infant. Our technique was developed in a post-disaster field hospital in the wake of Haiti's 2010 earthquake, where resources for bone storage were limited, there was an uncertainty that cranioplasty could or would ever be accomplished, and wound infections were common [Figure 1]. Our review of the literature on this technique shows that it has not been previously reported. Our technique borrows from treatment strategies for craniosynostosis in infants, and may provide a "one-step" alternative to traditional decompressive craniectomy where the resources for preservation of bone flaps are limited, or when a second procedure is undesirable.

CASE REPORT

Clinical presentation

A 13-month-old Haitian boy presented to Project Medishare field hospital in Port-au-Prince, with a 4-day history of traumatic brain injury (TBI). A cement block fell through the roof of his "sheet" tent, striking him on the right side of the head. He initially lost consciousness, and once he was more alert, was noted to be hemiplegic. The family did not seek immediate medical attention, but when he became increasingly sleepy and irritable, they brought him to the hospital.

On examination, the child exhibited left hemiplegia, prominent scalp veins, a bulging fontanelle, irritability, and a depressed level of consciousness. Computed tomography (CT) scanning was unavailable at the field hospital, and a decision for urgent surgical intervention was made based on the patient's history of neurological deterioration and observed signs of increased ICP.

Operative technique

General anesthesia was induced, and then the patient

positioned supine for a typical trauma flap craniotomy/craniectomy procedure. A reverse question mark scalp incision was utilized and a myocutaneous flap elevated, revealing a large frontoparietotemporal linear depressed skull fracture with active herniation of cortical tissue from the fracture line [Figure 2]. Multiple burr holes were placed with a Hudson Brace, and then a Gigli saw was used to perform a craniectomy in three large pieces, roughly corresponding to the frontal bone, parietal bone, and squamous temporal bone.

A large dural rent was extended to create a stellate dural opening. Epidural hemostasis was achieved using bipolar cautery and Surgicel (Ethicon, Cincinnati, OH, USA). Evacuation of a small intraparenchymal hematoma and brain elevation out of the large craniectomy defect resulted in significant brain relaxation. After hemostasis was ensured, the stellate dural flaps were laid on the brain surface and the entire defect was covered with a thin layer of Fibrillar hemostatic agent (Ethicon) [Figure 3a]. The three bone flaps were then placed on the surface of the dura/fibrillar cushion in approximate anatomic position [Figure 3b]. Because of the expansion of the brain out of the craniectomy and the requisite increase in surface area, there were gaps of 5–10 mm between each of the flaps. The bone flaps were not affixed in any way to the skull or to each other, but were fairly adherent in their positions. The scalp was then reapproximated under mild tension in a standard fashion.

After surgery, the patient remained intubated, but was extubated on postoperative day 1. He was transferred out of the pediatric ICU after several days. He was alert and feeding well immediately, and was noted to have movement of the left hand and lower extremity by postoperative day 6. The incision site remained intact without swelling or defect. The patient had excellent cosmetic outcomes and neurological recovery, and was discharged on postoperative day 10 [Figure 4]. Due to the



Figure 1: Project Medishare tent hospital on the grounds of Port-au-Prince Airport. Since 1994, Project Medishare has provided healthcare and development services to Haiti, and was one of the first medical relief organizations on the ground following the earthquake in Haiti

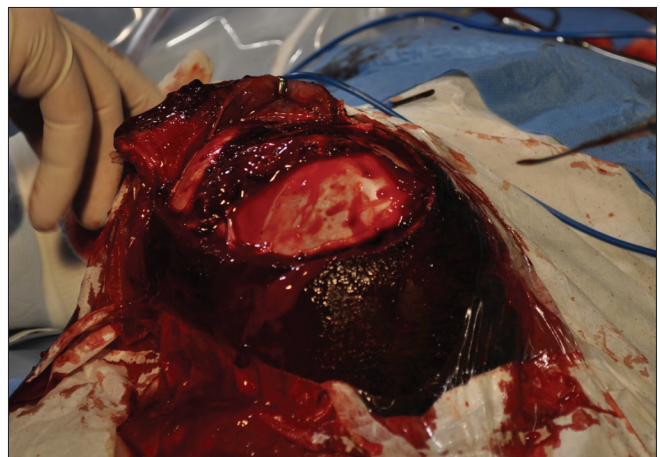


Figure 2: Herniation of cortical tissue from linear depressed skull fracture

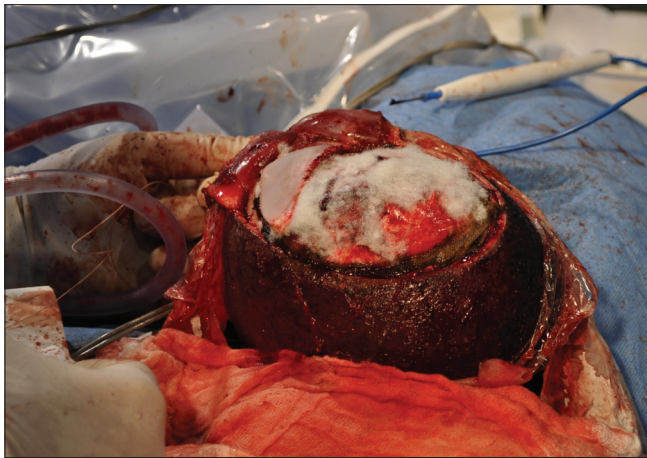


Figure 3a: Thin layer of absorbable Surgical Fibrillar dressing over the dura blankets the entire defect. Surgical Fibrillar enhances hemostasis and is bactericidal

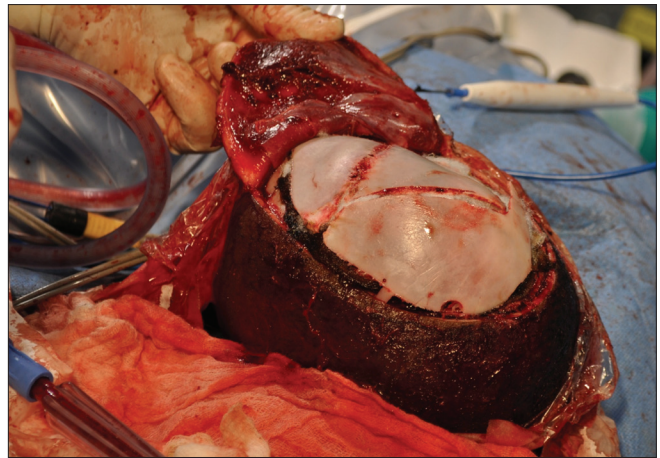


Figure 3b: Technique of *in situ* free-floating craniectomy bone flaps positioned 5–10 mm apart on the surface of the Fibrillar cushion. Bone flaps were not affixed to each other or to the skull or underlying dura, and were designed to permit mobility for outward expansion in case of further traumatic edema

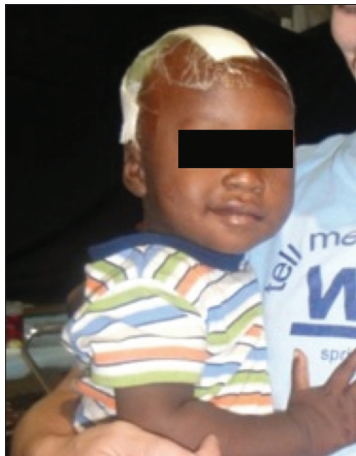

Figure 4: By postoperative day 6, our 13-month-old patient had remarkable neurological recovery, with improvements in mood, alertness, and improved range of motion of left upper and lower extremities

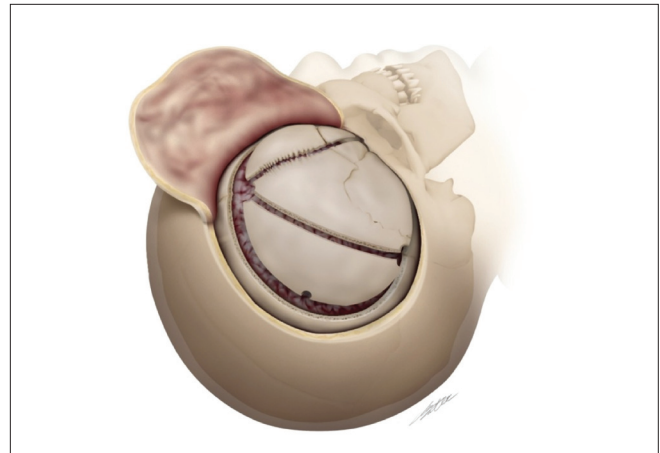


Figure 5a: Illustration demonstrating the technique of *in situ* free-floating craniectomy. Bone flaps accommodate to acute brain swelling, may prevent absence of bone flap complications such as syndrome of the trephined, and preclude the need for a second surgery

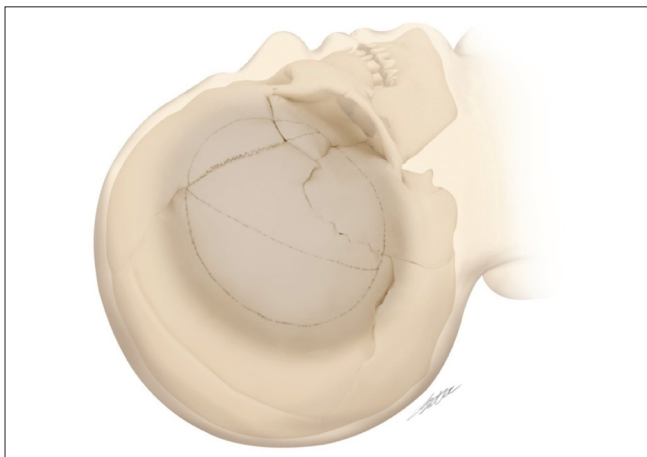


Figure 5b: Following abatement of the brain swelling, the skull flaps will likely fuse together, conforming to the natural contours of the brain with excellent cosmetic outcome

unique nature of this case and the post-disaster condition in Haiti, long-term clinical or radiographic follow-up was not available.

DISCUSSION

Traditional decompressive craniectomy

Studies in adult and pediatric patient populations have shown the beneficial effects of decompressive craniectomy in severe TBI. Yet, craniectomy carries with it inherent morbidity and requires special accommodations. Bone flap storage requires a strict sterile environment, a bone bank freezer^[11] or separate incision in the abdomen.^[11] There are many hospitals that lack the protocols and resources for proper skull flap preservation. Furthermore,

the need for an additional surgery to perform the cranioplasty can lead to increased risks associated with a second procedure, including injury to the cortex from dissection of the adherent scalp, infection of the devitalized flap, or wound healing complications.^[8]

Alternatives to traditional decompressive craniectomy

Several investigators have developed alternative techniques to address these concerns. To the best of our knowledge, only two described techniques simultaneously eliminate the need for secondary storage of the bone flap and a second operation for the cranioplasty/bone flap replacement. Schmidt *et al.*^[13] reviewed 25 patients who underwent a hinge craniotomy utilizing titanium mini-plates and screws to affix the bone flap to the surrounding bone at one point only. The authors portray this technique as a way to maintain cerebral protection, without risking bone resorption or sunken skin flap syndrome. However, the single point of fixation may also prevent the full expansion of edematous brain from restriction under the affixed segment of bone.

Ahn *et al.*^[4] reported seven patients who underwent *in situ* floating resin cranioplasty for cerebral decompression. This technique potentially reduces complications from an absent bone flap by providing a 1-mm-thick resin implant that stretches 5 mm beyond the outer rim of the craniectomy defect. The resin cranioplasty affords cerebral protection, but as a foreign implant may lead to the formation of a membrane interface, increasing the risk of inflammation and infection.^[6]

Parallels with craniosynostosis treatment

While the pathophysiology of craniosynostosis and TBI are distinct, parallels can be drawn between our technique of free-floating bone flaps and craniectomy techniques for synostosis. Both disease processes can result in increased ICP. Craniosynostosis is the premature and abnormal fusion of one or more of the six suture lines that form the living skull.^[5] Treatment options range from simple strip craniectomy to complex cranial vault remodeling. Clinical studies have shown that following craniosynostosis surgery in this age group, reossification of craniectomized bone fragments occurs.^[3] Biological studies have also shown that the dura and the pericranium have osteogenic properties, especially in the young.^[7]

Risks of leptomenigeal cyst, role of the dura

One might suggest that our technique could lead to a leptomenigeal cyst or growing skull fracture, a rare (0.01%) late complication of traumatic skull fractures^[10] and craniosynostosis patients undergoing strip craniectomy. It has been discussed that lacerated dura proximal to the linear skull fracture promotes growing skull fractures via cerebral/subarachnoid herniation

through the skull fracture.^[15] In leaving the dura open in a stellate fashion, it is certainly possible that our patient could have a leptomenigeal cyst. However, in order to maximize the decompression, it was necessary to open the dura, and dural substitute was in short supply. Studies show that opening the dura is associated with better reduction of ICP when compared with bone elevation alone. Our technique might be combined with the placement of an expanded dural graft to ensure complete closure of the dura after wide opening.

Risk of bone depression

One limitation of our technique may be the risk of bone depression if the gaps between the free bone flaps are too wide.^[14] In our case, the only bone removed was the small defect created by the Gigli saw. However, due to brain expansion out of the skull from cerebral edema, there were larger gaps that resolved once the edema abated. The hinge craniotomy^[13] and resin cranioplasty^[4] techniques mentioned above may reduce the risk of bone depression, though they are not without their own complications (inadequate decompression, nidus for infection).

CONCLUSION

We report our experience with a new technique developed in a distressed operating environment: *in situ* free-floating craniectomy for treatment of severe TBI in infants. The procedure allows mobile bone flaps to float outward during the acute phase of injury [Figure 5a], and then return to normal anatomic position with fusion of the bone edges once brain swelling resolves [Figure 5b]. Our experience suggests that it may be possible to surgically alleviate ICP without preservation of craniotomy flaps, a subsequent procedure, or foreign implants. This is our first and only experience thus far with this technique. We believe readers may find this case interesting, but further research and a longer follow-up period will be needed to substantiate our findings.

ACKNOWLEDGMENT

We would like to thank Sangwon Yeo for his illustration.

REFERENCES

1. Açikgöz B, Ozcan OE, Erbeni A, Bertan V, Ruacan S, Açikgöz HG. Histopathologic and microdensitometric analysis of craniotomy bone flaps preserved between abdominal fat and muscle. *Surg Neurol* 1986;26:557-61.
2. Adamo MA, Drazin D, Waldman JB. Decompressive craniectomy and postoperative complication management in infants and toddlers with severe traumatic brain injuries. *J Neurosurg Pediatrics* 2009;3:334-9.
3. Agrawal D, Steinbok P, Cochrane DD. Reformation of the sagittal suture following surgery for isolated sagittal craniosynostosis. *J Neurosurg* 2006;105:115-7.
4. Ahn DH, Kim DW, Kang SD. *In situ* floating resin cranioplasty for cerebral decompression. *J Korean Neurosurg Soc* 2009;46:417-20.

5. Clayman MA, Murad GJ, Steele MH, Seagle MB, Pincus DW. History of craniostylosis surgery and the evolution of minimally invasive endoscopic techniques: The University of Florida experience. *Ann Plast Surg* 2007;58:285-7.
6. Gladstone HB, McDermott MW, Cooke DD. Implants for cranioplasty. *Otolaryngol Clin North Am* 1995;2:381-400.
7. Gosain AK, Santoro TD, Song LS, Capel CC, Sudhakar PV, Matloub HS. Osteogenesis in calvarial defects: Contribution of the dura, the pericranium, and the surrounding bone in adult versus infant animals. *Plast Reconstr Surg* 2003;112:515-27.
8. Hancock DO. The fate of replaced bone flaps. *J Neurosurg* 1963;20:983-4.
9. Hejazi N, Witzmann A, Fae P. Unilateral decompressive craniectomy for children with severe brain injury: Report of seven cases and review of the relevant literature. *Eur J Pediatr* 2002;161:99-104.
10. Khandelwal S, Sharma GL, Gopal S, Sakhi P. Growing skull fractures/leptomeningeal cyst. *Indian J Radiol Imaging* 2002;12:485-6.
11. Kreuz FP, Hyatt GW, Turner TC, Bassett AL. The preservation and clinical use of freeze-dried bone. *J Bone Joint Surg Am* 1951;33A:863-72.
12. Münch E, Horn P, Schürer L, Piepgras A, Paul T, Schmiedek P. Management of severe traumatic brain injury by decompressive craniectomy. *Neurosurgery* 2000;47:315-22; discussion 322-3.
13. Schmidt JH 3rd, Reyes BJ, Fischer R, Flaherty S. Use of hinge craniotomy for cerebral decompression. *J Neurosurg* 2007;107:678-82.
14. Stiver SI. Complications of decompressive craniectomy for traumatic brain injury. *Neurosurg Focus* 2009;26:E7.
15. Taveras J, Ransohoff J. Leptomeningeal cysts of the brain following trauma with erosion of the skull: A study of seven cases treated by surgery. *J Neurosurg* 1953;10:233-41.