



Clinical and genetic aspects of mild hypophosphatasia in Japanese patients

Katsuyuki Yokoi^{a,b}, Yoko Nakajima^{a,*}, Yasuko Shinkai^b, Yoshimi Sano^c, Mototaka Imamura^c, Tomoyuki Akiyama^d, Tetsushi Yoshikawa^a, Tetsuya Ito^a, Hiroki Kurahashi^b

^a Department of Pediatrics, Fujita Health University School of Medicine, Toyoake 470-1192, Japan

^b Division of Molecular Genetics, Institute for Comprehensive Medical Science, Fujita Health University, Toyoake 470-1192, Japan

^c Department of Plastic Surgery, Division of Pediatric Dentistry & Orthodontics, Fujita Health University of Medicine, Toyoake 470-1192, Japan

^d Department of Child Neurology, Okayama University Hospital, Okayama 700-8558, Japan

ARTICLE INFO

Keywords:

Hypophosphatasia

ALPL

Premature loss of deciduous teeth

Dominant-negative mutations

ABSTRACT

Background: Hypophosphatasia (HPP) is a rare inborn error of metabolism that results from a dysfunctional tissue non-specific alkaline phosphatase enzyme (TNSALP). Although genotype-phenotype correlations have been described in HPP patients, only sparse information is currently available on the genetics of mild type HPP. **Methods:** We investigated 5 Japanese patients from 3 families with mild HPP (patients 1 and 2 are siblings; patient 4 is a daughter of patient 5) who were referred to Fujita Health University due to the premature loss of deciduous teeth. Physical and dental examinations, and blood, urine and bone density tests were conducted. Genetic analysis of the *ALPL* gene was performed in all patients with their informed consent.

Results: After a detailed interview and examination, we found characteristic symptoms of HPP in some of the study cases. Mobile teeth or the loss of permanent teeth were observed in 2 patients, and 3 out of 5 patients had a history of asthma. The serum ALP levels of all patients were 30% below the lower limit of the age equivalent normal range. *ALPL* gene analysis revealed compound heterozygous mutations, including Ile395Val and Leu520Argfs in family 1, Val95Met and Gly491Arg in family 2, and a dominant missense mutation (Gly456Arg) in family 3. The 3D-modeling of human TNSALP revealed three mutations (Val95Met, Ile395Val and Gly456Arg) at the homodimer interface. Severe collisions between the side chains were predicted for the Gly456Arg variant. **Discussion:** One of the characteristic findings of this present study was a high prevalence of coexisting asthma and a high level serum IgE level. These characteristics may account for the fragility of tracheal tissues and a predisposition to asthma in patients with mild HPP. The genotypes of the five mild HPP patients in our present study series included 1) compound heterozygous for severe and hypomorphic mutations, and 2) dominant-negative mutations. All of these mutations were at the homodimer interface, but only the dominant-negative mutation was predicted to cause a severe collision effect between the side chains. This may account for varying mechanisms leading to different effects on TNSALP function.

1. Objective

Hypophosphatasia (HPP) is an inherited disorder characterized by defective bone and tooth mineralization, and a deficiency in tissue-nonspecific alkaline phosphatase isoenzyme (TNSALP) activity [1]. The incidence of this disorder is not accurately known, but the birth prevalence of the most severe forms of HPP, i.e. perinatal and infantile, is estimated at 1:100,000 [2]. An estimate of 1:6370 has been suggested previously for less severe forms of HPP using molecular data [3].

TNSALP is a phosphomonoesterase of 507 residues that is anchored at its carboxyl terminus to the plasma membrane by a

phosphatidylinositol-glycan moiety. This enzyme is physiologically active in its dimeric form and cleaves the extracellular substrates pyridoxal-5'-phosphate (PLP), phosphoethanolamine (PEA) and inorganic pyrophosphates (PPi) [1]. Low TNSALP activity has impacts on multiple systems, including the respiratory, central nervous, renal, musculoskeletal, and immune systems, and on dental structures [4].

HPP is caused by mutations in the liver/bone/kidney alkaline phosphatase (*ALPL*) gene encoding TNSALP [5,6]. To date, 390 mutations have been identified in *ALPL* that show an association with HPP. (http://www.sesep.uvsq.fr/03_hypo_mutations.php). HPP symptoms are highly variable in terms of their clinical expression, and six clinical

* Corresponding author at: Department of Pediatrics, Fujita Health University School of Medicine, 1-98 Dengakugakubo, Kutsukake-cho, Toyoake, Aichi 470-1192, Japan.

E-mail address: yonaka@fujita-hu.ac.jp (Y. Nakajima).

<https://doi.org/10.1016/j.ymgmr.2019.100515>

Received 3 July 2019; Received in revised form 5 August 2019; Accepted 2 September 2019

Available online 11 October 2019

2214-4269/ © 2019 The Authors. Published by Elsevier Inc. This is an open access article under the CC BY-NC-ND license (<http://creativecommons.org/licenses/by-nc-nd/4.0/>).

forms are currently recognized. These are based on the age at diagnosis and the severity of disease features including lethal perinatal, benign perinatal, infantile, childhood, adult, and odontohypophosphatasia (odonto-HPP) [6]. Enzyme replacement therapy (ERT) has recently been reported to be efficient and improve patient outcomes even in cases of life-threatening forms of HPP [7]. Although some genotype/phenotype correlations have been described for a portion of the *ALPL* mutations, the mechanisms underlying HPP remain incompletely understood, particularly in the mild forms of this disorder.

In our present study, we analyzed the clinical and genetic aspects of a small series of Japanese patients with mild HPP.

2. Material and methods

2.1. Informed consent and ethical approval

Informed consent was obtained from each patient and/or their family. The study protocol was approved by the Ethical Review Board for Human Genome Studies at Fujita Health University.

2.2. Clinical survey of mild HPP patients

In our present study, mild HPP refers to childhood and adult HPP, odontohypophosphatasia, and perinatal benign HPP. Severe HPP denotes the perinatal and infantile forms. We reviewed the medical charts of 5 patients from 3 families who presented with mild HPP and had sufficient follow-up data. Patients 1 and 2 are siblings, and patient 4 is the daughter of patient 5. All of these cases had been referred to Fujita Health University Hospital for a detailed medical examination due to the premature loss of deciduous teeth. Our review of these cases included all available data from the physical examinations and medical care provided at the Fujita Health University Hospital.

All patients had a diagnosis of HPP clinically, biochemically, and genetically. The diagnosis of HPP required that all of the following criteria be met at the first admission: 1) a medical history or physical examination consistent with one or more dento-osseous complication(s) of HPP; 2) no evidence of any other condition that could cause the early loss of primary teeth; and 3) a serum ALP activity level below the age-matched reference ranges [8]. Physical and dental histories were recorded through a diagnostic interview process. Dental examinations were carried out at Department of Plastic Surgery, Division of Pediatric Dentistry & Orthodontics, Fujita Health University of Medicine. Clinical signs and symptoms were evaluated based upon a physical and oral examination, and the available medical or dental records. Biochemical and radiographic tests were performed at diagnosis. The serum ALP, PLP, Ca, phosphorus, parathyroid hormone (PTH), total serum IgE and 1,25-OH vitamin D levels, and the urine PEA levels on a spot urine test, were evaluated in all patients. The reference values for serum ALP, serum PLP/PL and urine PEA were obtained from Tanaka et al. [9], Akiyama et al. [10] and SRL Inc., respectively. A high total serum IgE was defined as a level higher than the adult standard value (> 250 IU/mL). Short stature was defined as a height below -2SD. Non atopy was

defined as no evidence of pruritic skin, including no reporting by a parent of any rubbing or scratching by the child [11].

Bone mineral density (BMD) was measured at the level of the lumbar spine (L2-L4) using dual-energy X-ray absorptiometry. BMD Z-scores were calculated using data from a general population of Japanese children and adolescents (BMD of the lumbar spine and total body mass) after adjusting for age. However, because these prior data do not include children under 6 years of age, the Z-scores were calculated for our current study patients 1 and 2 only.

2.3. *ALPL* gene analysis

ALPL gene analysis was performed with informed consent. DNA was extracted from peripheral blood samples and sequenced using the Sanger method to screen for genetic variations at the nucleotide level throughout all coding exons of the *ALPL* gene. We used the UCSC genome browser (<http://genome-asia.ucsc.edu/human> GRCh38/hg38) as the human genome assembly. PCR was carried out in a 10 µL volume containing 5.7 µL of distilled water, 2 µL of 5×PrimeSTAR GXL buffer (TaKaRa, Japan), 0.2 µL of each primer (10 µM), 0.1 µL of PrimeSTAR GXL DNA polymerase (TaKaRa, Japan), and 1 µL of template DNA (20 ng/µL). The primer sequences are listed in the Online Supplementary Table. PCR amplifications were performed using a DNA thermal cycler (Applied Biosystems) under the following cycling conditions: initial denaturation at 94 °C for 2.5 min followed by 35 cycles at 98 °C for 10s, 60 °C for 15 s and 68 °C for 45 s. The PCR products were sequenced using a standard Sanger method. The *ALPL* sequence from the HPP patients was compared to control subjects and the reference *ALPL* sequence (Ref Seq NM_000478.5). Allele frequencies were investigated via gnomAD browser beta (<http://gnomad.broadinstitute.org/>). In silico analysis was performed using PolyPhen and SIFT.

2.4. 3D-modeling

A 3D model of the TNSALP molecule was previously constructed using the homology between TNAP and human placental alkaline phosphatase, which has a determined crystal structure. The locations of the mutations were determined using the UCSF Chimera (www.cgl.ucsf.edu/chimera).

3. Results

3.1. Clinical evaluations

The chief complaints at diagnosis were premature loss of deciduous teeth in patients 1 to 4 and permanent teeth loss in patient 5. The dental features of these cases are summarized in Table 1. All of the study patients had premature loss of their anterior deciduous teeth and atrophy of the alveolar bone. Permanent tooth loss was found in patient 5 only, but the mobility of permanent teeth was also evident in patient 1. Elongation of teeth and enamel hypoplasia were observed in 2 and 3 of the 5 patients, respectively. The results of biochemical of

Table 1
Dental features of the study patients.

Dental features	Patient 1	Patient 2	Patient 3	Patient 4	Patient 5
Age at diagnosis	9 y	7 y	1 y	4 y	39 y
Premature loss of anterior deciduous teeth	+	+	+	+	+
Premature loss of posterior deciduous teeth	+	Mobility	–	–	+
Loss of permanent teeth	Mobility	–	– ^a	– ^a	+, Mobility
Delay of eruption	–	–	–	–	–
Atrophy of alveolar bone	+	+	+	+	+
Elongation of teeth	–	+	–	–	+
Enamel hypoplasia	+	–	+	+	–

^a Deciduous dentition.

Table 2

Clinical, biochemical and radiographic data for the study patients. N/A, not available. Reference values: Serum ALP from Tanaka et al. [9]; Serum PLP and PL from Akiyama et al. [8]; urine PEA from SRL Inc. For serum ALP, reference values are shown for patients over 20 years of age. For serum PLP and PL, reference values for 7–17 year-old patients are shown.

Patient ID	Patient 1	Patient 2	Patient 3	Patient 4	Patient 5
Age	10	8	1	4	39
Gender	Female	Male	Female	Female	Female
Biochemical test					
Ca (mg/dl)	9.7 (Reference: 8.7–10.3)	9.8 (8.7–10.3)	11.1 (8.7–10.3)	10.4 (8.7–10.3)	9.7 (8.7–10.3)
Phosphorus (mg/dl)	5.3 (2.5–4.7)	5.9 (2.5–4.7)	7.5 (2.5–4.7)	4.9 (2.5–4.7)	4.3 (2.5–4.7)
ALP (U/L)	228 (470–1450)	245 (450–1300)	155 (395–1289)	286 (430–1150)	50 (120–340)
PTH (pg/ml)	31 (15–65)	27 (15–65)	8 (15–65)	21 (15–65)	32 (15–65)
1,25-OH vitD (pg/ml)	62.2 (20–70)	58.1 (20–70)	88.3 (20–70)	61.2 (20–70)	57.2 (20–60)
PLP (pyridoxal-5'-phosphate)(nmol/L)	469.9 (14.5–57.3)	322.5 (14.5–57.3)	375.2 (16.2–57.4)	325.9 (16.2–57.4)	89.9 (14.5–57.3)
PL (pyridoxal)(nmol/L)	39.9 (7.4–17.7)	28.8 (7.4–17.7)	27.2 (8.8–28.0)	43.8 (8.8–28.0)	6.7 (7.4–17.7)
PLP/PL	11.8	11.2	13.8	7.4	13.3
Total IgE (IU/ml)	638.4	349.5	267.5	1099	17.1
Urine PEA (μmol/g Cr)	480.1 (39.4–93.5)	720.6 (29.1–75.6)	662.7 (39.4–93.5)	507.7 (39.4–93.5)	274.7 (39.4–93.5)
Clinical findings without dental features					
Shortening or deformity of the extremities	–	–	–	–	–
Bone fractures (NO.)	1	0	0	0	1
Part of fractures	Forearm	–	–	–	Right shoulder
Seizure	–	–	–	–	–
Enlargement of the anterior fontanelle	–	–	–	–	–
Renal calcification	–	–	–	–	–
Stature (cm)	130 (–1.4SD)	123 (–0.2SD)	71.5 (–1.9SD)	100.4 (–0.85SD)	148.1 (–1.96SD)
Body weight (kg)	28.8 (–0.7SD)	23.9 (–0.1SD)	8.29 (–1.9SD)	15.5 (–0.9SD)	35.9
Deafness	–	–	–	–	–
Asthma	+	+	+	–	–
Atopy	–	–	–	–	–
Muscle ache	–	+	–	–	–
Dysphagia	–	–	+	–	–
Other symptom	–	–	–	–	Headache
Radiographic findings					
Hypomineralisation	–	–	–	–	–
Deformity of long bones	–	–	–	–	–
Flared metaphyses	–	–	+	–	–
Narrow thorax	–	–	–	–	–
Bone mineral density (g/cm ²)	0.644 (Z-score – 1.2)	0.551 (Z-score – 1.8)	0.298	0.395	N/A
Birth					
Gestational age	39w5d	38w0d	38w2d	39w6d	N/A
Birth weight (g)	2786 (–0.5SD)	2770 (–0.4SD)	2405 (–1.1SD)	2538 (–1.4SD)	N/A
Birth stature (cm)	47 (–1.2SD)	48.5 (0.2SD)	48 cm (–0.2SD)	49 (–0.2SD)	N/A
Birth head circumference (cm)	30 (–2.5SD)	33 (0.0SD)	N/A	31.4 (–1.5SD)	N/A
Birth chest circumference (cm)	31	31	N/A	30	N/A

radiographic testing, and the clinical findings other than the dental features at diagnosis, for all 5 study patients are presented in Table 2. Our present cases had been referred to our hospital in the first instance due to a single symptom i.e. the premature loss of deciduous teeth. After a detailed interview and examination however, other characteristic symptoms, and biochemical and radiographic findings, became evident as follows: dysphagia (1/5), headache (1/5), muscle ache (1/5), bone fractures (2/5), asthma (3/5), low serum ALP levels (5/5), high serum PLP/PL (5/5), high urine PEA levels (5/5), high serum IgE (4/5), flared metaphyses (1/5), and low Z-score BMD (2/2). All of our study patients showed serum ALP levels at > 30% below the lower limit of the age equivalent normal range. The serum PLP/PL and urine PEA levels were higher in all of our HPP patients compared to the control subjects. The BMD was measured in four patients, of whom two patients showed a low Z-score but this could not be calculated in the remaining two cases because their age were under 6.

3.2. Gene analysis

The results of our *ALPL* mutation sequencing analyses are presented in Table 3. The clinical forms of the genotypes were described previously [12–15]. The three families in our current series all harbored different mutations that are rare within the general population, and had

a minor allele frequency ranging from completely unreported to 0.00003716 (gnomAD browser beta). Family 1 (patients 1 and 2) members carried the compound heterozygous *ALPL* variants c.1183A > G (p.Ile395Val) and c.1559delT (p.Leu520Argfs). The c.1183A > G (p.Ile395Val) mutation was reported previously to result in a prenatal benign phenotype as the gene product still possessed residual ALP activity of 19.1% [16]. The c.1559delT (p.Leu520Argfs) variant is a null mutation that was previously reported to be common in Japanese severe HPP patients [17].

Family 2 (patient 3) was found to harbor compound heterozygous variants including c.283G > A (p.Val95Met) and c.1471G > A (p.Gly491Arg). Mutation c.283G > A (p.Val95Met) was registered previously in a public database (Institute of Human Genetics, University Of Wurzburg), and classified as “with likely pathogenic” in ClinVar, but no clinical information has been reported to date for this variation. Analysis of the Val95Met substitution using SIFT and PolyPhen prediction software indicated that this mutation was ‘tolerable’ and ‘possibly damaging’, with scores of 0.12 and 0.897, respectively. In contrast, c.1471G > A (p.Gly491Arg) is reported to be a severe perinatal phenotype mutation [14]. These data suggest that the c.1471G > A (p.Gly491Arg) mutation may be null whereas the gene product harboring the c.283G > A (p.Val95Met) variation may still possess residual enzymatic activity.

Table 3
Genotype-phenotype correlations within the HPP families examined in this study.

Mode of inheritance	Family 1 (patients 1 and 2)		Family 2 (patient 3)		Family 3 (patients 4 and 5)
	AR	AR	AR	AR	AD
Genotype	c.1183A > G(p.Ile395Val)	c.1559delT(p.Leu520Argfs)	c.283G > A(p.Val95Met)	c.1471G > A(p.Gly491Arg)	c.1366G > A(p.Gly456Arg)
In silico function (PolyPhen)	0.535	0.535	0.897	1	0.945
In silico function (SIFT)	0.08	0.08	0.12	0	0
Clinical form of the genotype	Prenatal benign	Infantile	Unknown	Perinatal	Infantile
Previous report	Wenkert et al. 2011	Orimo et al. 1994	Novel	Mornet et al. 1998	Ozono et al. 1996
Prevalence (% east Asia/total)	0.002031/ 0	0.0008803/ 0.01187	0.003716/ 0	0/0	0/0
ACMG evaluation	Likely pathogenic	Pathogenic	Likely pathogenic	Likely pathogenic	Pathogenic
Position in the 3D structure	Interface of homodimer	Unclear lesion	Interface of homodimer	Surface of protein	Interface of homodimer

Family 3 (patients 4 and 5) had only one heterozygous mutation, c.1366G > A (p.Gly456Arg), which had been initially reported as one of the compound heterozygous mutations in the infantile form of HPP [15]. Furthermore, a recent study using transfection experiments has indicated that this mutation has a dominant-negative effect [18].

3.3. 3D-modeling

The locations of the identified mutated residues in the 3D structures of human TNSALP are presented in Fig. 1. In contrast to the severe Gly491Arg mutation located at the surface of this protein, the three mutations that characterized the mild HPP cases in our present study (Val95Met, Ile395Val and Gly456Arg) were all localized at the homodimer interface. Severe collisions between the side chains were predicted in the Gly456Arg variant (Fig. 2a), whereas a mild only and no effect were predicted for the Val95Met and Ile395Val mutations, respectively (Fig. 2b, c).

4. Discussion

One of the characteristic findings in our present study series of 5 patients was the high percentage of coexisting asthma (3/5) as well as high level serum IgE (4/5). In addition, 3 out of the 4 patients with a high serum IgE had asthma. Tracheomalacia is a known symptom of perinatal lethal HPP [5] but the frequency of other clinical conditions associated with wheezing in these cases, such as asthma and the serum

IgE level, have remained unknown. Although we examined only a very small cohort of patients in our present study, more than half of these cases showed a past or current medical history of asthma and a high serum IgE. These characteristics may account for the fragility of tracheal tissues and a predisposition to asthma in mild HPP patients. Although the treatment approaches for HPP have historically been supportive in nature, enzyme replacement therapy (ERT) has recently become available for these patients using asfotase alfa (Strensiq™), a bone-targeting recombinant alkaline phosphatase [19]. This enzyme has produced beneficial effects in terms of survival and function in HPP patients [20,21]. However the selection of appropriate candidates for this ERT has remained challenging when the condition is not life-threatening [19]. The loss of permanent teeth has a detrimental impact on quality of life but no study has demonstrated the effectiveness of an early ERT in preventing this outcome in mild HPP. Further studies are needed to assess the efficacy of these therapies.

Our present mutational analysis identified compound heterozygous mutations in family 1, i.e. one obvious loss-of-function mutation (1559delT) and one variant that still possessed some residual enzymatic activity (Ile395Val). In family 2, one identified mutation (Gly491Arg) was previously described as severe, and another (Val95Met) to have only weak effects, by in silico functional data. Since the phenotype of patient 3 in this family was mild, it is possible that Val95Met may possess some residual ALP activity in this case. Family 3 harbored only one mutation (Gly456Arg) with an autosomal dominant transmission. This variant was reported previously to have a dominant-negative effect

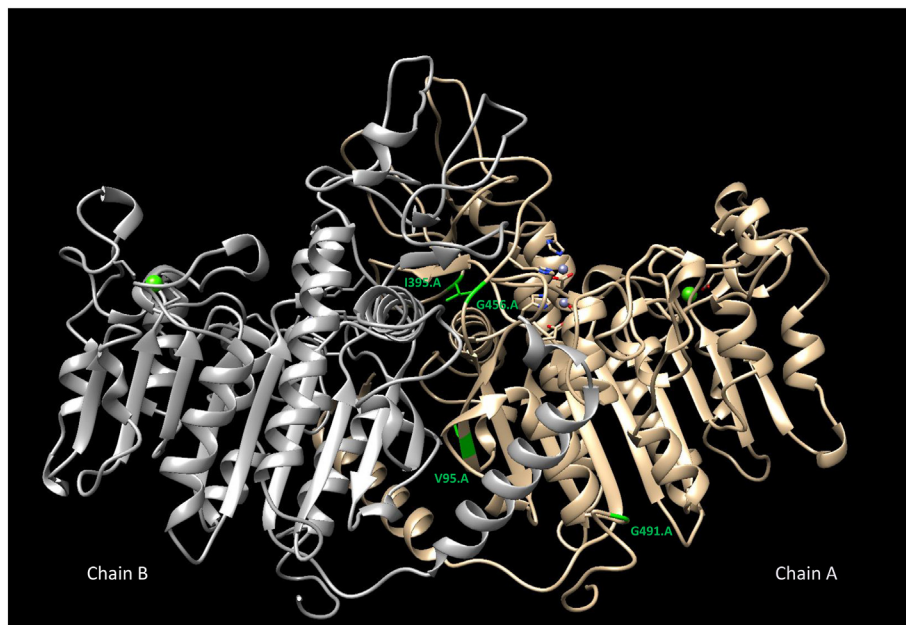


Fig. 1. 3D strand view of the human TNSALP protein. The two monomers are denoted by Chain A and Chain B. The three amino-acid residues that were found to be mutated in our mild HPP cases (G456R, V95M, I395V) are localized on the homodimer interface. Gly491Arg is located on the surface of the protein. Leu520Argfs is located within the region where the 3D structure has not yet been clearly determined.

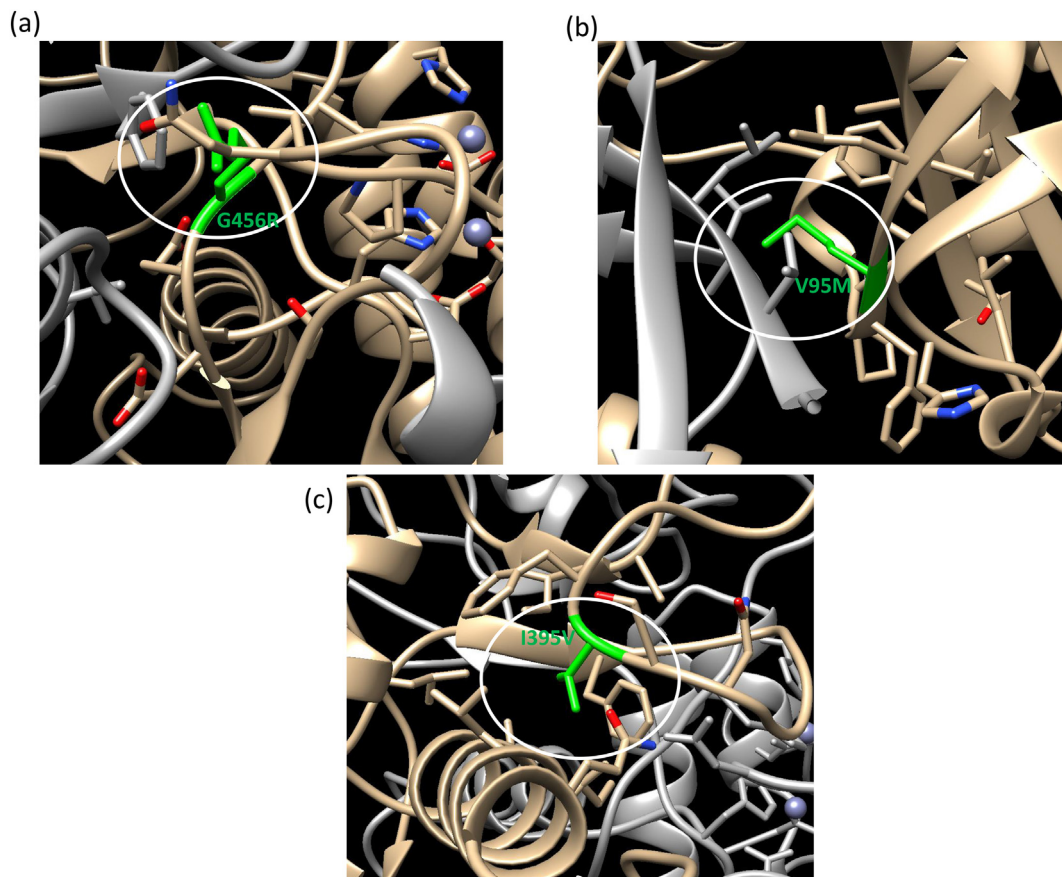


Fig. 2. Structural models of the human TNSALP protein. (a) Gly456 is located at the homodimer interface. Severe collisions between the side chains occur in the case of Gly456Arg (green). (b) Val95 is located at the homodimer interface. Mild collisions occur in the case of Val95Met (green). (c) Ile395 is located at the homodimer interface. No significant changes occur in the case of Ile395Val (green). (For interpretation of the references to colour in this figure legend, the reader is referred to the web version of this article.)

in vitro, although our present study is the first to clinically demonstrate Gly456Arg as autosomal dominant. Hence, the genotype of mild HPP can be classified as either 1) compound heterozygous for a severe and hypomorphic mutation; or 2) dominant-negative mutations. In family 1, two patients harboring the same mutations seemed to manifest a similar degree of disease severity. In family 3, patient 5 is the mother of patient 4 harboring the same mutation and had similar symptoms in her own childhood. Hence, a genotype-phenotype correlation was present in our current cases. Genetic testing for these genotypes will assist with genetic counseling.

The mechanisms underlying the effects of the mutations in our current study series, i.e. the reasons for a dominant or recessive effect, are still unclear. However, interactions between the monomers of the dimeric TNSALP protein structure are likely to be involved [22]. TNSALP has five regions (the active site and its vicinity, the active site valley, the homodimer interface, the crown domain, and the calcium-binding domain), which are crucial for enzyme function and bone mineralization [23]. It was previously reported that the TNSALP mutations identified to date with a dominant effect are restricted to three regions of the protein: the active site, homodimer and crown domain. However the difference between the standard recessive mutation and these dominant mutations is still unknown. A prevailing hypothesis is that the dominant-negative effect may be due to the inhibition of the wild-type monomer by a mutated monomer in the heterodimer, or the sequestration of the wild-type protein by a mutant product in the Golgi apparatus that prevents it from being transported to the membrane [24]. In our current analysis, three of the identified mutations were located at the homodimer interface, but the Gly456Arg mutation

showing a dominant-negative effect produced the most severe change in 3-D modeling. TNSALP Gly456Arg variants may maintain monomer interactions and might directly affect the enzymatic activity of dimers, including those harboring mutations, whilst the dimers from normal monomers would maintain small amounts of enzymatic activity. In contrast, the dimers of the proteins containing the hypomorphic mutations identified in families 1 and 2 (Ile395Val, Val95Met) could maintain low levels of enzymatic activity because of the lesser impact of these variations compared to Gly456Arg. Future investigations of the differences in the 3D structures of TNSALP variants may reveal the precise mechanisms underlying dominant-negative and recessive but weak mutation effects.

Ethics approval and consent to participate

All procedures in this study were conducted in accordance with the ethical standards of the responsible committee on human experimentation (institutional and national) and with the Helsinki Declaration of 1975, as revised in 2005(5).

Consent for publication

Written informed consent to publish medical information and images was obtained from all patients and/or their family reported in this publication.

Declaration of Competing Interests

The authors declare no conflicts of interest in relation to this study.

Funding

This research did not receive any specific grant from funding agencies in the public, commercial, or not-for-profit sectors.

Contributions of individual authors

Katsuyuki Yokoi: Sanger sequencing, data retrieval, drafting and revision of the manuscript.

Yoko Nakajima: conception and design, analysis and interpretation, drafting of the manuscript.

Yasuko Shinkai: 3-D modeling.

Yoshimi Sano: dental examinations.

Mototaka Imamura: dental examinations.

Tomoyuki Akiyama: analysis of the serum PLP, PL and urine PEA levels.

Tetsushi Yoshikawa: experimental analysis and interpretation of data.

Tetsuya Ito: experimental analysis and interpretation of data.

Hiroki Kurahashi: conception and design, analysis and interpretation, critical revision of the manuscript for important intellectual content.

Acknowledgements

We thank the patients and their families for their participation. We also thank past and present members of our laboratory.

Appendix A. Supplementary data

Supplementary data to this article can be found online at <https://doi.org/10.1016/j.ymgmr.2019.100515>.

References

- [1] E. Mornet, Hypophosphatasia, *Orphanet. J. Rare. Dis.* 2 (2007) 40, <https://doi.org/10.1186/1750-1172-2-40>.
- [2] D. Fraser, Hypophosphatasia, *Am. J. Med.* 22 (1957) 730–746.
- [3] E. Mornet, A. Yvard, A. Taillandier, D. Fauvert, B. Simon-Bouy, A molecular-based estimation of the prevalence of hypophosphatasia in the European population, *Ann. Hum. Genet.* 75 (3) (2011) 439–445.
- [4] A.B. Daniel, V. Saraff, N.J. Shaw, R. Yates, M.Z. Mughal, R. Padidela, Healthcare resource utilization in the management of hypophosphatasia in three patients displaying a spectrum of manifestations, *Orphanet. J. Rare. Dis.* 13 (2018) 142, <https://doi.org/10.1186/s13023-018-0869-4>.
- [5] T. Taketani, K. Onigata, H. Kobayashi, Y. Mushimoto, S. Fukuda, S. Yamaguchi, Clinical and genetic aspects of hypophosphatasia in Japanese patients, *Arch. Dis. Child.* 99 (2014) 211–215, <https://doi.org/10.1136/archdischild-2013-305037>.
- [6] L. Martins, T.L. Rodrigues, M.M. Ribeiro, M.T. Saito, A.P. Giorgetti, M.Z. Casati, et al., Novel ALPL genetic alteration associated with an odontohypophosphatasia phenotype, *Bone* 56 (2) (2013) 390–397, <https://doi.org/10.1016/j.bone.2013.06.010>.
- [7] M.P. Whyte, C.R. Greenberg, N.J. Salman, M.B. Bober, W.H. McAlister, D. Wenkert, et al., Enzyme-replacement therapy in life-threatening hypophosphatasia, *N. Engl. J. Med.* 366 (10) (2012) 904–913, <https://doi.org/10.1056/NEJMoa1106173>.
- [8] M.P. Whyte, F. Zhang, D. Wenkert, W.H. McAlister, K.E. Mack, M.C. Benigno, et al., Hypophosphatasia: validation and expansion of the clinical nosology for children from 25 years experience with 173 pediatric patients, *Bone* 75 (2015) 229–239, <https://doi.org/10.1016/j.bone.2015.02.022>.
- [9] T. Tanaka, A. Yamashita, K. Ichihara, Reference intervals of clinical tests in children determined by a latent reference value extraction method (in Japanese), *J. Jpn. Pediatr. Soc.* 112 (2008) 1117–1132.
- [10] T. Akiyama, Y. Hayashi, Y. Hanaoka, T. Shibata, M. Akiyama, H. Tsuchiya, et al., Pyridoxal 5'-phosphate, pyridoxal, and 4-pyridoxic acid in the paired serum and cerebrospinal fluid of children, *Clin. Chim. Acta* 472 (2017) 118–122, <https://doi.org/10.1016/j.cca.2017.07.032>.
- [11] H.C. Williams, *Clinical practice. Atopic dermatitis*, *N. Engl. J. Med.* 352 (22) (2005) 2314–2324.
- [12] D. Wenkert, W.H. McAlister, S.P. Coburn, J.A. Zerega, L.M. Ryan, K.L. Ericson, et al., Hypophosphatasia: nonlethal disease despite skeletal presentation in utero (17 new cases and literature review), *J. Bone Miner. Res.* 26 (10) (2011) 2389–2398, <https://doi.org/10.1002/jbmr.454>.
- [13] H. Orimo, Z. Hayashi, A. Watanabe, T. Hirayama, T. Shimada, Novel missense and frameshift mutations in the tissue-nonspecific alkaline phosphatase gene in a Japanese patient with hypophosphatasia, *Hum. Mol. Genet.* 3 (9) (1994) 1683–1684.
- [14] E. Mornet, A. Taillandier, S. Peyramaure, F. Kaper, F. Muller, R. Brenner, et al., Identification of fifteen novel mutations in the tissue-nonspecific alkaline phosphatase (TNSALP) gene in European patients with severe hypophosphatasia, *Eur. J. Hum. Genet.* 6 (4) (1998) 308–314.
- [15] K. Ozono, M. Yamagata, T. Michigami, S. Nakajima, N. Sakai, G. Cai, et al., Identification of novel missense mutations (Phe310Leu and Gly439Arg) in a neonatal case of hypophosphatasia, *J. Clin. Endocrinol. Metab.* 81 (12) (1996) 4458–4461.
- [16] B. Chen, L. Li, W. Ren, L. Yi, Y. Wang, F. Yan, A novel missense mutation in the ALPL gene causes dysfunction of the protein, *Mol. Med. Rep.* 16 (1) (2017) 710–718, <https://doi.org/10.3892/mmr.2017.6668>.
- [17] T. Michigami, T. Uchihashi, A. Suzuki, K. Tachikawa, S. Nakajima, K. Ozono, Common mutations F310L and T1559del in the tissue-nonspecific alkaline phosphatase gene are related to distinct phenotypes in Japanese patients with hypophosphatasia, *Eur. J. Pediatr.* 164 (5) (2005) 277–282.
- [18] G. Del Angel, E. Mornet, J. Reynders, Combining large-scale in vitro functional testing with protein stability simulations to develop new insights into hypophosphatasia genotype/phenotype correlation, *Abstract ASHG*, 2018.
- [19] E.T. Rush, Childhood hypophosphatasia: to treat or not to treat, *Orphanet. J. Rare. Dis.* 13 (2018) 116, <https://doi.org/10.1186/s13023-018-0866-7>.
- [20] M.P. Whyte, J.H. Simmons, S. Moseley, K.P. Fujita, N. Bishop, N.J. Salman, et al., Asfotase alfa for infants and young children with hypophosphatasia: 7 year outcomes of a single-arm, open-label, phase 2 extension trial, *Lancet Diabetes Endocrinol.* 7 (2) (2019) 93–105, [https://doi.org/10.1016/S2213-8587\(18\)30307-3](https://doi.org/10.1016/S2213-8587(18)30307-3).
- [21] P.S. Kishnani, C. Rockman-Greenberg, F. Rauch, M.T. Bhatti, S. Moseley, A.E. Denker, et al., Five-year efficacy and safety of asfotase alfa therapy for adults and adolescents with hypophosphatasia, *Bone* 121 (2019) 149–162, <https://doi.org/10.1016/j.bone.2018.12.011>.
- [22] A.S. Lia-Baldini, F. Muller, A. Taillandier, J.F. Gibrat, M. Mouchard, B. Robin, et al., A molecular approach to dominance in hypophosphatasia, *Hum. Genet.* 109 (1) (2001) 99–108.
- [23] E. Mornet, E. Stura, A.S. Lia-Baldini, T. Stigbrand, A. Menez, M.H. Le Du, Structural evidence for a functional role of human tissue nonspecific alkaline phosphatase in bone mineralization, *J. Biol. Chem.* 276 (33) (2001) 31171–31178.
- [24] D. Fauvert, I. Brun-Heath, A.S. Lia-Baldini, L. Bellazi, A. Taillandier, J.L. Serre, et al., Mild forms of hypophosphatasia mostly result from dominant negative effect of severe alleles or from compound heterozygosity for severe and moderate alleles, *BMC Med. Genet.* 10 (2009) 51, <https://doi.org/10.1186/1471-2350-10-51>.