

Hypospadias repair during adulthood: Case series

Waleed M. AlTaweel, Raouf M. Seyam

Department of Urology, King Faisal Specialist Hospital and Research Center, Riyadh, Saudi Arabia

Abstract

Purpose: We report our complications and success rate in adult hypospadias repair.

Patients and Methods: This was a retrospective study of patients aged ≥ 17 years who underwent hypospadias repair during 2006–2014. We analyzed two groups, one with primary repair and the other that had secondary repair after failed childhood hypospadias surgery. Outcome was compared between the two groups and among different surgical procedures. Descriptive statistics and Fisher's exact test were used and significance level was set at $P < 0.05$.

Results: Forty patients were included, of which 26 presented for a secondary repair and 14 for primary repair. The meatus was distal in 15 patients, mid-penile in 16, and penoscrotal in 9. The median age of patients at the time of surgery was 21 years (standard deviation [SD] = 4, range 17–30). The median follow-up period was 37 months (SD = 8, range 5–75). In the primary repair group, the success rate was 71% (10/14), whereas in the secondary repair group, the success rate was 55% (14/26). The overall complication rate was 60%. Following a subsequent repair, the overall success rate reached 95% (38/40). There was no significant difference in success or complications between patients who presented with primary or secondary hypospadias or between methods of repair.

Conclusion: Delayed hypospadias repair in adults is associated with a high success rate of 95% with no difference between primary and secondary repair. Secondary repair however may require more than one procedure most of the time.

Keywords: Adult, complications, hypospadias, surgery

Address for correspondence: Prof. Waleed M. AlTaweel, Department of Urology, King Faisal Specialist Hospital and Research Centre, P.O. Box: 3354, Riyadh 11211, Saudi Arabia.

E-mail: drwt1@hotmail.com

Received: 06.04.2017, **Accepted:** 26.05.2017

INTRODUCTION

Hypospadias is defined as an insufficient development of the urethral fold and the ventral foreskin of the penis, with or without penile curvature.^[1,2] It affects at least 1 in 300 newborn males.^[3–6] Correction of such anomaly is done to achieve cosmesis and fertility and allow voiding while standing.^[3,7,8] Surgical repair is usually done early in life and has a significant impact on the urinary and sexual function in

adult life.^[1,9,10] The success of a surgical repair is influenced by tissue quality and vascular supply which may be affected by the patient's age and previous failed surgical repair.^[11–13]

Occasionally, some children are not treated and present with such anomaly in adulthood. Those subsets of patients are treated in the same surgical approach as in children. The reported complication rate is of hypospadias repair in adulthood ranges 10%–37%.^[14,15] Another subset of patients is those who were repaired during childhood and present with complications

Access this article online	
Quick Response Code:	Website: www.urologyannals.com
	DOI: 10.4103/UA.UA_54_17

This is an open access article distributed under the terms of the Creative Commons Attribution-NonCommercial-ShareAlike 3.0 License, which allows others to remix, tweak, and build upon the work non-commercially, as long as the author is credited and the new creations are licensed under the identical terms.

For reprints contact: reprints@medknow.com

How to cite this article: AlTaweel WM, Seyam RM. Hypospadias repair during adulthood: Case series. *Urol Ann* 2017;9:366-71.

in adulthood. These patients are considered a challenge to treat as they have poor tissue quality and vascular supply. The reported complication rate is 27%–63%.^[14,15] As a result of such reported higher complication rate, some advocated for subglanular repair.^[16] Although timing of hypospadias repair is recommended in early childhood, different opinions exist on the surgical success and complication rates between adults and children. While several investigators reported a higher complication rate in adult hypospadias surgery, others did not find a significant difference using the same surgical techniques between the two age groups.^[15,17-20]

In this study, we report the outcomes of a series of patients who underwent primary and secondary hypospadias repair in adulthood and compare surgical success rate with published series.

PATIENTS AND METHODS

After Institutional Review Board approval, a retrospective study was performed for all patients older than 17 years who underwent hypospadias repair from January 2006 to December 2014.

Data reviewed were the patient's demographic information, presenting complaint, and site of hypospadias, history of previous repair, type of surgery performed, and outcome. We utilized the Snodgrass repair of tubularized incised plate (TIP) procedure or two-stage buccal mucosa grafting technique.^[21,22] The choice of surgical techniques used in repair was influenced by meatus location, urethral plate appearance, and genital skin available for urethroplasty and wound closure. In postoperative follow-up, we reviewed the patient's progress for their improvement in symptoms including urinary stream, cosmetic appearance, and any complication of surgery. The penis was examined for meatus position and size, fistula, and chordee. Success rate was defined as a functional urethra without fistula, stricture or residual chordee, and a cosmetically acceptable glanular meatus.

Success rates were compared between primary versus secondary repair and complication rate between groups. Two-tailed Fisher's exact test was used and $P < 0.05$ was considered statistically significant.

RESULTS

Forty patients were included, of which 26 presented for a secondary repair after failed surgery in childhood. These failures included residual hypospadias, fistula, meatal stenosis, urethral stricture, and penile curvature. The remaining 14 patients presented for primary repair in adulthood. These patients chose to defer surgical treatment

to a later date. Table 1 shows the association between the type of meatal location and type of presentation. The median age of patients at the time of surgery was 21 years (standard deviation [SD] = 4, range 17–30). All procedures were done by the same surgical team. The median follow-up period was 37 months (SD = 8, range 5–75).

The progress of surgical repair is shown in Figure 1. TIP repair was done in 28 (14 primary and 14 secondary) patients, two-stage buccal graft repair in 11 patients, and two-stage skin graft in one patient [Table 2]. The most common complications were fistula, suture line breakdown, wound infection, and stricture formation. In the primary repair group, the success rate was 71% (10/14). The four failed cases were subjected to a second surgery in the form of two-stage buccal graft, and the resulting success rate was 100% (4/4). Patients who presented with secondary hypospadias had a success rate of 55% (14/26) after first surgery. Following a subsequent repair, successful results were achieved in 8 out of 12 repairs. The remaining four patients had a final surgery with only two achieving successes. The overall success rate for adult hypospadias repair was 95% (38/40).

Primary versus secondary hypospadias repair

Success after first surgery (TIP) was not significantly different between patients who presented with primary or secondary hypospadias [Table 2]. After subsequent surgeries, the difference in success between the two groups remained insignificant. Complications were not significantly different between primary and secondary hypospadias repair using the TIP procedure [Table 3].

Tubularized incised plate versus two-stage repair

TIP success after first surgery was 18/28 (64.3%), which was not significantly different from that of first two-stage repair (6/12, 50%, $P = 0.473$). Comparing overall complications between TIP and grafting showed borderline insignificant difference. The subset of complications that was significantly higher in grafting was the infection rate [Table 3].

DISCUSSION

Timing of repair

The current recommendation for timing of primary hypospadias repair is during infancy.^[8,23] Several

Table 1: Location of hypospadias at presentation

Location of meatus	n (%)	Type of presentation	
		Primary	Secondary
Distal	15 (37)	4	11
Mid penile	16 (40)	4	12
Proximal (penoscrotal)	9 (23)	6	3

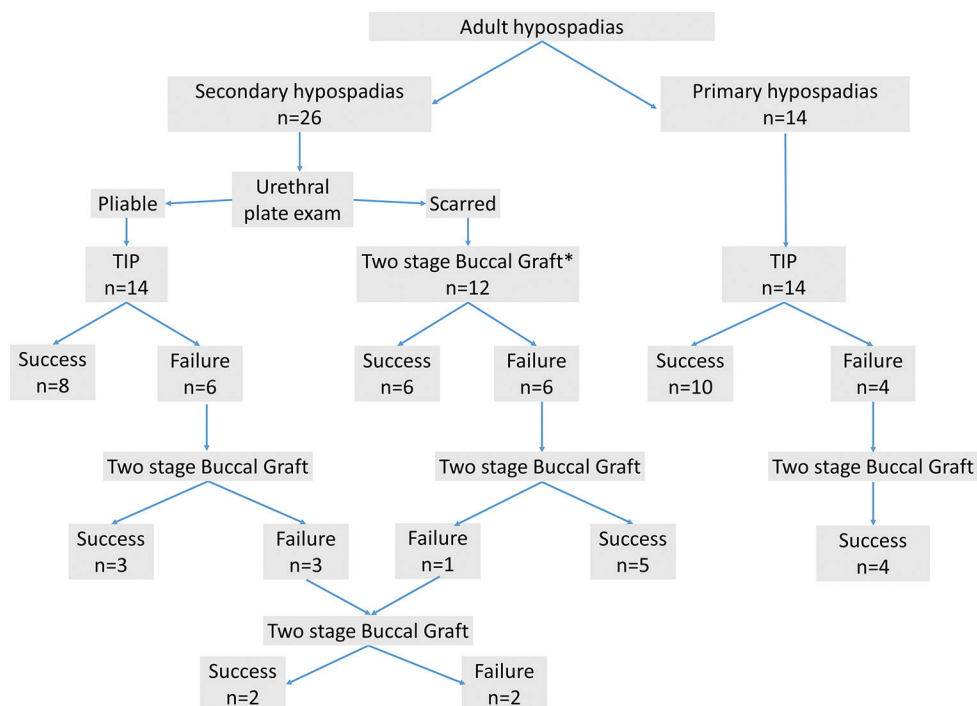


Figure 1: Flow sheet of surgical procedures. *One case of two-stage skin graft

Table 2: Type of hypospadias repair and success

Groups	TIP		Two stage buccal graft*		Total patients Success, n (%)	P
	Success first surgery, n (%)	P	Cumulative success, n (%)	P		
Primary hypospadias	10/14 (71.4)	0.695	14/14 (100)	1.0	14/14 (100)	0.533
Secondary hypospadias	8/14 (57.1)		13/14 (92.9)		6/12 (50)	11/12 (91.7)
Total	18/28 (64.3)		27/28 (96.4)		6/12 (50)	11/12 (91.7)

Fisher’s exact test, two-tailed. *One case of two-stage skin graft. TIP: Tubularized incised plate

Table 3: Complications

Complication	Total number of patients (%)	TIP		P	Total (n=28)	Grafting		Total (n=12)	P*
		Primary hypospadias (n=14)	Secondary hypospadias (n=14)			Primary hypospadias (n=0)	Secondary hypospadias (n=12)		
Fistula	8 (20)	2	3	1	5	-	3	3	0.677
Breakdown	7 (17)	2	5	0.385	7	-	0	0	0.081
Infection	5 (17)	0	1	1	1	-	4	4	0.022
Stricture	4 (10)	0	1	1	1	-	3	3	0.073
Overall	24 (60)	4	10		14	-	10	10	0.079

Fisher’s exact test, two-tailed. *Comparison between total TIP and total grafting. TIP: Tubularized incised plate

reports showed that in adult patients, there is clearly a less favorable outcome in terms of wound healing, infection, complication rates, and overall success.^[15,17,18] Dodson *et al.* reported that delay of primary repair to adolescence or older age was associated with an unacceptable outcome.^[17] In patients 17 years or older, only four out of eight patients had a successful primary repair. Hensle *et al.* reported a higher complication rate involving 38% of adult patients who had a primary repair although the techniques used to repair hypospadias in adults were similar to those used in children.^[15] They attributed the higher complication rate to difference in wound healing and infection rate.

Histological changes in the skin that develop with aging may explain the less favorable outcome of surgery in adults. da Silva *et al.* described age-related changes in the human urethral plate in patients operated on for hypospadias.^[24] They reported that the extracellular matrix of the older urethral plates had more abundant collagen content (Types I and III), rare elastic fibers, fewer cells, and absent vascular sinusoids. There was a significant increase in total collagen concentration with aging.

Our overall complication rate is high reaching 60% which is comparable to reported series.^[25] However, with proper

management and subsequent surgery, the overall success rate markedly increased. In the adult patient, erection and hematoma formation were responsible for high complication rate approaching 50% in the early experience in treating hypospadias using local skin flaps, free skin grafts, advancement of the urethra, and preputial island flap techniques.^[26] We had, at the beginning of our experience, more breakdown of suture and fistula due to strong nocturnal erection and use of Foley catheter bag which exerted a pulling effect on the repair. To mitigate these factors, we treated patients with antiandrogen bicalutamide for 2 weeks before surgery and 1 week postoperatively to prevent nocturnal erection. We avoided using Foley catheter bag replacing it with a catheter clamp and frequent bladder emptying.

On a different note, some recent reports showed no difference between repair in children and adults. In a small study group, Sharma reported a good result using TIP procedure. Despite the fact that it was only 13 adult patients included in this study, he concluded that there is no difference in terms of wound healing, infection, complication rates, and overall success between the TIP repair in children and adults.^[19] Another recent report from Snodgrass *et al.* on a large series of men treated with hypospadias surgery concluded that there were no differences in outcomes between adults and children.^[20] Complications were noted in 12.5% versus 14% with primary repair and in 26% versus 35% with reoperation. However, the authors reported that patients were relatively young and therefore not likely to have vascular disease that would impact wound healing, which might be more prevalent in an older cohort.

Our study did not include pediatric patients; therefore, a direct comparison in success rates between adults and children was not possible. However, we report an overall success rate for primary and secondary hypospadias repair of 95% which is comparable to published series and in agreement with the opinion that adult hypospadias repair is comparable in success rate to pediatric procedures.^[15,19,20,27] The overall success rate of repair of primary hypospadias (100%) and secondary hypospadias (92.3%) was not significantly different [Table 2]. Even after the first attempt for surgical repair, the success rate remained not statistically significant (71.4% vs. 57.1%, respectively).

Primary versus secondary repair

Adult patients previously treated with surgery for hypospadias during childhood present with various complications including urethral stricture, persistent

hypospadias, urethrocutaneous fistula, diverticulum, urethral calculi, obstruction from hair-bearing skin, and chordee.^[25] The number and complexity of surgeries these patients had previously are usually staggering. In a report of failed hypospadias repair, a total of 1176 patients in two tertiary European centers had a median of three operations to repair primary hypospadias while almost 10% of patients required five or more operations.^[27] These patients remain a challenge for reconstruction in adulthood.^[25] After a mean follow-up of 33.8 months in 60 cases of adult hypospadias, Barbagli *et al.* reported a high failure rate and complications. They reported that 36% of the patients had one complication and 64% had two or more complications.^[25] Diligent follow-up and subsequent interventions may markedly improve outcome in those patients. Using one-stage and multistage repair, Barbagli *et al.* subsequently reported a 5-year overall success rate of 88% in patients with a mean age of 31 years at the time of evaluation and treatment for failed hypospadias repair.^[27]

In our study, we had 71% success in primary hypospadias after the first surgery using the TIP procedure; however, we achieved 100% success rate after the subsequent surgery using two-stage buccal graft. In secondary hypospadias, we achieved 50%–57% success after one surgery and reached 92%–93% success after subsequent surgery depending on the technique. This excellent outcome was a result of a meticulous effort to maintain good vascularity in the surgical field utilizing the ventral penile shaft skin and the ventral dartos.

Variability of surgical technique

We opted to limit surgical repair to only two procedures, the TIP technique whenever possible and two-stage buccal mucosal graft in complicated cases. Studies which utilized numerous variations of techniques for delayed hypospadias repair reported a high complication rate. In a group of 31 patients, Dodson *et al.* used procedures of meatal-based flaps, meatoplasty and glanuloplasty, island onlay flaps, staged procedures, Snodgrass repair, and others. The authors reported a 48% complication rate at a median follow-up of 14 months.^[17] Similarly, Hensle *et al.* reported for adult hypospadias Thiersch-Duplay repair, Mathieu procedure, island pedicle tube graft; island pedicle onlay, buccal mucosal onlay graft; bladder mucosal tube, buccal mucosal tube, and buccal mucosal onlay. These procedures were associated with high primary complication rate of 52.3%. Longer follow-up however resulted in an overall long-term success in 88.1%.^[15]

Limiting the number of selected surgical procedures may result in a better outcome. In a large series of failed

childhood hypospadias repair, Barbagli *et al.* reported one-stage or two-stage reconstruction in 926 patients older than 16 years.^[27] The most common procedures used for single stage repair were fistula closure, one-stage oral mucosa graft, and skin flap. The most common procedures carried for staged repair were oral mucosa graft, glans reconstruction, and skin reconstruction. Patients of this age group constituted 78.8% of the whole series which had an overall success rate of 88.1%.

Limiting the surgical options for our patients was associated with a favorable outcome. We report a high success rate of 95% at a median follow-up of 3 years. Other factors may have contributed to the high success rate and are repeated surgical correction of failed cases, prevention of nocturnal erections, and avoiding the use of collecting urine bag.

We utilized the TIP procedure whenever feasible in repair of primary and secondary hypospadias with a success rate of 64.3% after one surgery. This is in contrast with reports of TIP repair having more than 92% success rates in a small group of adults when used for primary repair.^[19] TIP urethroplasty can be used for hypospadias reoperation. Previous incision of the urethral plate was not a contraindication when the plate appeared supple; however, TIP repair should be avoided in repeat hypospadias surgery if the plate has been resected or is obviously scarred.^[28] Our results indicate that with proper selection of cases for secondary repair, there is no significant difference in success rate as compared to primary repair [Table 2].

Repeated surgery increases the likelihood of recurrent fistula and stricture formation, mainly because the ventral penile shaft skin is less well vascularized and the ventral dartos is deficient in hypospadias. We required up to four surgeries in the redo patients to achieve satisfactory results. Buccal graft was used to treat 11 patients with poor urethral plate vascularity and bad scarring. We graft the glans cleft with a patch of buccal mucosa and neo-urethral graft used after we excise the unsatisfactory urethra and put on a large graft of buccal mucosa.

CONCLUSION

Adult hypospadias repair is a challenging situation. Delayed hypospadias repair in adults is associated with a high success rate of 95% with no difference between primary and secondary repair. Secondary repair however may require more than one procedure most of the time.

Financial support and sponsorship

Nil.

Conflicts of interest

There are no conflicts of interest.

REFERENCES

1. Bracka A. Sexuality after hypospadias repair. *BJU Int* 1999;83 Suppl 3:29-33.
2. Jiao C, Wu R, Xu X, Yu Q. Long-term outcome of penile appearance and sexual function after hypospadias repairs: Situation and relation. *Int Urol Nephrol* 2011;43:47-54.
3. Backus LH, Defelice CA. Hypospadias – Then and now. *Plast Reconstr Surg Transplant Bull* 1960;25:146-60.
4. Wolffenbuttel KP, Wondergem N, Hoefnagels JJ, Dieleman GC, Pel JJ, Passchier BT, *et al.* Abnormal urine flow in boys with distal hypospadias before and after correction. *J Urol* 2006;176(4 Pt 2):1733-6.
5. Baskin LS. Hypospadias and urethral development. *J Urol* 2000;163:951-6.
6. Thomas DF. Hypospadiology: Science and surgery. *BJU Int* 2004;93:470-3.
7. Avellán L. The development of puberty, the sexual début and sexual function in hypospadias. *Scand J Plast Reconstr Surg* 1976;10:29-44.
8. Manzoni G, Bracka A, Palminteri E, Marrocco G. Hypospadias surgery: When, what and by whom? *BJU Int* 2004;94:1188-95.
9. Rynja SP, de Jong TP, Bosch JL, de Kort LM. Functional, cosmetic and psychosexual results in adult men who underwent hypospadias correction in childhood. *J Pediatr Urol* 2011;7:504-15.
10. Baskin LS, Ebbers MB. Hypospadias: Anatomy, etiology, and technique. *J Pediatr Surg* 2006;41:463-72.
11. Retik AB, Atala A. Complications of hypospadias repair. *Urol Clin North Am* 2002;29:329-39.
12. Snodgrass W, Koyle M, Manzoni G, Hurwitz R, Caldamone A, Ehrlich R. Tubularized incised plate hypospadias repair: Results of a multicenter experience. *J Urol* 1996;156(2 Pt 2):839-41.
13. Ross JH, Kay R. Use of a de-epithelialized local skin flap in hypospadias repairs accomplished by tubularization of the incised urethral plate. *Urology* 1997;50:110-2.
14. Senkul T, Karademir K, Iseri CN, Erden DO, Baykal K, Adayener CN. Hypospadias in adults. *Urology* 2002;60:1059-62.
15. Hensle TW, Tennenbaum SY, Reiley EA, Pollard J. Hypospadias repair in adults: Adventures and misadventures. *J Urol* 2001;165:77-9.
16. Armenakas NA, Morey AF, McAninch JW. Reconstruction of resistant strictures of the fossa navicularis and meatus. *J Urol* 1998;160:359-63.
17. Dodson JL, Baird AD, Baker LA, Docimo SG, Mathews RI. Outcomes of delayed hypospadias repair: Implications for decision making. *J Urol* 2007;178:278-81.
18. Forster FM. The first examination in obstetrics and gynaecology in Australia. *Aust N Z J Obstet Gynaecol* 1965;5:186-9.
19. Sharma G. Tubularized-incised plate urethroplasty in adults. *BJU Int* 2005;95:374-6.
20. Snodgrass W, Villanueva C, Bush N. Primary and reoperative hypospadias repair in adults – Are results different than in children? *J Urol* 2014;192:1730-3.
21. Snodgrass WT. Snodgrass technique for hypospadias repair. *BJU Int* 2005;95:683-93.
22. Snodgrass W, Elmore J. Initial experience with staged buccal graft (Bracka) hypospadias reoperations. *J Urol* 2004;172(4 Pt 2):1720-4.
23. Timing of elective surgery on the genitalia of male children with particular reference to the risks, benefits, and psychological effects of surgery and anesthesia. *American Academy of Pediatrics. Pediatrics* 1996;97:590-4.
24. da Silva EA, de Marins RL, Rondon A, Damião R. Age-related structural changes of the urethral plate in hypospadias. *J Pediatr Urol* 2013;9(6 Pt B):1155-60.
25. Barbagli G, De Angelis M, Palminteri E, Lazzari M. Failed hypospadias repair presenting in adults. *Eur Urol* 2006;49:887-94.

26. Baran CN, Tiftikcioglu YO, Ozdemir R, Baran NK. What is new in the treatment of hypospadias? *Plast Reconstr Surg* 2004;114:743-52.
27. Barbagli G, Perovic S, Djinovic R, Sansalone S, Lazzeri M. Retrospective descriptive analysis of 1,176 patients with failed hypospadias repair. *J Urol* 2010;183:207-11.
28. Snodgrass WT, Lorenzo A. Tubularized incised-plate urethroplasty for hypospadias reoperation. *BJU Int* 2002;89:98-100.