

Emphysematous cholecystitis in a young male without predisposing factors

A case report

Ming-Yu Chen, MD, Chen Lu, MD, Yi-fan Wang, MD, Xiu-Jun Cai, MD, PhD*

Abstract

This report describes the diagnosis and treatment for Emphysematous cholecystitis (EC) without predisposing factors, and reviews the current literature.

A 49-year-old male without predisposition presented to emergency department with a two-day history of sudden onset abdominal pain, hypertension and received empirical antibiotics with Imipenem/Cilastatin 0.5 g via intravenous route every 8 hours. Computed tomography (CT)-scan revealed that air encircling gallbladder is the most important and accurate evidence for EC diagnosis.

Laparoscopic cholecystectomy was performed, and no stone was seen in gallbladder.

The patient's temperature and pulses returned to normal following laparoscopic cholecystectomy. The festering bile culture report showed *E.coli* and pathological analysis of the resected gallbladder disclosed that necrosis and mild mucosal dysphasia. The patient fully recovered without complication at outpatient clinic visit three months later.

The EC is an acute infection of the gallbladder wall caused by gas-forming organisms, is a life-threatening cholecystitis with mortality rate as high as 25%. Therefore, the combination of laparoscopic cholecystectomy and antibiotics is recommended as soon as possible once the diagnosis of EC was a clean-cut.

Abbreviations: CT = computed tomography, EC = emphysematous cholecystitis, LC = laparoscopy, NA = unknown, PTGBD = percutaneous transhepatic gallbladder drainage.

Keywords: emphysematous cholecystitis, laparoscopic cholecystectomy, predisposing factors

1. Introduction

Emphysematous cholecystitis (EC) is one of the most life-threatening forms of acute cholecystitis, with low morbidity, averaging from 1% to 3%. However, the mortality rate is as high as 25%.^[1] Presentation of EC with metabolic disorders such as diabetes mellitus, and immunosuppressed and peripheral vascular disease is common,^[2] but diagnosis is rather difficult. Patients

usually present with sudden-onset right upper quadrant pain in the abdomen, fever, vomiting, and jaundice. Hence, it is very challenging to distinguish EC from gallstone-related acute cholecystitis or acute obstructive suppurative cholangitis (AOSC) based on symptoms and signs. Imaging showing gas in gallbladder walls or lumen is the most important and accurate clinical characteristic for diagnosing of EC.^[3] There is no doubt that the postoperative pathological analysis of resected gallbladder is the gold standard, yet it cannot provide us any indications before the operation. There are few literatures reported (Table 1); therefore, we decided to share our experience in the diagnosis and treatment of EC.

2. Case presentation

A 49-year-old male presented to the emergency department at the Sir Run Run Shaw Hospital, China, complaining of a 2-day history of sudden-onset nonradiating abdominal pain in the right upper quadrant with Murphy sign, muscular defense of the upper abdomen, fever (38.5–39°C) without vomiting, or jaundice. The patient did not have a history of diabetes mellitus, immunosuppressed, peripheral vascular disease, or hepatic disease. Although his blood pressure was 150/85 mm Hg, pulse of 120 per minute, the respiratory rate was normal at 19 per minute. The result of a computed tomography (CT)-scan revealed air encircling the gallbladder and intrahepatic bile duct without gallstones (Fig. 1). The patient was then prescribed with empirical antibiotics imipenem/cilastatin 0.5 g by intravenous infusion every 8 hours. Emergency laparoscopy was performed. Around 10 mL of gas and festering bile was collocated by needle to culture, determining

Editor: Perbinder Grewal.

Author contributors: MYC cared for the patient; CL performed the study; MYC, CL, YFW, and XJC interpreted the data and helped in writing the report.

The authors have no funding and conflicts of this case report.

Ethical statement: All procedures in this study have been approved by the ethical standards on human experimentation by the Sir Run Run Shaw Hospital committee, and performed according to the guidelines of the Helsinki Declaration of 2008.

Department of General Surgery, Sir Run Run Shaw Hospital, College of Medicine, Zhejiang University, Hangzhou, Zhejiang Province, China.

* Correspondence: Xiu-Jun Cai, Department of General Surgery, Sir Run Run Shaw Hospital, College of Medicine, Institute of Minimally Invasive Surgery, Zhejiang University, No. 3 East Qingchun Road, Hangzhou 310016, Zhejiang Province, China (e-mail: caixiujunzju@163.com).

Copyright © 2016 the Author(s). Published by Wolters Kluwer Health, Inc. All rights reserved.

This is an open access article distributed under the Creative Commons Attribution License 4.0 (CCBY), which permits unrestricted use, distribution, and reproduction in any medium, provided the original work is properly cited.

Medicine (2016) 95:44(e5367)

Received: 18 July 2016 / Received in final form: 14 October 2016 / Accepted: 17 October 2016

<http://dx.doi.org/10.1097/MD.0000000000005367>

Table 1
Review of case report of emphysematous cholecystitis without predisposing factors.

Author, year	Age	Sex	Stone	Culture	Operation/survival	Antibiotics
Sayit and Gunbey ^[4] , 2015	24	M	Yes	NA	LC/yes	NA
Huang et al ^[5] , 2012	54	M	Yes	<i>Clostridium baratii</i>	LC/yes	NA
Safioleas et al ^[6] , 2007	80	F	—	<i>Clostridium difficile</i>	PTGBD/no	NA
Lse et al ^[7] , 2002	72	M	—	NA	LC/yes	NA
Yoshida ^[8] et al, 1998	67	F	—	<i>Escherichia coli</i>	LC/yes	-
Tooms and Barlow ^[9] , 1955	63	M	—	NA	NA/yes	NA

LC=laparoscopy, NA=Not available, PTGBD=percutaneous transhepatic gallbladder drainage.

the presence of gas-forming organisms causing acute cholecystitis. Laparoscopic cholecystectomy showed no gallstones. The resected gallbladder was delivered for pathological analysis. The patient’s temperature and pulses returned to normal after laparoscopic cholecystectomy. The festering bile culture report was *Escherichia coli* and pathological analysis of the resected gallbladder showed that necrosis and mucosal dysplasia graded mild (Fig. 2). Three months at follow-up, the patient was fully functional without complication.

3. Discussion

Emphysematous cholecystitis is a rare variant of acute infection of the gallbladder wall caused by gas-forming organisms. Stoltz et al^[10] reported the first case of EC in 1990, and Garcia-Sancho et al^[11] described and reported its clinical features with mortality rates up to 25% and the morbidity rates up to 50%, which are much higher in complicated patients compared with uncomplicated patients (1%–3% and 15%, respectively).^[1,11,12] There are

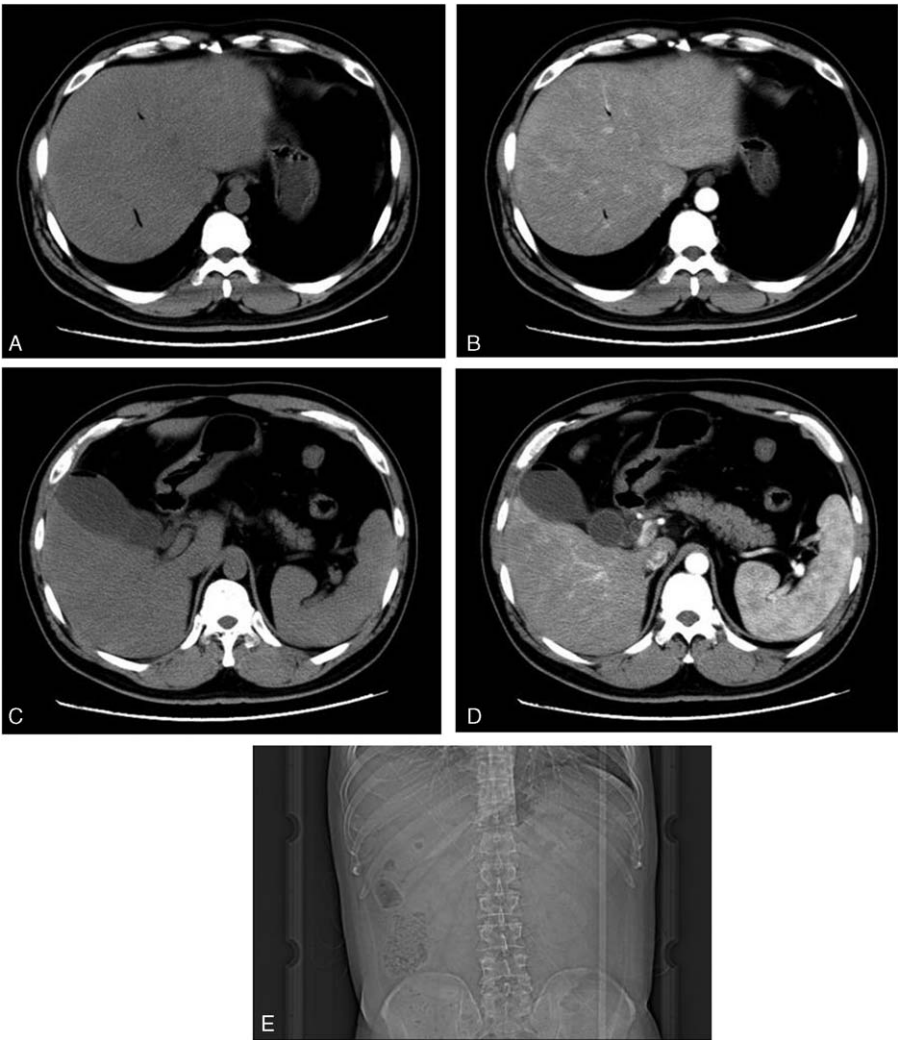


Figure 1. Computed tomography (CT)-scan (A-D) and plain-film radiography (E) showing air in the gallbladder wall or lumen.

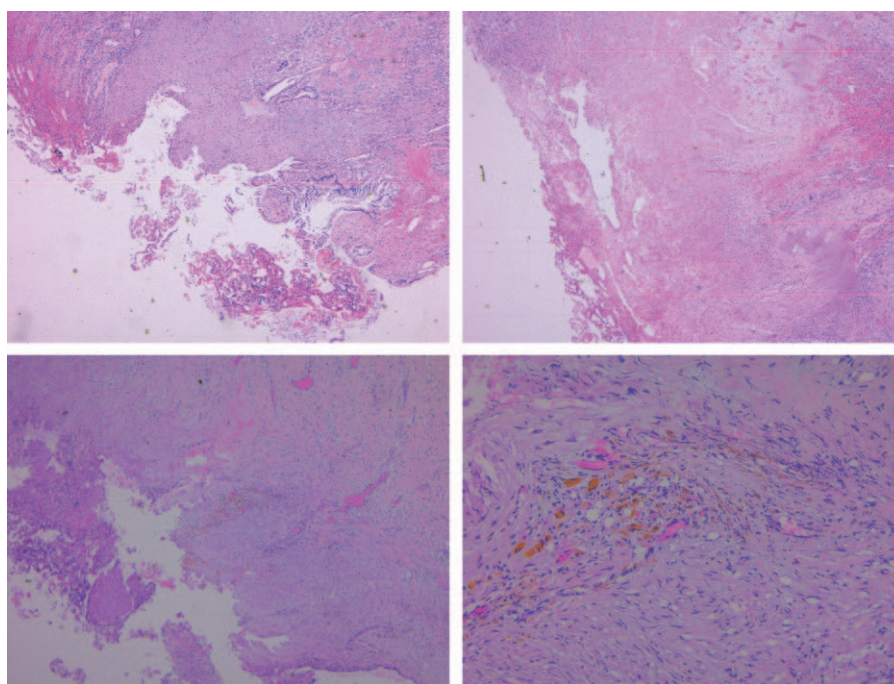


Figure 2. Pathologic analysis of the resected gallbladder.

various predisposing factors including diabetes mellitus, immunosuppression, peripheral vascular disease,^[2] abdominal surgery, and trauma.^[4] EC is particularly common in older patients with diabetes mellitus because ischemia environments in diabetic patients reduce phagocytes' mobility in the areas of infection and further reduce antimicrobial activity.^[13] Appropriate glycemic control can lower the likelihood of bacterial overgrowth and associated disease severity. In our case, the patient was 49 years old without diabetes, which made the diagnosis a bit more difficult and arduous.

There are some differences between EC and gallstone-related acute cholecystitis in its pathophysiology and epidemiology.^[14] The symptoms of EC are almost identical with those of acute cholecystitis, right upper quadrant pain, fever, vomiting, and jaundice, but EC begins as acute cholecystitis, then develops into ischemia and gangrene in the gallbladder wall with gas encircling the gallbladder due to gas-forming organisms, including *E coli*, *Clostridium welchii*, *Perfringens*, *Klebsiella*, and *Streptococci*.^[1,3,7,15,16] Hence, gas encircling the gallbladder or air within the gallbladder becomes the typical presentation of EC from the CT-scan.^[3,14] Of courses, ultrasonography (USG) and plain radiography can also be used for the diagnosis of EC. However, USG, which almost depends on the number of air pockets and on localization in the soft tissues, is an operator-dependent and less sensitive technique,^[12,17] whereas a gaseous halo around the gallbladder and gas-fluid level in the gallbladder can be shown more clearly by plain radiography and CT-scan. Moreover, CT-scan can detect pericholecystic edema and exclude other differential diagnosis.^[18] In a word, the imaging of CT-scan presenting gas encircling the gallbladder wall or lumen is the most important and accurate clinical characteristic for EC. CT-scan is the first choice for us to differentially diagnosing possibilities including AOSC, perforation, and acute pancreatitis.

In addition, laboratory examination consisting of C-reactive protein and liver function [aspartate aminotransferase (AST) and

alanine aminotransferase (ALT)] cannot be neglected. The pus and blood culture also contribute to the diagnosis. Broad-spectrum antibiotics should be used to prevent worsening infection, and continued until blood and pus culture is reported. Then, according to aerobic culture report, we should switch to the antibiotics that bacteria are sensitive to.

Reviewing published literature, the broad-spectrum antibiotics and adequate surgical interventions should be taken into practice as soon as possible.^[3,18,19] The laparoscopic cholecystectomy is recommended as an effective and safe approach.^[15] If the doctor is unable to perform laparoscopic cholecystectomy, the gallbladder drainage can be considered.

4. Conclusions

Emphysematous cholecystitis is an unusual life-threatening variant of acute infection of the gallbladder wall caused by gas-forming organisms. The imaging of CT-scan presenting gas encircling gallbladder wall or lumen is the most important and accurate method for differential diagnosis. The combination of laparoscopic cholecystectomy and antibiotics is regarded as an effective and safe approach on treatment of EC.

References

- [1] Garcia-Sancho TL, Rodriguez-Montes JA, Fernandez DLS, et al. Acute emphysematous cholecystitis. Report of twenty cases. *Hepatogastroenterology* 1999;46:2144–8.
- [2] Choi HS, Lee YS, Park SB, et al. Simultaneous emphysematous cholecystitis and emphysematous pancreatitis: a case report. *Clin Imaging* 2010;34:239–41.
- [3] Liao CY, Tsai CC, Kuo WH, et al. Emphysematous cholecystitis presenting as gas-forming liver abscess and pneumoperitoneum in a dialysis patient: a case report and review of the literature. *BMC Nephrol* 2016;17:23.
- [4] Sayit AT, Gunbey HP. Emphysematous cholecystitis in 24-year-old male without predisposing factors. *J Clin Diagn Res* 2015;9:D1–2.

- [5] Huang WC, Lee WS, Chang T, et al. Emphysematous cholecystitis complicating liver abscess due to *Clostridium baratii* infection. J Microbiol Immunol Infect 2012;45:390–2.
- [6] Safioleas M, Stamatakis M, Kanakis M, et al. Soft tissue gas gangrene: a severe complication of emphysematous cholecystitis. Tohoku J Exp Med 2007;213:323–8.
- [7] Ise N, Andoh H, Furuya T, et al. Acute emphysematous cholecystitis preceded by symptoms of ileus: report of a case. Surg Today 2002;32:183–5.
- [8] Yoshida K, Arakawa M, Ishida S, et al. A case of hemolytic uremic syndrome associated with emphysematous cholecystitis and a liver abscess. Tohoku J Exp Med 1998;185:147–55.
- [9] Tooms D, Barlow D. Acute emphysematous cholecystitis. Proc R Soc Med 1955;48:757–9.
- [10] Stoltz AP, Donald PR, Strebel PM, et al. Criteria for the notification of childhood tuberculosis in a high-incidence area of the western Cape Province. S Afr Med J 1990;77:385–6.
- [11] Kirchhoff P, Muller V, Petrowsky H, et al. Fatal emphysematous cholecystitis caused by clostridium perfringens. Surgery 2007;141: 411–2.
- [12] Sunnapwar A, Raut AA, Nagar AM, et al. Emphysematous cholecystitis: imaging findings in nine patients. Indian J Radiol Imaging 2011;21: 142–6.
- [13] Moanna A, Bajaj R, Del RC. Emphysematous cholecystitis due to *Salmonella derby*. Lancet Infect Dis 2006;6:118–20.
- [14] Miyahara H, Shida D, Matsunaga H, et al. Emphysematous cholecystitis with massive gas in the abdominal cavity. World J Gastroenterol 2013;19:604–6.
- [15] Bouras G, Lunca S, Vix M, et al. A case of emphysematous cholecystitis managed by laparoscopic surgery. JSLS 2005;9:478–80.
- [16] Carrascosa MF, Salcines-Caviedes JR. Emphysematous cholecystitis. CMAJ 2012;184:E81.
- [17] Le Brun JC, Katz RM, Nasr AA, et al. Emphysematous cholecystitis in a non-diabetic patient. JBR-BTR 2013;96:316.
- [18] Hazey JW, Brody FJ, Rosenblatt SM, et al. Laparoscopic management and clinical outcome of emphysematous cholecystitis. Surg Endosc 2001;15:1217–20.
- [19] Katagiri H, Yoshinaga Y, Kanda Y, et al. Emphysematous cholecystitis successfully treated by laparoscopic surgery. J Surg Case Rep 2014;2014: doi: 10.1093/jscr/rju027.