



Ionised hypercalcaemia in a cat with extrahepatic biliary tract obstruction secondary to a bile duct vegetal foreign body

Journal of Feline Medicine and Surgery Open Reports
1–6

© The Author(s) 2024

Article reuse guidelines:

sagepub.com/journals-permissions

DOI: 10.1177/20551169241258635

journals.sagepub.com/home/jfmsopenreports

This paper was handled and processed by the European Editorial Office (ISFM) for publication in *JFMS Open Reports*



Diane Pichard^{1*} , Pauline Bernard^{1,2*} , Marion Fenet³, Paul Garnier⁴ , Sarah Schoffit⁴, Sarah Manzoni⁴ , Ghita Benchekroun¹, Mathieu Manassero⁴ and Valérie Freiche¹

Abstract

Case summary A 10-year-old neutered female domestic shorthair cat was presented to our hospital with a 2-day history of anorexia, vomiting and lethargy. The biochemistry panel revealed increased hepatic enzyme activity and serum amyloid A concentration. Haematological values were within reference intervals. An abdominal ultrasound identified a hyperechoic spindle-shaped structure within the common bile duct and a suspected secondary subobstruction, associated with signs of intra- and extrahepatic biliary tract inflammation. During hospitalisation, the cat developed severe and sustained ionised hypercalcaemia. Exploratory surgery was elected as a result of the lack of clinical improvement, despite supportive treatment and suspected retrograde migration of the spindle-shaped structure. Two grass awns were extracted at the junction of an extrahepatic duct and the common bile duct via choledochotomy using intraoperative ultrasound guidance. A stent was then placed in the bile duct to prevent subsequent bile leakage. Histopathology of the liver revealed a moderate neutrophilic and lymphoplasmacytic inflammation with rare bacterial colonies. *Escherichia coli* was cultured from a bile sample. No specific cause of hypercalcaemia was identified. The cat recovered uneventfully from surgery. Hepatic enzyme activities and hypercalcaemia progressively decreased within a few weeks after surgery and remained within the reference intervals without treatment. Therefore, hypercalcaemia was suspected to be secondary to a foreign body-related granulomatous reaction.

Relevance and novel information To our knowledge, only one other feline case report of biliary tract obstruction secondary to a biliary foreign body has been described in the literature. This is also the first case reporting the use of intraoperative ultrasound to localise a vegetal foreign body within the biliary tract of a cat. This case is also unique because of the onset of hypercalcaemia suspected to be secondary to a foreign body-related granulomatous reaction.

Keywords: Abdominal ultrasonography; foreign body; grass awn; intraoperative ultrasound guidance; choledochotomy; choledochal stenting

Accepted: 15 May 2024

¹Ecole Nationale Vétérinaire d'Alfort, CHUVA, Service de Médecine Interne, Maisons-Alfort, France

²Ecole Nationale Vétérinaire de Toulouse, CHUV-Ac, Service de Médecine Interne, Toulouse, France

³Ecole Nationale Vétérinaire d'Alfort, CHUVA, Service d'Imagerie Médicale, Maisons-Alfort, France

⁴Ecole Nationale Vétérinaire d'Alfort, CHUVA, Service de Chirurgie, Maisons-Alfort, France

*Diane Pichard and Pauline Bernard contributed equally to this work

Corresponding authors:

Diane Pichard DVM, ECVIM, Ecole Nationale Vétérinaire d'Alfort, CHUVA, Service de Médecine Interne, 7 avenue du Général de Gaulle, Maisons-Alfort, 94704, France
Email: diane.pichard@vet-alfort.fr

Pauline Bernard DVM, ECVIM, Ecole Nationale Vétérinaire de Toulouse, CHUV-Ac, Service de Médecine Interne, 23 chemin des Capelles, Toulouse, Occitanie 31300, France
Email: pauline.bernard@envt.fr



Creative Commons Non Commercial CC BY-NC: This article is distributed under the terms of the Creative Commons

Attribution-NonCommercial 4.0 License (<https://creativecommons.org/licenses/by-nc/4.0/>) which permits non-commercial use, reproduction and distribution of the work without further permission provided the original work is attributed as specified on the SAGE and Open Access pages (<https://us.sagepub.com/en-us/nam/open-access-at-sage>).

Case description

A 10-year-old spayed female domestic shorthair cat was presented for a 2-day history of anorexia, vomiting and lethargy. The cat also had a 1-year history of suspected weight loss and intermittent decreased appetite. The cat was reported to be up to date with vaccinations and anthelmintic treatment, had free outdoor access and was fed a commercial diet.

At presentation, the cat was lethargic but alert, with a body condition score of 4/9. Physical examination revealed mild tachycardia (200 beats/min) and mild diffuse discomfort on abdominal palpation. Haematological values were within reference intervals. Blood smear evaluation showed toxic and hyposegmented neutrophils. Serum biochemistry revealed a severe elevation in alanine transaminase (ALT) activity, mild hyperglobulinaemia, moderate hyperbilirubinaemia and a severe elevation of serum amyloid A (SAA) concentration (Table 1). An abdominal ultrasound examination (AFFINITY50; Philips Medical Systems) revealed a diffusely hypoechoic liver associated with thickening and dilation of the intrahepatic biliary tract and the cystic duct. In the common bile duct, a hyperechoic spindle-shaped structure was identified, measuring 12 × 2.5 mm and characterised by several hyperechoic linear interfaces, which generated mild acoustic shadowing (Figure 1a). Another linear hyperechoic structure extending into the duodenal major papilla without dilation of the distal common bile duct (ie, common bile duct of <2 mm of diameter) was identified. Severe signs of cholecystitis were also noted (Figure 1b). The ultrasonographic appearance of the two spindle-shaped structures identified were suggestive of vegetal foreign bodies (grass awns) or a conglomerate of biliary sludge. Biliary worms seemed very unlikely based on the geographical location. Cytologic examination of fine-needle aspirates of liver tissue and bile revealed rare plasmacytes and lymphocytes, and septic suppurative inflammation, respectively.

Pending antibiotic susceptibility results, the cat was hospitalised and maintenance intravenous fluid therapy (lactated Ringer's solution, 2 ml/kg/h), empiric broad spectrum antibiotic bi-therapy with additional activity against anaerobes (ampicillin sulbactam 20 mg/kg IV q8h [Unacim; Pfizer], metronidazole 10 mg/kg IV q12h [Metronidazole; Phoenix Pharma]), antiemetics (maropitant 1 mg/kg IV q24h [Cerenia; Zoetis], metoclopramide 0.3 mg/kg IV q8h [Emepriid; CEVA]) and analgesia (buprenorphine 20 µg/kg IV q8h [Bupaq; Virbac]) were administered. Assisted enteral feeding via nasoesophageal tube was also implemented. A bacterial culture of bile recovered only *Escherichia coli*. The organism was sensitive to marbofloxacin, doxycycline, amoxicillin and sulfatrimethoprim.

Table 1 Serum biochemistry at initial presentation (8 days before surgery)

	RI	On admission
Creatinine (µmol/l)	71–212	108
Urea (mmol/l)	5.6–12.5	7.7
ALT (U/l)	12–130	456
ALP (U/l)	22–187	54
Ammonium (µmol/l)	0–95	20
Total protein (g/l)	57–89	80
Globulin (g/l)	28–51	53
Albumin (g/l)	25–35	27
Albumin:globulin ratio	>0.8	0.5
Bilirubin (µmol/l)	2–6	14
DGGR lipase (U/l)	0–35	32
Ionised calcium (mmol/l)	1.1–1.4	1.29
Phosphorus (mmol/l)	0.99–2.4	1.57
Sodium (mmol/l)	150–165	154
Potassium (mmol/l)	3.6–5.5	3.9
SAA (µg/ml)	0–12	138.6

Abnormal values are highlighted in bold

ALP = alkaline phosphatase; ALT = alanine transaminase; DGGR = 1,2-*o*-dilauryl-rac-glycero-3-glutaric acid-(6'-methylresorufin) ester; RI = reference interval; SAA = serum amyloid A concentration

Despite treatments, the cat remained lethargic and anorexic during hospitalisation. Severe persistent ionised hypercalcaemia was observed, associated with an increased phosphorus concentration compared with the baseline value (Table 2). Abdominal ultrasound was repeated and supported retrograde migration of the spindle-shaped structures (Figure 2).

Additional diagnostic testing was performed because of the onset of severe and sustained ionised hypercalcaemia. Clinical examination, initial biochemistry and electrolyte panel, and diagnostic imaging (ie, abdominal ultrasound and thoracic radiography) did not reveal any other inflammatory/neoplastic condition or significant kidney or adrenal abnormalities. Plasma parathormone (PTH) measurement using a validated assay in cats was performed and was below the RI (<20 pg/ml, RI 50–200). Therefore, idiopathic hypercalcaemia or granulomatous inflammation secondary to the presumed biliary foreign body was suspected. Because of the severe increase in ionised calcaemia and persistent clinical signs, dexamethasone (0.1 mg/kg IV q24h [Rapidexon; Dechra]) was added, associated with modification of fluid therapy (sodium chloride 0.9%, 3 ml/kg/h). Low-dose corticosteroids were added to the treatment 7 days after the beginning of antibiotics and were chosen (in the light of possible but probably minor delayed healing) because of their fast-acting properties in the emergency setting of hypercalcaemia and the lack of rapid access to other therapies such as calcitonin.

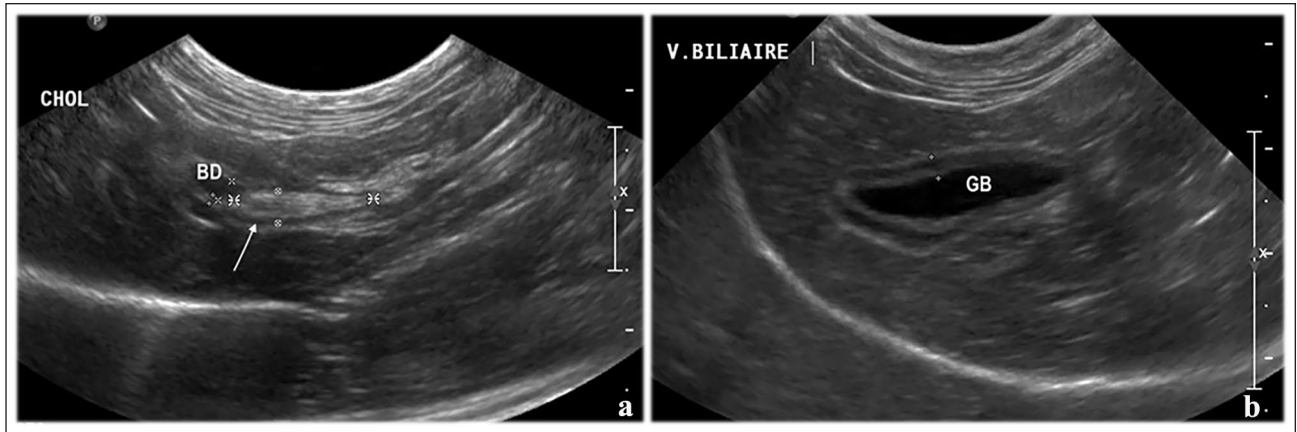


Figure 1 Ultrasonographic imagefigure of (a) the hyperechoic spindle-shaped structure within the common bile duct (BD) (arrow) and (b) marked thickening of the wall of the gallbladder (GB) (2.1 mm thickness) consistent with cholecystitis. Imaging was performed with (a) a linear multifrequency 5–12 MHz transducer probe and (b) a microconvex multifrequency 5–8 MHz transducer probe. © Imaging Department, Ecole Nationale Vétérinaire d'Alfort

Table 2 Serum biochemistry over the follow-up period

	RI	1 day before surgery	2 days after surgery	10 days after surgery	17 days after surgery	45 days after surgery
ALT (U/l)	12–130	146	122	37	–*	68
AST (U/l)	0–45	42	89	0	–*	10
ALP (U/l)	22–187	44	35	41	–*	74
Globulin (g/l)	28–51	33	34	42	–*	48
Albumin (g/l)	25–35	24	21	27	–*	32
Albumin:globulin ratio	<0.8	0.7	0.6	0.6	–*	0.7
Bilirubin (µmol/l)	2–6	7	5	3	–*	3
DGGR lipase (U/l)	0–35	37.1	–*	–*	–*	–*
Ionised calcium (mmol/l)	1.1–1.4	1.87	1.54	1.55	1.28	1.30
Phosphorus (mmol/l)	0.99–2.4	2.27	1.5	1.73	–*	1.54

*Analyte not rechecked

ALP = alkaline phosphatase; ALT = alanine transaminase; AST = aspartate transaminase; DGGR = 1,2-*o*-dilauryl-rac-glycero-3-glutaric acid-(6'-methylresorufin) ester; RI = reference interval

Given the lack of clinical improvement and the migration of the spindle-shaped structure, surgical management was undertaken. Perioperative biliary tract evaluation revealed dilatation of the gallbladder and extrahepatic bile ducts. One firm linear structure was palpated through the common bile duct. The second structure, suspected to be the second foreign body, was not identified, justifying an intraoperative ultrasound evaluation to accurately localise the two multilinear structures and choose the best incision site. Choledochotomy was performed distally to the hepatic duct's connection and two grass awns were seen, each measuring approximately 2 cm in length (Figure 3). The common bile duct was flushed and a choledochal stent using a 4 Fr urinary catheter was placed via duodenotomy and fixed transparietally. A liver biopsy using the wedge technique was performed for histopathological

analysis during the surgery and revealed a moderate neutrophilic and lymphoplasmacytic inflammation with rare bacterial colonies.

The cat recovered uneventfully from surgery. Lethargy progressively resolved during postoperative hospitalisation and her appetite improved. The 2-day recheck ultrasound showed no surgical complications. The cat was discharged 5 days postoperatively with antibiotic bi-therapy (amoxicillin–clavulanic acid 14 mg/kg PO q12h [Clavaseptin; Vetoquinol], metronidazole 12.5 mg/kg PO q12h [Eradia; Virbac]) for a duration of 5 weeks to minimise the risk of recurrence, and low-dose corticosteroid (prednisolone 0.3 mg/kg PO q24h [Microsolone; Dopharma]).

After discharge, clinical signs and biochemistry abnormalities progressively resolved (Table 2). The corticosteroid dose was tapered over 2 weeks. Ionised calcaemia

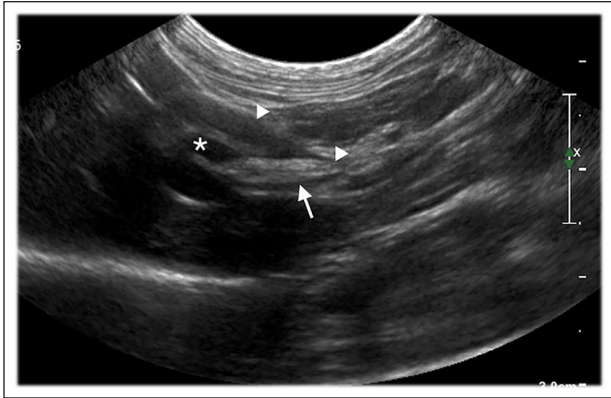


Figure 2 Ultrasonographic figure of the hyperechoic spindle-shaped structure (arrow) at the junction of a dilated intrahepatic bile duct (asterisk) with the common bile duct (arrowheads). The image was realised with a microconvex multifrequency 5–8 MHz transducer probe. © Imaging Department, Ecole Nationale Vétérinaire d'Alfort

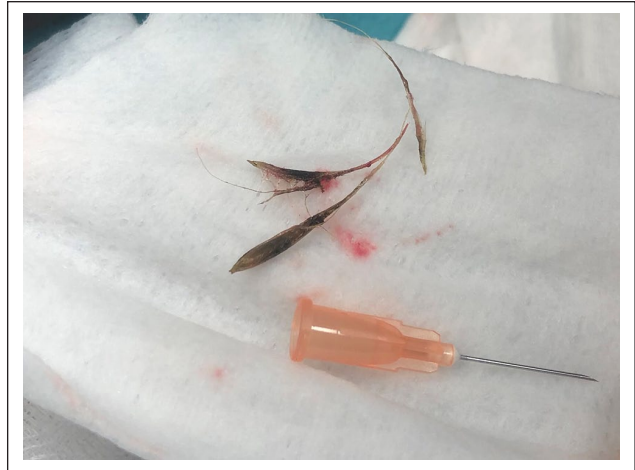


Figure 3 Macroscopic view of the two grass awns after surgical extraction with a hypodermic needle (25 G, 16 mm long) for scale. © Surgery Department, Ecole Nationale Vétérinaire d'Alfort

remained within the reference interval 2 weeks after discontinuation of the corticosteroid treatment (Table 2). The cat recovered well for the next 15 months.

Discussion

Extrahepatic biliary tract obstruction (EHBO) is uncommonly reported in cats.^{1–4} Several causes have been described, including inflammatory and neoplastic conditions involving the pancreas, liver, common bile duct and duodenum, foreign material in the biliary tract or proximal duodenum, biliary mucoceles, diaphragmatic hernia, liver fluke obstruction and congenital abnormalities.^{1,3,5–10} To our knowledge, only one case report of a biliary foreign body has been reported in a cat in the veterinary literature.¹⁰ In human medicine, a few reports of biliary tract obstruction secondary to foreign material, such as fish bone or surgical material, have been reported in the literature.^{11,12} In our case, a retrograde migration was strongly suspected because of the absence of fistulous tract found during surgery and the evidence of migration between the two ultrasonographic examination.^{10–12}

As EHBO can be a life-threatening condition in cats, the identification of this condition remains essential to provide suitable treatment. Clinical signs are usually non-specific; therefore, ultrasonographic examination is considered to be the best non-invasive diagnostic method.^{1–3,13,14} In our case, abdominal ultrasound identified intrahepatic duct dilation but the common bile duct diameter was within the feline reference interval. The ultrasonographic features of vegetal foreign material localised in different tissues have already been described in dogs and cats, and the ultrasound features in this case prompted surgical management.^{10,15,16}

Guidelines for the medical and surgical management of cats with EHBO have not been fully established, although in human medicine, evidence denotes an increased mortality rate after delays in surgical treatment.¹⁷ In our case, surgery was elected because of the progressive migration of the grass awn and the lack of clinical improvement despite treatment. The use of intraoperative ultrasound helped to localise the grass awns in the biliary tract and to determine the most appropriate choledochotomy site over the two foreign bodies that could not be accurately identified or palpated. Hepatobiliary intraoperative ultrasound has already been described in human and canine medicine.^{18,19} In cats, the utility of intraoperative ultrasound guidance for a vegetal foreign body in the retroperitoneal area has already been reported;¹⁶ however, to our knowledge, intraoperative ultrasound detection of grass awns in the biliary tract in a cat has not yet been described in the veterinary literature.

This case is also unique because of the onset of severe and persistent ionised serum hypercalcaemia. In the veterinary literature, the most frequently reported causes of hypercalcaemia in cats are kidney disease, malignancy and idiopathic hypercalcaemia.^{20–22} Other differentials in cats include vitamin D toxicity, severe and diffuse osteolytic processes, hypervitaminosis A, thyrotoxicosis, granulomatous disease and diet-induced hypercalcaemia.^{20–22} Case reports of hypercalcaemia associated with elevated concentrations of 1,25-dihydroxyvitamin D in granulomatous inflammatory reaction secondary to a foreign body, such as talc and silicone injections, have also been reported in humans^{23,24} and suspected in one dog with a xenogeneic pericardial patch.²⁵ In cats, a few cases of granulomatous hypercalcaemia have been

reported with cutaneous and systemic blastomycosis, cutaneous xanthoma, atypical *Mycobacterium* species infection and immune-contraceptive injection, with only one case describing the development of hypercalcaemia during hospitalisation.^{26–29} In some cases, evaluation of vitamin D metabolites and resolution of hypercalcaemia after withdrawal of the granulomatous lesion support the link between hypercalcaemia and hypervitaminosis D.^{26–28} Increased phosphorus concentration concomitantly with hypercalcaemia in granulomatous inflammatory reaction is usually expected and reported in human medicine and in a few cases in cats.^{23,29} In our case, no hyperphosphoraemia was noted but phosphorus concentration significantly increased with the onset of ionised hypercalcaemia and has progressively resolved during follow-up.

In our case, most causes of hypercalcaemia were ruled out, such as chronic kidney disease and primary hyperparathyroidism, or seemed very unlikely owing to the history, electrolyte panel, diagnostic imaging and long-term follow-up (eg, hypoadrenocorticism, hypercalcaemia of malignancy, vitamin D toxicity, diet-induced hypercalcaemia).^{20,21} Idiopathic hypercalcaemia was initially suspected in our case. However, the acute and severe onset as well as the absence of recurrence after corticosteroids questioned this hypothesis.

Knowing the reports of hypercalcaemia secondary to granulomatous reaction in cats and secondary to a foreign body in humans and dogs, hypercalcaemia secondary to a foreign body granulomatous reaction was suspected in our case. This might be supported by the non-recurrence of hypercalcaemia during follow-up after the removal of the foreign bodies and the trend in serum phosphorus concentration. However, liver histopathology did not identify granulomatous inflammation to support this hypothesis. It cannot be excluded that this subtype of inflammation was restrained to the bile duct or the extrahepatic duct or was hidden by the secondary neutrophilic and lymphoplasmacytic cholangitis lesions. Therefore, it might be more accurate to state that hypercalcaemia was associated with foreign body obstruction of the biliary tract in our case. The evaluation of vitamin D metabolites would have been interesting to further support this hypothesis but could not be performed because of the lack of approved assays readily available for cats.

Conclusions

Biliary vegetal foreign body should remain in the differential diagnosis of EHBO in cats. In this case, surgical

management with intraoperative ultrasound guidance resolved the obstruction. Marked hypercalcaemia appeared during hospitalisation, but progressively resolved after surgery with no recurrence during follow-up, supporting the suspected granulomatous origin.

Acknowledgements The authors thank the intensive care team (C Dartencet, DVM; L Marigliano, DVM) for emergency care, the imaging team (J Mortier DVM, DipECVDI, FHEA, MRCVS) and the internal medicine team (P Rimmel, DVM, ECVIM resident) from National Veterinary School of Alfort, Paris, France. The authors also thank Emi Ludemann for English proofreading, and Antonin Forestier (Idexx Students Clinical Case Competition) and Laure Lustman (AFVAC Internship Clinical Case Competition) for their oral presentation of this case.


Conflict of interest The authors declared no potential conflicts of interest with respect to the research, authorship, and/or publication of this article.

Funding The authors received no financial support for the research, authorship, and/or publication of this article.


Ethical approval The work described in this manuscript involved the use of non-experimental (owned or unowned) animals. Established internationally recognised high standards ('best practice') of veterinary clinical care for the individual patient were always followed and/or this work involved the use of cadavers. Ethical approval from a committee was therefore not specifically required for publication in *JFMS Open Reports*. Although not required, where ethical approval was still obtained, it is stated in the manuscript.

Informed consent Informed consent (verbal or written) was obtained from the owner or legal custodian of all animal(s) described in this work (experimental or non-experimental animals, including cadavers) for all procedure(s) undertaken (prospective or retrospective studies). For any animals or people individually identifiable within this publication, informed consent (verbal or written) for their use in the publication was obtained from the people involved.

ORCID iD Diane Pichard  <https://orcid.org/0000-0002-0965-8891>

Pauline Bernard  <https://orcid.org/0000-0003-4921-7182>

Paul Garnier  <https://orcid.org/0000-0002-3871-0986>

Sarah Manzoni  <https://orcid.org/0000-0002-8902-1240>

References

- 1 Lee K. **Extrahepatic bile duct obstruction and diseases of the gallbladder**. In: Procoli F, Allenspach K and Salavati S (eds). *Feline gastroenterology*. Palm Beach Gardens, FL: Edra Publishing, 2021, pp 405–427.

- 2 Mayhew PD, Holt DE, McLear RC, et al. **Pathogenesis and outcome of extrahepatic biliary obstruction in cats.** *J Small Anim Pract* 2002; 43: 247–253.
- 3 Otte CMA, Penning LC and Rothuizen J. **Feline biliary tree and gallbladder disease: aetiology, diagnosis and treatment.** *J Feline Med Surg* 2017; 19: 514–528.
- 4 Fahie MA and Martin RA. **Extrahepatic biliary tract obstruction: a retrospective study of 45 cases (1983–1993).** *J Am Anim Hosp Assoc* 1995; 31: 478–482.
- 5 Furneaux RW. **A series of six cases of sphincter of Oddi pathology in the cat (2008–2009).** *J Feline Med Surg* 2010; 12: 794–801.
- 6 Venier F, Compagnone K, Kerins A, et al. **Common bile duct obstruction caused by a helminth in a cat in the UK: ultrasonographic findings, histopathology and outcome.** *JFMS Open Rep* 2021; 7. DOI: 10.1177/2055116920984391.
- 7 Linton M, Buffa E, Simon A, et al. **Extrahepatic biliary duct obstruction as a result of involuntary transcutaneous implantation of hair in a cat.** *JFMS Open Rep* 2015; 1. DOI: 10.1177/2055116915610359.
- 8 Cornell KK, Jakovljevic S, Waters DJ, et al. **Extrahepatic biliary obstruction secondary to diaphragmatic hernia in two cats.** *J Am Anim Hosp Assoc* 1993; 29: 502–507.
- 9 Della Santa D, Schweighauser A, Forterre F, et al. **Imaging diagnosis – extrahepatic biliary tract obstruction secondary to a duodenal foreign body in a cat.** *Vet Radiol Ultrasound* 2007; 48: 448–450.
- 10 Brioschi V, Rousset N and Ladlow JF. **Imaging diagnosis – extrahepatic biliary tract obstruction secondary to a biliary foreign body in a cat.** *Vet Radiol Ultrasound* 2014; 55: 628–631.
- 11 Yu M, Huang B, Lin Y, et al. **Acute obstructive cholangitis due to fishbone in the common bile duct: a case report and review of the literature.** *BMC Gastroenterol* 2019; 19: 177. DOI: 10.1186/s12876-019-1088-8.
- 12 Giestas S, Mendes S, Gomes D, et al. **Obstructive jaundice due to foreign body in the bile duct: an unusual finding.** *GE Port J Gastroenterol* 2016; 23: 228–230.
- 13 Gaillot HA, Penninck DG, Webster CRL, et al. **Ultrasonographic features of extrahepatic biliary obstruction in 30 cats.** *Vet Radiol Ultrasound* 2007; 48: 439–447.
- 14 Spain HN, Penninck DG, Webster CRL, et al. **Ultrasonographic and clinicopathologic features of segmental dilations of the common bile duct in four cats.** *JFMS Open Rep* 2017; 3. DOI: 10.1177/2055116917716881.
- 15 Gnudi G, Volta A, Bonazzi M, et al. **Ultrasonographic features of grass awn migration in the dog.** *Vet Radiol Ultrasound* 2005; 46: 423–426.
- 16 Cola V, Del Magno S, Valentini S, et al. **Deep vegetal foreign bodies in cats: a retrospective study of 10 cases.** *J Am Anim Hosp Assoc* 2019; 55: 249–255.
- 17 Mehler SJ. **Complications of the extrahepatic biliary surgery in companion animals.** *Vet Clin North Am Small Anim Pract* 2011; 41: 949–967.
- 18 Patel NA and Roh MS. **Utility of intraoperative liver ultrasound.** *Surg Clin North Am* 2004; 84: 513–524.
- 19 Silva DM, Silva MAF, Vieira GP, et al. **Intraoperative ultrasonography in nine dogs with intra-abdominal neoplasm suspect.** *Cienc Rural* 2017; 47. DOI: 10.1590/0103-8478cr20151532.
- 20 de Brito Galvão JF, Parker V, Schenck PA, et al. **Update on feline ionized hypercalcemia.** *Vet Clin North Am Small Anim Pract* 2017; 47: 273–292.
- 21 Mellanby R. **Calcium, phosphorus.** In: Ettinger JM, Feldman EC and Côté E (eds) *Textbook of veterinary internal medicine*. 8th ed. Philadelphia, PA: Saunders Elsevier, 2017, pp 275–279.
- 22 Broughton SE, O'Neill DG, Syme HM, et al. **Ionized hypercalcemia in 238 cats from a referral hospital population (2009–2019).** *J Vet Intern Med* 2023; 37: 80–91.
- 23 Dangol GMS and Negrete H. **Silicone-induced granulomatous reaction causing severe hypercalcemia: case report and literature review.** *Case Rep Nephrol* 2019; 2019. DOI: 10.1155/2019/9126172.
- 24 Woywodt A, Schneider W, Goebel U, et al. **Hypercalcemia due to talc granulomatosis.** *Chest* 2000; 117: 1195–1196.
- 25 Linde KJ, Kelleher TR and Perry JA. **Biological implant-associated granulomatous inflammation resulting in secondary hypercalcemia and azotemia in a dog.** *Clin Case Rep* 2018; 6: 1801–1806.
- 26 Mealey KL, Willard MD, Nagode LA, et al. **Hypercalcemia associated with granulomatous disease in a cat.** *J Am Vet Med Assoc* 1999; 215: 959–962, 946.
- 27 Stern J, Chew D, Schissler J, et al. **Cutaneous and systemic blastomycosis, hypercalcemia, and excess synthesis of calcitriol in a domestic shorthair cat.** *J Am Anim Hosp Assoc* 2011; 47: e116–e120.
- 28 Ma D, Romine JF and Hardcastle M. **Cutaneous xanthoma causing hypercalcaemia in a cat.** *JFMS Open Rep* 2022; 8. DOI: 10.1177/20551169221082050.
- 29 Munson L, Harrenstien LA, Acton AE, et al. **Immunologic responses and adverse reactions to Freund's-adjuvanted porcine zona pellucida immuno-contraceptives in domestic cats.** *Vaccine* 2005; 23: 5646–5654.