

Metachronous Cancer of Breast and Adenocarcinoma of Cervix: A Rare Case Report

Nalini Sharma¹, J Lalnunem Thiek¹, Das Rituparna¹, Jaya Mishra², Ahanthem Santa Singh¹

¹Department of Obstetrics and Gynecology, North Eastern Indira Gandhi Regional Institute of Health and Medical Sciences, Shillong, Meghalaya, India, ²Department of Pathology, North Eastern Indira Gandhi Regional Institute of Health and Medical Sciences, Shillong, Meghalaya, India

The occurrence of a second primary cancer in a cancer survivor is well documented. It may be synchronous or metachronous. Incidence of metachronous cancer involving cervix is 0.82% to 1.33%. One such metachronous cancer is that of breast and cervix. We present a case of a woman who received tamoxifen for invasive ductal cancer of breast following a modified radical mastectomy and subsequently developed adenocarcinoma of cervix after six month of tamoxifen therapy. The role of tamoxifen in pathogenesis of cervical cancer and that of human papillomavirus infection in pathogenesis of both cancer of cervix and breast cancer has been well recognized. In our patient, the adenocarcinoma of cervix (rare occurrence) which is likely due to six month of tamoxifen therapy is a perplexing question. Women diagnosed and treated for breast cancer need to be followed up for development of other metachronous gynecological cancers. (**J Menopausal Med 2017;23:131-134**)

Key Words: Cervical cancer · Metachronous cancer · Tamoxifen Breast cancer

Introduction

The occurrence of a second primary cancer in a cancer survivor is well documented. It may be synchronous (within 6 months of diagnosis of first primary cancer) or metachronous (more than 6 months of diagnosis of first primary cancer). There may be several factors responsible for development of multiple primary malignancies like genetic predisposition and exposures to carcinogenic substances. Treatment of first primary malignancy may lead to development of second cancer. The improvement in survival after a successful treatment of one cancer itself is a factor which increases the possibility of second primary malignancy. One such metachronous cancer is that of breast and cervix. Incidence of metachronous cancer involving cervix is 0.82%

to 1.33%.¹ The other organs commonly involved are gastric, colon and lung. The histological type of cervical cancer in metachronous cancer is mostly squamous cell cancer and adenocarcinoma was rare.¹ The role of tamoxifen given for breast cancer in development of uterine and cervical cancer have been reported. But tamoxifen does not appear to endorse the pathogenesis of non-squamous cervical cancer.² On the other hand, the role of human papillomavirus (HPV) in breast cancer have also been reported. We present a case of a woman who received tamoxifen for invasive ductal carcinoma of breast and subsequently developed adenocarcinoma of cervix.

Received: April 13, 2017 Revised: June 23, 2017 Accepted: July 22, 2017

Address for Correspondence: Nalini Sharma, Department of Obstetrics and Gynecology, B 1 D, North Eastern Indira Gandhi Regional Institute of Health and Medical Sciences, Shillong, Meghalaya 793018, India

Tel: +91-36-4253-8234, Fax: +91-36-4253-8025, E-mail: Nalinisharma100@rediffmail.com

Copyright © 2017 by The Korean Society of Menopause

© This is an Open Access article distributed under the terms of the Creative Commons Attribution Non-Commercial License (<http://creativecommons.org/licenses/by-nc/4.0/>).

Case Report

A 48-year-old, para 3 and live 3 (P3L3) attended surgery outpatient department (OPD) in the month of November 2015 with the complaint of lump in the left breast since 3 months. There was no history of associated pain, nipple discharge or trauma. There was no family history of breast cancer or any other type of cancer in the family. She was having amenorrhea since last 6 months. On examination of the breast, a hard lump of approximately 7 × 5 cm, non-mobile, non tender was felt in inner lower quadrant of the left breast with retraction of the skin overlying the mass. The nipple and areola of the left breast was normal with no discharge on expression. The right breast was found to be normal with no palpable axillary nodes on both sides. Supraclavicular nodes were not palpable bilaterally. Complete gynecological examination was done and no abnormality was detected. Pap smear was taken which was negative for intraepithelial lesion and malignancy. Ultrasound revealed normal uterus and bilateral adnexa. Trucut biopsy of the breast lump shows cells suggestive of invasive ductal carcinoma-NOS (Fig. 1). Patient was clinically staged as invasive ductal carcinoma stage T4bN0M0.

The patient received 3 cycles of neo-adjuvant chemotherapy with Cyclophosphamide, Epirubicin, 5 fluorouracil. Patient underwent modified radical mastectomy in January 2016. Histopathological examination of the tissue showed

invasive cancer of breast-No special type: Modified Bloom Richardson grade I with cancerization of lobules and lymphovascular emboli. Out of the 16 lymph nodes identified in the axillary tail, 11 showed tumor cells. Immunohistochemistry report

Estrogen receptor-Positive, Allred score 4/8, Progesterone receptor-positive, Allred score 5/8, Her2/neu-negative (1+). Patient received 3 more cycles of chemotherapy after surgery. Patient also received radiotherapy and tamoxifen.

After 6 months of tamoxifen therapy i.e., in the month of November 2016 the patient attended gynaecology OPD with the complaint of bleeding per vaginum. On examination, ulceroproliferative growth approx. 3 × 2 cm seen in the posterior lip of the cervix involving the posterior fornix. Bilateral parametrium was free. The size of uterus was normal. Cervical biopsy shows endometrioid variety of endocervical adenocarcinoma (Fig. 2). Magnetic resonance imaging pelvis revealed irregular thickening predominantly of the posterior part of cervix with T2 hyper intense vaginal collection suggestive of cancer of cervix with no parametrial involvement. Patient was diagnosed as second primary malignancy with adenocarcinoma cervix Stage IIa. Patient was advised surgery but she opted for chemo radiation. Patient received chemotherapy with paclitaxel and carboplatin. She completed 3 cycle of chemotherapy. Clinically she is doing well. Size of her cervical growth has also decreased. Patient is presently on radiotherapy.

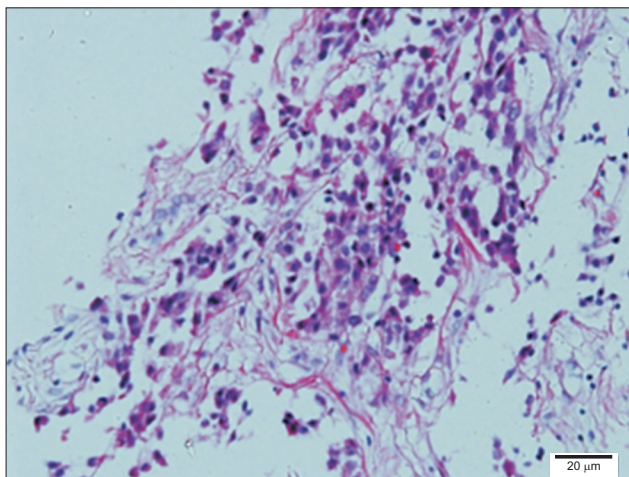


Fig. 1. Hematoxylin and eosin at 20× shows cells are arranged in nests and occasional duct like structure and solid clusters suggestive of invasive ductal carcinoma-NOS.

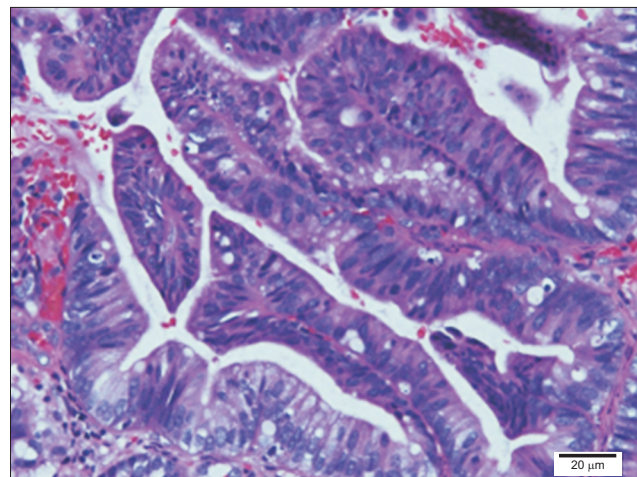


Fig. 2. Hematoxylin and eosin at 20× shows back to back glandular pattern of tubules, papillae and glands with features of moderately differentiated adenocarcinoma of cervix.

Discussion

Tamoxifen, a selective estrogen receptor modulator is a commonly used drug as an adjuvant therapy following surgery for breast cancer. The significant improvement of 10 year survival with tamoxifen in patients with estrogen receptor positive breast cancer patient has been well documented.³ As tamoxifen is strongly associated with development of endometrial hyperplasia and carcinoma; the patients must be well informed regarding the possibility of developing the same. The association of tamoxifen with endometrial carcinoma has been established.^{4,5} More than 2 year of tamoxifen therapy increases 2,3 times chance of endometrial cancer.⁶ The possibility of developing cervical cancer following tamoxifen therapy has also been studied. In patients with HPV infection, tamoxifen is responsible for enhancing the expression of HPV 16 & 18 and also expression of E6 & E7 in cancer cells of the cervix, the molecular mechanism of which has been established.^{7,8} In our patient, the cervical cancer screening with Pap smear was negative for intraepithelial lesions and malignancy when she was diagnosed with breast cancer. However, after 6 months of tamoxifen therapy the patient was diagnosed with cervical adenocarcinoma which is a rare occurrence. In one study use of tamoxifen was associated with development of papillary-serous adenocarcinoma of uterine cervix.²

On the other hand, the role of HPV infection in breast cancer has also been considered. The presence of HPV in the tumor tissue and not in the normal breast tissue had been reported by several studies, which suggests the role of HPV in development of breast cancer.⁹⁻¹¹ Henning et al.¹² reported the presence of HPV 16 DNA in breast tissue and cervix of patients with breast cancer being treated for cervical intraepithelial neoplasia III. Though the route of infection and transmission is not yet known, the possibility of spread of HPV infection to different organs with subsequent development of carcinoma is a possibility. The role of tamoxifen in cervical cancer and the role of HPV infection in both cancer of cervix and breast cancer have been well documented. In our patient, the adenocarcinoma of cervix (rare occurrence) which is likely due to six month of tamoxifen therapy is a puzzling question. Women diagnosed and treated for breast cancer need to be followed up for development of other

metachronous gynecological cancers.

Conflict of Interest

No potential conflict of interest relevant to this article was reported.

References

1. Takatori E, Shoji T, Miura Y, Takeuchi S, Uesugi N, Sugiyama T. Triple simultaneous primary invasive gynecological malignancies: a case report. *J Obstet Gynaecol Res* 2014; 40: 627-31.
2. Watrowski R, Striepecke E, Jäger C, Bauknecht T, Horst C. Papillary-serous adenocarcinoma of the uterine cervix during tamoxifen therapy after bilateral breast cancer. *Anticancer Res* 2012; 32: 5075-8.
3. Muss HB. Role of adjuvant endocrine therapy in early-stage breast cancer. *Semin Oncol* 2001; 28: 313-21.
4. De Muylder X, Neven P, De Somer M, Van Belle Y, Vanderick G, De Muylder E. Endometrial lesions in patients undergoing tamoxifen therapy. *Int J Gynaecol Obstet* 1991; 36: 127-30.
5. Bergman L, Beelen ML, Gallee MP, Hollema H, Benraadt J, van Leeuwen FE. Risk and prognosis of endometrial cancer after tamoxifen for breast cancer. Comprehensive Cancer Centres' ALERT Group. Assessment of Liver and Endometrial cancer Risk following Tamoxifen. *Lancet* 2000; 356: 881-7.
6. van Leeuwen FE, Benraadt J, Coebergh JW, Kiemeny LA, Gimbrère CH, Otter R, et al. Risk of endometrial cancer after tamoxifen treatment of breast cancer. *Lancet* 1994; 343: 448-52.
7. Hwang JY, Lin BY, Tang FM, Yu WC. Tamoxifen stimulates human papillomavirus type 16 gene expression and cell proliferation in a cervical cancer cell line. *Cancer Res* 1992; 52: 6848-52.
8. Kim CJ, Um SJ, Kim TY, Kim EJ, Park TC, Kim SJ, et al. Regulation of cell growth and HPV genes by exogenous estrogen in cervical cancer cells. *Int J Gynecol Cancer* 2000; 10: 157-64.
9. Heng B, Glenn WK, Ye Y, Tran B, Delprado W, Lutze-Mann L, et al. Human papilloma virus is associated with breast cancer. *Br J Cancer* 2009; 101: 1345-50.
10. Di Lonardo A, Venuti A, Marcante ML. Human papillomavirus in breast cancer. *Breast Cancer Res Treat* 1992; 21:

- 95–100.
11. Liu Y, Klimberg VS, Andrews NR, Hicks CR, Peng H, Chiriva-Internati M, et al. Human papillomavirus DNA is present in a subset of unselected breast cancers. *J Hum Virol* 2001; 4: 329–34.
12. Hennig EM, Suo Z, Thoresen S, Holm R, Kvinnsland S, Nesland JM. Human papillomavirus 16 in breast cancer of women treated for high grade cervical intraepithelial neoplasia (CIN III). *Breast Cancer Res Treat* 1999; 53: 121–35.