




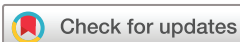Technical and clinical outcomes following EUS-guided thrombin injection and coil implantation for parastomal varices

Andrew Todd ¹, Chander Shekhar,² Joanne O'Rourke,¹ Colm Forde,¹ Arvind Pallan,¹ Sharan Suresh Wadhwani ¹, Dhiraj Tripathi ^{1,3}, Brinder Singh Mahon¹

To cite: Todd A, Shekhar C, O'Rourke J, *et al*. Technical and clinical outcomes following EUS-guided thrombin injection and coil implantation for parastomal varices. *BMJ Open Gastro* 2023;**10**:e000819. doi:10.1136/bmjgast-2021-000819

DT and BSM are joint senior authors.

Received 19 January 2022
Accepted 28 March 2022



© Author(s) (or their employer(s)) 2023. Re-use permitted under CC BY-NC. No commercial re-use. See rights and permissions. Published by BMJ.

¹Liver Unit, University Hospitals Birmingham NHS Foundation Trust, Birmingham, UK

²Department of Gastroenterology, Walsall Healthcare NHS Trust, Walsall, UK

³Institute of Immunology and Immunotherapy, University of Birmingham, Birmingham, UK

Correspondence to

Professor Dhiraj Tripathi;
dhiraj.tripathi@uhb.nhs.uk

ABSTRACT

Background and aims Bleeding from parastomal varices causes significant morbidity and mortality. Treatment options are limited, particularly in high-risk patients with significant underlying liver disease and other comorbidities. The use of EUS-guided embolisation coils combined with thrombin injection in gastric varices has been shown to be safe and effective. Our institution has applied the same technique to the treatment of parastomal varices.

Methods A retrospective review was performed of 37 procedures on 24 patients to assess efficacy and safety of EUS-guided injection of thrombin, with or without embolisation coils for treatment of bleeding parastomal varices. All patients had been discussed in a multidisciplinary team meeting, and correction of portal hypertension was deemed to be contraindicated. Rebleeding was defined as stomal bleeding that required hospital admission or transfusion.

Results All patients had significant parastomal bleeding at the time of referral. 100% technical success rate was achieved. 70.8% of patients had no further significant bleeding in the follow-up period (median 26.2 months) following one procedure. 1-year rebleed-free survival was 80.8% following first procedure. 7 patients (29.1%) had repeat procedures. There was no significant difference in rebleed-free survival following repeat procedures. Higher age was associated with higher risk of rebleeding. No major procedure-related complications were identified.

Conclusions EUS-guided thrombin injection, with or without embolisation coils, is a safe and effective technique for the treatment of bleeding parastomal varices, particularly for patients for whom correction of portal venous hypertension is contraindicated.

INTRODUCTION

Portal hypertension in cirrhosis results from increased intrahepatic resistance and increased portal inflow due to splanchnic vasodilatation. Clinically significant portal hypertension develops at a hepatic venous pressure gradient of ≥ 10 mm Hg and signals the development of varices and bleeding.

WHAT IS ALREADY KNOWN ON THIS TOPIC

- ⇒ Bleeding from parastomal varices causes significant morbidity for patients with a stoma and liver cirrhosis.
- ⇒ Definitive treatment options for portal hypertension are not available for all patients due to comorbidities.
- ⇒ Treatment of gastric varices using endoscopic ultrasound (EUS)-guided embolisation coils and human thrombin has been established as an alternative to cyanoacrylate glue.

WHAT THIS STUDY ADDS

- ⇒ We report a new technique for management of parastomal varices using EUS-guided embolisation.

HOW THIS STUDY MIGHT AFFECT RESEARCH, PRACTICE OR POLICY

- ⇒ Embolisation of parastomal varices may reduce bleeding and comorbidity for patients with portal hypertension.

Parastomal varices form when splanchnic veins from the portal venous system are surgically juxtaposed with the systemic veins of the abdominal wall. Bleeding from parastomal varices (also referred to as stomal or peristomal varices) has been reported in up to 5% of people with a stoma and 27% of the stoma patients with liver cirrhosis.^{1 2} Recurrent bleeding causes significant morbidity, and mortality from haemorrhage has been reported in 2.6%–4% of patients undergoing treatment.^{3 4}

Liver transplantation to treat the underlying liver disease is only available for a minority of patients; however, portal pressure can be reduced or normalised by creating a shunt between the portal and central venous systems. These patients often have multiple comorbidities and surgical porto-systemic shunt formation is associated with

perioperative mortality of 10%–20%⁵ and has been largely superseded by minimally invasive transjugular intrahepatic portosystemic stent shunt (TIPSS) with or without embolisation.⁶

Where a portosystemic shunt is contra indicated, or where bleeding persists despite normalisation of the portosystemic gradient, treatment is directed towards the varices at the stoma site. In acute haemorrhage, first-line, non-operative interventions such as compression, epinephrine-soaked gauze, ligation and cautery may be effective, and can be used in combination with medical therapy such as non-selective beta-blockade.³ Surgical revision of a stoma, with mucocutaneous disconnection, is performed in some cases; however, these patients are often high-risk surgical candidates as described above. Fluoroscopic-guided embolisation of parastomal varices with coils has been described using a transjugular approach (either alone⁷ or in combination with TIPSS⁸), via direct puncture of the liver in percutaneous transhepatic obliteration^{9 10} or via accessing the efferent systemic vein in balloon-occluded retrograde transvenous obliteration.¹¹

Utilisation of endoscopic ultrasound (EUS) for the treatment of gastric varices is increasingly established, although its use in parastomal varices is very limited.^{12 13} Worldwide, the most commonly used oblitative agent for varices is cyanoacrylate (N-butyl-2-cyanoacrylate; Histoacryl 'glue'); however, embolisation coils are increasingly considered in gastric varices, with evidence that a combination of coil and cyanoacrylate is superior to either coils or cyanoacrylate alone.¹⁴ Human thrombin has been proposed as an alternative to cyanoacrylate, and used with and without coils in gastric varices.^{15–18}

Our institution has successfully treated parastomal varices with human thrombin injection±embolisation coil(s), under EUS guidance to treat parastomal varices. A retrospective review was performed to assess the outcomes from this technique.

Aims

The aim of this study is to assess safety and efficacy of EUS-guided management of parastomal varices.

METHODS

Setting

Procedural and follow-up data for all EUS-guided interventions for bleeding parastomal varices from January 2014 to January 2020 at a regional liver transplant centre in the UK were retrospectively analysed. All procedures were performed by one of two experienced endosonographers or a trainee fellow under their direct supervision. The project was registered and approved as an audit following local policy.

Patients were identified using the Radiology Information System. Procedure reports and electronic medical records such as clinic letters and discharge summaries were reviewed to obtain clinical information. Model for

End-stage Liver Disease (MELD) scores were calculated using blood test results at the time of procedure.¹⁹ For rebleeding, where no date of admission was documented, the date of clinic letter was used as surrogate.

Preprocedure assessment

All cases were referred to the tertiary-care liver unit at our institution, mostly from other hospitals in the region, although a minority of patients were referred from within our own Trust. All had refractory bleeding; patients with acute severe bleeding were transferred under inpatient care and treated as emergent, with more stable cases admitted electively. All patients had portal venous CT scan to assist in management planning. All cases were discussed in liver multidisciplinary team meetings to review treatment options depending on history, comorbidities and portal vein anatomy. Where the risk of TIPSS or an alternative interventional radiology approach was deemed to be too high or not technically feasible, patients were referred for an EUS-guided treatment. Patients were consented for risk of bleeding, non-target embolisation (including intestinal ischaemia, stroke and pulmonary embolism), unsuccessful procedure, and repeat intervention including endovascular or surgical approach.

Standard procedure

Most procedures are performed without sedation or analgesia, but intravenous midazolam and fentanyl are available if required. The room was set up to allow the endoscopist to comfortably support and manipulate the lower end of the endoscope with their right hand throughout the procedure. Thrombin 500IU³/ml in prefilled syringes (Tisseel®, Baxter Healthcare, Newbury, UK) is prepared by defrosting over 10 min.

With the patient supine, the linear echoendoscope (GF-UCT240; Olympus, Southend, UK) in combination with a Hitachi Aloka ultrasound platform (ProSound F75 or Aloka Alpha 10; Hitachi Medical Systems, Wellingborough, UK) is inserted into the stoma. A deep vein or veins usually feeding a network of varices are identified, often within 2–5 cm of the stoma opening but no deeper than 10 cm (figure 1). The dominant feeding vessel diameter

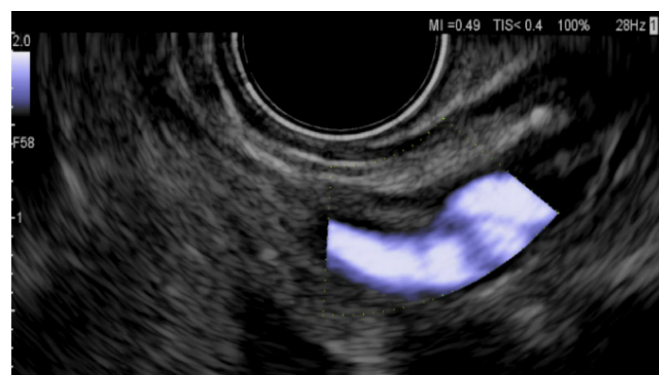


Figure 1 Feeding vessel identified using colour Doppler imaging.

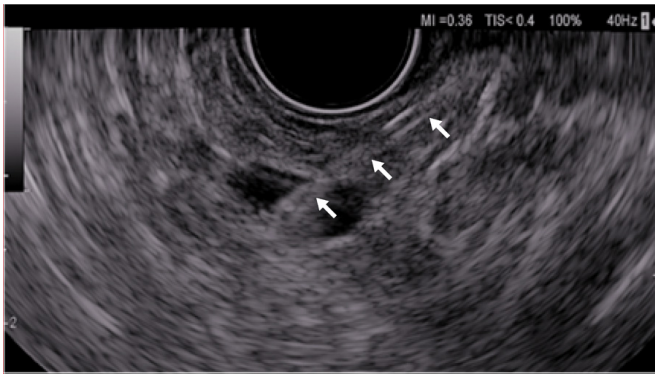


Figure 2 Needle (arrows), with tip in feeding vessel.

is measured, with Doppler imaging used to confirm flow direction and measure flow rate. Those feeding vessels deemed to have relatively high flow are considered for a two-step approach to thromboembolisation, with initial slowing of blood flow by coil placement, and subsequently completion of embolisation with thrombin.

The needle is prepared by flushing with saline to avoid introduction of air and degradation of the ultrasound image. A 19-gauge vascular access needle (EchoTip Ultra, Cook Medical, Limerick, Ireland) is used for 0.036" embolisation coils (Nester, Cook Medical, Limerick, Ireland), or a 22-gauge EUS needle is used for 0.018" microcoils or thrombin injection alone. The needle is placed in the target vessel and test injection of 10 mL saline is performed to ensure in the needle tip is intravascular (**figure 2**).

The initial coil diameter selected is slightly oversized by approximately 20%–25% relative to the diameter of the target vessel to be obliterated, in order to minimise the risk of coil migration and non-target embolisation. Any subsequent coil(s) placed can be of smaller diameter. The coil holding device is attached to the needle channel, the coil is loaded into the needle using the needle stylet, and the holding device is removed. Then coil is then delivered into the vessel using the needle stylet, carefully monitored under EUS imaging to ensure the entire length of coil is deployed within the vessel (**figure 3**, online supplemental video 1). Luminal flow is reassessed and subsequent smaller coils may be used to further reduce blood flow. Some loss of visibility of the

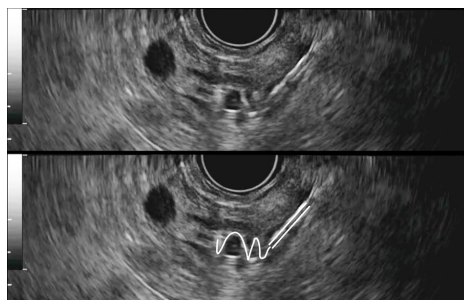


Figure 3 Coil deployment under endoscopic ultrasound guidance, with annotated image showing location of the needle (parallel lines) and coil (single line) within the vessel.

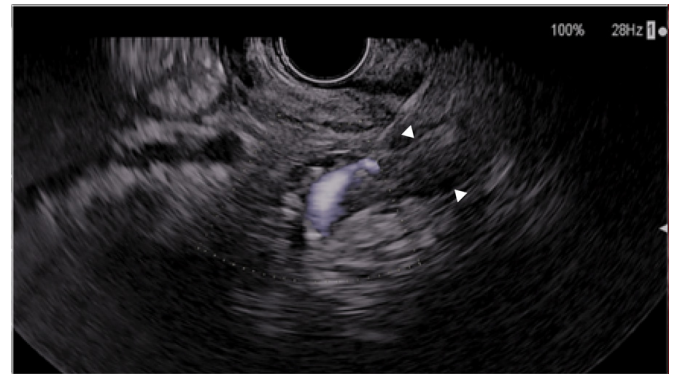


Figure 4 Injection of thrombin into a vessel showing colour Doppler flow (no coil in vessel) with immediate formation of echogenic thrombus in the vessel lumen (arrowheads).

distant wall of the vein should be expected, caused by acoustic shadowing from the coil(s).

Human thrombin 500 IU³/mL (Tisseel; Baxter Healthcare, Newbury, UK) is injected in 1 mL aliquots, until visible clot formation is seen obliterating the vessel lumen (**figures 4 and 5**).

Example EUS images are shown in **figures 1–5** and online supplemental video 1.

Post procedure

Patients are advised to stay in bed for at least 4 hours post procedure and observed for up to 12 hours. Paracetamol is prescribed as required for analgesia, and the patient is discharged the following day if well.

Routine reassessment with EUS is not usually required due to the relatively small size of parastomal varices and low risk of catastrophic haemorrhage (in contrast to follow-up of gastric varices).

Definitions

Significant rebleeding (SR): postprocedure stomal bleeding episodes requiring hospital admission or blood transfusion.

Mild rebleeding: postprocedure stomal bleeding documented but not requiring hospital admission or blood transfusion.

Procedural (technical) success: the ability to obliterate the vessel on direct EUS view at the time of the procedure.

Treatment success: no significant rebleeding in the follow-up period.

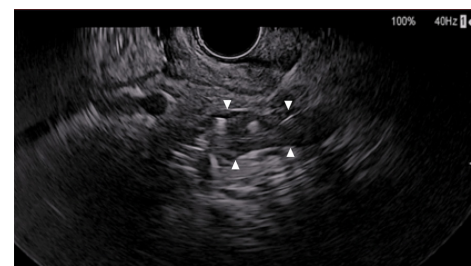

Figure 5 Complete occlusion of feeding vessel with thrombus (arrowheads) after coil embolisation and thrombin injection.

Statistical analysis

Statistical analysis was performed using IBM SPSS Statistics for Windows, V.25 (IBM, Armonk, USA). Kaplan-Meier estimator was used to analyse the SR-free survival, with log-rank test to compare between groups and Cox's proportional hazards model used to assess correlation with continuous variables. HRs with 95% CIs were calculated for each variable, and the result was considered statistically significant if $p < 0.05$. Continuous data were reported as median (IQR) values. Mann-Whitney U test was used to compare continuous variables, as appropriate. Categorical data were reported as proportions, and comparisons were made using either Fisher's exact test or χ^2 test, as appropriate.

RESULTS

Baseline characteristics

In total, 37 procedures were identified on 24 patients. Only 3 patients (12.5%) were referred from within our own institution, with 21 (87.5%) referred from other hospitals.

Background demographics and medical history are shown in [table 1](#). The most common cause for cirrhosis was primary sclerosing cholangitis and is associated with inflammatory bowel disease, which was the most common underlying cause for the stoma in this series.

Six patients had concurrent esophagogastric varices, with three of these patients having had previous banding of oesophageal varices as primary prevention. No recorded instances of previous upper gastrointestinal haemorrhage were identified. Most patients (70.8%) had been prescribed a non-selective beta-blocker (carvedilol or propranolol) to reduce the risk of variceal haemorrhage. One patient had a patent covered TIPSS in situ at the time of procedure, and another had an occluded TIPSS. All other patients were documented as being unsuitable for TIPSS—either due to risk of encephalopathy, or due to previously failed attempt at TIPSS insertion. Median MELD Score at the time of procedure was 12.

Previous blood transfusion for parastomal variceal bleeding was recorded in 19 of 24 patients (79.1%) prior to their first procedure EUS-guided intervention.

Procedural details

Of the 37 procedures, 18 (48.6%) were performed as emergent, with treatment of acute haemorrhage being the most common reason for admission ([table 2](#)). Patients undergoing elective procedures were admitted for routine overnight observation following the procedure. Based on preprocedural blood results, three patients required blood products (fresh frozen plasma and/or platelets) for correction of coagulopathy (international normalised ratio (INR) > 1.4 , platelets $< 50 \times 10^9/L$) prior to the procedure.

Sedation was used as required in a minority of procedures, depending on patient anxiety and discomfort.

Table 1 Baseline characteristics

	Number of patients/ median	Percentage/ IQR
Male gender	10	41.7
Age in years, median	59.0	22.5–74.7
Aetiology of portal hypertension		
Primary sclerosing cholangitis (PSC)	9	37.5
Alcoholic cirrhosis	6	25.0
Non-alcoholic fatty liver disease	4	16.7
Portal vein thrombosis (secondary to ITP)	1	4.2
PSC and portal vein stenosis	1	4.2
Primary biliary cholangitis	1	4.2
Liver metastasis	1	4.2
Hepatitis C cirrhosis	1	4.2
Child-Pugh Class		
A	14	58.3
B	7	29.2
C	3	12.5
Model for End-stage Liver Disease Score, median	12	10–17
Previous esophagogastric variceal haemorrhage	0	0
Previous treatment for varices		
Beta-blocker	17	70.8
Oesophageal variceal band ligation	3	12.5
Transjugular intrahepatic portosystemic stent shunt	2	8.3
None	5	20.8
Type of stoma		
Ileostomy	19	79.2
Colostomy	4	16.7
Urostomy	1	4.2
Indication for stoma		
Inflammatory bowel disease	17	70.8
Colorectal cancer	5	20.8
Previous bowel perforation	1	4.2
Cystectomy for tuberculosis	1	4.2
Years since stoma formation, median	5.4	2.9–21.6
Data presented as number of patients with percentage, or median and IQR as specified. ITP, Immune Thrombocytopaenia.		

Intravenous midazolam was used in five cases (maximum 2.5 mg) and fentanyl was used in two cases (maximum 100 µg).

The median diameter of the largest vessels treated in the group receiving combination therapy with coils and thrombin was larger than the group receiving thrombin alone, reflecting operator preference to use coils in larger, high-flow vessels. The median diameter of the largest coil used was 8 mm, slightly larger than the median diameter

Table 2 Summary of procedural details

	Number of procedures/ median	Percentage/ IQR
Emergency	18	48.6
Elective	19	51.3
Correction of anticoagulation pre-procedure		
Fresh frozen plasma	1	2.7
Platelets	1	2.7
Fresh frozen plasma and platelets	1	2.7
Sedation		
Midazolam	5	13.5
Fentanyl	2	5.4
By embolic agent used:		
Thrombin only	19	51.4
Diameter of largest vessel, median, mm	4	3–5
Units of thrombin used, median, IU ³	3000	2500–4000
Coil and thrombin	18	48.6
Diameter of largest vessel, median, mm	6.5	5–8
Diameter of largest coil, median, mm	8	6–10
Units of thrombin used, median, IU ³	3750	3000–4000
Data presented as number of patients with percentage, or median and IQR as specified.		

of the largest vessel in this group (6mm), also reflecting operator preference to oversize the coils in order to prevent non-target embolisation.

Clinical outcomes

All procedures reported technical success in identifying and thrombosing a variceal vessel as imaged on EUS.

Length of follow-up was defined by the period between the date of procedure and the date of the most recent follow-up letter. Median follow-up was 26.2 months (range 0–46 months, IQR 10.2–33.2 months).

Following their first procedure, SR occurred in 7 of 24 patients (29.1%) during the follow-up period, at a median of 10.8 months following the procedure. Seven patients had a second procedure, and three of these patients (42.9%) had further SR, at a median of 13.5 months post procedure. Three patients had a third procedure, and one patient had five procedures in total (figure 6, table 3).

Kaplan-Meier analysis was performed to assess SR-free survival (figure 6). One-year SR-free survival was 80.8% following first procedure, 83.3% following second procedure, and 76.6% with all procedures included (figure 7).

Log-rank test did not show significant difference when comparing first, second and third procedures ($p=0.132$). With only a single fourth and fifth procedure recorded (performed on the same patient), meaningful SR-free survival for these cases could not be determined.

SR-free survival for categorical data is shown in table 4. No statistically significant differences were identified between groups, except for longer estimated mean SR-free survival in patients below the median age of 59.0 (figure 8).

HRs for continuous variables are shown in table 5. The only statistically significant correlation was that of age, which is associated with an increased risk of SR of 1.072 for every additional year of age.

Complications

Postprocedure pain was recorded in 3 of 37 discharge summaries (8.1%). Postprocedure fever was recorded on 2 (7.4%)—both were treated with antibiotics and were otherwise uneventful—all other elective procedures were discharged on day 1 post procedure (median stay 1 day). Median length of stay for emergency cases was 3 days, with no discharge delays relating to the endoscopic procedure identified. One patient had three procedures within 3 months for recurrent bleeding. After the third procedure, the patient had further bleeding but was treated with palliative intent only and died 1 month later. Three other patients died within the follow-up period due to underlying liver disease—one due to metastatic colorectal cancer, one with PSC, previous transplant and portal vein stenosis (MELD Score 28), and one patient with primary biliary cholangitis, awaiting liver transplant, (MELD Score 13) with unknown cause of death.

DISCUSSION

Bleeding from parastomal varices is a relatively rare complication, but it poses a unique challenge in management. TIPSS has been found to be effective in achieving haemostasis, with one study recording a rebleeding rate of only 5% in parastomal varices, although post-TIPSS hepatic encephalopathy manifested or worsened in 30% of patients²⁰ and direct procedural mortality from TIPSS is 1%–2%.^{21 22} Guidelines from both the British Society of Gastroenterology^{6 15} and the American Association for the study of liver diseases²³ recommend TIPSS for control of variceal haemorrhage, but recognise the need to tailor treatment for individual patients.

Technique

The use of cyanoacrylate glue in the treatment of gastric varices has been associated with serious thromboembolic events,²⁴ with one series reporting pulmonary emboli being in 4% of cases.²⁵ In addition, glue can damage the endoscope if not administered appropriately, which adds complexity to the procedure, particularly for clinicians who do not use such adhesives on a regular basis. Thrombin has been suggested as an alternative to cyanoacetate glue with the benefit of being technically easier to

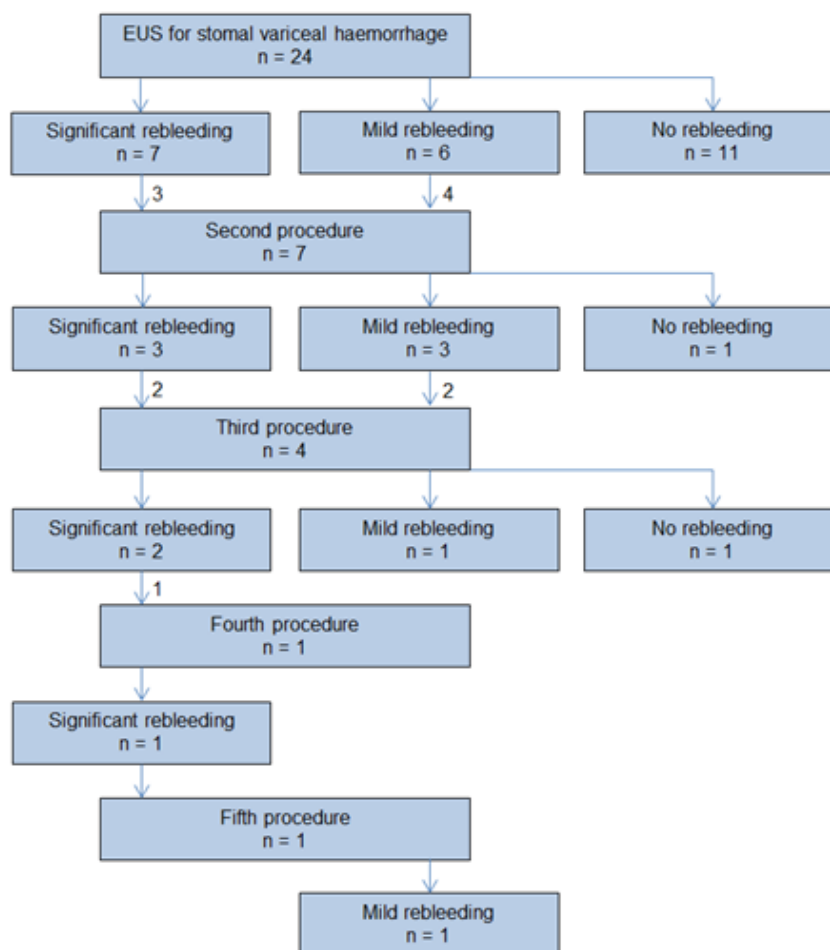


Figure 6 Flowchart of rebleeding and reintervention. Numbers denote number of patients at each step. EUS, endoscopic ultrasound.

use and potentially having fewer adverse events.^{16 26} One recent randomised controlled trial in acute gastric variceal haemorrhage has shown similar effectiveness between cyanoacrylate and thrombin, with reduced complications in the thrombin group.²⁷ Although there are no dedicated studies in parastomal varices, there are potential advantages to using thrombin over cyanoacrylate.

The technique of EUS embolisation described has advantages over fluoroscopically guided interventional radiology procedures to embolise parastomal varices. The risks associated with vascular access (transjugular

or transhepatic) are avoided, and procedure time and cost are likely to be lower with EUS. Concurrent fluoroscopy could be performed with EUS technique to confirm there is no migration of the coil from the target vessel; however, in our experience, B-mode and Doppler ultrasound are sufficient to visualise coil placement within the varix safely and efficaciously. Obtaining simultaneous fluoroscopic views would not justify the additional time, expense, complexity and radiation exposure required. If coil migration is deemed to be high risk, fluoroscopic imaging might be deemed necessary.

Table 3 SR occurrences by procedure number

Procedure	n	Number with SR following procedure	When SR occurred, median time to SR after the endoscopic ultrasound procedure (months)
First	24	7	10.8
Second	7	3	13.5
Third	3	2	5.8
Fourth	1	1	4.3
Fifth	1	0	–

SR, significant rebleeding.

Efficacy

There was a high burden of liver disease among the patients in this study, with median MELD Score of 12 associated with 3-month mortality of 6.0%²⁸ and a quarter of patients having MELD Score >20. All had significant stomal bleeding prior to the procedure and recurrence is not unexpected when the underlying portal hypertension has not been corrected. Overall, 100% of patients had required recent admission to hospital for bleeding or documented blood transfusions prior to their first procedure.

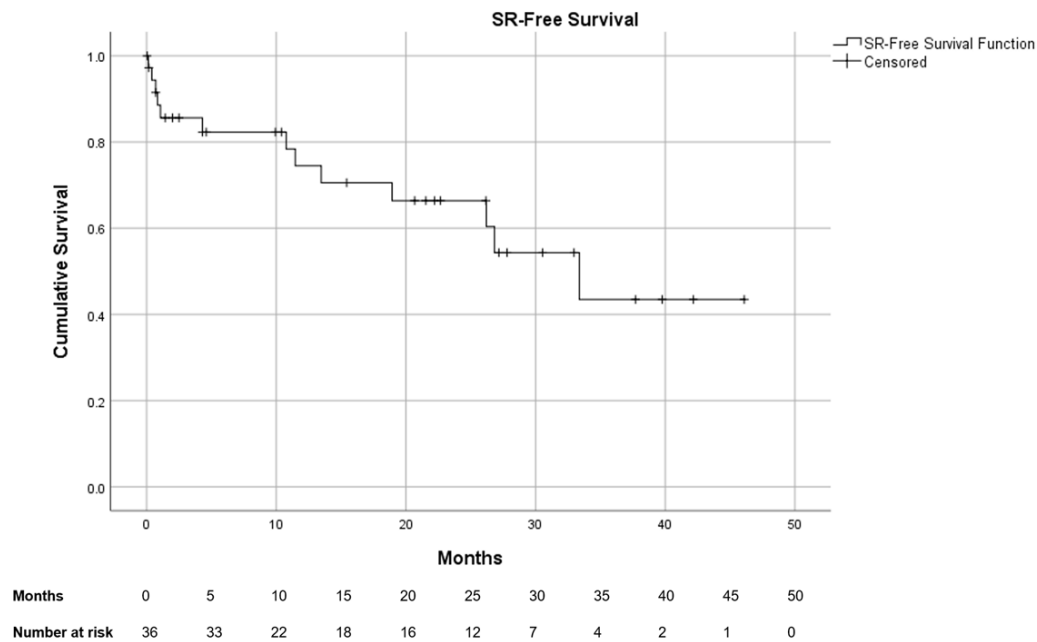


Figure 7 Significant rebleeding (SR)-free survival following endoscopic ultrasound-guided embolisation of stomal varices, all procedures included. Censored points denote time of last available follow-up information or death.

Our results showed 100% technical success over 37 procedures, which demonstrates that the EUS method is able to reliably identify a target vessel, insert coil(s) where required and inject thrombin to thrombose the vessel.

SR-free survival of 80.8% at 1 year following first procedure suggests a significant improvement in the degree of bleeding from parastomal varices. In patients who did suffer from recurrent bleeding, median time to

Table 4 Comparison of categorical variables using Kaplan-Meier estimation to determine SR-free survival and log-rank analysis to determine significance

Variable	Estimated mean SR-free survival	95% CI lower	95% CI upper	P value
Male	22.5	16.0	28.9	0.351
Female	31.5	22.9	40.1	
Emergency procedure	29.8	22.2	37.3	0.418
Elective procedure	25.1	14.7	35.6	
Age \geq 59.0 years	20.6	12.5	28.8	0.023
Age<59.0 years	36.4	28.4	44.3	
Thrombin only	25.8	18.4	33.2	0.536
Coil and thrombin	31.4	21.0	41.8	
Presence of gastro-oesophageal varices	27.0	18.1	35.8	0.275
Absence of gastro-oesophageal varices	31.4	22.9	39.8	
Patient treated with beta-blocker	25.5	18.7	32.2	0.211
Patient not treated with beta-blocker	40.7	31.1	50.2	
First procedure	32.8	25.0	40.6	0.142
Second procedure	21.7	12.7	30.7	
Third procedure	8.6	1.8	15.4	

Estimated mean survival is dependent and is limited to the largest survival time if data are censored. P values demonstrate a significantly lower mean SR-free survival for patients above the median age of 59.0 years.
SR, significant rebleeding.

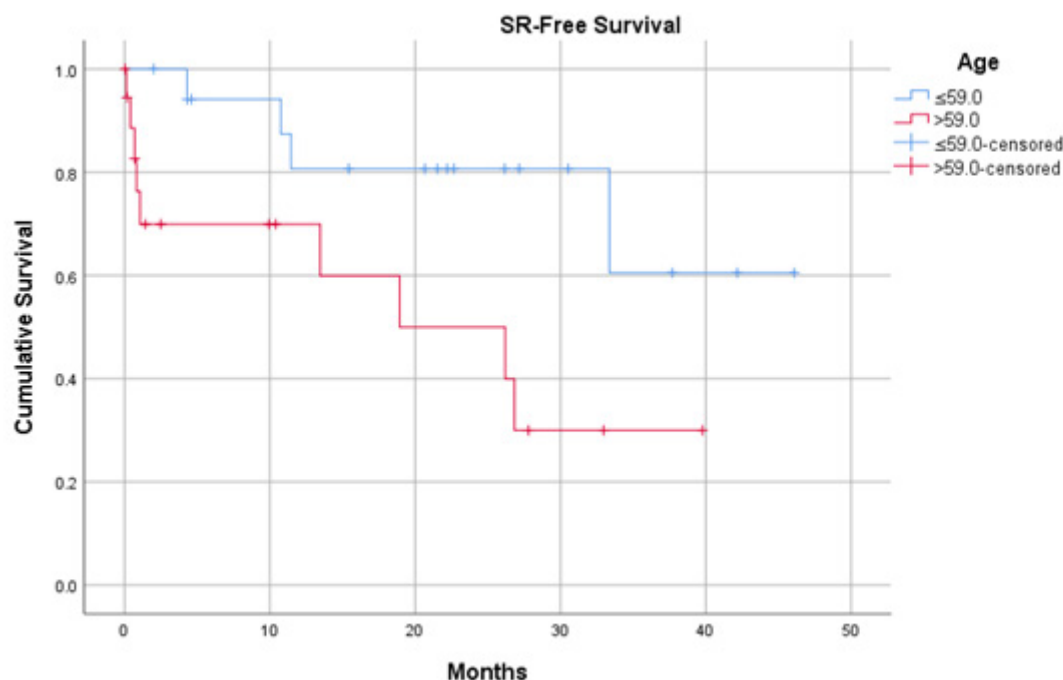


Figure 8 Significant rebleeding (SR)-free survival, patients grouped above or below median age (59 years) at time of procedure. Censored points denote time of last available follow-up information or death. Statistically significant difference between groups ($p=0.023$).

documentation was 10.8 months. These results demonstrate a reduction in severe bleeding at least the short-to-medium term following embolisation. There was no significant difference in SR-free survival following first, second or third intervention, which suggests that repeat procedures are also effective.

Oey *et al*²⁰ reported an estimated SR-free survival rate of 77% at 1 year for all ectopic variceal bleeding treated with TIPSS, using similar end-points to this study. However, only 1 of 21 patients in their series with paraesophageal varices had significant rebleeding. The numbers of patients included in both studies are limited, and the results are not directly comparable, but they suggest that

where TIPSS is feasible it may be superior to EUS-guided embolisation.

There was a higher level of rebleeding among older patients. There are multiple age-related physiological factors which could influence recurrence rates (eg, changes in the vascular wall) but the underlying mechanism for this relationship is unknown.

In our experience, we have not identified any vessels previously treated with coils which showed flow on subsequent procedures (recanalisation). It is more difficult to identify in retrospect vessels previously treated with thrombin alone; however, our experience suggests that recurrence is predominantly due to the development of new collaterals rather than recanalisation of treated varices, although this could be investigated in future studies.

Safety

In our series of 37 procedures, there were two instances of postprocedural fever, which were treated with antibiotics. The aetiology of this is unclear; however, both patients were treated with antibiotics. Three patients suffered postprocedural pain, which was self-limiting. It is possible that a mild inflammatory response should be expected following venous thrombosis, as recognised in deep venous thrombosis and arterial embolisation procedures.^{29 30} In patients who were in-patient at the time of procedure, median time to discharge was 3 days and for elective cases the median stay was 1 day, as per our protocol.

Table 5 Comparison of continuous variables

Variable	HR	95% CI lower	95% CI upper	P value
Age, years	1.072	1.007	1.142	0.030
Model for End-stage Liver Disease Score	0.992	0.903	1.089	0.859
Child-Pugh Score	0.855	0.606	1.206	0.373
Units of thrombin used	1.000	1.000	1.000	0.356
Time since stoma formation, years	1.024	0.978	1.072	0.310

HR describes relative risk of significant rebleeding event per unit increase in variable. P values demonstrate a significant correlation with age.

No serious complications were identified in our cohort of patients, and no stomal complications such as necrosis, ulceration or stricturing were reported. Such stomal complications have been reported with the use of sclerosants such as sodium morrhuate or sodium tetradecyl sulphate in parastomal varices.^{3 31}

Limitations

This is a retrospective study with inherent limitations in the completeness and accuracy of data collection. There is no control group of patients who did not undergo the procedure, and benefit can only be inferred by comparing the severity of bleeding before and after the procedure.

This study does not compare EUS-guided embolisation with other embolisation techniques or occlusive agents; however, the potential advantages of this particular technique are outlined. As with any novel technique, there is some difficulty in sharing knowledge, which may limit the uptake of this technique in other centres. In particular, the decisions of whether or not to use coils, and what size of coils to use are based on endosonographer's experience, depending on the size of the vessel and flow rate.

CONCLUSION

To our knowledge, EUS-guided embolisation of parastomal varices using thrombin has not previously been described. In the context of a difficult to treat problem in complex patients who are unable to undergo more definitive procedures, our results suggest this technique can provide a significant benefit at least in the short-term to mid-term. Importantly, the procedure is safe, minimally invasive and well-tolerated, allowing for multiple treatments if required. Further prospective studies shall help to establish its role in standard of management of bleeding parastomal varices.

Contributors BSM designed and oversaw the study. AWM performed the data collection with contribution from CS and JO. AWM, BSM and DT analysed the data. DT is the guarantor. All authors wrote the manuscript.

Funding The authors have not declared a specific grant for this research from any funding agency in the public, commercial or not-for-profit sectors.

Competing interests DT has received income from speaker fees and consultancy work with W.L. Gore and Associates. Other authors declared no competing interests.

Patient consent for publication Not applicable.

Ethics approval This study was approved as a service evaluation project by University Hospitals Birmingham NHS Foundation Trust Clinical Audit Registration & Management System.

Provenance and peer review Not commissioned; externally peer reviewed.

Data availability statement Data are available upon reasonable request.

Supplemental material This content has been supplied by the author(s). It has not been vetted by BMJ Publishing Group Limited (BMJ) and may not have been peer-reviewed. Any opinions or recommendations discussed are solely those of the author(s) and are not endorsed by BMJ. BMJ disclaims all liability and responsibility arising from any reliance placed on the content. Where the content includes any translated material, BMJ does not warrant the accuracy and reliability of the translations (including but not limited to local regulations, clinical guidelines, terminology, drug names and drug dosages), and is not responsible for any error and/or omissions arising from translation and adaptation or otherwise.

Open access This is an open access article distributed in accordance with the Creative Commons Attribution Non Commercial (CC BY-NC 4.0) license, which permits others to distribute, remix, adapt, build upon this work non-commercially, and license their derivative works on different terms, provided the original work is properly cited, appropriate credit is given, any changes made indicated, and the use is non-commercial. See: <http://creativecommons.org/licenses/by-nc/4.0/>.

ORCID iDs

Andrew Todd <http://orcid.org/0000-0001-9874-4523>

Sharan Suresh Wadhvani <http://orcid.org/0000-0002-1042-9105>

Dhiraj Tripathi <http://orcid.org/0000-0001-9043-6382>

REFERENCES

- Pennick MO, Artiukh DY. Management of parastomal varices: who re-bleeds and who does not? A systematic review of the literature. *Tech Coloproctol* 2013;17:163–70.
- Fucini C, Wolff BG, Dozois RR. Bleeding from peristomal varices: perspectives on prevention and treatment. *Dis Colon Rectum* 1991;34:1073–8.
- Spier BJ, Fayyad AA, Lucey MR, et al. Bleeding stomal varices: case series and systematic review of the literature. *Clin Gastroenterol Hepatol* 2008;6:346–52.
- Scaletsky R, Wright JK, Shaw J, et al. Ileal conduit venous varices from portal hypertension as a cause of recurrent, massive hemorrhage: case report and review of the literature. *J Urol* 1994;151:417–9.
- Taslakian B, Faraj W, Khalife M, et al. Assessment of surgical portosystemic shunts and associated complications: the diagnostic and therapeutic role of radiologists. *Eur J Radiol* 2015;84:1525–39.
- Tripathi D, Stanley AJ, Hayes PC, et al. Transjugular Intrahepatic portosystemic stent-shunt in the management of portal hypertension. *Gut* 2020;69:1173–92.
- Lashley DB, Saxon RR, Fuchs EF, et al. Bleeding Ileal conduit stomal varices: diagnosis and management using transjugular transhepatic angiography and embolisation. *Urology* 1997;50:612–4.
- Alkari B, Shaath NM, El-Dhuwaib Y, et al. Transjugular intrahepatic porto-systemic shunt and variceal embolisation in the management of bleeding stomal varices. *Int J Colorectal Dis* 2005;20:457–62.
- Samaraweera RN, Feldman L, Widrich WC, et al. Stomal varices: percutaneous transhepatic embolisation. *Radiology* 1989;170:779–82.
- Kishimoto K, Hara A, Arita T, et al. Stomal varices: treatment by percutaneous transhepatic coil embolisation. *Cardiovasc Intervent Radiol* 1999;22:523–5.
- Saad WE, Saad NE, Koizumi J. Stomal varices: management with decompression tips and transvenous obliteration or sclerosis. *Tech Vasc Interv Radiol* 2013;16:176–84.
- DeWitt JM. Endoscopic ultrasound guided injection of 2-Octylcyanoacrylate for treatment of refractory bleeding from peristomal varices. *Gastrointestinal Endoscopy* 2016;83:AB475–6.
- Shekhar C, O'Rourke J, Tripathi D, et al. Feasibility of direct EUS guided embolisation of recurrent bleeding parastomal varices. *Gut* 2018;67:A171–2.
- Mohan BP, Chandan S, Khan SR, et al. Efficacy and safety of endoscopic ultrasound-guided therapy versus direct endoscopic glue injection therapy for gastric varices: systematic review and meta-analysis. *Endoscopy* 2020;52:259–67.
- Tripathi D, Stanley AJ, Hayes PC, et al. UK guidelines on the management of variceal haemorrhage in cirrhotic patients. *Gut* 2015;64:1680–704.
- Smith MR, Tidswell R, Tripathi D. Outcomes of endoscopic human thrombin injection in the management of gastric varices. *Eur J Gastroenterol Hepatol* 2014;26:846–52.
- Frost J, Hebb S. EUS-guided thrombin injection for management of gastric fundal varices. *Endosc Int Open* 2018;06:E664–8.
- O'Rourke J, Shekhar C, Tripathi D. PWE-093 treatment of gastric fundal varices with EUS guided embolisation combining coil placement with thrombin injection. *Gut* 2018;A118LP–9.
- Kamath PS, Kim WR, Advanced Liver Disease Study Group. The model for end-stage liver disease (MELD). *Hepatology* 2007;45:797–805.
- Oey RC, de Wit K, Moelker A, et al. Variable efficacy of TIPSS in the management of ectopic variceal bleeding: a Multicentre retrospective study. *Aliment Pharmacol Ther* 2018;48:975–83.
- Qiu B, Li K, Dong X, et al. Transjugular intrahepatic portosystemic shunt for portal hypertension in hepatocellular carcinoma with portal vein tumor thrombus. *Cardiovasc Intervent Radiol* 2017;40:1372–82.

- 22 Freedman AM, Sanyal AJ, Tisnado J, *et al.* Complications of transjugular Intrahepatic portosystemic shunt: a comprehensive review. *Radiographics* 1993;13:1185–210.
- 23 Garcia-Tsao G, Abraldes JG, Berzigotti A, *et al.* Portal hypertensive bleeding in cirrhosis: risk stratification, diagnosis, and management: 2016 practice guidance by the American Association for the study of liver diseases. *Hepatology* 2017;65:310–35.
- 24 Rios Castellanos E, Seron P, Gisbert J, *et al.* Endoscopic injection of cyanoacrylate glue versus other endoscopic procedures for acute bleeding gastric varices in people with portal hypertension. *CDSR* 2015:5.
- 25 Hwang SS, Kim HH, Park SH, *et al.* N-Butyl-2-cyanoacrylate pulmonary embolism after endoscopic injection sclerotherapy for gastric variceal bleeding. *J Comput Assist Tomogr* 2001;25:16–22.
- 26 Tripathi D, Hayes PC. Endoscopic therapy for bleeding gastric varices: to clot or glue *Gastrointest Endosc* 2008;68:883–6.
- 27 Lo G-H, Lin C-W, Tai C-M, *et al.* A prospective, randomised trial of thrombin versus cyanoacrylate injection in the control of acute gastric variceal hemorrhage. *Endoscopy* 2020;52:548–55.
- 28 Wiesner R, Edwards E, Freeman R, *et al.* Model for end-stage liver disease (MELD) and allocation of donor livers. *Gastroenterology* 2003;124:91–6.
- 29 Barba R, Di Micco P, Blanco-Molina A, *et al.* Fever and deep venous thrombosis. findings from the RIETE Registry. *J Thromb Thrombolysis* 2011;32:288–92.
- 30 Arslan M, Degirmencioglu S. Risk factors for postembolisation syndrome after transcatheter arterial chemoembolisation. *Curr Med Imaging Rev* 2019;15:380–5.
- 31 Wolfsen HC, Kozarek RA, Bredfeldt JE, *et al.* The role of endoscopic injection sclerotherapy in the management of bleeding peristomal varices. *Gastrointest Endosc* 1990;36:472–4.