



Aortic aneurysm and dissection in pregnancy: A case report

Jennifer M. Chin ^{*}, Marguerite L. Bartholomew

University of Hawaii, Department of Obstetrics, Gynecology, and Women's Health, 1319 Punahou St, Ste 824, Honolulu, HI 96826, USA

ARTICLE INFO

Article history:

Received 14 September 2020

Received in revised form 26 September 2020

Accepted 30 September 2020

Available online xxxx

Keywords:

Aortic aneurysm

Aortic dissection

Pregnancy

Case report

ABSTRACT

We describe a 24-year-old pregnant woman at 34 weeks of gestation who presented to a community hospital with sharp chest pain radiating to her back. She was found to have a 6 cm ascending aortic aneurysm despite not having any established risk factors. She was transported by air ambulance to a tertiary-care hospital. She delivered a live female neonate via cesarean delivery. Her postpartum course was notable for multiple episodes of chest pain and multiple imaging studies that were read as negative for aortic dissection. Definitive valve surgery was postponed by the cardiothoracic surgeons to allow for recovery from severe preeclampsia, treatment of endometritis, and due to concerns for uterine bleeding while on anticoagulation during cardiopulmonary bypass. She was eventually transferred to another hospital in another state for valve-sparing surgery. During transport, she developed a pulmonary embolism, and after arrival an aortic dissection was confirmed. She received a mechanical aortic valve replacement and the aneurysm was repaired. She returned home and recovered without complication. A gene panel revealed a heterozygous pathogenic variant of the Filamin A gene. Aortic aneurysms during pregnancy are rare, and aortic dissections are more rare. We recommend expeditious surgical treatment, a heightened index of suspicion, and testing for a genetic cause of aneurysm when diagnosed in a pregnant or postpartum woman with no known risk factors.

© 2020 The Authors. Published by Elsevier B.V. This is an open access article under the CC BY-NC-ND license (<http://creativecommons.org/licenses/by-nc-nd/4.0/>).

1. Introduction

Aortic aneurysms in pregnancy are rare but potentially fatal. Aortic dissections in pregnancy account for 0.1–0.4% of all dissections and represent 0.0004% of all pregnancies [1]. Maternal mortality ranges from 21% to 53% [2]. Among women with aortic aneurysms less than 40 years old, pregnancy has been shown to increase the risk of dissection by up to 25-fold [1]. This increased risk is likely due to increased cardiac output, heart rate, and circulating volume, and is worsened by preeclampsia. Estrogen and progesterone have been proven to change the microstructure of the media and intima, causing fragmentation of reticulum fibers and loss of corrugation of elastic fibers [3]. These vascular changes are generally the most pronounced in the third trimester, when 50% of dissections occur, and in the peripartum period, when 33% of dissections occur [4]. Aneurysm in a young woman usually occurs in the setting of an underlying connective tissue disorder or aortopathy, such as Marfan's disease, Ehlers-Danlos syndrome, bicuspid aorta, Loeys-Dietz syndrome, familial thoracic aorta dissection syndrome, Turner's syndrome, or aneurysm-osteoarthritis. We describe a case of newly diagnosed aortic aneurysm in the setting of severe

preeclampsia in a pregnant woman without known risk factors, which ultimately resulted in an acute Stanford Type A dissection.

2. Case Presentation

A 24-year-old G1 Marshallese woman at 34 weeks of gestation presented to the emergency department due to sharp chest pain radiating to her back. Prenatal course was significant for insufficient prenatal care. Blood pressure was 190/70 mmHg, oxygen saturation was 92% on room air, and other vitals were normal. Physical exam was notable for a height of five feet, normal uvula, hyperflexible joints, velvety skin, and a café au lait macule (shown in Fig. 1). Fetal heart rate tracing was reassuring, and no contractions were noted.

She had no known medical problems nor surgeries and was not taking medications regularly. She denied family history of cardiac or genetic disorders. Our differential diagnosis at this point included severe preeclampsia, myocardial infarction, and aortic dissection. Significant laboratory values included a platelet count of 99×10^9 per liter and a urine protein creatinine ratio of 444. Electrocardiography showed normal sinus rhythm with a rightward axis, Q waves in lead III, and T-wave inversions in lead III. Chest x-ray (CXR) showed cardiomegaly and a widened mediastinum. Computed tomography angiography (CTA) showed a 6.2 cm ascending thoracic aortic aneurysm. Trans-thoracic echocardiogram showed a 5.8 cm ascending aortic aneurysm, severe aortic regurgitation, pericardial effusion, and ejection fraction of 50–55%.

Abbreviations: CXR, chest x-ray; CTA, computed tomography angiography; CT, cardiothoracic; CPB, cardiopulmonary bypass.

* Corresponding author.

E-mail addresses: chinj@hawaii.edu (J.M. Chin), mbarthol@hawaii.edu (M.L. Bartholomew).



Fig. 1. Café-au-lait macule.

She received oral nifedipine 60 mg, IV labetalol 20 mg, and IV magnesium sulfate 2 mg for seizure prophylaxis, and was transported to a tertiary-care hospital due to lack of cardiothoracic and neonatology services available. The diagnosis was 6 cm ascending aortic aneurysm and severe preeclampsia. Maternal fetal medicine service accepted the patient, and the timeline of her care is shown in Fig. 2. Cardiology, cardiothoracic (CT) surgery, and anesthesia were consulted. She was started on an esmolol drip and underwent a primary low transverse cesarean delivery under spinal anesthesia. During the cesarean delivery, permissive hypotension was maintained to reduce risk of aortic rupture. The delivery was complicated by uterine atony treated with uterotonics, and final estimated blood loss was 800 mL. The live neonate was discharged home. Immediately after delivery, a transesophageal echocardiogram was performed which revealed no dissection, but was limited by patient discomfort. She was transitioned to an intravenous labetalol drip and started on subcutaneous unfractionated heparin 5000 units BID for venous thromboembolism prophylaxis and oral diazepam 10 mg TID for seizure prophylaxis for 24 h. A repeat CTA showed an aortic aneurysm with a maximum diameter of 5.9 cm. The plan per CT surgery was for aortic valve replacement immediately if dissection occurred but after the postpartum period if dissection did not occur. Due to her age, plans were made for transfer to an out-of-state hospital that specialized in the David procedure, which would eliminate the need for lifelong anticoagulation and decomplicate future pregnancies. During her immediate postoperative course, she had several episodes of chest pain with negative CTA scans.

She was airlifted and developed acute respiratory distress, which required intubation. Once she arrived, she was diagnosed with a pulmonary embolism and immediately taken to the operating room, where she was found to have a thin-walled ascending aortic aneurysm over 6 cm, a large dissection, and a translucent non-coronary sinus. Due to

the retraction of the leaflets of the aortic valve, it was not able to be salvaged. She thus underwent an aortic root replacement with a mechanical valve, replacement of her ascending aorta, an aortic arch replacement, reimplantation of her coronary buttons, and left axillary artery perfusion graft. Her postoperative course was significant for pulmonary hypertension, which was treated with nitrous oxide then oral sildenafil 20 mg TID. Anticoagulation was transitioned to warfarin. Genetics was consulted and discovered a heterozygous pathogenic variant of one allele of FLNA. Testing for Marfan, Loeys-Dietz, Ehlers-Danlos, and tuberous sclerosis were negative. Once the patient became therapeutic on warfarin, she was discharged home with warfarin 10 mg daily, metoprolol 75 mg daily, and losartan 12.5 mg daily, all of which she had tolerated during her hospitalization.

Before discharge, the patient expressed gratitude for the extensive care she had received and was anxious to return home to her family and her new baby.

3. Discussion

We describe a patient who presented with chest pain in the third trimester and was diagnosed with a large aortic aneurysm that progressed to Stanford type A aortic dissection after a delay of 18 days before definitive repair. Prompt recognition of aortic aneurysm in pregnancy is essential due to the high risk of progression to aortic dissection. Table 1 shows types of aortic dissections and associated mortality rates. It is important to select the correct imaging modality. Transesophageal echocardiography is usually sufficient for diagnosing dissection; however, it has significant inter-observer variability. CTA imaging accuracy approaches 100% with the newest machines. Magnetic resonance angiogram is able to properly evaluate left ventricular dysfunction; however, most imaging units refer acute patients to CTA due to the significant time difference [5,6].

The patient in the present case lacked traditional risk factors for aortic dissection, including Marfan's disease, Ehlers-Danlos syndrome, bicuspid aorta, and Loeys-Dietz syndrome. Her genetic workup revealed a heterozygous pathogenic variant of one allele of FLNA, which has been linked to cardiac valvular defects, aortic aneurysms, and joint hypermobility [7].

In patients with a known aneurysm, vaginal delivery is reserved for aortic root diameters less than 4 cm [8]. Cesarean delivery is recommended for aortic root diameters over 4 cm, significant progression of the aneurysm, or previous dissection or repair [1].

When aortic aneurysm or dissection occurs during pregnancy, management is largely based on case series and expert opinion. Table 2 shows society recommendations for surgical intervention in nonpregnant patients. The presence of pregnancy, aortopathy, genetic disorders, short stature, or preeclampsia may lower thresholds for surgical repair as risk for dissection and death are increased. Optimal management for the health of the mother and fetus depends on the size of the aneurysm, presence of dissection or aortopathy, gestational age, and desires for the pregnancy. If surgical repair is indicated before fetal viability, termination of pregnancy should be considered due to the high rate of fetal loss – up to 33% [9]. After fetal viability, delivery before repair may be considered with acceptance of prematurity complications. Continuing

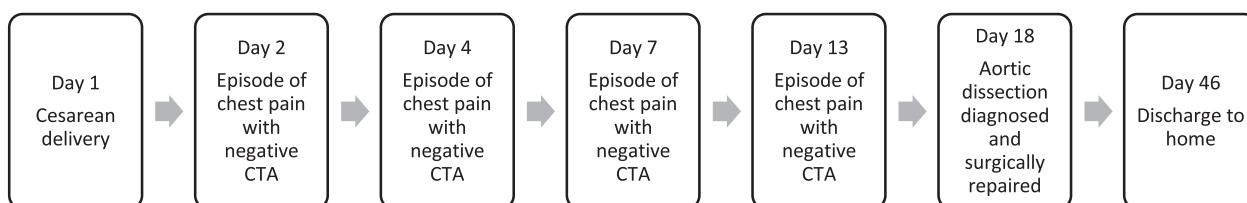


Fig. 2. Timeline of episodes of care.

Table 1
Types of Aortic Dissections And Associated Mortality Rates [2].

| Type of dissection | Description | Mortality |
|--------------------|----------------------------------|-----------|
| Stanford A | Involves ascending aorta | 40% |
| Stanford B | Does not involve ascending aorta | 10% |

Table 2
Comparison of Society Guidelines for Surgical Intervention of Thoracic Ascending Aortic Aneurysms [6].

| Society | Recommendation |
|---------------------------------------|---|
| Canadian Society for Vascular Surgery | Diameter at or above 5 cm, less if growing faster than 10% per year |
| Japanese Circulation Society | Diameter at or above 6 cm, 5 cm if accompanied by pain |
| European Society of Cardiology | Diameter greater than 5.5 cm, less if indication for surgery on the aortic valve to combine surgery |

pregnancy during cardiopulmonary bypass (CPB) can be considered for women with compelling surgical indications. During CPB, several modifications can improve the fetal mortality rate below 20%, including performing the procedure under normothermic conditions, high pump flow, short CPB and aortic cross-clamp time, perfusion above 70 mmHg and hematocrit over 28% [4,10]. If surgery is indicated after 32 weeks, delivery should be by cesarean section, followed immediately by cardiac surgery [1]. For the present patient, one of the main concerns was risk of uterine bleeding if CPB were done soon after cesarean delivery. However, in a large case series, mothers who had CPB initiated immediately after cesarean delivery had an average blood loss of 800 mL and none had excessive bleeding requiring abdominal packing or hysterectomy [10].

Equally as important as managing acute complications of aortic aneurysms in pregnancy is planning for or prevention of the next pregnancy. The patient described here received a 3-year subdermal contraceptive implant.

The strengths of our case report include the unique presentation of a new diagnosis of aortic aneurysm in a young pregnant woman with no known risk factors and multiple imaging studies that showed no evidence of dissection. Limitations of our case report include a significant delay in definitive cardiothoracic surgery due to the patient's age and postpartum state as well as insufficient prenatal care.

This case demonstrates that a high index of suspicion and CXR were life saving for a young pregnant woman. Aortic aneurysm is rare in young women unless there is an underlying predisposition; therefore, workup for aortopathy and genetic disorders is essential to accurately triage timing of life-saving surgery. Pregnancy and its associated complications increase the risk of dissection and rupture; thus, waiting for confirmation of dissection in the presence of recurrent symptoms and a large aneurysm is not necessary.

Contributors

Jennifer M. Chin is the primary author and was the chief resident taking care of the patient described, conducted the review of the literature and wrote the manuscript.

Marguerite L. Bartholomew is the anchor author and was the attending physician for this patient, provided guidance and extensively edited the manuscript.

Declaration of Competing Interest

The authors declare that they have no conflict of interest regarding the publication of this case report.

Funding

No funding from an external source supported the publication of this case report.

Patient Consent

Obtained.

Provenance and Peer Review

This case report was peer reviewed.

Acknowledgements

We gratefully acknowledge the cardiology, cardiothoracic, genetics, and anesthesia teams who assisted in the multidisciplinary care of this patient. We also acknowledge our patient, without whom this case report would not have been possible. This case report was approved by the Queens' Medical Center Research and Institutional Review Committee.

References

- [1] Zhu JM, Ma WG, Peters S, et al. 2017. Aortic dissection in pregnancy: Management Strategy and outcomes. *Ann. Thorac. Surg.* 2017;103:1199–206.
- [2] S. Rajagopalan, N. Nwazota, S. Chandrasekar, Outcomes in pregnant women with acute aortic dissections: A review of the literature from 2003 to 2013. *Int. J. Obstet. Anesth.* 23 (4) (2014) 348–356.
- [3] I.M. van Hagen, J.W. RoosHesseling, Aorta pathology and pregnancy, *Best Pract. Res. Clin. Obstet. Gynaecol* 28 (4) (2014) 537–550.
- [4] D.A. Smok, Aortopathy in pregnancy, *Semin. Perinatol.* 38 (2014) 295–303.
- [5] G. Hartnell, Imaging of aortic aneurysms and dissection: CT and MRI, *J. Thorac. Imaging* 16 (1) (2001) 35–46.
- [6] E. Saliba, Y. Sia, The ascending aortic aneurysm: When to intervene? *Int. J. Cardiol. Heart Vasc.* 6 (2015) 91–100.
- [7] FLNA gene, Available at, <https://ghr.nlm.nih.gov/gene/FLNA> Accessed 3 June 2020.
- [8] L. Muino Mosquera, J. De Backer, Managing aortic aneurysms and dissections during pregnancy, *Expert. Rev. Cardiovasc. Ther.* 13 (2015) 703–714.
- [9] L. Houston, M. Tuuli, G. Macones, Marfan syndrome and aortic dissection in pregnancy, *Obstet. Gynecol.* 117 (2011) 956–960.
- [10] A.S. John, F. Gurley, H.V. Schaff, et al., Cardiopulmonary bypass during pregnancy, *Ann. Thorac. Surg.* 91 (4) (2011) 1191–1196.