

# Aorto-duodenal fistula: a rare but serious complication of gastrointestinal hemorrhage. A case report

---

Jolanta Šumskienė<sup>1,2</sup>,

Edita Šveikauskaitė<sup>1</sup>,

Jūratė Kondrackienė<sup>1,2</sup>,

Limas Kupčinskas<sup>1,2</sup>

<sup>1</sup>*Hospital of the Lithuanian University of Health Sciences  
Kauno klinikos,  
Gastroenterology Department,  
Kaunas, Lithuania*

<sup>2</sup>*Lithuanian University of Health Sciences*

A primary aortoduodenal fistula (PADF) is a rare cause of gastrointestinal bleeding that is difficult to diagnose (and sometimes not diagnosed until a laparotomy.) A PADF is associated with high mortality if undiagnosed and untreated (the mortality rate of nearly 100% in the absence of a surgical intervention). While this condition is extremely rare with an incidence rate at autopsy of 0.04% to 0.07%, a secondary ADF occurs much more commonly (the post-operative incidence of 0.5% to 2.3%) and is due to prior aortic surgery and/or the placement of a synthetic aortic graft. It should be considered in any elderly patient who presents with upper gastrointestinal bleeding in the context of a known abdominal aortic aneurysm or without it when no identifiable source of bleeding is found. We present an autopsy case of a 59-year-old man with no history of an abdominal aortic aneurysm who presented with intermittent massive gastrointestinal bleeding. The autopsy revealed a pinhole fistula. It was identified between an atherosclerotic abdominal aortic aneurysm and the lower horizontal part of the duodenum. Our case indicates that the aortoenteric fistula can result in fatal gastrointestinal bleeding. This case is unique in that the fistula formed as a result of a complex atherosclerotic abdominal aorta and a localized necrotizing granulomatous aortitis the etiology of which was not clear.

**Keywords:** primary aortoduodenal fistula, gastrointestinal bleeding

---

## INTRODUCTION

A primary aortoduodenal fistula (PADF) is a communication between the aorta and the enteric tract without any previous vascular intervention, e. g., aortic grafting. Most frequently, PADF is a lethal condition that requires a high index of suspicion. Delay in diagnosis and treatment has been historically associated with extremely high mortality (1).

Correspondence to: Jolanta Šumskienė, Hospital of the Lithuanian University of Health Sciences, Kauno klinikos, Gastroenterology department, Kaunas, Lithuania. E-mail: j.sumskiene@gmail.com

The first case report of a PADF was described by Salmon in 1843. Since then, about 250 cases have been reported in literature (2).

In this paper we present the first case of a PADF in our clinic and discuss the diagnosis and management of the condition, the fallibility of diagnostic investigations, and the importance of having a clinical suspicion.

## Case Report

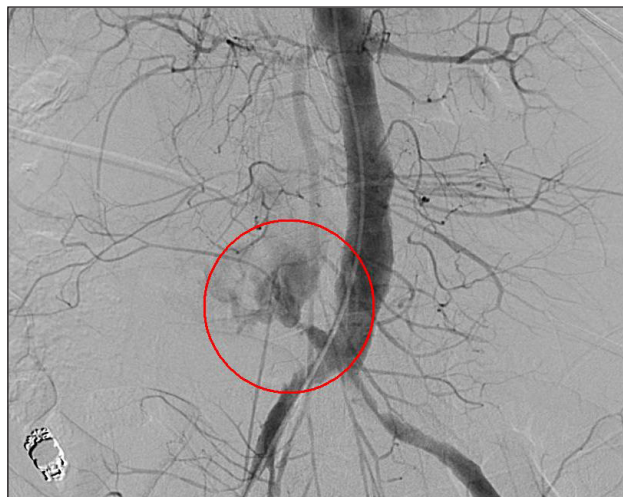A 59-year-old man was hospitalized after suffering from massive lower gastrointestinal bleeding.

The patient reported intermittent bleeding for two years which had worsened over the past six months. He also reported general weakness, feeling “dizzy”, abdominal pain with occasional bright red blood and clots per rectum. For this reason, he was hospitalized several times to find the exact bleeding location. No visible abnormalities were found during an upper GI tract endoscopy, colonoscopy, chest and abdominal computed tomography, and enteroscopy, but the suspicion was that the bleeding point was localized in the small intestine. A CT angiography – aortography with contrast – did not highlight an aneurysm or any signs of a leak. A diagnostic laparotomy was also performed but no abnormalities were found. The arterial blood pressure was 90/60–135/85 mmHg. The patient suffered from posthemorrhagic anaemia (hemoglobin level of 5.8, which had dropped from 12 g/dL). He had no previous surgery, trauma, a peptic ulcer, nor any other medical condition. No history of drug, alcohol or tobacco use. A review of systems was otherwise non-contributory.

During hospitalization, intense abdominal pain with massive bleeding from the lower GI tract occurred a few times and twice a transfusion of 2 U of packed red blood cells was required. One bleeding episode occurred on the first day of hospitalization. The patient was taken to the angiography suite where a flash aortography and a visceral angiography showed no active extravasation of the contrast material.

The patient was admitted with the diagnosis of GI bleeding of unknown etiology. An upper endoscopy, a colonoscopy, an echoscopy, an abdominal CT scan, and an enteroscopy were performed, which appeared to be normal. Capsule endoscopy with MiroCam–MC1000 was started. The last haemorrhagic attack recurred the same day. It manifested with sudden intense abdominal pain, profuse bleeding per rectum and haematemesis, acute hypotension and tachycardia (shock). The patient was resuscitated with intravenous fluids, haemostatic agents and a transfusion of packed red blood cells in the intensive care department. A repeated upper endoscopy showed bright red blood in the stomach and the duodenum, but no source of bleeding could be found. Capsule endoscopy views “online” showed fresh blood in the upper GI tract. An emergency repeated angiography revealed a small (0.5 cm) aneurysm close to the aortic bi-

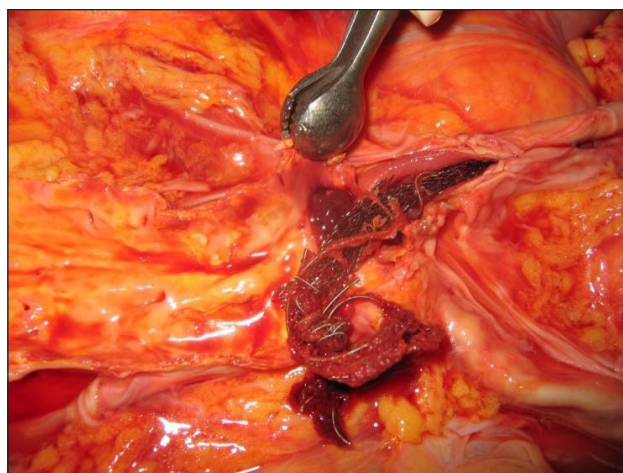
furcation and a massive haemorrhage that had not been detected two weeks before (Fig. 1). Embolization stopped extravasation, but intensive care procedures were unable to save the patient’s life.



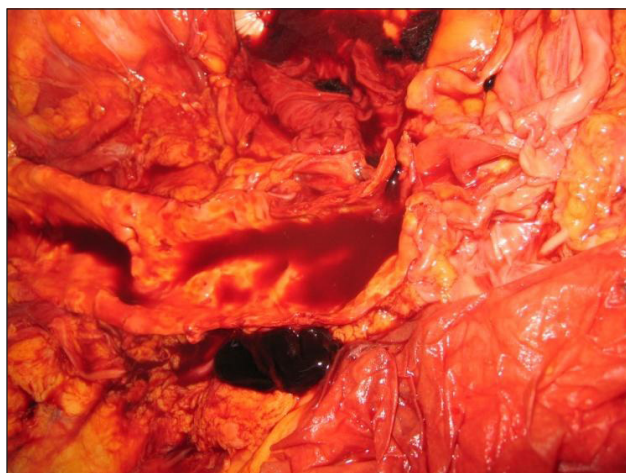
**Fig. 1.** Angiography revealed a small (0.5 cm) aneurysm close to the aortic bifurcation and a massive haemorrhage

## AUTOPSY FINDINGS

An internal examination revealed neither abdominal organ injury nor blood in the abdominal cavity. An abdominal aortic aneurysm (AAA) was located above the bifurcation of the aorta. An AAA with atherosclerosis thrust forward to the digestive duodenal wall (Figs. 2, 3). A pinhole rupture was located on the lower horizontal part of the duodenum. No other origin of bleeding was found in the gastrointestinal tract.



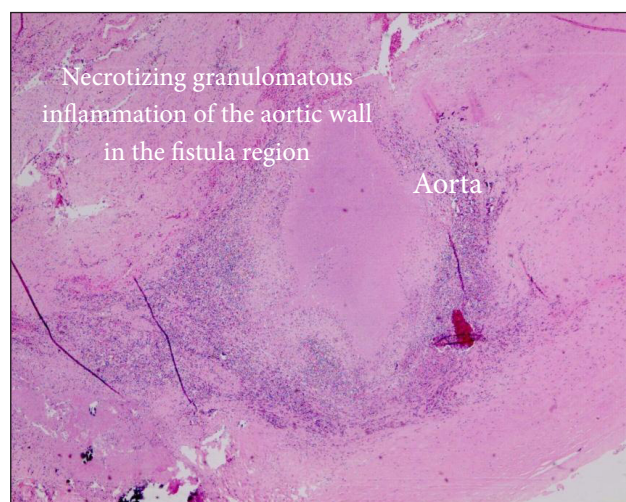
**Fig. 2.** Autopsy findings



**Fig. 3.** Autopsy findings: a fistula between an atherosclerotic abdominal aortic aneurysm and the lower horizontal part of duodenum

### Microscopic investigations

A histological examination revealed a necrotizing granulomatous inflammation in the aortic wall in the fistula region, but the exact cause of the granulomatous inflammation was not identified (Fig. 4).



**Fig. 4.** Microscopic investigations

### DISCUSSION

The most common site of primary aortoenteric fistulization (PAEF) is at the third portion of the duodenum because of its fixed retroperitoneal location overlying the aorta. A large autopsy series reported an incidence of PAEF of 0.04–0.07% (3–5). A fistula most commonly originates from an AAA, of which 85% are atherosclerotic. In our case, histological

examination revealed a necrotizing granulomatous inflammation in the aortic wall in the fistula region. Differential diagnosis and management demand a skilful interpretation of clinical findings and pathological evidence. They are classified into infections, vasculitis, an immunological aberration, leucocyte oxidase deficiency, hypersensitivity, chemicals, and neoplasia. Despite the correlation with clinical, serological, and other microbiological studies, some necrotizing granulomas remain unexplained (6).

Literature reports that PAEFs are often fatal, with a total mortality rate of 80–100% and a perioperative mortality rate of 18–63% (1–3, 7). The classic triad of symptoms – gastrointestinal bleeding, abdominal pain, and a pulsating abdominal mass – occurs in less than 25% of PAEF cases (6). The diagnosis and treatment of aortoenteric fistulas are difficult because of its nonspecific and subtle clinical presentation (2, 5). However, PAEF usually present with a herald bleeding prior to exsanguination. The time interval between the herald bleeding and the exsanguination is known to range from hours to months (8). The interval was about 6 months in the case of the patient discussed. Frequently, the choice of the diagnostic procedure is based on the clinical condition. In a hemodynamically stable patient with gastrointestinal bleeding, an endoscopy is the preferred primary procedure which provides valuable information (1–3). However, an endoscopy rarely reveals confirmatory evidence of a PAEF because stable patients do not often have active bleeding (1, 2, 8, 9). An endoscopy should be followed by a CT with contrast, and if there is consistent evidence of bleeding without an identifiable source, an angiogram should be considered. A CT might reveal the size, location, and degree of calcification of an AAA. In the clinical setting, the absence of identifiable bleeding lesions with initial gastrointestinal endoscopy is regarded by some as a strong indicator for laparotomy (10, 11). Recently, since the introduction of a capsule endoscopy for clinical use, small bowel bleeding from the ampulla of Vater into the terminal ileum can be easily visualized and defined (12).

### CONCLUSIONS

In summary, a diagnosis of a primary aortoenteric fistula should be considered in any patient known



to have an abdominal aortic aneurysm or lower abdominal pain associated with midline mass and upper gastrointestinal bleeding of unexplained etiology. The three most useful diagnostic modalities for detecting a PADF are an abdominal CT scan with intravenous contrast, an endoscopy, and an arteriography. A herald bleed is an indication for a prompt intervention. An endoscopy is the first step in diagnosis, while a CT and an arteriography may be used for confirmation. An emergency exploratory laparotomy should also be performed second time as soon as the diagnosis is considered.

Received 30 March 2016

Accepted 27 September 2016

## References

1. Bissacco D, Freni L, Attisani L, Barbetta I, Dallatana R, Settembrini R. Unusual clinical presentation of primary aortoduodenal fistula. *Gastroenterology Report*. 2014; 1–5, doi:10.1093/gastro/gou040.
2. Shehzad KL, Riaz A, Meyrick-Thomas J. Primary aortoduodenal fistula – a rare clinical entity. *J R Soc Med Sh Rep*. 2010; 1: 7. doi: 10.1258/shorts.2009.090430
3. Saers SJ, Scheltinga MR. Primary aortoenteric fistula. *Br J Surg*. 2005; 92: 143–52.
4. Lemos DW, Raffetto JD, Moore TC, Menzoian JO. Primary aortoduodenal fistula: a case report and review of the literature. *J Vasc Surg*. 2003; 37: 686–9.
5. Peck JJ, Eidemiller LR. Aortoenteric fistulas. *Arch Surg*. 1992; 127: 1191–3; discussion 1193–1194.
6. Aubry MC. Necrotizing granulomatous inflammation: what does it mean if your special stains are negative? *Modern Pathology*. 2012; 25: S31–8; doi:10.1038/modpathol.2011.155
7. Hohman D, Noghrehkar D, Sorensen V, Taylor E. Primary Aortoduodenal Fistula. *The Internet Journal of Internal Medicine*. 2008; 8: 1.
8. Tareen AH, Schroeder TV. Primary aortoenteric fistula: two new case reports and a review of 44 previously reported cases. *Eur J Vasc Endovasc Surg*. 1996; 12: 5–10.
9. Finch L, Heathcock RB, Quigley T, Jiranek G, Robinson D. Emergent treatment of a primary aortoenteric fistula with N-butyl 2-cyanoacrylate and endovascular stent. *J Vasc Interv Radiol*. 2002; 13: 841–3.
10. Delgado J, Jotkowitz AB, Delgado B, Makarov V, Mizrahi S, Szendro G. Primary aortoduodenal fistula: Pitfalls and success in the endoscopic diagnosis. *Eur J Intern Med* 2005.
11. Duncan JR, Renwick AA, Mackenzie I, Gilmore DG. Primary aortoenteric fistula: pitfalls in the diagnosis of a rare condition. *Ann Vasc Surg*. 2002; 16: 242–5.
12. Nakamura T, Terano A. Capsule endoscopy: past, present, and future. *J Gastroenterol*. 2008; 43: 93–9.

**Jolanta Šumskienė, Edita Šveikauskaitė,  
Jūratė Kondrackienė, Limas Kupčinskas**

## RETAS KRAUJAVIMO Į VIRŠKINAMĄJĮ TRAKTĄ ATVEJIS – KOMPLIKUOTA AORTOS ANEURIZMA

### Santrauka

PADF yra reta sunkiai diagnozuojama kraujavimo į virškinamąjį traktą priežastis. Autopsijų metu dėl kraujavimo į virškinimo traktą ji diagnozuojama 0,04–0,07 % mirusiųjų. Dažniausiai aortoduodeninės fistulizacijos vieta yra trečioji ir ketvirtoji dvylikapirštės žarnos (lot. *duodenum*) dalis. PADF priežastis paprastai yra aterosklerotinė pilvinės aortos aneurizma. Retesnės priežastys – infekcinis aortitas, sukeltas sifilio ar tuberkuliozės, infekuota (mikotinė) aortos aneurizma, kraujagyslių kolageninės ligos.

Aprašoma 59 m. amžiaus paciento ligos istorija, kuriam dvejus metus kartoja neaiškios kilmės kraujavimai į virškinamąjį traktą, tačiau priežastis nebuvo nustatyta. Pasikartojus gausiam kraujavimui, skubos tvarka atlikta angiografija. Aortos bifurkacijos srityje rasta nedidelė aortos sienelės aneurizma (0,5 cm diametro) ir susidariusi fistulė į dvylikapirštę žarną, iš kurios gausiai kraujavo. Angiografijos metu atliktas fistulės kanalo embolizavimas. Kraujavimas sustojo, tačiau ligonio būklė blogėjo, progresavo hemoraginis šokas, ir ligonis mirė. Aprašytas atvejis parodo, kad susiformavusios fistulės tarp aortos ir virškinamojo trakto gali būti pavojingos ir baigtis mirtimi. Susidariusios fistulės etiologija liko neaiški. Autopsijos metu, ištyrus histologiškai, diagnozuota granuliozinis nekrozinis aortitas.

**Raktažodžiai:** pirminė aortoduodenalinė fistulė, kraujavimas į virškinamąjį traktą