

Surgical Treatment of Malignant Pheochromocytomas in Spine

Shu-Zhong Liu¹, Xi Zhou¹, An Song², Zhen Huo³, Yi-Peng Wang¹, Yong Liu¹

¹Department of Orthopaedic Surgery, Peking Union Medical College Hospital, Chinese Academy of Medical Science and Peking Union Medical College, Beijing 100730, China

²Department of Endocrinology, Key Laboratory of Endocrinology, National Health and Family Planning Commission, Peking Union Medical College Hospital, Chinese Academy of Medical Science and Peking Union Medical College, Beijing 100730, China

³Department of Pathology, Peking Union Medical College Hospital, Chinese Academy of Medical Science and Peking Union Medical College, Beijing 100730, China

To the Editor: Pheochromocytomas are rare neuroendocrine tumors that originate from the chromaffin cells in the adrenal glands or associated sympathetic ganglia.^[1] To the best of our knowledge, malignant pheochromocytoma is extraordinarily rare, with a frequency of 0.2–0.9 case per 1,000,000 individuals per year, and there is obvious shortage of clinical reports on metastatic pheochromocytoma to the spine. Thus, it can be difficult to diagnose and may result in devastating consequences upon mismanagement.^[2]

In February of 2018, a 63-year-old male patient presented to our hospital with progressive back pain and decreased muscle strength of his bilateral lower limbs. The pain in his back was evaluated as up to 4–6 points by visual analog scale (VAS) and could hardly be alleviated through rest and hot compresses. Physical examination showed that the patient had suffered from pressure pain and percussion pain in the spinal region, especially in thoracic and sacral spine, but with normal sensation to pinprick and fine touch on bilateral lower extremities though exhibiting a 5–/5 strength in the lower extremities. Routine laboratory tests were conducted including electrolytes, liver and kidney function tests, complete blood count, and tumor markers. Genetic evaluations and 24-h urine fractionated catecholamines were also delivered. Results of all studies were almost within normal range. Nevertheless, magnetic resonance imaging (MRI) of the spine revealed a widespread abnormal signal of multiple vertebrae including T2, T4, T7, L1, L3, and sacrum in keeping with diffused metastatic infiltration [Figure 1a and 1b]. A fluorodeoxyglucose-positron emission tomography/computed tomography (FDG-PET/CT) scan revealed multiple osteolytic lesions of the spine especially prominent in T2, T4, T7, L1, L3, and sacrum [Figure 1c]. FDG-PET/CT also demonstrated multiple suspicious metastases to liver, lung, ribs, pelvis, and retroperitoneal lymph nodes [Figure 1d]. Through further communication, the patient stated that he had previously undergone a resection of right adrenal pheochromocytoma in another hospital in 2009, an exploratory surgery and right posterior lobectomy of the liver in 2012, as well as a branch embolization of hepatic artery in 2016. Besides, he recalled a history of paroxysmal hypertension above

180/110 mmHg during the past nine years. Postadmission, we consulted the department of endocrinology who suggested that phenoxybenzamine should be taken before the operation. We, therefore, performed a percutaneous vertebroplasty procedure to the spinal metastases 4 weeks later in order to alleviate the symptoms caused by the spinal cord compression. This has subsequently stabilized the vertebral spine to prevent multiple vertebral bodies from collapsing. The biopsy specimens appeared to be fish like. The operation was a success, with the intraoperative bleeding being about 50 ml. It was also recorded that blood pressure fluctuated in the operation with 277/101 mmHg as the highest point when bone cement was injected into the vertebral bodies. The X-ray taken after the surgery confirmed that the cement was positioned with satisfactory without any signs of displacement [Figure 1e and 1f]. The postoperative pathology report later confirmed the diagnosis of malignant pheochromocytomas to the spine [Figure 1g]. One week after the operation, the VAS score of his back pain has improved down to 0–1 points compared with the preoperative status of 4–6 points. The patient was unwilling to undergo any further postoperative adjuvant treatment including radiation therapy, chemotherapy, or metaiodobenzylguanidine therapy. The postoperative 3-month follow-up visit to the patient showed that there is no tumor progression or any new symptoms.

The location of the spinal lesion determines the neurological deficits, and there is a great deal of variability. Pheochromocytoma may become malignant through their metastatic tendency, and the metastases can help us diagnose a malignant pheochromocytoma. The “gold standard” diagnosis of pheochromocytoma relies on pathological findings.^[2,3]

Address for correspondence: Dr. Yong Liu,

Department of Orthopaedic Surgery, Peking Union Medical College Hospital, Chinese Academy of Medical Science and Peking Union Medical College, Beijing 100730, China
E-Mail: liuyong_pumch@163.com

Access this article online

Quick Response Code:



Website:
www.cmj.org

DOI:
10.4103/0366-6999.244126

This is an open access journal, and articles are distributed under the terms of the Creative Commons Attribution-NonCommercial-ShareAlike 4.0 License, which allows others to remix, tweak, and build upon the work non-commercially, as long as appropriate credit is given and the new creations are licensed under the identical terms.

© 2018 Chinese Medical Journal | Produced by Wolters Kluwer - Medknow

Received: 05-06-2018 **Edited by:** Yuan-Yuan Ji

How to cite this article: Liu SZ, Zhou X, Song A, Huo Z, Wang YP, Liu Y. Surgical Treatment of Malignant Pheochromocytomas in Spine. Chin Med J 2018;131:2614-5.

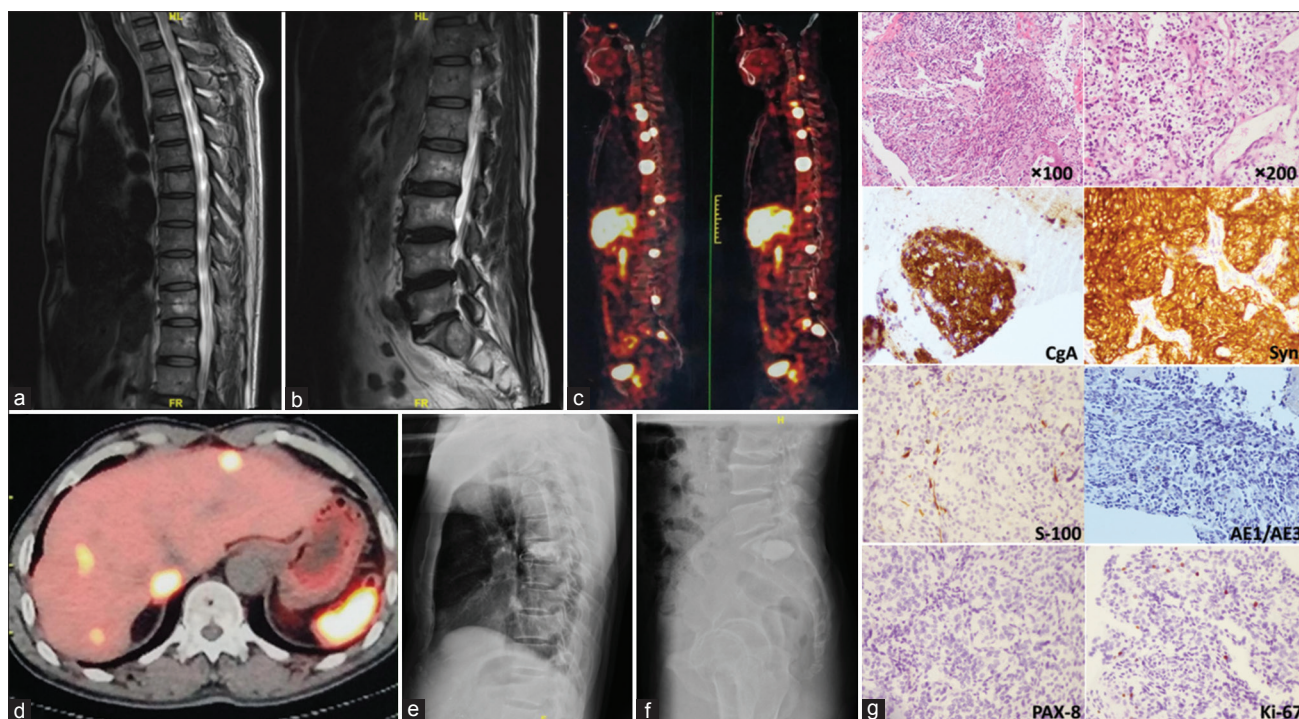


Figure 1: Spinal metastases of pheochromocytoma treated with percutaneous vertebroplasty in a 63-year-old male. (a and b) Preoperative sagittal T2-weighted MRI scan revealed widespread abnormal signal of multiple vertebrae including T2, T4, T7, L1, L3, and sacrum in keeping with diffuse metastatic infiltration. (c) FDG-PET/CT revealed multiple osteolytic lesions of the spine, especially prominent in T2, T4, T7, L1, L3, and sacrum with high suspicion of metastasis. (d) FDG-PET/CT revealed multiple suspicious metastases of liver. (e and f) Posteroanterior and lateral X-ray films of the spine showed cement augmentation was satisfactory. (g) Histopathology confirmed metastatic pheochromocytomas of spine (H and E, $\times 100$ and $\times 200$). Immunohistochemistry revealed neoplastic cells being chromogranin A, synaptophysin, and S-100 positive, AE1/AE3 and PAX-8 negative with 6% Ki-67 positive nuclei ($\times 200$). MRI: Magnetic resonance imaging; FDG-PET/CT: Fluorodeoxyglucose-positron emission tomography/computed tomography.

It is believed that the surgery is the best treatment for metastatic spinal pheochromocytomas causing back pain or paralysis. This protocol enables the accomplishment of two objectives: it alleviates the neurological deficits by decompressing the stenosis while provides histopathological specimens for diagnosis at the same time. Nevertheless, there are several considerations to be kept in mind when deliberating on surgical intervention to malignant pheochromocytoma with spinal metastasis including preoperative hemodynamic instability and cardiac arrhythmia control, possible incomplete tumor resection, intraoperative blood loss and hemodynamic instability, as well as postoperative adjuvant therapy. Percutaneous vertebroplasty by cement augmentation may be an alternative treatment for patients with metastatic pheochromocytoma in the spine who cannot undergo appropriate surgery or decline open surgery.^[3,4] There is yet a consensus on the combined treatment for metastatic pheochromocytomas in the spine due to insufficient amount of case studies.^[5] In spite of the low occurrence rate, it is still highly recommended that metastatic pheochromocytoma of the spine should be carefully differentiated when patients present with back pain or paralysis with labile blood pressure. With a multidisciplinary team approach, proper planning, and adequate perioperative medical management, metastatic pheochromocytoma in the spine could be managed much more effectively.

Declaration of patient consent

The authors certify that they have obtained all appropriate patient consent forms. In the form, the patient has given his consent for

his images and other clinical information to be reported in the journal. The patient understands that his name and initial will not be published and due efforts will be made to conceal his identity, but anonymity cannot be guaranteed.

Financial support and sponsorship

Nil.

Conflicts of interest

There are no conflicts of interest.

REFERENCES

- Jin YS, Fan MX. Pheochromocytoma characterizing both fever and acute renal failure. *Chin Med J* 2017;130:617-8. doi: 10.4103/0366-6999.200543.
- Liu S, Song A, Zhou X, Kong X, Li WA, Wang Y, *et al.* Malignant pheochromocytoma with multiple vertebral metastases causing acute incomplete paralysis during pregnancy: Literature review with one case report. *Medicine (Baltimore)* 2017;96:e8535. doi: 10.1097/MD.0000000000008535.
- Cai S, Kong X, Yan C, Liu Y, Zhou X, Qiu G, *et al.* Successful treatment of metastatic pheochromocytoma in the spine with cement augmentation. *Medicine (Baltimore)* 2017;96:e5892. doi: 10.1097/MD.0000000000005892.
- Kaloostian PE, Zadnik PL, Kim JE, Groves ML, Wolinsky JP, Gokaslan ZL, *et al.* High incidence of morbidity following resection of metastatic pheochromocytoma in the spine. *J Neurosurg Spine* 2014;20:726-33. doi: 10.3171/2014.3.SPINE13535.
- Jimenez P, Tatsui C, Jessop A, Thosani S, Jimenez C. Treatment for malignant pheochromocytomas and paragangliomas: 5 years of progress. *Curr Oncol Rep* 2017;19:83. doi: 10.1007/s11912-017-0643-0.