

Childhood focal compressive mononeuropathies during the COVID-19 pandemic in Buenos Aires, Argentina

Patricio Brand MD¹  | Claudia P. Cejas MD² | Alberto D. Rivero MD¹

¹Neurology Department, FLENI, Buenos Aires, Argentina

²Radiology Department, FLENI, Buenos Aires, Argentina

Correspondence

Patricio Brand, Neurology Department, FLENI Institute, Montaneses 2325, Buenos Aires 1425, Argentina.
Email: pbrand@fleni.org.ar

Abstract

Introduction/Aims: Focal peripheral neuropathies are infrequently seen in pediatric patients. The COVID-19 pandemic has disrupted normal life for many people, including complete lockdowns and school closing for long periods of time in many countries, which prompted children to stay at home. Our aim is to assess whether there has been an increased incidence of focal compressive peripheral neuropathies in the pediatric population during COVID-19-associated lockdown.

Methods: Clinical, electrophysiological, and imaging characteristics were reviewed for patients referred to the electrodiagnostic (EDx) laboratory with suspicion of a focal neuropathy. The incidence of focal compressive peripheral neuropathies seen during the period of March to September 2020 was compared with the same time period in 2019.

Results: An increased incidence of focal neuropathies was seen in 2020 (31%) compared with 2019 (6.8%). During 2020, 7 fibular (peroneal) mononeuropathies and 2 ulnar neuropathies were diagnosed. Most patients with focal neuropathies were underweight and acknowledged prolonged screen time periods. Electrophysiological findings consisted of mostly demyelinating lesions with an overall good clinical outcome.

Discussion: In this study we raise awareness about a possible increased incidence of focal compressive peripheral neuropathies in children during COVID-19-associated lockdown, which may be prevented with changing positions during sedentary activities.

KEYWORDS

electromyogram, entrapment neuropathy, fibular nerve, nerve compression, pediatric

1 | INTRODUCTION

Focal peripheral neuropathies and compressive neuropathies are rare in the pediatric electrodiagnostic (EDx) laboratory, with a reported frequency of 6%.¹

In Argentina, a national lockdown was ordered by the government on March 20, 2020 due to the COVID-19 pandemic, and has lasted for most of the academic year. The lockdown was lifted for the city of Buenos Aires on November 7, 2020, although open-air social gatherings and recreational activities for children in parks were gradually allowed over the previous 2 months.

Schools closed and children had online lessons during this time, requiring extended periods sitting in front of a computer. Moreover, the lack of physical activity and outdoor leisure activities have prompted children to spend significant time playing video games for socialization.

These long periods spent in front of screens, together with the lack of appropriate space and furniture designed for such activity, may have led to prolonged potentially harmful postures which may have increased the likelihood of developing focal compressive neuropathies.

The aim of this study is to evaluate whether there has been an increased incidence of focal compressive peripheral neuropathies in children during the COVID-19 pandemic-associated lockdown.

2 | METHODS

We searched the database of EDx studies performed at our tertiary neurological referral center in Buenos Aires, Argentina, and retrieved all pediatric EDx studies (ages 0-18 years) done from March to September 2020 and during the same time period in 2018 and 2019.

We compared the total number of EDx studies performed during 2019 and 2020, as only 6 studies were performed in 2018. Focal peripheral neuropathies and compressive neuropathies were then identified within those studies.

Clinical records, neurophysiological data, and imaging studies from patients with focal compressive mononeuropathies during the pandemic period were reviewed. Patients or their parents were contacted by telephone if follow-up data were unavailable during October and November 2020 and questioned on their self-assessed average daily screen time (time spent in front of a computer, cellular phone, tablet, or television).

EDx studies were classified as axonal if compound muscle action potential (CMAP) amplitude was decreased or denervation was present on needle electromyography, and/or demyelinating if conduction velocities were segmentally decreased by more than 10 m/s compared with the unaffected segment in the same nerve and/or there was evidence of definite conduction block defined by a reduction in CMAP amplitude of more than 50% with proximal stimulation compared with distal stimulation of a short nerve segment.²

Frequencies in each study group were compared using the Fisher exact test, with $P < .05$ the cutoff point for statistical significance. R statistical software (R Foundation for Statistical Computing, Vienna, Austria) was used.

This study was approved by our hospital's institutional ethics committee. Informed consent was not required.

3 | RESULTS

A total of 44 pediatric EDx studies were performed between March and September 2019 (control group), compared with 29 in the same time frame during 2020 ("lockdown" group). Studies were normal in 27 patients in 2019 (61%) and 14 patients in 2020 (48%). Table 1 shows a breakdown of all diagnoses.

Among the studies done in 2019, three (6.8%) compressive focal neuropathies were found, compared with nine (31%) in 2020 ($P < .01$). One case of focal neuropathy in 2019 was excluded due to the final diagnosis of a perineurioma in the proximal median nerve.

In 2019, one fibular (peroneal) neuropathy, one sciatic neuropathy, and one femoral cutaneous neuropathy were found, whereas, in 2020, the findings consisted of seven fibular neuropathies and two ulnar neuropathies.

The lockdown group had a mean age of 15.2 ± 1.9 (range, 13-18) years, compared with 11 ± 4.4 (range, 9-16) years in the control group. None of the patients in the "lockdown" group had diabetes. Mean body mass index (BMI) was 18.76 ± 1.52 (range, 17.1-22.0) kg/m^2 , with eight of nine (88.9%) having a BMI under 20. Three of nine patients

TABLE 1 Electrodiagnostic study results (n)

Diagnosis year	2019	2020
Normal	27	14
Focal mononeuropathy	4	9
Polyneuropathy	5	3
Motor neuropathy	1	0
Plexopathy	2	1
Radiculopathy	3	0
Myopathy	2	0
Myasthenia gravis	0	2
Total	44	29

acknowledged weight loss during lockdown and four noted a rapid growth spurt during the months preceding the onset of focal deficit.

Clinical characteristics of patients with focal compressive neuropathies in 2020 are summarized in Table 2.

During the lockdown period, all patients with fibular neuropathies presented with a foot drop and those with ulnar neuropathies had only sensory symptoms. All patients had unilateral involvement.

All patients in 2020 acknowledged an increase in screen time. Mean self-assessed daily screen time was 8.4 ± 2.8 (range, 5-14) hours. All patients with fibular neuropathy acknowledged crossing their legs while on the computer.

Electrophysiological assessment revealed demyelinating involvement of all affected nerves, with associated axonal damage in five. Conduction blocks were present in six of seven patients with fibular mononeuropathies and no patients with ulnar neuropathies. The superficial fibular nerve was spared in six of seven patients with fibular neuropathies. Mean time from symptom onset to EDx study was 40 (range, 7-150) days. Key nerve conduction study and EMG data are presented in the Table S1.

Magnetic resonance (MR) neurography was performed in four of seven patients with fibular neuropathy, revealing increased signal intensity on T2-weighted images (W-I) and thickening of the common fibular nerve near the fibular head in all (Figure 1).

Four patients underwent physical therapy, one required surgical decompression of the fibular nerve at the fibular head and the rest did not require any treatment.

The outcome was favorable in all patients with complete or near-complete recovery in eight patients and partial recovery in one.

4 | DISCUSSION

We found that the percentage of focal neuropathies at our center in the pre-pandemic setting was similar to what had been previously reported,¹ but increased significantly during the COVID-19 pandemic and its associated lockdown period.

Compressive lesions are the second most common cause of acute focal mononeuropathies in children after trauma, but etiologies vary.¹ Focal mononeuropathies in children have been reported in the median, radial, ulnar, fibular, and sciatic nerves associated with metabolic or

TABLE 2 Demographic and clinical characteristics of patients with focal neuropathies in 2020

Patient	Gender	Age (years)	Weight (kg)	BMI (kg/m ²)	Screen time (h/day)	Affected nerve	Lesion type
1	M	15	65	18.9	7	Fibular	Demyelinating
2	M	16	53	17.1	8	Fibular	Mixed
3	M	14	51	19.2	8	Fibular	Demyelinating
4	F	13	47	18.6	7	Fibular	Demyelinating
5	M	18	66	19.7	6	Ulnar	Mixed
6	M	14	56	18.3	11	Fibular	Mixed
7	M	13	51	17.9	5	Fibular	Mixed
8	M	17	73	22.0	10	Fibular	Mixed
9	M	17	50	17.1	14	Ulnar	Demyelinating

Abbreviations: BMI, body mass index; F, female; M, male.

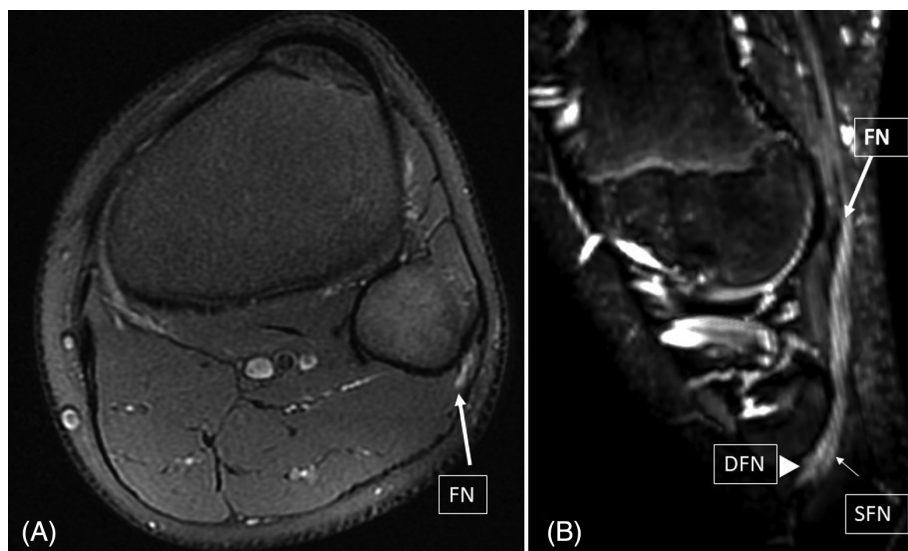


FIGURE 1 MR neurography. Axial DP FS T2 W-I (A) and sagittal MPR reconstruction WATER IDEAL T2 W-I (B) sequences showing increased signal and thickening of the left common fibular nerve (thick arrow) and its branches, deep (arrowhead) and superficial (thin arrow) fibular nerves, around the fibular neck. Abbreviations: DFN, deep fibular nerve; DP FS, density protonic fat saturation; FN, fibular nerve; MPR, maximum projection reconstruction; SFN, superficial fibular nerve

genetic disorders, bone abnormalities, tumors, vascular malformations, trauma, entrapment, and compression, or rarely idiopathic.³⁻¹⁷

Leg crossing has been shown to be a predisposing factor for developing compressive fibular mononeuropathies.^{1,14,18,19} Prolonged pressure on the elbow may also lead to compressive ulnar neuropathy at the site.²⁰

The fibular nerve lies superficially while traveling around the fibular head. It has been shown that weight loss is another predisposing factor for developing compression at the site, perhaps due to the loss of the protective layer of fat around the nerve,^{15,16,19} or to metabolic and endocrine disturbances, especially in anorexic patients.¹⁵ There have been reports of bilateral fibular neuropathies in adolescents due to prolonged leg crossing in front of a computer,¹⁴ but our patients all had unilateral fibular neuropathies.

We hypothesize that, in our patients, leg crossing with long periods of screen time together with a high proportion of underweight patients may have contributed to developing fibular neuropathies. The addition of a rapid growth spurt may have also played a role.

Prognosis overall was good. Consistent with what was previously reported,¹³ most of our patients with fibular neuropathy had sparing of the superficial fibular nerve.

Our study has several limitations. First, it was retrospective, so recall bias regarding leg-crossing and screen time may have been

overestimated. Moreover, time spent on other sedentary activities (eg, reading) that may have been associated with prolonged periods in uncomfortable postures was not assessed. Second, patients from only one neurological center were included. As many other EDx laboratories were not operating at full capacity during the pandemic, a referral bias to our center may have increased the number of focal neuropathies. If that were true, however, an increase in the total number of studies performed or an increase of focal neuropathies in the same proportion would have been expected, and neither was the case for our series. However, it is possible that, in the pandemic setting, studies in children with generalized weakness or nonspecific symptoms were deferred due to concerns of contracting COVID, whereas more urgent or worrisome symptoms, such as an acute focal deficit, warranted EDx appointments. In that regard, we found a slightly higher proportion of normal studies overall in 2019 than in 2020 (61% vs 48%). Finally, this is not a population-based study.

In conclusion, although social distancing and stay-at-home orders were necessary public health measures, our study raises awareness about possible preventable adverse outcomes of isolation in children and adolescents, which are preventable with habit modifications and education. Further population-based studies are warranted.

CONFLICT OF INTEREST

None of the authors has any conflict of interest to disclose.

ETHICAL PUBLICATION STATEMENT

We confirm that we have read the Journal's position on issues involved in ethical publication and affirm that this report is consistent with those guidelines.

DATA AVAILABILITY STATEMENT

The data that support the findings of this study are available on request from the corresponding author. The data are not publicly available due to privacy or ethical restrictions.

ORCID

Patricio Brand  <https://orcid.org/0000-0001-5117-245X>

REFERENCES

- Jones H. Mononeuropathies of infancy and childhood. *Clin Neurophysiol*. 2000;53(Suppl):396-408.
- American Association of Electrodiagnostic Medicine. Guidelines in electrodiagnostic medicine. Consensus criteria for the diagnosis of partial conduction block. *Muscle Nerve*. 1999;8(Suppl):S225-S229.
- Kang PB, McMillan HJ, Kuntz NL, et al. Utility and practice of electrodiagnostic testing in the pediatric population: an AANEM consensus statement. *Muscle Nerve*. 2020;61:143-155.
- Illeez OG, Ozkan FU, Ozkaya O. Bilateral idiopathic carpal tunnel syndrome in a 4-year-old girl. *J Trop Pediatr*. 2017;63:78-81.
- Batdorf NJ, Cantwell SR, Moran SL. Idiopathic carpal tunnel syndrome in children and adolescents. *Surg Am*. 2015;40:773-777.
- Rüsch CT, Knirsch U, Weber DM, et al. Etiology of carpal tunnel syndrome in a large cohort of children. *Children (Basel)*. 2021;8:624.
- Acciario AL, Pilla F, Faldini C, Adani R. The carpal tunnel syndrome in children. *Musculoskelet Surg*. 2018;102:261-265.
- Potulska-Chromik A, Lipowska M, Gaweł M, Ryniewicz B, Maj E, Kostera-Pruszczyk A. Carpal tunnel syndrome in children. *J Child Neurol*. 2014;29:227-231.
- Karakis J, Georgiou S, Jones R, Darras BT, Kang PB. Electrophysiologic features of radial neuropathy in childhood and adolescence. *Pediatr Neurol*. 2018;81:14-18.
- Mohan K, Ellanti P, Hadidi O, Bossut C. Tardy ulnar nerve palsy following a neglected childhood lateral epicondyle fracture non-union and resultant cubitus valgus deformity. *BMJ Case Rep*. 2018;11:e227918.
- Rubin G, Orbach H, Bor N, Rozen N. Tardy ulnar nerve palsy. *J Am Acad Orthop Surg*. 2019;27:717-725.
- Karakis J, Liew W, Szlag Fournier H, Jones HR Jr, Darras BT, Kang PB. Electrophysiologic features of ulnar neuropathy in childhood and adolescence. *Clin Neurophysiol*. 2017;128:751-755.
- Karakis J, Khoshnoodi M, Liew W, et al. Electrophysiologic features of fibular neuropathy in childhood and adolescence. *Muscle Nerve*. 2017;55:693-697.
- Guzel S, Ozen S, Cosar S. Bilateral peroneal nerve palsy secondary to prolonged sitting in an adolescent patient. *Int J Neurosci*. 2020;17:1-3.
- Shahar E, Landau E, Genizi J. Adolescence peroneal neuropathy associated with rapid marked weight reduction: case report and literature review. *Eur J Paediatr Neurol*. 2007;11:50-54.
- Cruz-Martinez A, Arpa J, Palau F. Peroneal neuropathy after weight loss. *J Peripher Nerv Syst*. 2000;5:101-105.
- Srinivasan J, Ryan MM, Escolar DM. Pediatric sciatic neuropathies. A 30-year prospective study. *Neurology*. 2011;76:976-980.
- Craig A. Entrapment neuropathies of the lower extremity. *PM R*. 2013;5(Suppl):S31-S40.
- Marciniak C. Fibular (peroneal) neuropathy: electrodiagnostic features and clinical correlates. *Phys Med Rehabil Clin N Am*. 2013;24:121-137.
- Campbell W. Diagnosis and management of compression entrapment neuropathies. *Neurol Clin*. 1997;15:549-567.

SUPPORTING INFORMATION

Additional supporting information may be found in the online version of the article at the publisher's website.

How to cite this article: Brand P, Cejas CP, Rivero AD. Childhood focal compressive mononeuropathies during the COVID-19 pandemic in Buenos Aires, Argentina. *Muscle & Nerve*. 2022;65(5):590-593. doi:10.1002/mus.27507

Risk factors for lumbosacral radiculoplexus neuropathy

Marcus V. Pinto MD, MS¹  | Peng-Soon Ng MBBS² | Ruple S. Laughlin MD¹ | Prabin Thapa MS³ | Catarina Aragon Pinto MD¹ | Shahar Shelly MD¹  | Kamal Shouman MD¹  | Peter J. Dyck MD¹ | P. James B. Dyck MD¹ 

¹Department of Neurology, Mayo Clinic, Rochester, Minnesota, USA

²Department of Neurology, National Neuroscience Institute, Singapore

Abstract

Introduction/Aims: Recently, our group found an association between diabetes mellitus (DM) and lumbosacral radiculoplexus neuropathy (LRPN) in Olmsted County,