

## Case Report

# Middle Cerebral Artery Aneurysm in a Premature Neonate

Chan-Young Choi, M.D., Chae-Heuck Lee, M.D.

Department of Neurosurgery, Ilsan Paik Hospital, College of Medicine, Inje University, Goyang, Korea

Intracranial aneurysms in the neonate are very rare and their clinicopathological findings remain unclear. We report a 26-day-old premature neonate who underwent microsurgical clipping on the ruptured middle cerebral artery bifurcation aneurysm successfully with a review of relevant literature.

**Key Words :** Cerebral aneurysm · Neonate · Clipping.

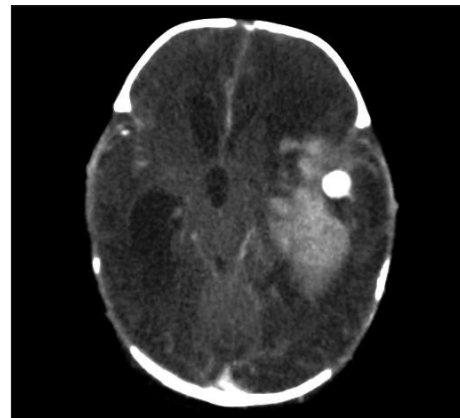
## INTRODUCTION

Cerebral aneurysms occurring in the pediatric age has been reported to be 0.5-4.6% of all cerebral aneurysms. Those in the neonate are even rarer and account for less than 30 cases<sup>1,10)</sup>. The recent studies for aneurysmal subarachnoid hemorrhages occurred in the pediatric age have mentioned several, different, clinical features as compared to those in adults. However, the pathophysiological mechanism for aneurysm formation in the pediatric age remains unclear. We report a 26-day-old premature neonate with a ruptured aneurysm on the middle cerebral artery bifurcation who underwent aneurysmal neck clipping with craniotomy successfully and review the relevant literatures.

## CASE REPORT

A 26-day-old female patient had normal delivery in prematurity at the gestation of 34th week. During delivery, any medical assistances were not required and the patient was normal on the physical examinations. Routine sonography of the brain did not show any significant findings. And then, the patient has been treated with antibiotics under the impression of sepsis for approximately 2 weeks. On the 26th day after birth, reduced spontaneous activity, bulging of the anterior fontanel and right hemiparesis were observed. Computed tomography (CT) showed a large subcortical hemorrhage with intraventricular hemorrhage

and subarachnoid hemorrhage in the left cerebral hemisphere. A 1 cm sized, round enhancing lesion suspected of the cerebral aneurysm was found together (Fig. 1). Light reflex of both pupils was prompt with no dilatations. It was thought that subarachnoid hemorrhage of Hunt-Hess grade IV was caused by rupture of infectious aneurysm. At first, frameless stereotactic aspiration of the intracerebral hematoma and extraventricular drainage were performed. Gram stain and culture for cerebro-



**Fig. 1.** Enhanced computed tomography shows large subcortical hemorrhage and 1 cm sized, round enhancing lesion suspected of the cerebral aneurysm in the left cerebral hemisphere. Ventricular enlargement, midline shift due to mass effects and separation of suture lines are accompanied.

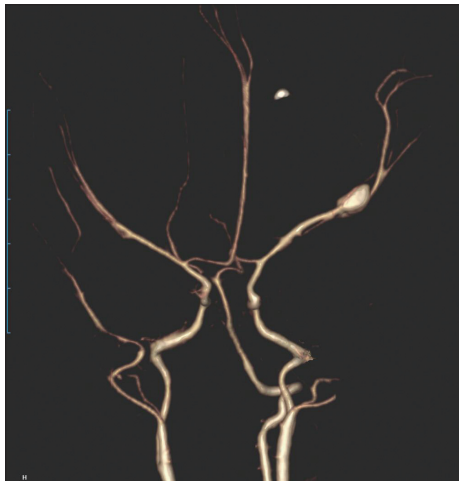
• Received : February 7, 2013 • Revised : April 21, 2013 • Accepted : June 19, 2013

• Address for reprints : Chan-Young Choi, M.D.

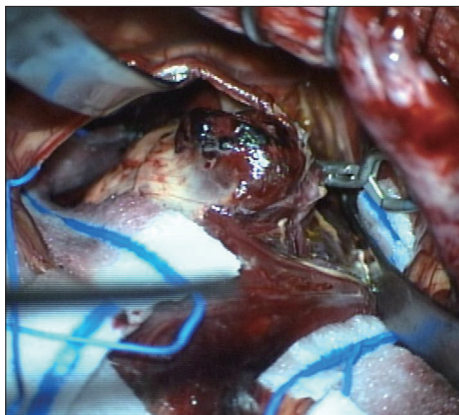
Department of Neurosurgery, Ilsan Paik Hospital, College of Medicine, Inje University, 170 Juhwa-ro, Ilsanseo-gu, Goyang 411-706, Korea  
Tel : +82-31-910-7730, Fax : +82-31-915-0885, E-mail : cychoi@paik.ac.kr

• This is an Open Access article distributed under the terms of the Creative Commons Attribution Non-Commercial License (<http://creativecommons.org/licenses/by-nc/3.0>) which permits unrestricted non-commercial use, distribution, and reproduction in any medium, provided the original work is properly cited.

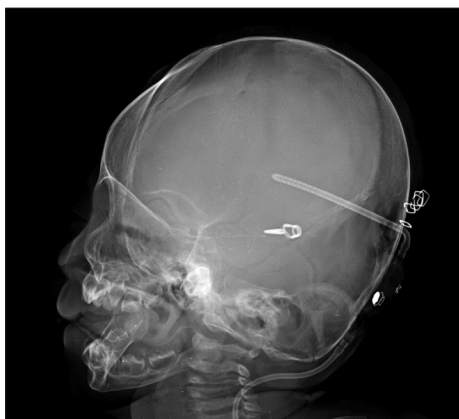
spinal fluid and hematoma were done together. After that, the patient kept stable without further neurological deteriorations. The follow-up CT angiograms showed a large intracerebral hemorrhage due to rebleeding and a 3×7 mm sized saccular an-



**Fig. 2.** CT angiograms reveal a large saccular aneurysm with 3×7 mm size on the middle cerebral artery bifurcation.



**Fig. 3.** Intraoperative photograph shows that aneurysmal neck clipping with hematoma evacuation are performed. There are no findings suggested of the infectious origin.



**Fig. 4.** The lateral skull X-ray shows ventriculoperitoneal shunt device and clip for aneurysm.

eurysm on the middle cerebral artery bifurcation (Fig. 2). Analysis of cerebrospinal fluid and echocardiogram showed no significant results. The patient underwent hematoma evacuation and aneurysmal neck clipping with craniotomy. Any findings suggested of the infectious origin were not found intraoperatively although resection of aneurysm sac could not be accomplished due to adherent perforators (Fig. 3). The neurological deficits have been improved gradually during follow-up period. 3 months after craniotomy, ventriculoperitoneal shunt was performed for hydrocephalus (Fig. 4).

## DISCUSSION

The pediatric cerebral aneurysms account for 0.5-4.6% of all cerebral aneurysms. They appear to have several epidemiological features as compared to those in adults, such as male predominance, preferential location of internal carotid artery bifurcation, and association with other congenital diseases<sup>(4)</sup>. Association with congenital diseases in the pediatric cerebral aneurysms and reverse sexual predominance in the adults ones may suggest that aneurysm formation is influenced by the biological factors or genetic expressions. In the pediatric cerebral aneurysms, the possibility to present with subarachnoid hemorrhage and to be in good grade clinically are higher than not<sup>(4)</sup>. In the present case, the patient tolerated very well clinically although a large intracerebral hemorrhage with severe mass effects seemed to be catastrophic. It is thought that separation of suture lines of this age may help the patient to tolerate increased intracranial pressure. Conventional angiogram has been a gold standard to diagnose the cerebral aneurysms. However, CT angiograms could show the serial information of intracerebral hematoma, ventricle size, and angiographic vasospasm as well as the morphology of aneurysm in this present case. With respect to rapidity and invasiveness, it is thought that CT angiograms may be very useful for diagnosis and treatment in this age. The posterior circulation aneurysm and giant aneurysm account for 17% and 20% of all pediatric cerebral aneurysms respectively. These rates are significantly greater than those in the adults and similar to those in the neonates. Mycotic aneurysms in the pediatric age appear to have higher prevalence than those in the adults and it is unclear in the neonates<sup>(4,10)</sup>. However, there are some controversies with respect to epidemiology of aneurysm size, location, and etiology<sup>(4,5,7-9)</sup>. Our case showed a large sized aneurysm occurred in the anterior circulation and definite evidence of infectious origin was not found. Angiographic vasospasm which can cause delayed neurological deficits has been often reported in the pediatric subarachnoid hemorrhages, but the clinical tolerance appears to be greater than the adults<sup>(4)</sup>. In our case, diffuse narrowing of the ipsilateral middle cerebral artery was seen on follow-up CT angiograms, but further neurological deteriorations were not found. It has been reported that the infantile cerebral aneurysms have several distinct characteristics as follows : male predominance, higher incidence of symp-

omatic onset in early infancy, preferential location of middle cerebral artery and posterior circulations, lower incidence of multiple aneurysms and tendency to be giant<sup>1,2</sup>. These clinical features of the infantile cerebral aneurysms seem to be more similar to those of the neonate ones than the pediatric ones<sup>10</sup>. The etiology of cerebral aneurysms remains controversial. Multiple intrinsic and environmental factors, such as congenital, degenerative, infectious, traumatic origins which may affect structural changes of cerebral vessels and hemodynamic stress are related with aneurysm formation. Atherosclerosis, hypertensive degeneration, abrupt termination of the internal elastic lamina and muscularis media at the entrance to the aneurysm sac have been considered as pathological characteristics in the adults cerebral aneurysm<sup>3,6</sup>. However, these clinicopathological findings are not consistent with the pediatric or neonate cerebral aneurysm. Therefore, aneurysm formation in this age may be more related with congenital or intrinsic factors than environmental factors because risk factors such as cigarette smoking, hypertension, and atherosclerosis can be excluded. Middle cerebral artery is preferential location of the neonate, infantile, and infectious cerebral aneurysms, although the largest part of pediatric middle cerebral artery aneurysms were not infectious<sup>2,4,10</sup>. Embryologically early appearance and hemodynamically large blood flow resulting in a longer period of stress, and phylogenetically new blood vessel of the middle cerebral artery may be the reasons to be prone to the aneurysm formation<sup>1</sup>. In our case, there were no obvious evidence of infection, birth trauma and associated congenital anomalies. And there was little exposure to environmental factors which may cause degeneration of the cerebral vessels. Therefore, it is thought that only intrinsic factors such as genetic or developmental components seem to affect aneurysm formation of this present case. Although the neonatal cerebral aneurysm is thought to have greater clinical tolerance and better clinical outcomes than the adults ones, mortality are as high as 40% because of a delay of diagnosis and a high proportion of bleeding<sup>1,4,5,10</sup>. Therefore, early diagnosis and treatment are considered to avoid poor clinical outcomes in spite of good functional compensation of the brain in this age. Fortu-

nately, our present case showed clinical improvements without further neurological deteriorations. However, long-term evaluation for neuropsychological functions is required.

## CONCLUSION

The neonatal cerebral aneurysm is very rare and distinct from those of the adults. Satisfactory clinical outcome can be achieved with modern diagnostic tools and microsurgery.

## References

1. Buis DR, van Ouwkerk WJ, Takahata H, Vandertop WP : Intracranial aneurysms in children under 1 year of age : a systematic review of the literature. *Childs Nerv Syst* 22 : 1395-1409, 2006
2. Elgamel EA, Murshid WR, Abu-Rahma HM, Samir D : Aneurysmal subarachnoid hemorrhage in the first year of life : case report and review of the literature. *Childs Nerv Syst* 20 : 489-493, 2004
3. Herman JM, Rekatte HL, Spetzler RF : Pediatric intracranial aneurysms : simple and complex cases. *Pediatr Neurosurg* 17 : 66-72; discussion 73, 1991-1992
4. Huang J, McGirt MJ, Gailloud P, Tamargo RJ : Intracranial aneurysms in the pediatric population : case series and literature review. *Surg Neurol* 63 : 424-432; discussion 432-433, 2005
5. Koroknay-Pál P, Laakso A, Lehto H, Seppä K, Kivisaari R, Hernesniemi J, et al. : Long-term excess mortality in pediatric patients with cerebral aneurysms. *Stroke* 43 : 2091-2096, 2012
6. Meyer FB, Sundt TM Jr, Fode NC, Morgan MK, Forbes GS, Mellinger JF : Cerebral aneurysms in childhood and adolescence. *J Neurosurg* 70 : 420-425, 1989
7. Pasqualin A, Mazza C, Cavazzani P, Scienza R, DaPian R : Intracranial aneurysms and subarachnoid hemorrhage in children and adolescents. *Childs Nerv Syst* 2 : 185-190, 1986
8. Proust F, Toussaint P, Garniéri J, Hannequin D, Legars D, Houtteville JB, et al. : Pediatric cerebral aneurysms. *J Neurosurg* 94 : 733-739, 2001
9. Stiefel MF, Heuer GG, Basil AK, Weigele JB, Sutton LN, Hurst RW, et al. : Endovascular and surgical treatment of ruptured cerebral aneurysms in pediatric patients. *Neurosurgery* 63 : 859-865; discussion 865-866, 2008
10. Van Raay Y, Darteyre S, Di Rocco F, Goodden J, Papouin M, Brunelle F, et al. : Neonatal ruptured intracranial aneurysms : case report and literature review. *Childs Nerv Syst* 25 : 1025-1033, 2009