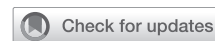

Combination High Flow Priapism With Low Flow Priapism: Case Report



Alejandro Carvajal, MD,¹ and Johana Andrea Benavides, MD¹

ABSTRACT

Introduction: Priapism is defined as a persistent penile erection lasting longer than 4 hours and unrelated to sexual activity. It is one of the most common emergencies treated by urologists. Advances in understanding the pathophysiology of various types of priapism have led to targeted management strategies according to type of priapism.

Aim: The aims of this article is report the case of a 24-year-old man who was presented in the emergency department with a combination of high flow priapism with low flow priapism.

Methods: This case report documents the case of a patient who presented in the emergency department with a high flow priapism that then became to a ischemic priapism.

Conclusion: Priapism is one of the most common emergencies treated by urologists. Advances in understanding the pathophysiology of various types of priapism have led to targeted management strategies as was shown in our case. **Carvajal A, Benavides JA. Combination High Flow Priapism With Low Flow Priapism: Case Report. Sex Med 2019;7:111–113.**

Copyright © 2018, The Authors. Published by Elsevier Inc. on behalf of the International Society for Sexual Medicine. This is an open access article under the CC BY-NC-ND license (<http://creativecommons.org/licenses/by-nc-nd/4.0/>).

Key Words: Priapism; High Flow; Low Flow Priapism

INTRODUCTION

Priapism is defined as a prolonged and persistent penile erection that is unrelated to sexual stimulation and lasts >4 hours.¹ The literature reports types including ischemic (low flow), non-ischemic (high flow), and stuttering (recurrent).² The overall incidence rate varies between .3 and 1.5 per 100,000 person-years.^{3,4} Ischemic priapism accounts for >95% of cases. The estimated incidence of high flow priapism is not well known because there are few case reports. Because the treatment and prognostic factors are different, it is important to make a differential diagnosis between the 2 types of priapism. In most patients, the symptoms orient the diagnosis. However, there are some reports of low flow priapism complications with high flow priapism in which the clinical type is mixed. In this article, we report a case of high flow priapism that that we believe became low flow priapism.

CASE REPORT

A 24-year-old man presented to the emergency department with a complete painless erection of 48 hours' duration. The erection started 2 hours after penile trauma in a motorcycle accident. He reported previous marijuana consumption. Upon physical examination, tumescence of penis was noted without pain or ecchymosis. High flow priapism was suspected based on medical history as well as physical examination.

Doppler ultrasonography and cavernous blood gas analysis were performed to confirm the diagnosis; however, Doppler ultrasonography reported no flow, and blood gas analysis showed acidotic, poorly oxygenated blood (pH 6.8, pCO₂ 81 mmHg, HCO₃ 14.4 mmol/L, pO₂ 6.4 mmHg, excess base −20.5 mmol/L), contributing to a diagnosis of ischemic priapism (Figure 1). A cavernous corpus aspiration was done first with no response, and a cavernosal-glandular shunt (Al-Ghorab procedure) was performed immediately. At corporeal incision, dark cavernosal blood was revealed. The patient was followed under observation with prophylactic antibiotics, but only partial improvement of the rigidity was obtained. During observation, a complete blood count was performed with no evidence of anemia.

3 days later, the only partial improvement of the painless priapism led to the suspicion of an arterial-lacunar fistula, for which a selective pudendal arteriography was performed (Figure 1A). On

Received August 28, 2018. Accepted October 4, 2018.

¹Department of Urology, CES University, Medellín, Colombia

Copyright © 2018, The Authors. Published by Elsevier Inc. on behalf of the International Society for Sexual Medicine. This is an open access article under the CC BY-NC-ND license (<http://creativecommons.org/licenses/by-nc-nd/4.0/>).

<https://doi.org/10.1016/j.esxm.2018.10.003>

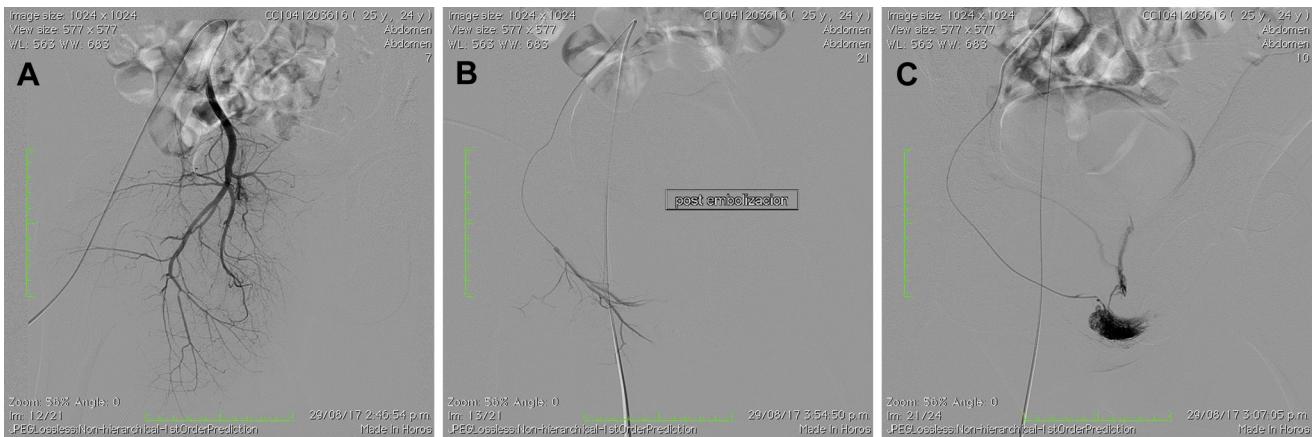


Figure 1. A, Selective arteriography of the pudenda. B, Bulbar fistula. C, After embolization.

confirming these suspicions, the fistula was recognized (Figure 1B). The right-side proximal bulbar artery was embolized with Gelfoam (Pfizer, New York, NY) (Figure 1C). The rigidity resolved, and patient was discharged on the sixth day.

At 3-month follow-up, the patient presented with severe erectile dysfunction and fibrotic corpus cavernosum.

DISCUSSION

High flow priapism is defined as a persistent erection caused by unregulated cavernous arterial inflow.⁵ Classically, erectile tissue shows a partial rigidity and the penis is not painful. Cavernosal aspiration reveals bright blood, and blood gases do not show hypoxia, hypercarbia, or acidosis. Etiology includes straddle injury, direct trauma to the penis or perineum, pelvic fractures, needle lacerations, or shunt procedures.⁶ Kuefer et al⁶ found that 70.5% of all reported patients suffered from a traumatic or iatrogenic laceration of a penile artery. 4.5% were caused by a malignant erosion of the penile vessels. 5.8% were described in patients with inherited diseases, and the etiology was not clear in 16.7%. The most common fistula location was cavernosal (72%).^{7,8} Color Doppler ultrasonography, the preferred diagnostic tool, has a sensitivity of nearly 100%.⁹ It helps to localize the arterio-lacunar fistula and make the differential diagnosis vs ischemic priapism.¹⁰

In contrast, ischemic priapism is like compartment syndrome in that there is no cavernous arterial inflow and progressive hypoxia and acidosis are present. It should be suspected with painful erections lasting >6 hours. A history of drug consumption is also a possibility. Treatment includes penile aspiration and injections of sympathomimetics. When these fail, surgery is indicated. The aim of surgical treatment is to provide a shunt between the corpus cavernosum and glans penis, corpus spongiosum, or a vein so that the obstructed veno-occlusive mechanism is bypassed and oxygenation of the smooth muscle is reestablished.

As was shown, the symptoms of our patient were misleading/confusing because they mimicked those of non-ischemic priapism. He had perineal trauma and presented with a painless erection. However, upon analysis, we diagnosed low flow priapism, which is why the arteriography was not done before cavernosal-glandular shunt.

In the literature, there are reports of cases of ischemic priapism changing to high flow priapism, but no known cases of non-ischemic priapism downgrading or transforming into ischemic priapism. The most frequent mechanism presented is secondary to a T-shunt procedure and needle trauma. Hoffman et al¹¹ reported a patient who underwent physiological transformation from a low flow state to ambiguous priapism. In our case report, we conclude that the patient presented with non-ischemic priapism that then transformed to ischemic priapism. He had 2 predisposing factors: mechanism of injury and prior drug consumption. What is shocking is that the patient never had pain, and the priapism resolved with fistula embolization. Only partial improvement was achieved after cavernospongiosum shunt.

CONCLUSION

Priapism is one of the most common emergencies treated by urologists. Advances in understanding the pathophysiology of various types of priapism have led to targeted management strategies, as was shown in this case.

Corresponding Author: Alejandro Carvajal, Universidad CES, Calle 10 A No. 22 – 04, Medellín, Colombia. Tel: 57 3014302122; Fax: 57 43260303; E-mail: ac@sexualidadyfertilidad.com

Conflict of interest: The authors report no conflicts of interest.

Funding: None.

STATEMENT OF AUTHORSHIP**Category 1****(a) Conception and Design**

Alejandro Carvajal

(b) Acquisition of Data

Johana Benavides

(c) Analysis and Interpretation of Data

Alejandro Carvajal; Johana Benavides

Category 2**(a) Drafting the Article**

Alejandro Carvajal; Johana Benavides

(b) Revising It for Intellectual Content

Alejandro Carvajal; Johana Benavides

Category 3**(a) Final Approval of the Completed Article**

Alejandro Carvajal

REFERENCES

1. Hudnall M, Reed-Maldonado AB, Lue TF. Advances in the understanding of priapism. *Transl Androl Urol* 2017;6:199-206.
2. Burnett AL. Pathophysiology of priapism: Dysregulatory erection physiology thesis. *J Urol* 2003;170:26-34.
3. Eland IA, van der Lei J, Stricker BH, Sturkenboom MJ. Incidence of priapism in the general population. *Urology* 2001;57:970-972.
4. Brock G, Breza J, Lue TF, Tanagho EA. High flow priapism: A spectrum of disease. *J Urol* 1993;150:968-971.
5. Moscovici J, Barret E, Galinier P, et al. Post-traumatic arterial priapism in the child: A study of four cases. *Eur J Pediatr Surg Off J Austrian Assoc Pediatr Surg Al Z Kinderchir* 2000;10:72-76.
6. Kuefer R, Bartsch G, Herkommer K, Krämer SC, Kleinschmidt K, Volkmer BG. Changing diagnostic and therapeutic concepts in high-flow priapism. *Int J Impot Res* 2005;17:109-113.
7. Qureshi JM, Wood H, Feldman M. High flow priapism on color Doppler ultrasound. *J Urol* 2013;189:2312-2313.
8. von Stempel C, Zacharakis E, Allen C, et al. Mean velocity and peak systolic velocity can help determine ischaemic and non-ischaemic priapism. *Clin Radiol* 2017;72:611; e9–e16.
9. Burnett AL, Sharlip ID. Standard operating procedures for priapism. *J Sex Med* 2013;10:180-194.
10. Burnett AL, Bivalacqua TJ. Priapism: New concepts in medical and surgical management. *Urol Clin North Am* 2011;38:185-194.
11. Hoffman S, Kaynan AM, Melman A. Priapism of ambiguous classification in a sickle cell patient. *Int J Impot Res* 2000;12:59-63.