

# Treatment and Outcome of Epileptogenic Temporal Cavernous Malformations

Yong-Zhi Shan, Xiao-Tong Fan, Liang Meng, Yang An, Jian-Kun Xu, Guo-Guang Zhao

Department of Neurosurgery, Xuanwu Hospital, Capital Medical University, Beijing 100053, China

## Abstract

**Background:** The aim of this study is to explore the treatment and outcome of epileptogenic temporal lobe cavernous malformations (CMs). **Methods:** We analyzed retrospectively the profiles of 52 patients diagnosed as temporal lobe CMs associated with epilepsy. Among the 52 cases, 11 underwent a direct resection of CM along with the adjacent zone of hemosiderin rim without electrocorticogram (ECoG) monitoring while the other 41 cases had operations under the guidance of ECoG. Forty-six patients were treated by lesionectomy + hemosiderin rim while the other six were treated by lesionectomy + hemosiderin rim along with extended epileptogenic zone resection. The locations of lesions, the duration of illness, the manifestation, the excision ranges and the outcomes of postoperative follow-up were analyzed, respectively.

**Results:** All of the 52 patients were treated by microsurgery. There was no neurological deficit through the long-term follow-up. Outcomes of seizure control are as follows: 42 patients (80.8%) belong to Engel Class I, 5 patients (9.6%) belong to Engel Class II, 3 patients (5.8%) belong to Engel Class III and 2 patients (3.8%) belong to Engel Class IV.

**Conclusion:** Patients with epilepsy caused by temporal CMs should be treated as early as possible. Resection of the lesion and the surrounding hemosiderin zone is necessary. Moreover, an extended excision of epileptogenic cortex or cerebral lobes is needed to achieve a better prognosis if the ECoG indicates the existence of an extra epileptic onset origin outside the lesion itself.

**Key words:** Cavernous Malformation; Electrocoorticogram; Epilepsy; Surgery; Temporal Lobe

## INTRODUCTION

With the development of modern neuroimaging, the detection rate of cavernous malformation (CM) has increased significantly. It was documented that the incidence normally ranged from 0.5% to 4%,<sup>[1]</sup> accounting for 8–15% of the total cerebrovascular diseases.<sup>[1,2]</sup> Approximately, 80% of the cerebral CMs are supratentorial. About 40–70% of such supratentorial lesions presented with seizures.<sup>[3,4]</sup> The hemosiderosis and gliosis in the adjacent brain tissues from the tiny hemorrhage of the lesions are considered the main reason of epilepsy.<sup>[5]</sup>

Around 10–20% of the cerebral CMs are located in the temporal lobes.<sup>[1]</sup> Previous studies have demonstrated that lesions in such an area might lead to a higher probability of epilepsy than in other areas.<sup>[3,6,7]</sup> We analyzed retrospectively the 52 cases of temporal CMs related to epilepsy. The patients underwent microneurosurgical treatment during the latest 5 years in our center.

## METHODS

### Patient population

Between January 2008 and December 2012, a total of 186 CM patients were included in this study population who underwent surgical treatment in our center, and the pathological examinations revealed CMs. Among these patients, 52 (28%) were with temporal CMs and the major concern included seizure attacks. There were 31 male and 21 female cases who aged from 8 to 52 years (mean 26.8 years). Among these patients, three types of epilepsy were defined: Drug-resistant epilepsy, epilepsy or single/sporadic seizures. Twenty-three had a history of <1 year and the other 29 suffered from more than 1 year although 19 of drug-resistant epilepsy received standard medical treatment before the operations. Generalized seizures occurred in 10 cases, simple partial seizure in 5 and complex partial seizure in 37 among which 17 presented with secondary epileptic attack. The lesions involved the mesial temporal lobes bordered by collateral sulcus in 19 cases and were located in the neocortical temporal lobes in 33 cases.

### Access this article online

#### Quick Response Code:



Website:  
www.cmj.org

DOI:  
10.4103/0366-6999.154289

**Address for correspondence:** Dr. Jian-Kun Xu,  
Department of Neurosurgery, Xuanwu Hospital, Capital Medical  
University, Beijing 100053, China  
E-Mail: xjk\_7563@163.com

## Surgical treatment

Among the 52 cases, 11 underwent a direct resection of CM along with the adjacent zone of hemosiderin rim without electrocorticogram (ECoG) monitoring while the other 41 cases had operations under the guidance of ECoG. Subdural grids and strips (Ad-Tech Medical Instrument Corporation) were used as necessary to span the borders of the CMs. The individual electrode contacts were 4-mm-diameter platinum-iridium discs with a center-to-center electrode distance of 10 mm. Subdural electrodes (4 × 5 or 2 × 8) were chosen. The cerebral areas displaying significant spikes discharges even after the CM and the zone of hemosiderin resection were also removed. In such patients, 6 have hippocampal sclerosis proved by magnetic resonance imaging (MRI) or abnormal electrical activities detected by sphenoid electrodes monitoring. Intra-operative depth electrodes (1 × 6) were utilized. Once epileptiform discharges were confirmed from the mesial temporal lobes, anterior temporal lobectomy or resection of the mesial part of temporal lobes were performed.

## Follow-up and evaluation of therapeutic effectiveness

All the patients kept taking antiepileptic drugs (AEDs) after the operation. The follow-up times were 3 months, 6 months and 12 months after the operation and then once per year. The changes of clinical symptoms were recorded and moreover, electroencephalography record, serum drugs concentration and computed tomography or MRI scanning were implemented. Based on the related result, the agent types and doses of AEDs were modified. Epilepsy outcome analysis after surgery were graded according to the Engel's classification<sup>[8]</sup> [Table 1].

## Statistical analysis

All statistical analyses were performed using SPSS (version 13.0; Chicago, IL, USA) for Windows. The significance of possible associations between discrete variables was compared by  $\chi^2$  test or Fisher's exact test. A  $P < 0.05$  was considered statistically significant.

## RESULTS

The follow-up time in this study varied from 6 months to 4 years (mean 3.2 years). The diagnosis was verified as CM by pathological examination in all the patients [Figure 1]. No permanent neurological dysfunction was observed during the long-term follow-up. The outcomes about seizure control are as follows [Table 2]: Forty-two patients (80.8%) belong to Engel Class I, 5 patients (9.6%) belong to Engel Class II, 3 patients (5.8%) belong to Engel Class III and 2 patients (3.8%) belong to Engel Class IV.

The patients in our study were divided into two groups according to preoperative seizure duration. The number of the patients who obtained the outcome grade of Engel I was 22 (95.7%) in the 23 patients with a history of <1 year and 20 (69.0%) in the 29 patients who suffered from epilepsy

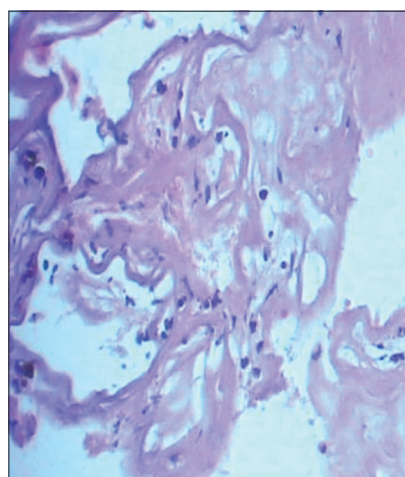
**Table 1: Engel's classification of the outcome of epilepsy surgery**

Outcome class	Definition
I	Free of disabling seizure Completely seizure-free since surgery, nondisabling simple partial seizures after surgery but completely seizure-free for at least 2 years, and convulsions only when medications are withdrawn
II	Almost seizure-free Initially seizure-free but has disabling seizures now, rare disabling seizures since surgery, more than rare seizures after surgery but now rare seizures for at least 2 years, nocturnal seizures only
III	Worthwhile improvement Worthwhile seizure reduction or prolonged seizure-free intervals amounting to half the follow-up period, but not < 2 years
IV	No worthwhile improvement No significant seizure reduction, no appreciable change, or seizures getting worse

**Table 2: The influence on the postoperative outcome**

Postoperative seizure outcome	History of epilepsy (ECoG)				Total
	<1-year		Longer than 1-year		
	With	Without	With	Without	
Engel Class I	19	3	17	3	42
Engel Class II	1	0	2	2	5
Engel Class III	0	0	1	2	3
Engel Class IV	0	0	1	1	2
Total	20	3	21	8	52

ECoG: Electrocorticogram.



**Figure 1:** HE × 250 Postoperative histological figure: High power view shows tumor tissue is composed of high expansion blood sinus, lined with thin wall flat endothelial cells, a few fibrous tissue separation between blood sinus, some area with visible red blood cells and hemosiderin deposition.

for more than 1 year. A slightly better statistically significant outcome appeared in our patients with a preoperative duration of seizures of <1 year ( $P = 0.03$ ).

Engel class I outcome was observed in 36 patients (88.1%) among the ones who underwent surgical resection under the monitoring of ECoG while it was seen in 6 patients (60.0%) among the ones without ECoG monitoring. The use of ECoG in cases of temporal lobe cavernomas resulted in a superior seizure-free outcome than without ECoG monitoring: 87.8% (41 patients) versus 54.5% (11 patients) of patients. There appeared to be a trend toward an increased seizure-free status with the use of ECoG, There was a very strong correlation ( $P = 0.013$ ) between the use of ECoG and more aggressive resections.

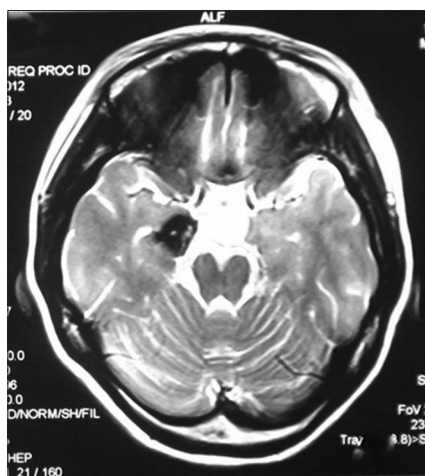
## DISCUSSION

Patients of cerebral CMs usually presented with epileptic seizures. The incidence of epilepsy in patients with temporal lesions is higher than those at other regions.<sup>[9,10]</sup> Patients with seizures due to temporal CM often go on to develop epilepsy that is medically intractable.<sup>[11]</sup> No exact data explain the mechanisms of high epileptogenicity of temporal CM, but close distance to limbic structures is likely to be a cause of intractable seizure activity.<sup>[2]</sup> Since the extended use of MRI, cerebral CMs are increasingly detected as a cause of symptomatic seizures. The typical appearance is annular hypointensive zone around the lesion on T2-WI [Figure 2] and susceptibility weighted imaging has the distinctive advantages in the identification of CMs.<sup>[12]</sup> The lesion can be enhanced inordinately [Figure 3]. The main cause of epileptogenesis of CMs is pathologic changes in the adjacent brain tissue due to chronic recurrent bleeding, the hemosiderin zone (hazard ratio [HR]) lead to the glial proliferation and immune response, which causes continuous stimulation on the adjacent neurons.<sup>[13,14]</sup> The corresponding excessive neural activity or abnormal discharges were supposed to be the main origin of epilepsy. The hemosiderin and iron is thought to play a major role in their epileptogenicity.<sup>[3,12,15]</sup>

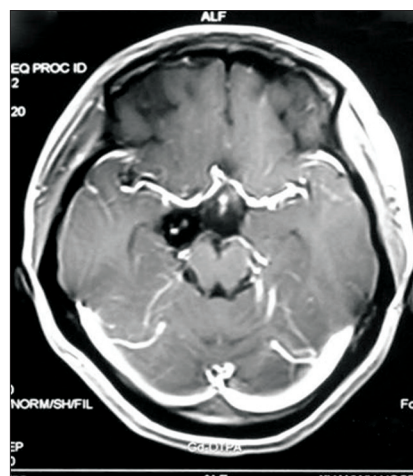
The optimal management of CM-associated seizures and epilepsy is still under debate. The spectrum reaches from

pure lesionectomy, lesionectomy including resection of the surrounding hemosiderin rim, and extended resections, lesionectomy plus cortical resection (including partial or complete lobar resections). Thus, the early surgical removal of the lesions along with the HR will help to improve the prognosis.<sup>[16,17]</sup> Most studies<sup>[16,18]</sup> about seizure outcome after surgery are in agreement that a long preoperative duration of illness is associated with a poor outcome. Early operation which reduces the preoperative duration of seizures is associated with a better outcome. Preferentially before seizures become drug resistant and in order to spare the unnecessary suffering of the patient from ongoing seizures and side effects of AED treatment.<sup>[19,20]</sup> The time during which the lesions exist was positively correlated with the formation of secondary epileptic foci and dual pathology, which makes the surgical effect more likely to be inadequate. Kivelev *et al.*<sup>[21]</sup> have reported about the surgical treatment of 49 cases with single temporal CM and relevant seizures. In all cases, total resection of the lesions and HR was performed. The follow-up demonstrated that 90% of the cases finally achieved Grade I or II in the Engel's classifications. The 10 patients who only had one epileptic seizure before the operation never had a seizure again. These results<sup>[21-23]</sup> are supported by our study as well as the overall positive effect of surgery in which up to 80.8% of the patients became seizure free. The patients in our study were divided into two groups according to preoperative epilepsy duration. The fact that the duration of illness was significantly related to a poor outcome in more than 1 year group ( $P = 0.03$ ). This is especially true for those patients who have sporadic seizures and a history of <1 year probably benefit from a early operation.

The finding of increased seizure freedom related to more aggressive resection has also been suggested by Hammen *et al.*<sup>[16]</sup> In the treatment of intractable epilepsy, Yeon *et al.*<sup>[24]</sup> trended to be more aggressive resection. In their view, removal of the involved areas and the possible secondary epileptic zone outside the lesion itself help to make it more likely to control

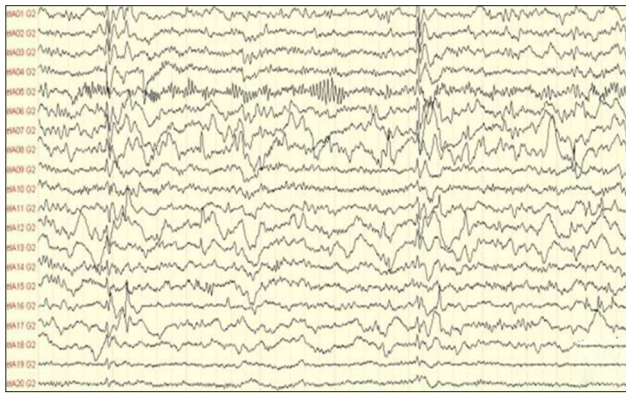

**Figure 2:** Preoperative MRI scans of a 12-year-old girl with intractable epilepsy. A cerebral cavernous angioma with perilesional hemosiderin deposits was detectable in a right-sided mesiotemporal location.



**Figure 3:** Preoperative MRI scans on T1-weighted images with a little contrast enhancement in the parenchymal part of the lesion after administration of intravenous gadolinium.

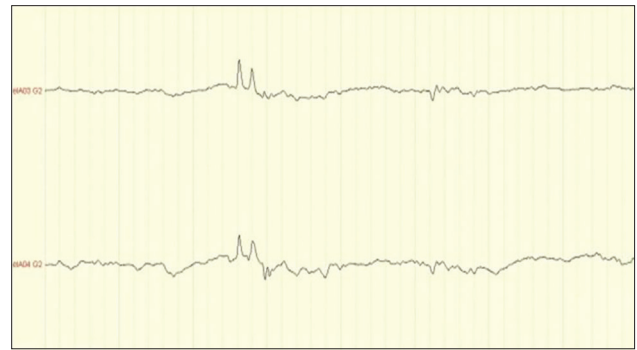




**Figure 4:** The ECoG showed the spikes on the electrodes inserted into the right temporal base. (0.5Hz-70Hz,800uV/cm)

the seizures ideally. However, it is unclear how aggressive resections should be in patients with medically refractory epilepsy. The use of ECoG intraoperatively as a means of identifying and removing secondary epileptic foci with more aggressive resection.<sup>[4,10]</sup> Van Gompel *et al.*<sup>[25]</sup> reported that in the 61 patients operated on their center, all the patients who underwent intraoperative ECoG monitoring showed other epileptic foci outside the lesions and thus received extended resection, the outcome was better about these patients. More and more researchers<sup>[24,26]</sup> turned to support the views that a broader range of resection is necessary in the patients with CM related intractable epilepsy. Our data indicated that although simple resection of CM can result in the control of clinical symptoms to some degree, extended excision under ECoG monitoring will help to achieve a better prognosis [Figure 4]. Patients with a relatively long history may have secondary epileptic foci or dual pathology, which can make the treatment even more complex. Dual pathology<sup>[23]</sup> (cavernoma + hippocampal sclerosis), which means the coexistence of hippocampal sclerosis with extra-hippocampal lesion, Recurrent seizures can cause hippocampal sclerosis constantly and thus generate a new epileptogenic zone in the mesial part of temporal lobe. Indeed, this makes the intraoperative ECoG monitoring necessarily. Six of our cases with CMs have hippocampal sclerosis confirmed by the preoperative MRI scanning or spike waves detected by the sphenoid electrodes. After the removal of lesions and HR, ECoG and the depth electrodes still demonstrated significant epileptic discharges which led to the anterior temporal lobectomy or resection of the mesial part of temporal lobes [Figure 5]. These patients had no recurrent of epilepsy postoperatively. Our results indicate that a satisfactory better therapeutic outcome requires complete elimination of the epileptogenic foci in which extended lesionectomy should include perilesional tissue if the ECoG reveals focal epileptic activity originated in the latter. Due to the present study and based on our data, we believe that ECoG and more aggressive surgical therapy is likely to enhance seizure-free survival.

Early surgical treatment is necessary in patients of temporal CMs who are presented with epilepsy. Intraoperative ECoG monitoring should be chosen routinely. Total resection of the CM, the surrounding HR and the secondary epileptic foci



**Figure 5:** After the removal of lesion and HR, ECoG with the depth electrodes puncture in hippocampus still demonstrate significant epileptic discharges which led to resect of the mesial part of temporal lobes.

without obvious impairment on the cerebral function will enable the patient to be seizure free. While the CM lesion is located in the mesial part of temporal lobe and intractable epilepsy has been confirmed, anterior temporal lobectomy or selective resection of the mesial part of temporal lobe to be needed.

## REFERENCES

1. Batra S, Lin D, Recinos PF, Zhang J, Rigamonti D. Cavernous malformations: Natural history, diagnosis and treatment. *Nat Rev Neurol* 2009;5:659-70.
2. Bertalanffy H, Benes L, Miyazawa T, Alberti O, Siegel AM, Sure U. Cerebral cavernomas in the adult. Review of the literature and analysis of 72 surgically treated patients. *Neurosurg Rev* 2002;25:1-53.
3. Awad I, Jabbour P. Cerebral cavernous malformations and epilepsy. *Neurosurg Focus* 2006;21:e7.
4. Ferrier CH, Aronica E, Leijten FS, Spliet WG, Boer K, van Rijen PC, *et al.* Electroconvulsive discharge patterns in patients with a cavernous hemangioma and pharmacoresistant epilepsy. *J Neurosurg* 2007;107:495-503.
5. Raabe A, Schmitz AK, Pernhorst K, Grote A, von der Brölie C, Urbach H, *et al.* Cliniconeuropathologic correlations show astroglial albumin storage as a common factor in epileptogenic vascular lesions. *Epilepsia* 2012;53:539-48.
6. Menzler K, Chen X, Thiel P, Iwinska-Zelder J, Miller D, Reuss A, *et al.* Epileptogenicity of cavernomas depends on (archi-) cortical localization. *Neurosurgery* 2010;67:918-24.
7. Maiuri F, Cappabianca P, Gangemi M, De Caro Mdel B, Esposito F, Pettinato G, *et al.* Clinical progression and familial occurrence of cerebral cavernous angiomas: The role of angiogenic and growth factors. *Neurosurg Focus* 2006;21:e3.
8. Engel J Jr. Clinical neurophysiology, neuroimaging, and the surgical treatment of epilepsy. *Curr Opin Neurol Neurosurg* 1993;6:240-9.
9. Stefan H, Hammen T. Cavernous haemangiomas, epilepsy and treatment strategies. *Acta Neurol Scand* 2004;110:393-7.
10. Sugano H, Shimizu H, Sunaga S. Efficacy of intraoperative electrocorticography for assessing seizure outcomes in intractable epilepsy patients with temporal-lobe-mass lesions. *Seizure* 2007;16:120-7.
11. Chang EF, Gabriel RA, Potts MB, Garcia PA, Barbaro NM, Lawton MT. Seizure characteristics and control after microsurgical resection of supratentorial cerebral cavernous malformations. *Neurosurgery* 2009;65:31-7.
12. Baumann CR, Schuknecht B, Lo Russo G, Cossu M, Citterio A, Andermann F, *et al.* Seizure outcome after resection of cavernous malformations is better when surrounding hemosiderin-stained brain also is removed. *Epilepsia* 2006;47:563-6.
13. Englot DJ, Han SJ, Lawton MT, Chang EF. Predictors of seizure

- freedom in the surgical treatment of supratentorial cavernous malformations. *J Neurosurg* 2011;115:1169-74.
14. Upchurch K, Stern JM, Salamon N, Dewar S, Engel J Jr, Vinters HV, *et al.* Epileptogenic temporal cavernous malformations: Operative strategies and postoperative seizure outcomes. *Seizure* 2010;19:120-8.
  15. Williamson A, Patrylo PR, Lee S, Spencer DD. Physiology of human cortical neurons adjacent to cavernous malformations and tumors. *Epilepsia* 2003;44:1413-9.
  16. Hammen T, Romstöck J, Dörfler A, Kerling F, Buchfelder M, Stefan H. Prediction of postoperative outcome with special respect to removal of hemosiderin fringe: A study in patients with cavernous haemangiomas associated with symptomatic epilepsy. *Seizure* 2007;16:248-53.
  17. Stavrou I, Baumgartner C, Frischer JM, Trattinig S, Knosp E. Long-term seizure control after resection of supratentorial cavernomas: A retrospective single-center study in 53 patients. *Neurosurgery* 2008;63:888-96.
  18. Kim W, Stramotas S, Choy W, Dye J, Nagasawa D, Yang I. Prognostic factors for post-operative seizure outcomes after cavernous malformation treatment. *J Clin Neurosci* 2011;18:877-80.
  19. Josephson CB, Leach JP, Duncan R, Roberts RC, Counsell CE, Al-Shahi Salman R, *et al.* Seizure risk from cavernous or arteriovenous malformations: Prospective population-based study. *Neurology* 2011;76:1548-54.
  20. von der Brälie C, Malter MP, Niehusmann P, Elger CE, von Lehe M, Schramm J. Surgical management and long-term seizure outcome after epilepsy surgery for different types of epilepsy associated with cerebral cavernous malformations. *Epilepsia* 2013;54:1699-706.
  21. Kivelev J, Niemelä M, Blomstedt G, Roivainen R, Lehecka M, Hernesniemi J. Microsurgical treatment of temporal lobe cavernomas. *Acta Neurochir (Wien)* 2011;153:261-70.
  22. Arita K, Kurisu K, Iida K, Hanaya R, Sugiyama K, Akimitsu T, *et al.* Surgical treatment for intractable epilepsy caused by cavernous angioma in the temporal lobe of the dominant hemisphere – Three case reports. *Neurol Med Chir (Tokyo)* 2000;40:439-45.
  23. Okujava M, Ebner A, Schmitt J, Woermann FG. Cavernous angioma associated with ipsilateral hippocampal sclerosis. *Eur Radiol* 2002;12:1840-2.
  24. Yeon JY, Kim JS, Choi SJ, Seo DW, Hong SB, Hong SC. Supratentorial cavernous angiomas presenting with seizures: Surgical outcomes in 60 consecutive patients. *Seizure* 2009;18:14-20.
  25. Van Gompel JJ, Rubio J, Cascino GD, Worrell GA, Meyer FB. Electrocorticography-guided resection of temporal cavernoma: Is electrocorticography warranted and does it alter the surgical approach? *J Neurosurg* 2009;110:1179-85.
  26. von der Brälie C, Schramm J. Cerebral cavernous malformations and intractable epilepsy: The limited usefulness of current literature. *Acta Neurochir (Wien)* 2011;153:249-59.

**Received:** 09-12-2014 **Edited by:** De Wang  
**How to cite this article:** Shan YZ, Fan XT, Meng L, An Y, Xu JK, Zhao GG. Treatment and Outcome of Epileptogenic Temporal Cavernous Malformations. *Chin Med J* 2015;128:909-13.  
**Source of Support:** Nil. **Conflict of Interest:** None declared.