

Troubleshooting the Femoral Attachment During Medial Patellofemoral Ligament Reconstruction

Location, Location, Location

M. Tyrrell Burrus,* MD, Brian C. Werner,* MD, Evan J. Conte,* MD, and David R. Diduch,*^{†‡} MD
Investigation performed at the University of Virginia Health System, Charlottesville, Virginia, USA

The medial patellofemoral ligament (MPFL) has been recognized as an important soft tissue restraint in preventing lateral patellar translation. As many patients with acute or chronic patellar instability will have a deficient MPFL, reconstruction of this ligament is becoming more common. Appropriately, significant research has been undertaken regarding graft biomechanics and techniques, as intraoperative errors in graft placement often result in poor patient outcomes. Although the research has not answered all of the dilemmas encountered during reconstruction, publications consistently emphasize the importance of re-establishing an anatomic femoral attachment. The purpose of this study was to briefly review the current literature on MPFL reconstruction. Graft selection and patellar graft attachment and fixation are discussed, but the main focus is the femoral attachment as this is where most errors are seen and, unfortunately, where getting it right appears to matter the most. Using a sawbones knee model, the concepts of an MPFL graft that is “high and tight” or “low and loose” are presented, with the goal of providing physicians with intraoperative tools to adjust an incorrectly placed femoral MPFL attachment. This model is also used to justify the recommendation of graft fixation in 30° to 45° of knee flexion.

Keywords: MPFL; femur; Schottle; anatomic

As patellar instability becomes a more commonly recognized entity, surgical techniques addressing this problem continue to be refined. There are myriad bony and soft tissue surgical procedures that have been developed to stabilize the patella. Reconstruction of the medial patellofemoral ligament (MPFL) is one such procedure that has garnered significant attention. In the first 30° of knee flexion when the patella may begin to dislocate, the MPFL acts as the primary static stabilizer for the patella.^{1,5} Traumatic disruptions of this ligament often warrant surgical intervention in patients with recurrent patellar instability. Although MPFL repair formerly was a popular procedure, it has

fallen out of favor because of higher failure rates after repair and more consistent successful results reported after reconstruction.^{7,14-16}

Important topics in MPFL reconstruction include graft choice, patellar tunnel location and fixation, and femoral tunnel location and fixation. Although no gold standard has been established for most of these aspects of MPFL reconstruction, most surgeons agree that obtaining an anatomic femoral attachment is imperative to a successful outcome.^{8,16} Radiographic and anatomic landmarks are 2 available resources to obtain this precise location, but the surgeon must also be able to predictably adjust this location intraoperatively to re-create each patient’s unique anatomy. This article briefly reviews the current literature and techniques of MPFL reconstruction and, using a sawbones model, illustrates graft kinematics and the logic behind making purposeful femoral attachment adjustments intraoperatively.

GRAFT OPTIONS

Numerous graft options exist for MPFL reconstruction. These include hamstring autograft or allograft, quadriceps tendon, adductor tendon, and several synthetic graft

[‡]Address correspondence to David R. Diduch, MD, University of Virginia Health System, PO Box 800159 HSC, Charlottesville, VA 22908, USA (email: drd5c@virginia.edu).

*Department of Orthopaedic Surgery, University of Virginia Health System, Charlottesville, Virginia, USA.

[†]University of Virginia Athletics Department, Charlottesville, Virginia, USA.

The authors declared that they have no conflicts of interest in the authorship and publication of this contribution.

options.^{5,11,19} The choice of graft is largely related to surgeon preference, as all the aforementioned graft options fail at a force much higher than the 208 N of the native MPFL.¹ Our preferred technique utilizes a gracilis autograft harvested from the ipsilateral knee. A minimum of 22 to 25 cm of length is necessary to loop the tendon through patellar tunnels and into the femoral tunnel, which is routinely achievable with a gracilis autograft. A medially based, partial-thickness quadriceps tendon turn-down also offers a length of around 10 cm to conveniently reach the femoral origin.

PATELLAR ATTACHMENT AND FIXATION OPTIONS

The patellar attachment of the MPFL has received considerably less scrutiny than the femoral attachment.¹⁶ Anatomic studies have found that the patellar attachment of the MPFL averages 7.4 ± 3.5 mm anterior to the posterior patellar cortical line and 5.4 ± 2.6 mm distal to the perpendicular line intersecting the proximal margin of the patellar articular surface.³ This equates to an insertion on the superomedial half to one-third of the patella, in addition to its insertion on the distal undersurface of the vastus medialis.²¹

It is far less critical to achieve the exact anatomic location of the patellar MPFL insertion during reconstruction than it is for the femoral attachment.^{23,26,27} Numerous acceptable options exist for graft configuration at the patellar insertion and fixation to the patellar insertion. Authors have described the use of single- or double-tailed grafts at the patellar insertion, with the latter being touted as covering more of the native MPFL patellar footprint.¹⁶ Options for patellar fixation are numerous and include suture anchors, interference screws, transpatellar sutures, suspensory techniques, and bone tunnels.^{12,17,20,22} Full-width, transverse patellar tunnels should be avoided, however, as they act as stress risers and may lead to an intraoperative or postoperative fracture.²⁰

Our preferred technique for patellar attachment is to place 2 short, parallel, oblique drill holes (3 mm in diameter) in the proximal one-third to one-half of the patella (Figure 1, A and B). A gracilis autograft is then looped through the tunnels, with mineral oil used to assist with tight graft passage. No patellar fixation is necessary using this technique, thereby decreasing implant cost, and the oblique drill holes significantly reduce the risk of fracture posed by full-width transverse tunnels. The graft is then passed between the capsule and medial retinaculum to the femoral attachment.

FEMORAL ATTACHMENT

The precise location of the femoral attachment of the MPFL has been recently delineated in cadaveric dissections by LaPrade et al.¹⁰ Anatomic placement of the femoral attachment is critical to a well-functioning reconstruction and minimizes complications. The location of the femoral origin of the MPFL is between the adductor tubercle and the medial epicondyle. It is closer to the adductor tubercle, being

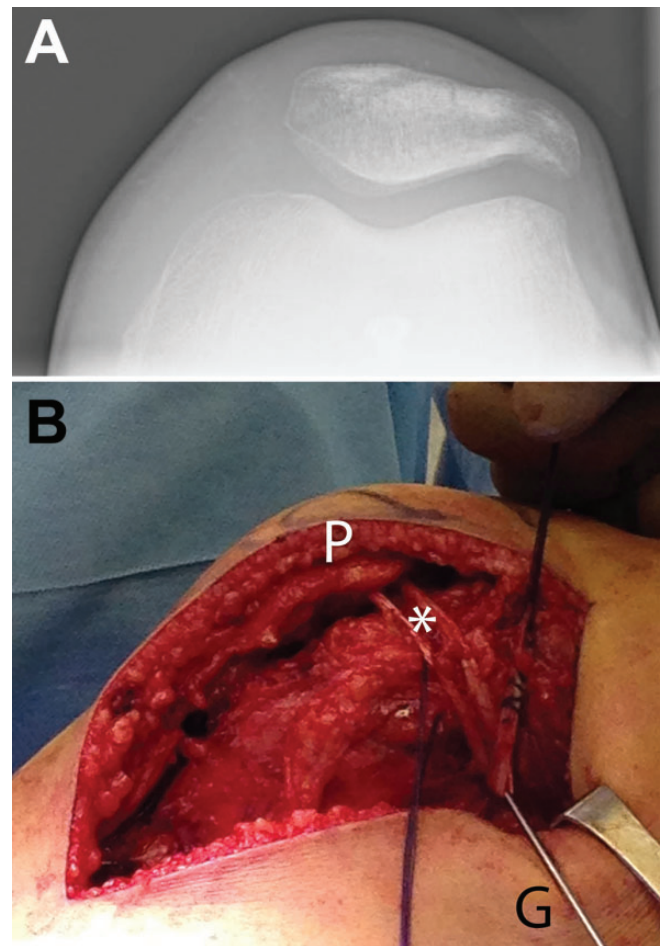


Figure 1. (A) Postoperative sunrise radiograph demonstrates the short, oblique patellar tunnels. As they are only 3 mm in diameter and the majority of the patella is not violated by the drill holes, the fracture risk is minimized. This patient had a bipartite patella. (B) Intraoperative image demonstrating the 2-tailed medial patellofemoral ligament (MPFL) technique with the surgeon assessing graft behavior through knee range of motion. Notice that the graft is wrapped around the guide pin. This patient also underwent a proximal tibial realignment procedure, which required a larger incision. G, guide pin; P, patella; *MPFL graft.

just 2 mm anterior and 4 mm distal to this prominence.¹⁰ The MPFL is not entirely isometric but does demonstrate mostly isometric properties between either 0° and 70° or 0° and 110° .^{21,26,29} Nonanatomic placement of the femoral attachment can cause significant changes in graft isometry, which results in a graft that is either too loose or too tight during various degrees of knee flexion. As described below, femoral attachments that are more proximally placed will result in increased graft tension in flexion that will dramatically increase the contact pressures between the medial facet of the patella and the medial trochlea. Grafts placed too distal will have decreased graft tension and provide a diminished check-reign effect to aid in patellar guidance into the trochlea.

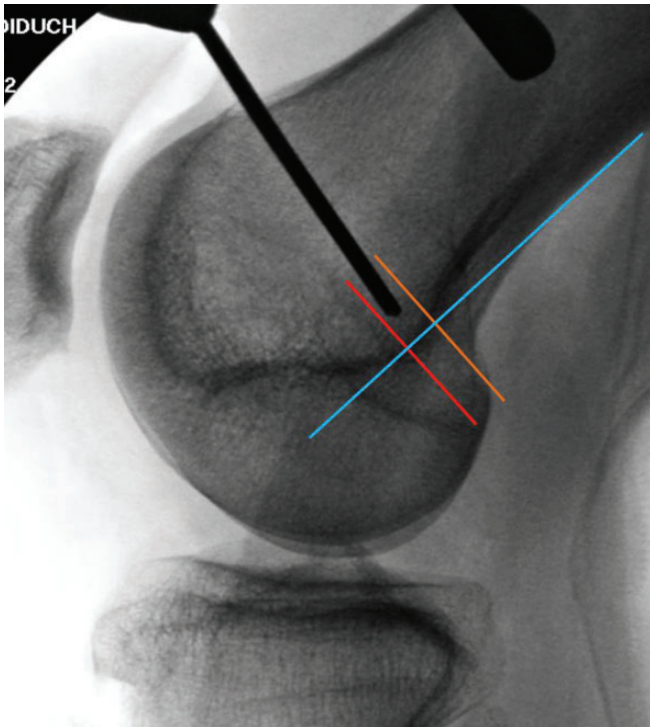


Figure 2. Intraoperative localization of the Schottle point. The blue line is drawn down the posterior femoral cortex. The orange line marks the transition of the curve of the posterior femoral condyle and is perpendicular to the blue line. The red line is at the posterior aspect of the Blumensaat line and is also perpendicular to the blue line.

Intraoperatively, a formal dissection to visually locate the femoral origin of the MPFL for proper tunnel placement is unnecessary thanks to research by Schottle et al,¹⁸ which correlated the fluoroscopic and anatomic location of the MPFL. The fluoroscopic location of the femoral origin of the MPFL has come to be known as the *Schottle point*. The first reference for the Schottle point is a line continued distally from the posterior femoral cortex. The second reference uses 2 lines that are perpendicular to the first: 1 at the posterior aspect of the Blumensaat line and the second at the transition of the curve of the posterior femoral condyles. The Schottle point rests 2 mm anterior to the posterior cortical line between the 2 perpendicular lines (Figure 2). It is critical to obtain a perfect lateral of the distal femur, as slight rotational or angular variations will lead to non-anatomic graft placement. Once the tip of the guide pin rests exactly on the Schottle point, it should be driven across the femur while being careful to not aim too distal or too posterior. Another method to find the femoral origin of the MPFL uses fluoroscopy to divide the distal femur into percentages based off of the anterior to posterior dimensions of the distal femur (Figure 3).²⁶ Once the pin is placed and the graft tunneled between the medial layers of the knee, the graft can then be wrapped around the pin and tensioned while the knee is taken

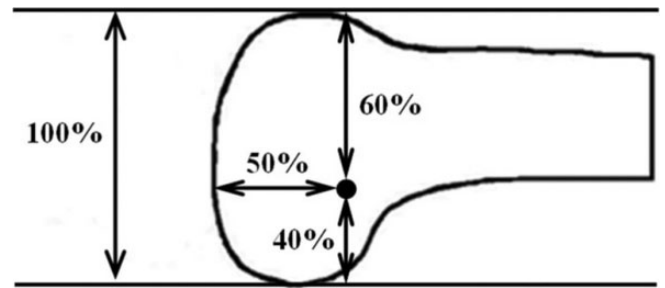


Figure 3. The medial patellofemoral ligament (MPFL) attachment is defined in relation to the anterior-posterior size of the medial femoral condyle: If the anterior-posterior size is referred to as 100%, then the MPFL attachment is 40% from the posterior and 50% from the distal outline. (Reprinted with permission from Stephen JM, Lumpaopong P, Deehan DJ, Kader D, Amis AA. The medial patellofemoral ligament: location of femoral attachment and length change patterns resulting from anatomic and nonanatomic attachments. *Am J Sports Med.* 2012;40:1871-1879. ©2012, The American Orthopaedic Society for Sports Medicine.)

through a complete range of motion to assess isometry (Figure 1B).

Even after locating the anatomic femoral insertion using lateral radiographs, some patients may have variable distal femoral anatomy that requires that the femoral attachment be fine-tuned.^{19,26} Thus, for some patients, even after placing the guide pin at the Schottle point, varying graft tension or length during knee range of motion necessitates minor femoral attachment adjustments. However, even for experienced knee surgeons, appropriately changing the guide pin location can be more of a trial and error endeavor. Given the lack of published recommendations for these adjustments, we developed a model to help illustrate how to troubleshoot selecting the optimal femoral location.

In our model, a sawbones replica of the knee (including collateral and cruciate ligaments) was used to simulate the basic kinematics of the MPFL. (Note: The inherent limitation of a sawbones model is that it lacks the complete knee soft tissue complement, including the secondary retinacular restraints; thus, this model is used here to describe overall graft behavior and not the numerical specifics regarding graft length changes.) Using fluoroscopy, a 2.4-mm guide pin was placed in the femur at the Schottle point. Two holes were placed in the patella at 25% and 50% distal from the superior pole, and a single suture was passed through them with the 2 free ends of the suture draped over the guide pin. A 1-lb weight was attached to the end of the suture to provide consistent tension. With the string draped over the guide pin in full knee extension, the location on the suture that touched the guide pin was marked. For each test, this was the “zero” distance, and all measurements were made relative to this. Four additional femoral “erroneous” MPFL attachments were created relative to the Schottle point: 1 cm proximal, 1 cm distal, 1 cm anterior, and 1 cm posterior.

Next, the knee was taken through a range of motion (ROM) from -10° (ie, hyperextension) to 135° of knee flexion, with changes in suture length recordings made at -10° , 0° , 30° , 45° , 60° , 90° , 120° , and 135° . The change from the “zero” mark was recorded with negative values corresponding to a shorter graft length between the patellar and femoral attachments, and positive values corresponding to the opposite. These values were measured to the nearest millimeter. Values were recorded 3 times for each femoral location, averaged, and rounded to the nearest millimeter. Using Excel (Microsoft Corp), line graphs were created that demonstrate suture (ie, graft) length change during knee ROM.

Based on the above data, recommendations were developed to assist surgeons in making intraoperative adjustments if the graft becomes too tight or too loose during knee flexion. As shown in Figure 4, if the guide pin is attached to the femur at a location proximal to the Schottle point, then the suture has positive length changes as the knee is brought into flexion (ie, the distance between the patellar and femoral attachments increases). This is due to the cam shape of the distal femur with the long anterior to posterior length of the femoral condyles. Thus, the graft will become too tight when the knee is brought into flexion. A simple way to recall this relationship is “high and tight,” as a proximal or high pin position results in a graft tight in flexion. Conversely, if the guide pin is attached to the femur at a location distal to the Schottle point, then the graft has negative length changes as the knee is brought into flexion (ie, the distance between the patellar and femoral attachments decreases) (Figure 5). Thus, the graft will become too loose when the knee is brought into flexion. A simple way to recall this relationship is “low and loose.” Intraoperatively, a commonly used technique to measure graft tension is to loop the 2 free graft ends around the guide pin in the femur and take the knee through a full ROM. As light tension is applied, changes in length are observed. The surgeon can also manually assess patella translation and stability. Thus, the surgeon can roughly gauge graft tension and, based on the above concepts, make femoral attachment adjustments as needed.

Moving the guide pin location 1 cm posterior was challenging on the knee model because of the already posterior location of the Schottle point. The graphic representation of this attachment mimicked the distal femoral attachment and did not appear to present any unique graft kinematics. However, the difficulty in obtaining this location on the model reinforces the idea that the Schottle point is already quite posterior on the condyle. The anterior guide pin location was noted to become slightly loose in extension, which may result in recurrence of instability. Based on this analysis, graft malpositioning in the anterior-posterior direction appears to have a less deleterious effect on graft kinematics than proximal-distal attachment inaccuracies.

KNEE FLEXION ANGLE FOR FIXATION

As this model demonstrates, the cam shape of the distal femur does play a role in graft length during ROM,

especially in deep flexion. There is currently no consensus in the literature regarding how many degrees the knee should be flexed when the graft is secured to the femur. Positions from full knee extension to 90° of flexion are reported, with the most frequent recommendations in the 30° to 60° range.^{9,11,24,25,28,29}

Our findings indirectly support securing the graft in the 30° to 45° range. The basis for this recommendation is established from prior research, which suggests that (1) the MPFL is the most important patellar stabilizer during the first 30° of knee flexion until the patella engages the trochlear groove,^{1,5} (2) overtightening the graft in extension results in iatrogenic medial subluxation of the patella, and (3) overtightening the graft in flexion results in loss of flexion and chondrosis.^{6,8,16,25,28} By examining the line graphs, if the graft is secured in more than 45° of knee flexion, the graft demonstrates significant variability in length during the 0° to 30° flexion range if the femoral attachment is not exactly at the Schottle point (Figure 6). In other words, fixing the graft at greater than 45° of knee flexion will magnify any mistakes in location and creates additional difficulty in maintaining appropriate graft kinematics when it is most important for patellar stability (ie, from 0° to 30° of knee flexion). Even if the femoral attachment is not exactly at the Schottle point, fixing the graft in the 30° to 45° range will minimize any deleterious effect.

Fixing the graft in more extension before the patella engages in the trochlear groove is also not recommended since allowing the patella to rest in its corresponding groove assists greatly in establishing the correct graft length. Prior to entering the trochlear groove, the patella is fairly mobile and may be placed anywhere on the anterior femoral cortex. A loose graft here results in continued lateral subluxation in extension. Depending on the femoral attachment, a tight graft will likely only become tighter in deep knee flexion and results in medial subluxation in extension.

GRAFT TENSIONING

In addition to tunnel position, another critical variable contributing to a successful outcome after MPFL reconstruction is appropriate tensioning of the graft.¹⁶ Even with the correct femoral tunnel location, grafts can create significant postoperative problems if inappropriately tensioned. MPFL graft tension of only 2 N restores normal patellar translation.^{4,25} Grafts tensioned between 10 and 40 N result in significantly increased medial patellofemoral pressures and medial patellar tilt.²⁵ Additional complications from overtensioning include loss of knee flexion, medial patellar subluxation, and patellofemoral chondrosis.^{6,8,13,16,25,28} Clinically, an appropriately tensioned MPFL reconstruction should allow up to 2 quadrants of lateral patellar translation with the knee extended and will fully stabilize the patella to attempts at passive lateral translation by approximately 30° of flexion.²

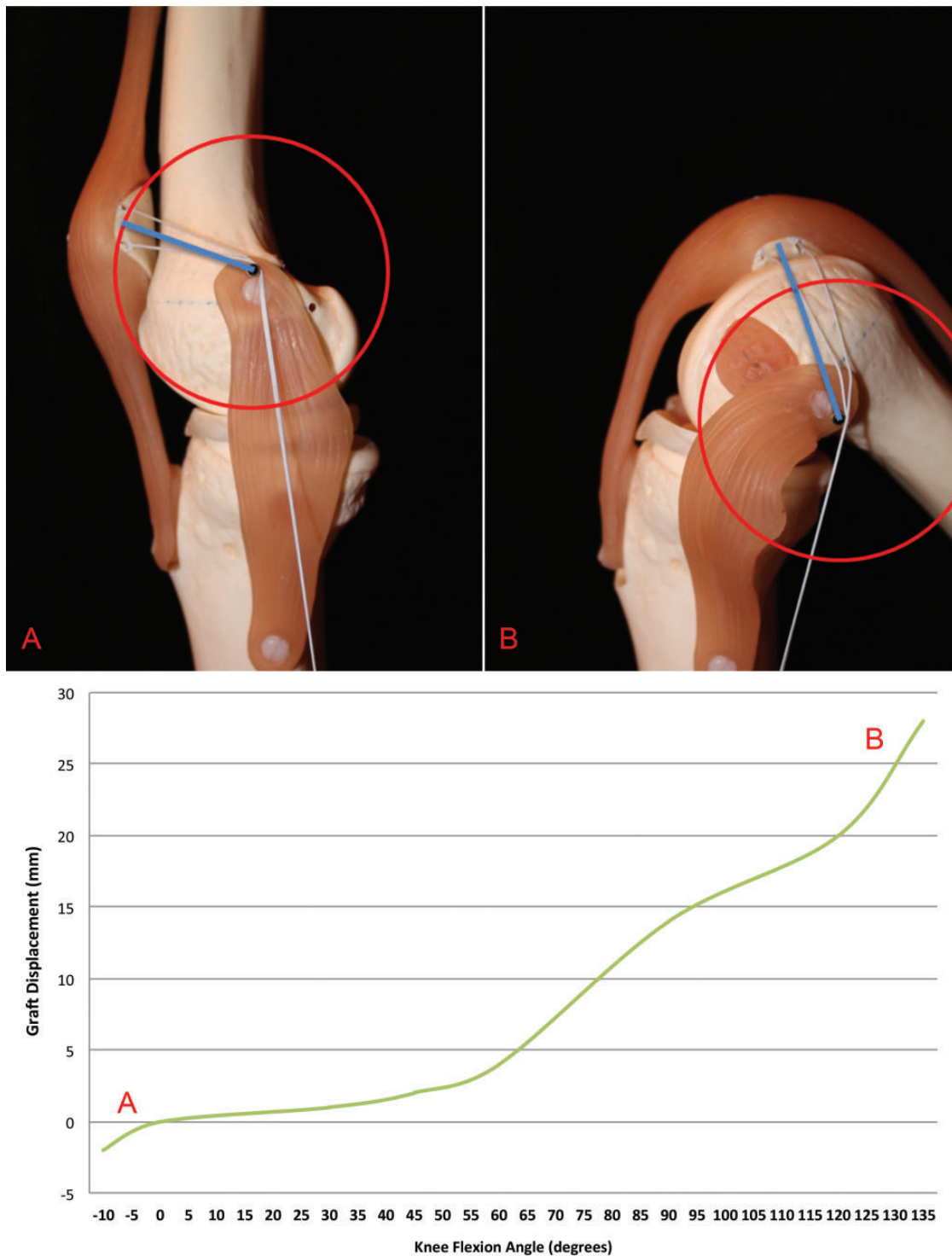


Figure 4. Sawbones and corresponding graphic depiction of how a poorly placed proximal medial patellofemoral ligament (MPFL) femoral attachment creates too much tension in the graft during knee flexion, as a longer graft would be required to maintain the same amount of tension. The red circle matches the radius of the graft at full extension. The blue line represents the distance from the femoral insertion to the patellar insertion. In other words, if the blue line ends outside of the red circle, then the graft would be too tight. Thus, “high and tight.”

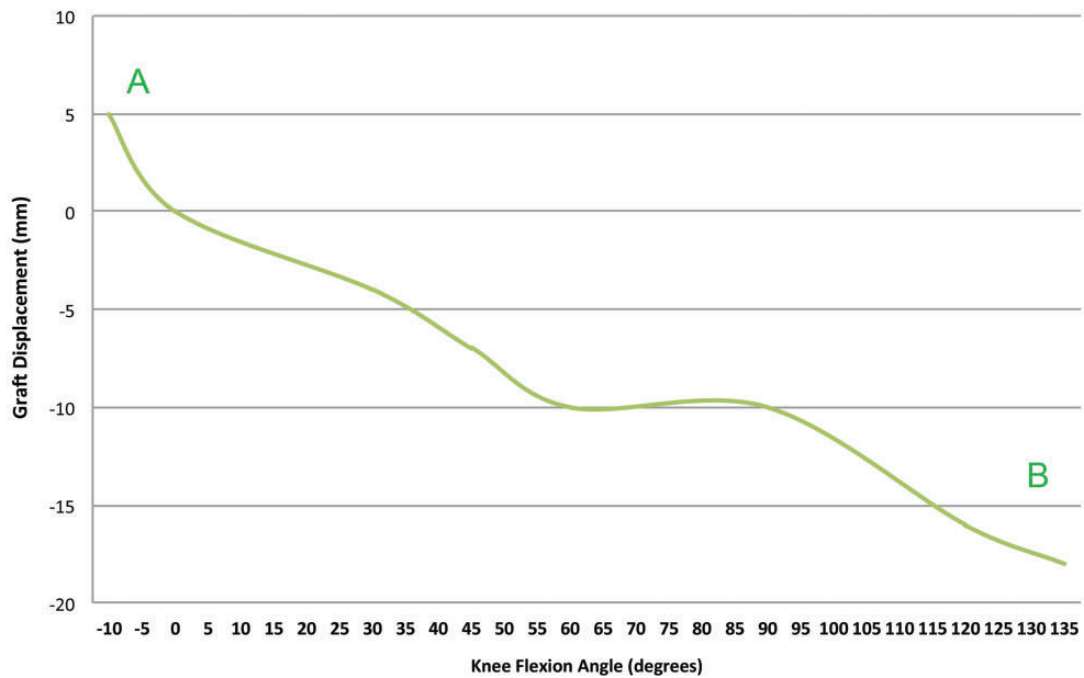
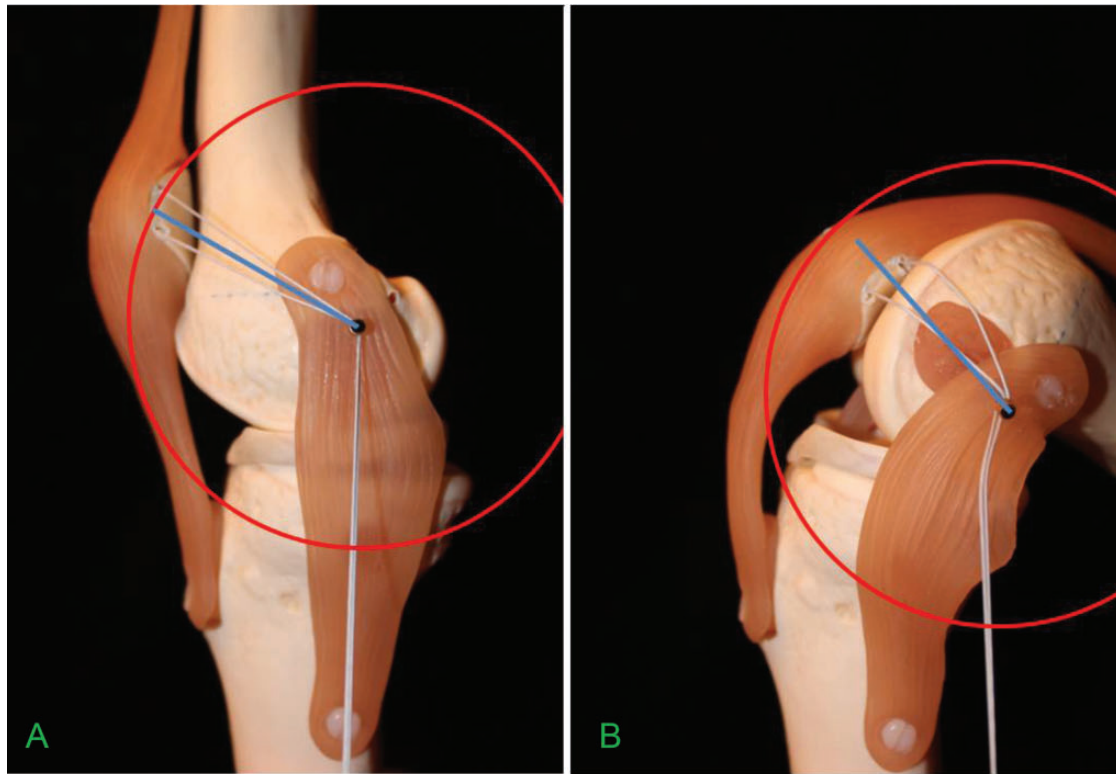


Figure 5. Sawbones and corresponding graphic depiction of how a poorly placed distal medial patellofemoral ligament (MPFL) femoral attachment creates too much laxity in the graft during knee flexion, as a shorter graft would be required to maintain the same amount of tension. The red circle matches the radius of the graft at full extension. The blue line represents the distance from the femoral insertion to the patellar insertion. In other words, if the blue line ends inside of the red circle, then the graft would be too loose. Thus, “low and loose.”

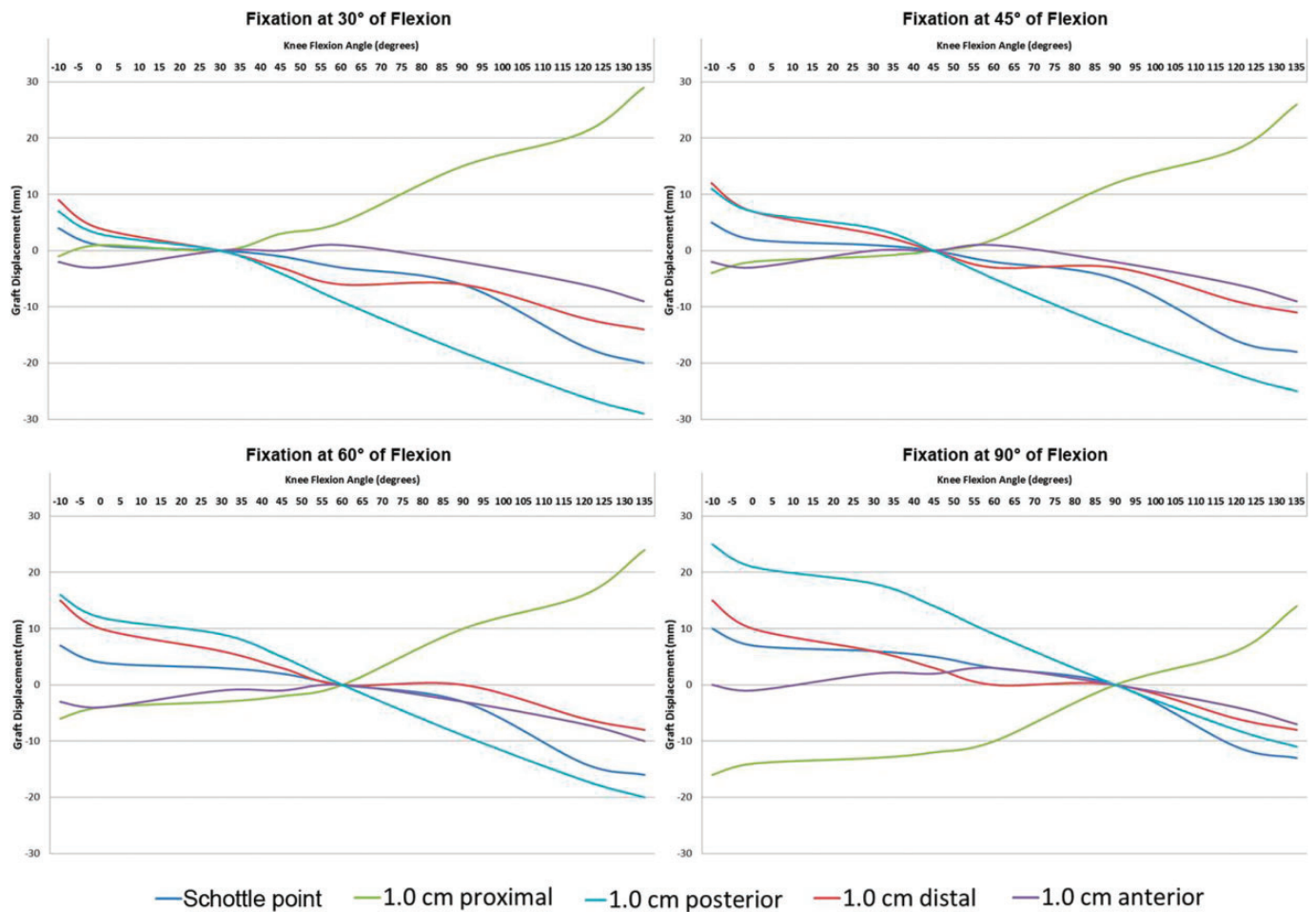


Figure 6. Graphic depictions of various femoral attachments with the model medial patellofemoral ligament (MPFL) fixed at different knee flexion angles. For grafts fixed at >45° of knee flexion, substantial variation in graft lengths occur during the 0° to 30° range if the femoral attachment is not exactly at the Schottle point. As the MPFL is most important during the first 30° of flexion, deviations from proper kinematics will have significant clinical implications.

FEMORAL FIXATION

Options for femoral fixation during MPFL reconstruction are not nearly as varied as on the patellar side. Although there is no clear gold standard, the majority of studies describing MPFL reconstruction utilize an interference screw in a bone tunnel.^{11,19} Suture anchor fixation is another described but less commonly utilized option. Our preferred technique for femoral fixation during MPFL reconstruction is a 7-mm bioabsorbable interference screw. The 2 free tails of the gracilis autograft are placed into a 7-mm femoral tunnel and then secured with the described interference screw.

CONCLUSION

To properly reconstruct the MPFL, surgeons must have an appreciation of the MPFL anatomy, kinematics, and reconstruction options. Obtaining an anatomic femoral attachment appears to have the most significant impact

on outcomes as small errors result in clinically important changes in graft behavior. Understanding the length-tension relationships of the MPFL based on different femoral attachment points will help the surgeon troubleshoot intraoperatively. “High and tight” and “low and loose” are 2 easily remembered sayings that can help surgeons adjust the femoral attachment to predictably correct initial errors and thus improve postoperative outcomes.

REFERENCES

1. Amis AA, Firer P, Mountney J, Senavongse W, Thomas NP. Anatomy and biomechanics of the medial patellofemoral ligament. *Knee*. 2003; 10:215-220.
2. Arendt EA. *Medial Side Patellofemoral Anatomy: Surgical Implications in Patellofemoral Instability*. Berlin, Germany: Springer; 2010.
3. Barnett AJ, Howells NR, Burston BJ, Ansari A, Clark D, Eldridge JD. Radiographic landmarks for tunnel placement in reconstruction of the medial patellofemoral ligament. *Knee Surg Sports Traumatol Arthrosc*. 2012;20:2380-2384.

4. Beck P, Brown NA, Greis PE, Burks RT. Patellofemoral contact pressures and lateral patellar translation after medial patellofemoral ligament reconstruction. *Am J Sports Med.* 2007;35:1557-1563.
5. Bicos J, Fulkerson JP, Amis A. Current concepts review: the medial patellofemoral ligament. *Am J Sports Med.* 2007;35:484-492.
6. Bollier M, Fulkerson J, Cosgarea A, Tanaka M. Technical failure of medial patellofemoral ligament reconstruction. *Arthroscopy.* 2011;27:1153-1159.
7. Camp CL, Krych AJ, Dahm DL, Levy BA, Stuart MJ. Medial patellofemoral ligament repair for recurrent patellar dislocation. *Am J Sports Med.* 2010;38:2248-2254.
8. Elias JJ, Cosgarea AJ. Technical errors during medial patellofemoral ligament reconstruction could overload medial patellofemoral cartilage: a computational analysis. *Am J Sports Med.* 2006;34:1478-1485.
9. Farr J, Schepesis AA. Reconstruction of the medial patellofemoral ligament for recurrent patellar instability. *J Knee Surg.* 2006;19:307-316.
10. LaPrade RF, Engebretsen AH, Ly TV, Johansen S, Wentorf FA, Engebretsen L. The anatomy of the medial part of the knee. *J Bone Joint Surg Am.* 2007;89:2000-2010.
11. LeGrand AB, Greis PE, Dobbs RE, Burks RT. MPFL reconstruction. *Sports Med Arthrosc.* 2007;15:72-77.
12. Mariani PP, Liguori L, Cerullo G, Iannella G, Floris L. Arthroscopic patellar reinsertion of the MPFL in acute patellar dislocations. *Knee Surg Sports Traumatol Arthrosc.* 2011;19:628-633.
13. McCarthy M, Ridley TJ, Bollier M, Wolf B, Albright J, Amendola A. Femoral tunnel placement in medial patellofemoral ligament reconstruction. *Iowa Orthop J.* 2013;33:58-63.
14. Nikku R, Nietosvaara Y, Kallio PE, Aalto K, Michelsson JE. Operative versus closed treatment of primary dislocation of the patella. Similar 2-year results in 125 randomized patients. *Acta Orthop Scand.* 1997;68:419-423.
15. Palmu S, Kallio PE, Donell ST, Helenius I, Nietosvaara Y. Acute patellar dislocation in children and adolescents: a randomized clinical trial. *J Bone Joint Surg Am.* 2008;90:463-470.
16. Sanchis-Alfonso V. Guidelines for medial patellofemoral ligament reconstruction in chronic lateral patellar instability. *J Am Acad Orthop Surg.* 2014;22:175-182.
17. Schottle PB, Hensler D, Imhoff AB. Anatomical double-bundle MPFL reconstruction with an aperture fixation. *Knee Surg Sports Traumatol Arthrosc.* 2010;18:147-151.
18. Schottle PB, Schmeling A, Rosenstiel N, Weiler A. Radiographic landmarks for femoral tunnel placement in medial patellofemoral ligament reconstruction. *Am J Sports Med.* 2007;35:801-804.
19. Siebold R, Borbon CA. Arthroscopic extraarticular reconstruction of the medial patellofemoral ligament with gracilis tendon autograft—surgical technique. *Knee Surg Sports Traumatol Arthrosc.* 2012;20:1245-1251.
20. Siebold R, Chikale S, Sartory N, Hariri N, Feil S, Passler HH. Hamstring graft fixation in MPFL reconstruction at the patella using a transosseous suture technique. *Knee Surg Sports Traumatol Arthrosc.* 2010;18:1542-1544.
21. Smirk C, Morris H. The anatomy and reconstruction of the medial patellofemoral ligament. *Knee.* 2003;10:221-227.
22. Song SY, Kim IS, Chang HG, Shin JH, Kim HJ, Seo YJ. Anatomic medial patellofemoral ligament reconstruction using patellar suture anchor fixation for recurrent patellar instability. *Knee Surg Sports Traumatol Arthrosc.* 2014;22:2431-2437.
23. Steensen RN, Dopirak RM, McDonald WG 3rd. The anatomy and isometry of the medial patellofemoral ligament: implications for reconstruction. *Am J Sports Med.* 2004;32:1509-1513.
24. Steiner TM, Torga-Spak R, Teitge RA. Medial patellofemoral ligament reconstruction in patients with lateral patellar instability and trochlear dysplasia. *Am J Sports Med.* 2006;34:1254-1261.
25. Stephen JM, Kaider D, Lumpaopong P, Deehan DJ, Amis AA. The effect of femoral tunnel position and graft tension on patellar contact mechanics and kinematics after medial patellofemoral ligament reconstruction. *Am J Sports Med.* 2014;42:364-372.
26. Stephen JM, Lumpaopong P, Deehan DJ, Kader D, Amis AA. The medial patellofemoral ligament: location of femoral attachment and length change patterns resulting from anatomic and nonanatomic attachments. *Am J Sports Med.* 2012;40:1871-1879.
27. Tateishi T, Tsuchiya M, Motosugi N, et al. Graft length change and radiographic assessment of femoral drill hole position for medial patellofemoral ligament reconstruction. *Knee Surg Sports Traumatol Arthrosc.* 2011;19:400-407.
28. Thauinat M, Erasmus PJ. Management of overtight medial patellofemoral ligament reconstruction. *Knee Surg Sports Traumatol Arthrosc.* 2009;17:480-483.
29. Yoo YS, Chang HG, Seo YJ, et al. Changes in the length of the medial patellofemoral ligament: an in vivo analysis using 3-dimensional computed tomography. *Am J Sports Med.* 2012;40:2142-2148.