

Original Article

Twelve-month *in utero* safety assessment of gardenia blue, a natural food colorant

Robert R. Maronpot^{1*}, Michael Streicker², Debabrata Mahapatra², Rebecca Moore², Mihoko Koyanagi³, Shuichi Chiba³, Masayuki Nishino³, and Shim-mo Hayashi^{4,5}

¹ Maronpot Consulting, 1612 Medfield Road, Raleigh, North Carolina, 27607 USA

² Inotiv, PO Box 13501, Research Triangle Park, North Carolina, 27709 USA

³ San-Ei Gen F. F. I., Inc., 1-1-11 Sanwa-cho, Toyonaka, Osaka 561-8588, Japan

⁴ Tokyo University of Agriculture and Technology, 3-5-8 Saiwaicho, Fuchu-shi, Tokyo 183-8509, Japan

⁵ National Institute of Health Sciences, 3-25-26 Tonomachi, Kawasaki-ku, Kawasaki-shi, Kanagawa 210-9501, Japan

Abstract: Toxicity assessment of the food colorant *Gardenia jasminoides* Ellis at dietary exposures of 0.0%, 0.1%, 0.5%, 1.5%, 3.0% and 5.0% included measures of T-cell- dependent antibody response, neurotoxicity, and clinical and anatomic pathology in Sprague Dawley rats during mating, gestation, lactation, postnatal development, and following weaning for up to 12 months including 3- and 6-month interim evaluations. Blue coloration of the gastrointestinal tract, mesenteric lymph nodes and kidneys was present in treated rats only at necropsy with minimal blue coloration at the lowest dose and without histopathological correlates in any of the tissues. There was good survival with no consistent treatment-related changes in hematology, clinical chemistry, enhanced evaluation of lymphoid tissues, or tissue histopathology at interim and final time points. T-cell dependent antibody response and neurotoxicity screening were negative in treated rats. The no-observed-adverse-effect level (NOAEL) was determined to be 5.0% gardenia blue (2,854.5 and 3,465.4 mg/kg/day in parental males and females, respectively, prior to mating; 3,113.5 and 4,049.6 mg/kg/day in male and female offspring, respectively, following up to 12 months of exposure. (DOI: 10.1293/tox.2023-0030; J Toxicol Pathol 2023; 36: 171–179)

Key words: food additive, food colorant, gardenia blue, *in utero* exposure, safety assessment, developmental landmarks

Introduction

Gardenia blue is a colorant widely used in Asia for food use in frozen desserts, confections and baked goods, jams, noodles, beverages, wine and liqueurs, processed seafood and agricultural products. Gardenia blue is a dark purple to blue colorant prepared as a powder from the ripe fruit of *Gardenia jasminoides* Ellis, an evergreen shrub known for its distinctive white flowers. The *Gardenia* genus is widely distributed in warm to tropical regions and is cultivated for food colorant and medicinal purposes in Southern China, Taiwan, Philippines and Vietnam. Decoctions of gardenia fruit based on their content of geniposide and genipin have a long history of use in traditional oriental medicine for treat-

ment of inflammation, jaundice, headache, edema, fever, hepatic disorders, hypertension, conjunctivitis, skin ulcers, cancer, etc.^{1–3} as well as possessing pharmacological properties such as the inhibition of liver apoptosis, neuroprotective effects, and anti-inflammatory activity^{4–7}. The gardenia fruit contains 7–8% geniposide and trace amounts of genipin.

While some previously conducted genotoxicity and mammalian toxicity studies have shown lack of gardenia blue toxicity, original study data is not available, and the gardenia blue test material used in those early studies was not completely characterized. Contemporary GLP- and OECD-compliant genotoxicity studies, including the bacterial reverse mutation assay, *in vitro* chromosomal aberration assay, *in vitro* micronucleus assay, and *in vivo* micronucleus/comet assays indicate neither gardenia blue nor genipin pose a significant genotoxic concern for humans⁸. There are recent reports on liver toxicity of the *Gardenia jasminoides* fruit⁹ and possible hepatotoxic effects of genipin were observed in both *in vitro* and *in vivo* studies¹⁰. A conventional GLP-compliant two-year study of gardenia blue at dietary exposure levels of 0.5, 2.5 and 5.0% confirms a lack of treatment-related adverse effects¹¹.

The principal coloring component of gardenia blue is a high molecular weight polymer formed by polymerization of the aglycone from the gardenia fruit and peptides. It is

Received: 18 February 2023, Accepted: 22 March 2023

Published online in J-STAGE: 4 April 2023

*Corresponding author: R Maronpot

(e-mail: maronpot@gmail.com)

(Supplementary material: refer to PMC <https://www.ncbi.nlm.nih.gov/pmc/journals/1592/>)

©2023 The Japanese Society of Toxicologic Pathology

This is an open-access article distributed under the terms of the Creative Commons Attribution Non-Commercial No Derivatives

(by-nc-nd) License. (CC-BY-NC-ND 4.0: <https://creativecommons.org/licenses/by-nc-nd/4.0/>).



produced commercially by adding β -glucosidase to a mixture of iridoid glycosides extracted from the fruits of *Gardenia jasminoides* Ellis (*Gardenia augusta* Merrill) to yield genipin, the aglycone of geniposide. The structural unit of the gardenia blue polymer is comprised of two genipin moieties containing peptide side chains crosslinked via an alkene chain (Fig. 1). Gardenia blue polymer has a mean molecular weight range of approximately 15,000 to 30,000 daltons.

Gardenia blue is currently permitted in food in several Asian countries including China, Taiwan, Korea, and has had over 30 years of use in Japan. Contemporary interest in replacing artificial food colorants with naturally derived colorants prompted conduct of safety assessment studies prior to planned global marketing of gardenia blue as a food colorant. The present safety assessment study examines the effects of 12-month dietary exposures to gardenia blue colorant in Sprague Dawley rats commencing with *in-utero* exposure.

Materials and Methods

Regulatory compliance

This study was conducted in Integrated Laboratory Systems (ILS) (Research Triangle Park, NC, USA), in accordance with U.S. Food and Drug Administration Good Laboratory Practice Regulations 21 CFR Part 58¹². Study design followed FDA guidelines for chronic toxicity studies beginning with *in utero* exposure¹³ using 5 dietary dose levels as well as Good Laboratory Practice regulations¹⁴, and all applicable ILS standard operating procedures (SOPs).

Test article

Gardenia blue powder (Lot Number 150501; San-Ei Gen F.F. I., Inc, Osaka, Japan) was prepared according to specifications outlined in the 8th edition of the Japanese Specifications and Standards for Food Additives (<http://www.ffcr.or.jp/zaidan/FFCRHOME.nsf/pages/spec.stand.fa>; http://www.mhlw.go.jp/seisakunitsuite/bunya/kenkou_iryuu/shokuhin/syokuten/kouteisho8e.html), consisted primarily of 24.7% gardenia blue color, 69.4% maltodextrin and 4.6% water, and represents the actual commercial dietary component. Diet was analyzed for gardenia blue by UV-Vis spectroscopy for each batch of prepared diet. Genipin was not detected in the test diet. Geniposide levels were 6 ppm or less.

Animal husbandry

Animals were housed in polycarbonate cages with micro-isolator tops and absorbent heat-treated hardwood bedding (Northeastern Products Corp., Warrensburg, NY, USA) with weekly cage changing. Basal diet was Purina Certified 5002 meal diet (Ralston Purina Co., St. Louis, MO, USA) and reverse osmosis-treated tap water (City of Durham, NC, USA) were provided *ad libitum* with weekly water bottle changes. Environmental temperature, humidity and lighting were in compliance with USDA Animal Care

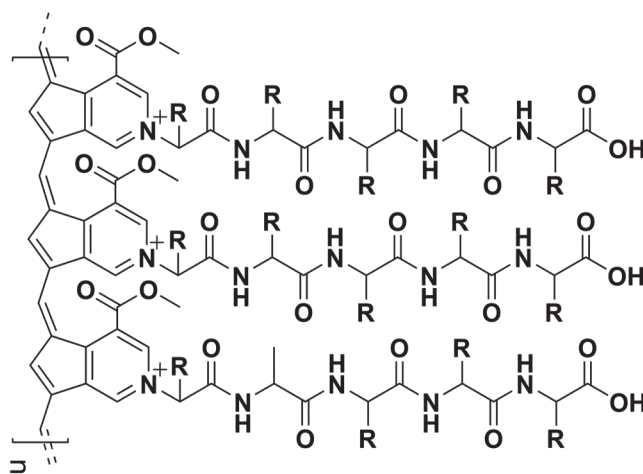


Fig. 1. Chemical structure of gardenia blue.

Animal Welfare Act and Animal Welfare Regulations, U.S. Department of Agriculture¹⁴, and animals were handled and treated according to the Guide for the Care and Use of Laboratory Animals¹⁵.

Study design

Dose levels selected for this study were based on lack of adverse effects in a 90-day gardenia blue study *in utero* exposures¹⁶. The frequency and timing of *in-life* and terminal measurements and observations are identified in Fig. 2 and Table 1. Following a 7-day acclimation period, cohorts of 50 male and 50 female Hsd:Sprague Dawley[®] rats (Envigo, Frederick, MD, USA) designated as parentals (P0) were allocated to each of six designated dose groups and exposed to gardenia blue at dose levels of 0.0%, 0.1%, 0.5%, 1.5%, 3.0%, and 5.0% in the feed for ten and four weeks, respectively, prior to mating. Guidance for a high dietary dose of 5% is considered appropriate for a non-nutritional test agent since a higher dietary percentage could potentially alter nutritional balance and cause compensatory overeating^{17–19}. Mating occurred at a 1:1 male:female ratio and was confirmed based on daily check for presence of vaginal plugs. Following delivery on post-natal day (PND) 4, litters were randomly culled to four male and four female pups with littermates of comparable body weights. Developmental markers were assessed on one male and one female per litter for all dose groups²⁰. F1 animals were exposed to gardenia blue in the feed at dose levels of 0.0%, 0.1%, 0.5%, 1.5%, 3.0%, and 5.0% during gestation and lactation through weaning. At weaning (~PND 21), randomly selected F1 animals continued exposure to the assigned diets of their parents and were allocated to Cohorts A through E for time periods indicated in Fig. 2. Due to an analytical error in the beginning phase of the study, 20% more gardenia blue was added to all F₁ cohort test diets beginning the first week of January 2019 after up to 8 weeks after initial dosing, resulting in approximate dose levels of 0.12%, 0.6%, 1.8%, 3.6%, and 6.0% for Groups 2–6, respectively, throughout the remainder of the

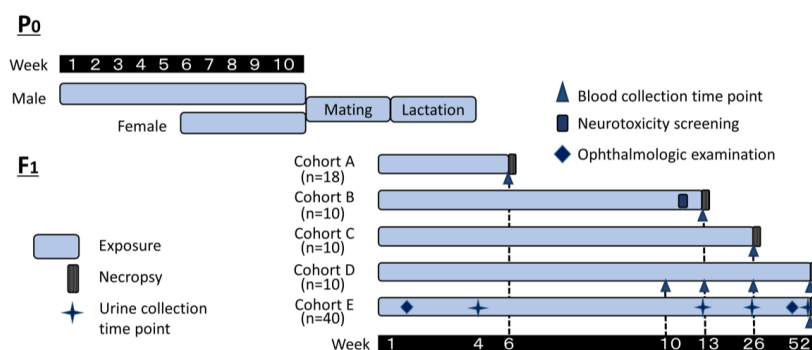


Fig. 2. Design of gardenia blue 12-month chronic study following *in utero* exposure phase. Sprague Dawley rats (300/sex/group) were allocated into 1 of 6 designated dose groups and administered at concentrations of Gardenia Blue at 0, 0.1, 0.5, 1.5, 3.0, or 5.0% in the diet to males and females for 10 and 4 weeks, respectively. Mating of P0 rats occurred at a 1:1 male:female ratio. On PND 4, F1 litters were randomly culled to 4 male and 4 female pups as possible. At weaning (~PND21), randomly selected F1 animals were allocated to Cohort A, B, C, D, or E (18, 10, 10, 10, and 40 animals/sex /group, respectively) and provided the diets assigned to their parents. Cohort A animals were evaluated for repeated-dose immunotoxicity by analysis of T-cell-dependent antibody response (TDAR). Cohort B animals were subjected to neurotoxicity screening. Cohort C animals were euthanized following 26 weeks of exposure. Fasted clinical pathology parameters were evaluated for Cohort D animals following 10, 13, and 26 weeks of exposure; these animals were euthanized after 52 weeks of exposure. Cohort E animals were subjected to ophthalmological examinations within 2 weeks post-allocation and again prior to termination and 18-hour urine samples were analyzed after 4, 13, and 26 weeks of exposure; these animals were euthanized after 52 weeks of exposure.

Table 1. Frequency and Timing of In-life and Terminal Assessments

Parameter evaluated	Frequency
Clinical observations	Daily
Body weights P ₀	Weekly
Body weights F ₁	PND 1, 4, 7, 10, 14, 21 & then weekly
Food consumption	L:D 1, 4, 7, 10, 14, 21 & then weekly
Developmental landmarks	
Anogenital distance	Postnatal day 1
Pinna unfolding	Postnatal day 1
Eye opening	Postnatal day 10
Incisor eruption	Postnatal day 7
Ophthalmological evaluation	Within 2 weeks following allocation & 1 week prior to termination
Survival blood collection ^a	Cohort D 10, 13 & 26 weeks
Terminal blood collection	Cohorts B, C, D & E at termination
Urinalysis	Cohort E after 4, 13, & 26 weeks & prior to termination at 52 weeks
Immunotoxicity	Cohort A after 6 weeks of exposure
Neurotoxicity screening (motor activity 7 functional observation battery)	Cohort B after 11 weeks of exposure
Tissue histopathology ^b	Cohort A – lymphoid tissues from control & 5% groups Cohort B & C – all tissues from control and 5% plus gross lesions Cohort E – all tissues and gross lesions from all groups

^aClinical chemistry assays: alanine aminotransferase, albumin, alkaline phosphatase, bile acids (total), bilirubin (total), blood urea nitrogen, calcium, chloride, cholesterol (total), cholinesterase, creatinine, gamma glutamyl transpeptidase, globulin, glucose, glutamate dehydrogenase, 5' nucleotidase, phosphorus, potassium, protein (total), sodium, sorbitol dehydrogenase, triglyceride. ^bTissues preserved for histopathology & tissues weighed*: adrenals*, aorta, bone & bone marrow (femur & sternum), brain* (cerebrum, cerebellum, medulla & pons), uterus, epididymides*, esophagus, eyes (with Harderian gland), heart*, kidneys*, liver*, intestines (small & large including Peyer's patches), lungs (with main-stem bronchi), lymph nodes (mesenteric & mandibular), mammary glands, muscle (skeletal), nasal cavity, ovaries*, oviducts, pancreas, pituitary, prostate*, salivary glands, sciatic nerve, seminal vesicle, skin, spinal cord (cervical, thoracic, lumbar), spleen*, stomach, testes*, thymus*, thyroid/parathyroid(s)*, tongue, trachea, urinary bladder, uterus & cervix*, vagina, Zymbal's glands.

study. After weaning and group allocation of F1 offspring, P0 animals were humanely euthanized. Oral dietary administration of gardenia blue was consistent with the planned

used of gardenia blue as a food colorant. P0 animals and F1 animals culled on PND4 or not selected for allocation were euthanized by CO₂ asphyxiation followed by decapitation

or cervical dislocation. Terminal cardiac blood collections from Cohorts B, C, D & E were followed by CO₂ overdose euthanasia with confirmation by exsanguination.

Reproductive assessment including number of successful matings, number of delivered litters, and number of live pups was carried out according to published guidelines²¹ with subsequent assessment of developmental landmarks including anogenital distance, day of pinna detachment, day of eye opening, and day of incisor eruption²².

For hematological analysis, a complete blood count, including platelet and differential count, was performed. In addition, prothrombin time and activated partial thromboplastin time were determined. Clinical chemistry analytes are footnoted in Table 1. Blood collected from animals in Cohort A was evaluated following GLPs for T-cell dependent antibody response (TDAR) using a rat anti-sheep red blood cell (SRBC) IgM ELISA assay (Life Diagnostics, Inc.) conducted at Burleson Research Technologies, Inc. (Morrisville, NC) according to Lebec *et al*²³.

A complete gross necropsy was done on all animals in Cohorts B through E, including external surfaces, orifices, cranial, thoracic and abdominal cavities, carcass, all organs, and gross lesions. The following tissues were weighed at necropsy: adrenals (paired), brain, epididymides (paired), heart, kidneys (paired), liver, ovaries (paired), prostate, spleen, testes (paired), thymus, thyroid with parathyroid (paired), and uterus with cervix. Tissues footnoted in Table 1 and all lesions, along with the carcass, from animals in Cohorts B through E were fixed in 10% NBF and saved. Eyes and testes which were fixed in modified Davidson's fixative. Histopathological evaluation was completed for the following: Group A – selected lymphoid tissues from control and 5% groups; Groups B & C – all tissues from control and 5% groups plus all gross lesions; Cohort E – all tissues and gross lesions from all groups. Tissues from Cohort D were fixed but not examined. H&E-stained slides were evaluated by light microscopy and lesions were graded as to severity. Lymphoid tissues (spleen, thymus, lymph nodes, bone marrow, and gut associated lymphoid tissue) from Cohorts A, B, C and E were microscopically evaluated using an enhanced histopathology method^{24, 25}. An independent histopathology peer review was conducted for Cohorts B, C and E.

Statistical analysis

All data were analyzed for each sex independently using Statistical Analysis System version 9.2²⁶. For each preweaning F₁ developmental landmark endpoint, the average value for pups of the same sex in the same litter was used in the statistical analysis. Homogeneity of variance was analyzed using Levene's test following transformation for heterogeneous data. If data could not be transformed to be homogeneous, the data were evaluated using the non-parametric Dunn's test and dose-dependent changes were analyzed via the non-parametric 2-sided Jonckheere's trend test. Endpoints in the Functional Observational Battery (FOB) using interval scales were evaluated for homogeneity using Levene's test for homogeneity of variances while end-

points using graded counts, descriptive, or quantal scales were analyzed using the Kruskal–Wallis test, Dunn's test and Fisher's exact test. Data from the motor activity test, with repeated measurements within a session, were analyzed using an analysis of variance with repeated measures and Dunnett's test when appropriate.

Results

Dose formulation analysis

Test article consumption from study initiation in July 2018 beginning with P₀ exposure to approximately 31 December 2018 (Interval 1) was calculated using the protocol-specified dose level concentration of 0.0%, 0.1%, 0.5%, 1.5%, 3.0%, and 5.0%. Due to an analytical error following discovery that diet formulations were 20% lower than target concentrations, starting in January 2019 (Interval 2) diets were formulated with 20% higher gardenia blue concentrations until study termination in December 2019 resulting in actual dose levels of 0.0%, 0.12%, 0.60%, 1.80%, 3.60%, and 6.00% affecting F₁ animals. To avoid confusion in presenting results, dose levels are presented in the report tables using the protocol-specified nominal values (0.0%, 0.1%, 0.5%, 1.5%, 3.0%, and 5.0%).

Reproductive performance & litter size—P₀ adults and F₁ preweaning pups

Rare early deaths or moribundities in control and 0.1% and 3.0% P₀ groups were considered spontaneous and unrelated to test article administration. There were no deaths or moribundities in the 5% P₀ rats. There were no toxicologically or statistically significant effects on male or female P₀ body weights, food and test article consumption, reproductive performance (mating, fertility, duration of gestation, or the process of parturition), litter size, preweaning pup weights, or preweaning survival in gardenia blue-exposed animals compared to controls.

For F₁ preweaning developmental landmarks there were scattered non-dose-dependent statistically significant increases in mean anogenital distance in male rats but not females (Supplementary Table 1). Statistically significant earlier mean days of eye opening were measured for both male and female rats in the top (5%) dose group with corresponding positive trend tests. Given the inconsistent observations between sexes for anogenital distance, and the direction of the changes for day of eye opening, the toxicological relevance of these findings is uncertain.

F₁ adults—Cohort A (T-cell dependent antibody response)

All F₁ animals survived to scheduled termination and those animals exposed to 0.5% gardenia blue or greater had blue to black feces throughout the treatment period with a single occurrence in 1 male and 1 female in the 0.1% groups. There were no treatment-related effects on body weight, body weight gain or food and gardenia blue consumption in males or females. Gross findings at necropsy in protocol-

required tissues (spleen, thymus, mesenteric lymph node, mandibular lymph node, gut-associated lymphoid tissue, and bone marrow) were blue discoloration of mesenteric lymph nodes in a few treated rats at 0.5% and higher doses of gardenia blue and blue discoloration of the small intestine in most treated rats.

There were no treatment-related effects on F1 Cohort A spleen and thymus weights. No statistically significant histopathological lesions were observed in high dose groups or controls. There were no statistically related treatment effects on anti-sheep red blood cell-IgM production in male or female or in combined sexes following exposure to gardenia blue (Supplementary Tables 2 and 3).

F₁ adults—Cohorts B through E

Study parameter endpoints and results for Cohorts B (13-week termination), C (26-week termination), D (10-, 13- and 16-week interval & 52-week termination) and E (52-week termination) are highlighted in Table 2. Because of lower food consumption in Interval 2, there was lower gardenia blue exposure in all treated groups despite the 20% greater levels of gardenia blue that had been added to the test diets. Aside from blue to dark coloration of intestines, mesenteric lymph nodes and kidney in animals receiving gardenia blue at 0.5% and above, there were no abnormal findings at necropsy. It is noted that there was only rare blue coloration of tissue in the 0.1% male and female groups.

Cohort B—histopathology

All protocol-required tissues from the control (0.0%) and high (5.0%) dose animals plus gross lesions in other groups were examined microscopically. A relative liver weight increase in the 3% and 5% females at 90 days (Cohort B) was without any correlating clinical chemistry or histopathological change in liver. Inflammatory and necrotic microscopic changes in the nose in several males and females occurred sporadically with similar incidences in control and high dose animals. A variety of incidental background microscopic changes with similar incidences in control and high dose animals or sporadically across groups included chronic progressive nephropathy, mixed cell infiltrate in the liver, cardiomyopathy, pulmonary alveolar histiocytosis, accessory capsule nodules and focal cortical adrenal hypertrophy, and lymphocytic infiltrates in the prostate and epididymis.

Cohort B—neurotoxicity screening and neurobehavioral evaluation

Following at least 11 weeks of dietary gardenia blue exposure there was no significant dose by time interaction effects on spontaneous motor activity for male or female rats nor clinical or functional changes in the appearance and behavior of animals other than blue-stained fur in higher exposure groups. Thyroid hormone levels were normal at this study interval as were liver and thyroid weights (Supplementary Table 4). There were no histopathological treatment related effect in the high dose versus the controls. Based on these results, administration of gardenia blue at dietary levels of 5.0% does not present a neurotoxicity haz-

ard as outlined in OECD rodent neurotoxicity guidelines²⁷.
F₁ Adults—Cohorts C & D—histopathology

Microscopic changes present in the nose with similar incidences in control and high dose animals or sporadically across groups were considered incidental findings unrelated to treatment. These changes were observed primarily in levels I and II and included chronic active inflammation of the respiratory and transitional epithelium, minimal to mild necrosis primarily in the dorsal meatus of the olfactory epithelium, and respiratory epithelium hyperplasia. Other microscopic changes occurring with similar incidences in control and high dose animals or sporadically across groups included expected background lesions such as chronic progressive nephropathy, mixed inflammatory cell infiltrates in the liver, cardiomyopathy, cystic uterine endometrial hyperplasia and squamous metaplasia, pulmonary alveolar histiocytosis, accessory capsular nodules and focal adrenal cortical hypertrophy.

Cohort E—ophthalmology examination

Expected common ophthalmological changes including corneal crystals and cataracts and were seen within two weeks of initial allocation to study groups. At one week prior to study termination ophthalmological abnormalities included mild keratitis, corneal crystals, mild cataracts, and mild blepharitis randomly occurring in control and high dose rats. Corneal crystals and mild cataracts are common spontaneous findings in Sprague Dawley rats. Blepharitis and keratitis are most commonly secondary to environmental irritation. Therefore, the observed ocular abnormalities in Group 6 animals at these examinations were not test article related.

Cohort E—histopathology

A variety of neoplasms commonly found in aged rats²⁸ were observed in various tissues and are considered spontaneous and unrelated to test article administration. These neoplasms included: mammary fibroadenomas, mammary adenocarcinomas, pituitary pars distalis adenomas, pheochromocytomas, adrenal cortical adenomas, hepatocellular adenomas, cholangiomas, histiocytic sarcomas, uterine stromal polyps, thymic lymphomas, follicular cell adenoma of the thyroid gland, and squamous cell carcinomas. Among them, mammary fibroadenomas were most prevalent followed by pituitary pars distalis adenomas in females.

Non-neoplastic lesions unassociated with test article administration included a range of spontaneous hyperplastic, hypertrophic, degenerative, infiltrative, and inflammatory lesions that either occurred with similar incidences in control and treated animals or sporadically across all groups. These included, but were not limited to, chronic progressive nephropathy of the kidney, cardiomyopathy, cystic endometrial hyperplasia of the uterus, thyroid gland C-cell hyperplasia and follicular cysts, polyarteritis nodosa in multiple organs, adrenal gland cortical and medullary hyperplasia, inflammation of the nasal cavity, and pituitary hypertrophy and pars distalis hyperplasia. Additionally, incidences of cysts (in the thymus, thyroid gland, pituitary gland, mammary gland, kidney, and ovary), mineraliza-

Table 2. Study Parameters/end Points and Results

	Cohort B	Cohort C	Cohort D	Cohort E
Study parameter	13-wk termination	26-wk termination	Clinical pathology (Survival at 10, 13 & 26 wks) and termination at 52 wks.	52-wk termination
Mortality/Moribundity	No mortality or morbidity	No mortality or morbidity except 3 males in 3% group.	Minor sporadic moribundity in 5 rats in control or lower doses without dose response	Minor mortality/morbidity without dose response in all dose groups
Clinical observations	Dark blue feces in 0.5% and higher dose groups plus 1 rat in 0.1% group.	Dark blue feces in 0.5% and higher dose groups plus 2 male rats in 0.1% group.	Dark blue feces in 0.5% and higher male & female dose groups & occasionally single occurrences in 0.1% males & females.	Dark blue feces in 0.5% and higher male & female dose groups & in over half of 0.1% males & females
Body weights/Weigh gains	No treatment-related effects	No treatment-related effects	No treatment-related effects	No treatment-related effects
Food & test article consumption	No treatment-related effects on food consumption. Lower gardenia blue exposure in both sexes in Interval 2 due to decreased food consumption.	Higher trend in food consumption in females in Interval 1*. Lower gardenia blue exposure in Interval 2* in both sexes due to decreased food consumption.	No treatment-related effects. Lower gardenia blue exposure in Interval 2* due to decreased food consumption except for increase in 0.1% males.	No treatment-related effects. Interval 2* consumption lower than Interval 1* for all groups.
Gross pathology	Blue coloration of GI tract, mesenteric LN and kidneys in 0.5% and higher dose groups	Blue coloration of GI tract, mesenteric LN and kidneys in 0.5% and higher dose groups. Blue coloration of stomach in 1 0.1% male.	Blue coloration of GI tract, mesenteric LN and kidneys in 0.5% and higher dose groups & in one 0.1% female.	Dark or blue coloration of kidney, mesenteric LN and GI tract in 0.5% and higher with occasional exceptions in 01% groups.
Organ weights	No organ weight changes except relative liver weight increases in 3% & 5% females.	No organ weight changes except decreased prostate weight in 0.5 & 5% groups.	No organ weight changes except statistically increased male relative kidney, liver & spleen weights at 3% dose level.	Increase thyroid weights & positive linear trends for multiple dose groups except for 5% groups.
Clinical pathology				
Hematology	No treatment-related effects	No treatment-related effects except lower RBC, Hgb, Hct trends in females.	No consistent treatment-related effects at 10, 13, 26 or 52 wks.	No treatment-related effects at 4, 13, 26 or 52 wks
Clinical chemistry	No treatment-related effects. Increased total cholesterol and triglycerides in 5% males & females	No treatment-related effects.	Increased bile acids in 5% male & female rats at 10 & 13 weeks. Increased total cholesterol & triglyceride in 5% males at 52 wks	No reproducible treatment-related effects seen. Increased serum sodium in 5% females with positive trend at 13, 26 and 52 wks
Coagulation PT & APTT	No treatment-related effects	No treatment-related effects.	No treatment-related effects at 10, 13 & 52	No treatment-related effects at 52 wks.
T3, T4, TSH	No treatment-related effects.			
Urinalysis				Qualitative increase in urinary bilirubin in 5% males at 13, 26 and 52 wks.
Histopathology	No treatment-related effects in 0% and 5% groups. Nasal inflammation & necrosis same in 0% & 5% groups. Expected sporadic background lesions present. No liver changes to explain liver weight effects. Blue tissue coloration seen grossly not present.	No treatment-related effects in 0% and 5% groups. Nasal inflammation & necrosis same in 0% & 5% groups. Expected sporadic background lesions present. No bone marrow or spleen changes to explain erythroid trends in females. Blue tissue coloration seen grossly not present.	No treatment-related effects in 0 & 5% groups. Expected sporadic background lesions present. No tissue changes to explain bile acid, cholesterol or triglyceride clinical pathology changes. Blue tissue coloration seen grossly not present.	No treatment-related effects in treated groups versus controls. Expected sporadic background lesions present. Blue tissue coloration seen grossly not present.

1* Initial 8 weeks of gardenia blue dose levels were 0.0%, 0.1%, 0.5%, 1.5%, 3.0 % and 5.0%.

2* Gardenia blue dose levels from 9th week to study conclusion were 0.0%, 0.12%, 0.6%, 1.8%, 3.6% and 6.0%.

tion (in the brain, glandular stomach, kidney, pelvis, ovary, salivary gland and thyroid gland), erosion of forestomach epithelium, duct dilation in Zymbal's glands, and skin ulceration were documented. These findings are all considered incidental.

Discussion

The present study following FDA guidelines for a chronic study with *in utero* exposure was well conducted without significant early mortality and included a 3, 6, and

two 12-month toxicity cohorts, a T-cell-dependent antibody assay, measurement of reproductive performance, and assessment of preweaning clinical and developmental endpoints. Dose levels were adjusted in the last study interval months because of a technical error in dosed feed analysis resulting in higher dietary dose levels of gardenia blue. However, due to decreased food consumption in all groups during that final study interval, actual systemic exposures to gardenia blue were lower than in earlier months of exposure.

There was no evidence of treatment-related clinical or toxicity effects in parental rats which had good reproductive performance and comparable litter size among all the experimental groups. Statistically significant increases of preweaning anogenital distance (AGD) noted in F1 males were within published historical control data from Sprague Dawley males^{29,30}. Significant early eye opening was documented in male and female F1 pups in the 5.0% gardenia blue groups. Since there were no maternal food consumption or maternal body weight effects, and no pup body weight effects or other relevant postweaning effects in F1 pups, the recorded developmental changes in AGD and early eye opening do not indicate adverse effects.

Statistically significant increased absolute and relative thyroid/parathyroid organ weight changes with significant linear trends were present in Cohort E males and females at the 12-month study termination (increased weights at 0.1%, 1.5% and 3.0% for males and 1.5% and 3.0% for females) in the absence of a clear response at the 5.0% dose level. In the absence of thyroid weight effects in the other study cohorts (Supplementary Tables 5–7), including Cohort D with 12-month exposure to the same doses, the toxicological relevance of the statistical significance is uncertain. Thyroid T3, T4 and TSH levels measured in Cohort B were normal. Slightly higher sporadic incidences of thyroid cysts in males and diffuse C-cell hyperplasia in females versus controls in Cohort E may have influenced thyroid/parathyroid weight effects. It is noted that thyroid hormone assays for TSH, T3 and T4 conducted in Cohort B after 90-days of exposure were normal in all treated groups. Furthermore, in the initial range finding *in utero* 90-day study, decreased thyroid weights in males exposed to 3.0% gardenia blue and in females exposed to 5.0% gardenia blue were present³¹. Taken together, the thyroid/parathyroid weight changes present only in Cohort E do not reflect a clear or consistent toxicological response.

With respect to clinical pathology assessments, there were occasional but inconsistent statistically significant flags or trends in the different cohort sampling intervals. In the 90-day Cohort B rats, serum clinical chemistry analytes were not affected by gardenia blue exposures aside from an increase in total cholesterol of questionable toxicological significance in males. No treatment-related alterations in hematology, coagulation, or clinical chemistry aside from a decreased trend without a significant dose group response for hemoglobin, hematocrit and red blood cell counts were identified in Cohort C females. For Cohort D there were no

reproducible treatment-related changes in hematology, coagulation, or clinical chemistry following 10, 13, 26, and 52 weeks of exposure. While there were sporadic statistically flagged effects in hematology and clinical chemistry, the only noteworthy changes in Cohort E were a statistically significant increased serum sodium in 5.0% females and a qualitative increased urinary bilirubin noted in 5% males without an associated trend. In summary, the documented clinical pathology statistical effects or trends affecting various treatment groups and sampling intervals were not consistent across the different cohorts and do not represent adverse responses.

Against the background of expected age-associated histopathological changes, there were no remarkable or consistent histopathological changes, including enhanced histopathology of lymphoid system tissues, attributed to gardenia blue exposure based on sampling at multiple study timepoints. The blue or dark coloration of internal tissues seen at necropsies throughout this study were without any correlated microscopic tissue pigmentation or related histopathological finding. This coloration is attributed to gardenia blue powder ingested with the formulated diet. Although gardenia blue is considered an unabsorbable high molecular weight polymer, blue/dark coloration of the mesenteric lymph nodes and kidneys present at necropsy in the highest doses indicates some gardenia blue entered the systemic circulation via lymphatics with ultimate renal excretion. In a recently completed ADME study³² with radiolabeled gardenia blue, 89.2 and 96.5% of the radioactivity was recovered in feces after administration of 1,000 mg/kg to male and female rats, respectively. In urine, approximately 0.25 and 0.35% was recovered in male and female rats, respectively. Recovery of radioactivity in tissues and in carcass digest was low, with most tissues at or near background. The highest tissue recovery representing 0.01–0.03% of the administered dose was recovered in kidneys.

Gardenia Blue and Jagua Blue are blue colorants; the former is manufactured using genipin contained in Gardenia fruits (*Gardenia jasminoides*) and protein hydrolysates, while the latter is manufactured using genipin contained in Jagua fruits (*Genipa americana* L. *jaua*) and glycine. The principal component of both Gardenia Blue and Jagua Blue is a polymer created via oxidative polymerization of monomers having a pyridine structure formed by the reaction of genipin with the primary amine group of protein hydrolysate or glycine. Similar to the findings in the present gardenia blue study reported here, in a 12-month study of Jagua Blue with *in utero* exposure in rats, there was gross blue coloration of kidneys and gastrointestinal segments but no associated histopathological tissue changes³³.

The present dietary study of the natural food colorant gardenia blue was conducted in accordance with U.S. FDA study guidelines commencing with an *in utero* phase exposure¹³. Doses of gardenia blue in laboratory chow ranged from 0.1% to 5.0% with negative responses for assessment of developmental landmarks, neurotoxicity and neurobehavioral endpoints, and *in vivo* assay for T-cell-dependent anti-

body response. There were no treatment related pathological findings other than dark blue/black tissue coloration primarily of the gastrointestinal tract, mesenteric lymph nodes, and kidneys seen grossly but not detected microscopically in fixed tissues. Occasional statistically significant flagged endpoints in tissue weights and clinical pathology were not consistent across the 3-, 6- and 12-month study cohorts and were not supported by associated relevant histopathology. The no-observed-adverse-effect level (NOAEL) was determined to be 5.0% gardenia blue (2,854.5 and 3,465.4 mg/kg/day in P₀ males and females, respectively, prior to mating; 3,113.5 and 4,049.6 mg/kg/day [corrected for 20% overage] in F₁ Cohort E males and females, respectively, following up to 12 months of exposure).

Disclosure of Potential Conflicts of Interest: The study was conducted at Inotiv, Inc., Research Triangle Park, NC, USA and funded by San-Ei Gen F.F.I., Inc., Osaka, Japan. The authors declare that they have no known competing financial interests that could have appeared to influence the work reported in this paper.

Acknowledgment: This study was supported by the Ministry of Agriculture, Forestry and Fisheries of Japan under a project for promotion of gardenia blue to an export environment. Data from this study was requested by the U.S. Food and Drug Administration as part of a formal Color Additive Petition.

References

- Koo HJ, Song YS, Kim HJ, Lee YH, Hong SM, Kim SJ, Kim BC, Jin C, Lim CJ, and Park EH. Antiinflammatory effects of genipin, an active principle of gardenia. *Eur J Pharmacol.* **495**: 201–208. 2004. [Medline] [CrossRef]
- Suzuki Y, Kondo K, Ikeda Y, and Umemura K. Antithrombotic effect of geniposide and genipin in the mouse thrombosis model. *Planta Med.* **67**: 807–810. 2001. [Medline] [CrossRef]
- Tsai TR, Tseng TY, Chen CF, and Tsai TH. Identification and determination of geniposide contained in *Gardenia jasminoides* and in two preparations of mixed traditional Chinese medicines. *J Chromatogr A.* **961**: 83–88. 2002. [Medline] [CrossRef]
- Koo HJ, Lim KH, Jung HJ, and Park EH. Anti-inflammatory evaluation of gardenia extract, geniposide and genipin. *J Ethnopharmacol.* **103**: 496–500. 2006. [Medline] [CrossRef]
- Tanaka M, Yamazaki M, and Chiba K. Neuroprotective action of genipin on tunicamycin-induced cytotoxicity in neuro2a cells. *Biol Pharm Bull.* **32**: 1220–1223. 2009. [Medline] [CrossRef]
- Yamamoto M, Miura N, Ohtake N, Amagaya S, Ishige A, Sasaki H, Komatsu Y, Fukuda K, Ito T, and Terasawa K. Genipin, a metabolite derived from the herbal medicine Inchin-ko-to, and suppression of Fas-induced lethal liver apoptosis in mice. *Gastroenterology.* **118**: 380–389. 2000. [Medline] [CrossRef]
- Yamazaki M, Sakura N, Chiba K, and Mohri T. Prevention of the neurotoxicity of the amyloid beta protein by genipin. *Biol Pharm Bull.* **24**: 1454–1455. 2001. [Medline] [CrossRef]
- Hobbs CA, Koyanagi M, Swartz C, Davis J, Maronpot R, Recio L, and Hayashi SM. Genotoxicity evaluation of the naturally-derived food colorant, gardenia blue, and its precursor, genipin. *Food Chem Toxicol.* **118**: 695–708. 2018. [Medline] [CrossRef]
- Cui Y, Sun R, Wang Q, and Wang M. Hepatotoxicity induced by intragastrically administrated with Gardenia decoction in mice. *Nat Prod Res.* **31**: 2824–2827. 2017. [Medline] [CrossRef]
- Li Y, Pan H, Li X, Jiang N, Huang L, Lu Y, and Shi F. Role of intestinal microbiota-mediated genipin dialdehyde intermediate formation in geniposide-induced hepatotoxicity in rats. *Toxicol Appl Pharmacol.* **377**: 114624. 2019. [Medline] [CrossRef]
- Maronpot R, Ramot Y, Nyska A, Sproul C, Moore R, Koyanagi M, Chiba S, Nishino M, and Hayashi SM. Chronic toxicity and carcinogenicity study of dietary gardenia blue in Sprague Dawley rats. *Food Chem Toxicol.* **176**: 113734. 2023. [Medline] [CrossRef]
- U.S. Food and Drug Administration. Good laboratory practice regulations 21 CFR Part 58. Code of federal regulations title 21. 2022. <https://www.accessdata.fda.gov/scripts/cdrh/cfdocs/cfcfr/CFRSearch.cfm?CFRPart=58&showFR=1>.
- U.S. Food and Drug Administration. 2007. In-Utero Exposure Phase for Addition to Carcinogenicity Studies or Chronic Toxicity Studies with Rodents. Redbook 2000. Chapter IV.C.8., U.S. Food and Drug Administration. Washington, D.C.
- U.S. Department of Agriculture. Animal Care Animal Welfare Act and Animal Welfare Regulations. U.S. Department of Agriculture. Washington, D.C. 2017.
- National Research Council. Guide for the Care and Use of Laboratory Animals. National Academies Press. 2011.
- Streicker M. 12-Month In Utero Exposure Study of Gardenia Blue in Sprague Dawley Rats. Prepared by Integrated Laboratory Systems, Inc., 50082.0103: 993 pages. 2020.
- Knudsen I, and Poulsen M. Comparative safety testing of genetically modified foods in a 90-day rat feeding study design allowing the distinction between primary and secondary effects of the new genetic event. *Regul Toxicol Pharmacol.* **49**: 53–62. 2007. [Medline] [CrossRef]
- EFSA Scientific Committee. Guidance on conducting repeated-dose 90-day oral toxicity in rodents on whole food/feed. *EFSA J.* **9**: 2438. 2011. [CrossRef]
- OECD test No. 452. Chronic Toxicity Studies. OECD Guidelines for the Testing of Chemicals. OECD, Paris. 2018.
- International Council for Harmonisation. Guideline S5(R3). Detection of Reproductive and Developmental Toxicity for Human Pharmaceuticals. 2020.
- Redbook 2000. Toxicological Principles for the Safety Assessment of Food Ingredients. Chapter IV.C.9. Guidelines for Reproduction Studies. U.S. Food and Drug Administration. 2007.
- International Council for Harmonisation (ICH). Final Version ICH Harmonised Guideline S5(R3) Detection of Reproductive and Developmental Toxicities for Human Pharmaceuticals. Geneva, ICH. 2020.

23. Lebrech H, Molinier B, Boverhof D, Collinge M, Freebern W, Henson K, Mytych DT, Ochs HD, Wange R, Yang Y, Zhou L, Arrington J, Christin-Piché MS, and Shenton J. The T-cell-dependent antibody response assay in nonclinical studies of pharmaceuticals and chemicals: study design, data analysis, interpretation. *Regul Toxicol Pharmacol.* **69**: 7–21. 2014. [[Medline](#)] [[CrossRef](#)]
24. Elmore SA. Enhanced histopathology of the immune system: a review and update. *Toxicol Pathol.* **40**: 148–156. 2012. [[Medline](#)] [[CrossRef](#)]
25. Haley P, Perry R, Ennulat D, Frame S, Johnson C, Lapointe JM, Nyska A, Snyder P, Walker D, Walter G, STP Immunotoxicology Working Group. STP position paper: best practice guideline for the routine pathology evaluation of the immune system. *Toxicol Pathol.* **33**: 404–407, discussion 408. 2005. [[Medline](#)] [[CrossRef](#)]
26. SAS/STAT9 2 User's Guide. SAS Institute, Cary, SAS Institute 2008.
27. OECD test No. 424. Neurotoxicity in rodents. OECD Guidelines for the Testing of Chemicals. OECD, Paris. 1997.
28. Boorman G, and Suttie A. Boorman's Pathology of the Rat: Reference and Atlas, 2nd ed. Academic Press, London. 2018.
29. Carney EW, Zablony CL, Marty MS, Crissman JW, Anderson P, Woolhiser M, and Holsapple M. The effects of feed restriction during in utero and postnatal development in rats. *Toxicol Sci.* **82**: 237–249. 2004. [[Medline](#)] [[CrossRef](#)]
30. Marty MS, Allen B, Chapin RE, Cooper R, Daston GP, Flaws JA, Foster PM, Makris SL, Mylchreest E, Sandler D, and Tyl RW. Inter-laboratory control data for reproductive endpoints required in the OPPTS 870.3800/OECD 416 reproduction and fertility test. *Birth Defects Res B Dev Reprod Toxicol.* **86**: 470–489. 2009. [[Medline](#)] [[CrossRef](#)]
31. Davis JP. In Utero Exposure Range Finder and Subchronic Oral Toxicity Study of Gardenia Blue in Sprague Dawley Rats. Prepared by Integrated Laboratory Systems, Inc., 50082.0102: 46. 2017.
32. Fennell TR. Absorption, Distribution, Metabolism and Excretion Studies of [¹⁴C] Gardenia Blue in Male and Female Rats and Mice. RTI International, Research Triangle Park. 79. 2021.
33. Joint FAO/WHO Expert Committee on Food Additives. Safety Evaluation of Certain Food Additives: Prepared by the 89th Meeting of the Joint FAO/WHO Expert Committee on Food Additives. Geneva, World Health Organization and Food and Agriculture Organization of the United Nations. WHO Food Additives Series, No. 80: 29–44. 2022.