


Cite this article as: Wang Y, Cai Y, Wu Y. Successful thoracoscopic repair of traumatic diaphragmatic hernia in a child. *Interact CardioVasc Thorac Surg* 2022;34:703–5.

# Successful thoracoscopic repair of traumatic diaphragmatic hernia in a child

Yi Wang, Yuanxia Cai and Yeming Wu \*

Department of Pediatric Surgery, Xinhua Hospital Affiliated to Medicine School of Shanghai Jiaotong University, Shanghai, China

\* Corresponding author. Department of Pediatric Surgery, Xinhua Hospital Affiliated to Medicine School of Shanghai Jiaotong University, Shanghai, 200092, China. Tel: +86 13003178888; e-mail: wuyeming@xinhuamed.com.cn (Y, Wu).

Received 16 June 2021; received in revised form 6 September 2021; accepted 9 September 2021

## Abstract

Traumatic diaphragmatic hernia is very rare in children, and the diagnosis is often missed or delayed. Herein, we reported a 2-year-old boy who had suffered with traumatic diaphragmatic hernia due to a car crash. The child was manifested as tachypnoea without any other severe symptoms. The computed tomography scanning showed his right diaphragm was rupture. Soon, this patient was received a thoracoscopic repair surgery, and he was discharged 2 weeks later without any complication.

**Keywords:** Traumatic diaphragmatic hernia • Diagnosis • Treatment • Thoracoscopic surgery

## INTRODUCTION

Traumatic diaphragmatic hernia (TDH) is an uncommon and serious disease that usually results from blunt thoracic or abdominal injury. Current research suggests that TDH has a low incidence of 0.8–1.6% in patients with trauma, but that it has a high mortality rate ranging from 16.6% to 33.3% [1]. In this report, we present a paediatric case of TDH and share our experience with its clinical presentation, diagnosis and surgical treatment.

## CASE PRESENTATION

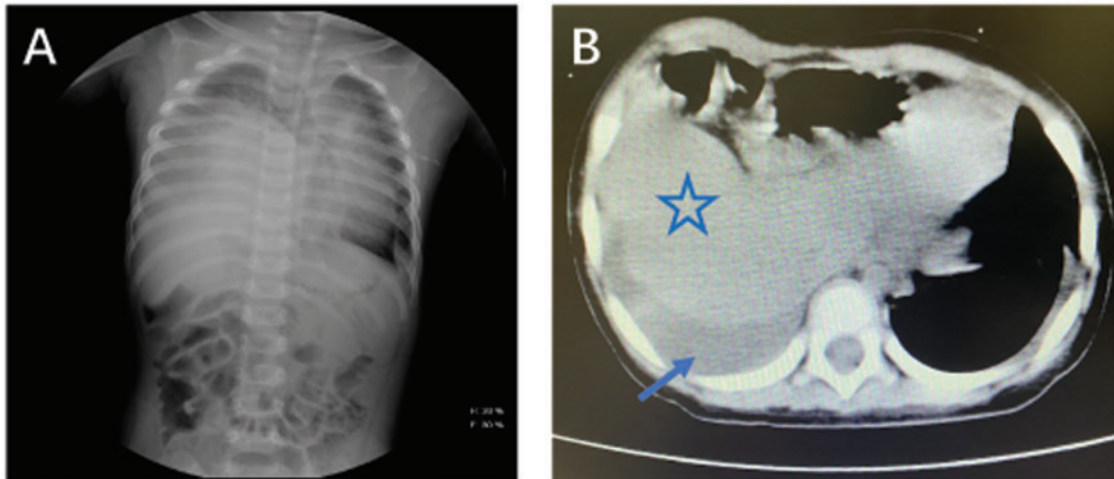
A 2-year-old boy was transferred to our medical centre for management of tachypnoea after a vehicle accident 1 day previously. The patient was conscious with a rapid respiratory rate. A careful physical examination revealed multiple skin contusions on the right side of his body, and respiratory sounds were diminished in the right lower thorax. Although he had undergone a general examination at a local clinic, the only abnormality found was elevation of the right diaphragm on chest radiography. When we reviewed his chest X-rays, we suspected that his right hemidiaphragm was injured; not only was the right diaphragm in a higher position but also an obvious mediastinal shift was present (Fig. 1A). Computed tomography confirmed TDH on the right side (Fig. 1B).

A thorough preoperative evaluation was performed. Based on his stable haemodynamics, we decided to perform an exploration through video-assisted thoracoscopic surgery.

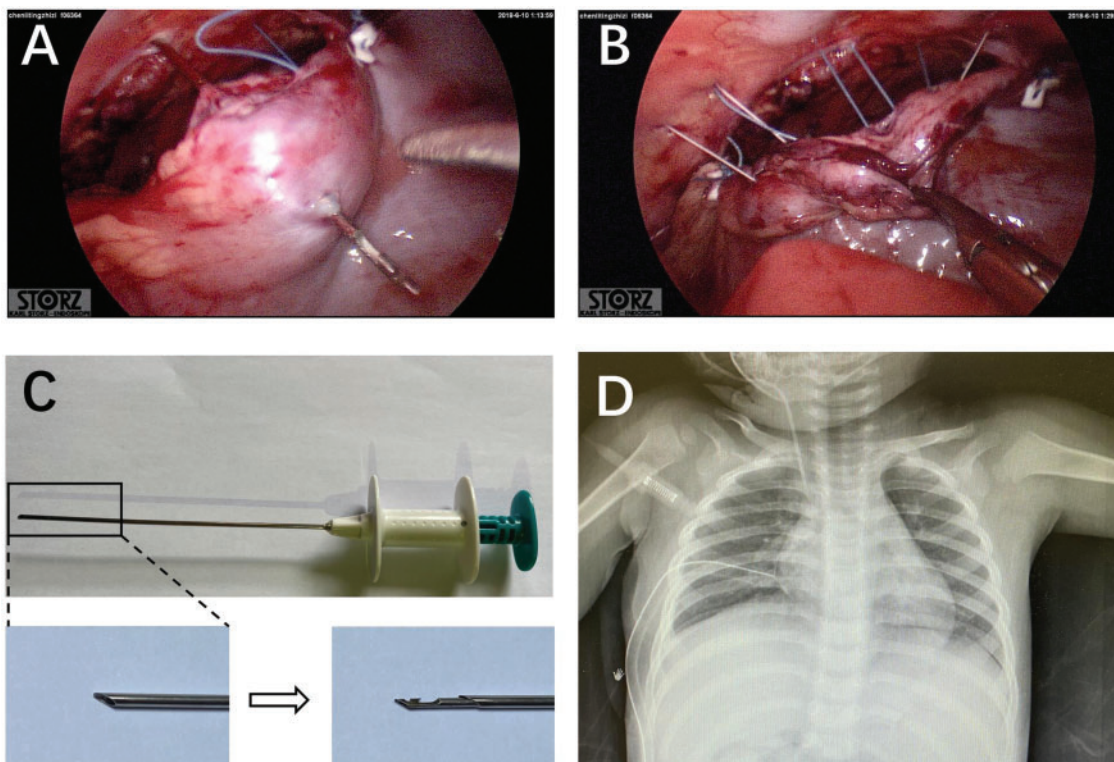
During the operation, we found a large anterolateral traumatic laceration with herniation of part of the liver. We then gently reduced the liver into the abdomen. However, when we started to repair the laceration, we found that it was too difficult to firmly fix the diaphragm to the chest wall. Therefore, we used a special paediatric inguinal hernia repairing needle to bring the suture line into the thorax, cross the edge of the diaphragm and pull the line out of the chest through the same micro-incision (Fig. 2A–C). Four single stitches were placed using this method, and the diaphragm was repaired successfully (Fig. 2D). The patient recovered uneventfully and was discharged 2 weeks after the operation.

## DISCUSSION

Making an accurate diagnosis of TDH in a timely manner is challenging because of its non-specific clinical presentation. Some patients report chest pain, upper abdominal pain, tachypnoea, breathlessness and vomiting. However, a few patients may be asymptomatic after trauma [1, 2]. In our case, the diagnosis of TDH was missed at the local hospital because of the patient's non-specific presentation. Based on his tachypnoea combined with diminished respiratory sounds and abnormal chest radiograph findings, we suspected a diaphragm injury, and a computed tomography scan was immediately arranged. Therefore, clinicians should obtain a detailed history and perform a careful physical examination. If TDH is suspected based on chest radiographs, a high-resolution multislice computed tomography scan is recommended.



**Figure 1:** (A) Chest X-ray showing an obviously elevated right diaphragm combined with air way and mediastinal shift. (B) Computed tomography scan showing that the right side of the chest was occupied by the herniating liver (star marked) and pleural effusion (arrow marked).



**Figure 2:** (A, B) After induction of general anaesthesia, 3 incisions were performed in the right posterior axillary line/fifth intercostal space (thoracoscope position), right anterior axillary line/third intercostal space (operation hole) and right inferior scapular line/fifth intercostal space (operation hole). Intraoperative examination revealed a complete laceration of the right diaphragm extending from the intact pericardial margin to the lateral margin. We used a special instrument (Crochet Hook<sup>®</sup>) for firming sutures. (C) Overall appearance and close-up of the special needle. A stretchable crochet hook is concealed in the needle head sheath. When the tail is pushed, the hook can move out of the sheath to bring the suture line. The tail is then relaxed, and the hook is returned to the sheath. (D) Postoperative chest X-ray showing that the right diaphragm had returned to its normal position.

Once the patient is diagnosed as TDH, operation should be performed early. Recently, thoracoscopic technique is more and more used in the management of TDH [3]. This approach bears the significant advantage of being minimally invasive and allows

visualization of herniated abdominal organs. In our case, video-assisted thoracoscopic surgery helps us to clearly evaluate the right hemi-diaphragm and liver. Finally, we successfully repaired the laceration with a special instrument.

## CONCLUSION

The preoperative diagnosis of TDH is difficult. In paediatric patients, clinicians should be particularly aware of any history of injury and any abnormal respiratory or gastrointestinal symptoms, perform a thorough physical examination and perform necessary imaging examinations. Once the diagnosis of TDH has been confirmed, immediate surgery is required. The thoracoscopic approach can be recommended for stable paediatric patients.

## Funding

This work was supported by a grant from the National Natural Science Foundation of China [NSFC No. 81802987].

**Conflict of interest:** none declared.

## Reviewer information

Interactive CardioVascular and Thoracic Surgery thanks Milton Saute and the other anonymous reviewer(s) for their contribution to the peer review process of this article.

## REFERENCES

- [1] Fangbiao Z, Chunhui Z, Chun Z, Hongcan S, Xiangyan Z, Shaosong T. Thoracotomy for traumatic diaphragmatic hernia. *Indian J Surg* 2016;78:371-4.
- [2] Al-Refaie RE, Awad E, Mokbel EM. Blunt traumatic diaphragmatic rupture: a retrospective observational study of 46 patients. *Interact CardioVasc Thorac Surg* 2009;9:45-9.
- [3] Ghionzoli M, Bongini M, Lo Piccolo R, Martin A, Persano G, Deaconu DE *et al.* Role of thoracoscopy in traumatic diaphragmatic hernia. *Pediatr Int* 2016;58:601-3.