

Evaluation of the surgical learning curve for I-125 episcleral plaque placement for the treatment of posterior uveal melanoma: a two decade review

Nisha V Shah¹
Samuel K Houston¹
Timothy G Murray^{1,2}
Arnold M Markoe²

¹Department of Ophthalmology,
Bascom Palmer Eye Institute,

²Department of Radiation Oncology,
University of Miami Miller School
of Medicine, Miami, FL, USA

Purpose: To evaluate the surgical learning curve in episcleral plaque brachytherapy placement in the management of posterior uveal melanoma.

Methods: A retrospective chart review of two cohorts of 250 consecutive patients undergoing plaque placement for posterior uveal melanoma from 2002 to 2004 and from 2008 to 2009 was conducted. The plaque–tumor apposition rates verified by intraoperative echography were evaluated and correlated with surgical volume over a 19-year period.

Results: In an initial study of 29 consecutive patients undergoing plaque placement from January 1992 to January 1995, a suboptimal plaque placement rate of 21% (n = 29) was identified. This percentage declined to 12% (n = 100) from January 2002 to January 2004, and further declined to 4% (n = 150) from June 2008 to August 2009. The tumor–plaque apposition rates for these three groups were 79% (1992–1995), 88% (2002–2004), and 96% (2008–2009). An estimated surgical volume of 1275 cases was performed to achieve a >90% precision rate for first application of primary plaque centration.

Conclusion: There are challenges to mastering the precise placement of radioactive plaques for posterior uveal melanoma. We have demonstrated a significant learning curve for plaque placement techniques, and have emphasized the importance of intraoperative ultrasound in the verification of plaque placement, thus allowing for intraoperative repositioning.

Keywords: intraoperative ultrasound, brachytherapy, ocular oncology

Introduction

Surgical proficiency and the statistical evaluation of the individual surgeon's learning curve have been of interest in multiple specialties, including orthopedic surgery, neurosurgery, otorhinolaryngology, and cardiovascular surgery, typically by utilizing quantifiable precision outcomes.^{1–4} The value of standardizing such outcomes, as measures of surgical competence to ultimately develop predictive models of surgical learning curves in training residents, has been addressed by authorities such as the Accreditation Council for Graduate Medical Education (ACGME) and the American Board of Ophthalmology.⁵ It is evident that surgeon experience improves outcomes and that volume of cases is one of the most important factors for establishing the length of the learning curve,^{1–4} or to determine “time to mastery”, which we defined as the predicted number of hours to attain >90% precision rates for first application of plaque placement. In ocular surgery, for instance, the number of cases required to achieve proficiency for phacoemulsification was found to be 75, while the number of scleral buckling operations found to achieve clinically stable results was 30.^{6,7} Numerous other studies have explored mastery of ocular surgical techniques, especially

Correspondence: Timothy Murray
Bascom Palmer Eye Institute,
900 NW 17th Street, Miami,
FL 33136, USA
Tel +1 305 326 6166
Fax +1 305 326 6417
Email tmurray@med.miami.edu

in phacoemulsification, micro-incisional surgery, primary vitrectomy, glaucoma surgery, and LASIK.^{8–14} Other fields have reported learning curves for accurate placement of prosthetic devices,¹⁵ and the contributory role of imaging to evaluate optimal device placement.^{16–18}

Tumors treated with iodine-125 (I-125) plaque brachytherapy require an accurate placement typically including a minimum of 2 mm border around the tumor.^{19,20} Techniques to facilitate accurate plaque placement include a modified fiberoptic light source combined with indirect ophthalmoscopy, and postoperative imaging studies with MRI or ultrasound.^{21–24} Currently, the most effective way to test for adequate plaque margins is intraoperative echography, used in conjunction with transillumination and indirect ophthalmoscopy.^{20,24,25} Using such imaging modalities helps overcome the challenges in tumor localization, especially for posterior and juxtapapillary tumors,²⁵ and allows the assessment and location of various structures lying close to the tumor, such as the optic nerve.²⁴ Intraoperative echography also allows for the determination of the degree of displacement and the direction of displacement during adjustment. Furthermore, the real time nature of intraoperative diagnosis allows for immediate repositioning of the plaque as needed.²⁵

This study tracks the reposition rates over a 19-year time span divided into three major periods or groups. Group 1 includes data published from Bascom Palmer Eye Institute (Miami, FL) in 1996 by Harbour et al²⁰ which included 29 consecutive patients with medium-sized posterior uveal melanoma undergoing I-125 plaque placement by a single surgeon. This study showed that 4/29 (14%) plaques did not cover at least one tumor margin and 2/29 (7%) were displaced away from the sclera due to the optic nerve or other structures. A total of 6/29 (21%) plaques required repositioning, achieving a precise first placement position rate of 79%. A larger series during this time period (1992–1998), also from our institution, looked at choroidal tumors of medium size, and demonstrated similar satisfactory tumor–plaque apposition rates of 76% ($n = 117$).²⁵ The current study addresses the learning curve (time to mastery) associated with I-125 plaque placement in the management of uveal melanoma as a measurable determinant of surgical proficiency.

Methods

The study protocol was approved by the Institutional Review Board of the University of Miami Miller School of Medicine. Clinical records including operative reports were reviewed on 250 patients undergoing plaque placement for posterior

uveal melanomas by one of the authors (TGM) at Bascom Palmer Eye Institute. Group 1 consisted of 29 consecutive patients starting January 1992, acquired from the study by Harbour et al.²⁰ Group 2 consisted of 100 consecutive patients between 2002 and 2004. Group 3 consisted of 150 consecutive patients between 2008 and 2009. All procedures were performed by one surgeon (TGM). The data recorded for each patient included patient demographics, tumor size, plaque size, date of plaque placement, plaque–tumor relationship as evaluated by intraoperative echography, need for plaque repositioning, last follow-up date, and presence of tumor recurrence or metastasis.

All patients presenting with posterior uveal melanoma underwent placement with I-125 radioactive plaque using standard surgical techniques.^{26,27} Briefly, after initial prepping, draping, and anesthesia, patients underwent 360 degree conjunctival peritomy. All four rectus muscles were isolated using 2-0 Ethibond (Ethicon Inc, Somerville, NJ) suture, and the globe was transilluminated to mark the tumor's location. If needed, one of the rectus muscles was disinserted in order to make room for plaque insertion. A standard Collaborative Ocular Melanoma Study plaque (a silastic implant including integrated I-125 seed grooves placed into a gold-backed shield) with I-125 plaque seeds designed to deliver 85 Gy to the tumor apex, was used in all cases. After the plaque was brought into the field, 5-0 nylon sutures were used to secure the plaque. The plaque position was assessed with intraoperative ultrasound by either the surgeon (TGM) or a registered diagnostic medical ultrasonographer using a contact B-scan instrument (Ophthascan S; Alcon Surgical Inc, Irvine, CA, or Innovative Imaging Inc, Sacramento, CA). Echographic studies were performed to view the tumor both longitudinally and transversely in order to verify plaque location relative to the intraocular tumor. If the plaque was found to be sub-optimally positioned, the nylon sutures were removed and using ultrasound guidance, the plaque was repositioned with placement of new nylon sutures through the sclera to secure the plaque. The position was then reconfirmed using intraoperative ultrasound. At the conclusion of the procedure, all plaques showed excellent positioning. If removed, the rectus muscle was reattached, and the conjunctiva was closed. The operated eye was patched and shielded with a lead shield, and the plaque was removed after an average of 3 days, 3 hours (range: 3–4 days).

Patients were examined at follow up visits every 3–6 months and yearly by medical oncology. Ophthalmology visits included a complete ophthalmic examination, echography, wide-field imaging and currently, spectral

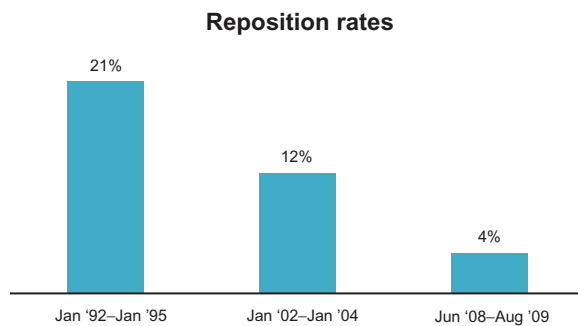


Figure 1 Reposition rates from 1992–1999.

Notes: Graph shows the declining trend ($P = 0.007$) of suboptimal plaque placement from January 1992 to August 2009 (17.6 years) performed by the same surgeon. Rates correlate to consecutive patients undergoing plaque placement for posterior uveal melanoma from January 1992 to January 1995 ($n = 29$), January 2002 to January 2004 ($n = 100$), and June 2008 to August 2009 ($n = 150$).

domain optical coherence tomography (SD-OCT). Tumor growth greater than 0.3 mm verified either echographically or clinically was considered indicative of tumor recurrence.

Results

Group 1 (January 1992) revealed a plaque suboptimal position rate of 21% ($n = 29$). This percentage declined to 12% ($n = 100$) from January 2002 to January 2004 (Group 2), and further declined to 4% ($n = 150$) from June 2008 to August 2009 (Group 3), (Figure 1).

Group 2 analysis in Table 1 shows that of plaques that were placed suboptimally, 25% (3/12) of plaques were displaced superiorly, 17% (2/12) were displaced inferiorly, 8% (1/12) anteriorly, 8% (1/12) nasally, 8% (1/12) postero-inferiorly, and 33% (4/12) were decentered in an unspecified direction. Eighty-three percent (10/12) of tumors were of

medium size (thickness 2.5–10 mm) and 17% (2/12) were large (thickness > 10 mm). Mean plaque size for Group 2 was 18.8 mm (range: 14–22 mm). In terms of tumor location, 33% (4/12) of tumors were macularly located, 8% (1/12) exclusively involved the ciliary body, 25% (3/12) involved both the ciliary body and the choroid, and 8% (1/12) were juxtapapillary. Average follow-up time after plaque placement was 53 months (range: 4–101 months) of which no patients were shown to have tumor recurrence or metastasis to other organs.

Group 3 (Table 2) tumor sizes were medium in 50% of cases and large in the other 50%. Ultrasound revealed that 50% (2/4) of plaques were originally decentered, 25% were displaced superiorly (1/4), and the other 25% (1/4) were displaced inferiorly. Twenty-five percent of tumors in Group 3 were macularly located, and 25% of cases were characterized as diffuse. Mean follow-up time for patients in Group 3 was 21.3 months (range: 20 days–36.6 months). For all Group 2 and Group 3 patients, time required for repositioning and evaluation ranged from 3 minutes to 15 minutes. At last follow up visit, none of the patients undergoing plaque repositioning displayed metastasis. All patients tolerated the procedure well without any complication.

From 1992 to 1995, precision rates of plaque placement were 79% ($n = 29$). After a mean time of 9.5 years, the precision rate increased to 88% ($n = 100$) which further increased to 96% ($n = 150$) after a mean time of 15.5 years. The positive trend of precision rates was found to be statistically significant ($P = 0.0007$) via Chi-squared analysis. Figure 2 summarizes the positive correlation between precision rates and cumulative surgical volume. Trend analysis for this 18-year period shows

Table 1 Group 2 patient characteristics – plaque reposition (12/100)

Patient	Age	Gender	Size	Location	Eye	Plaque displacement
1	42	M	Medium	Ciliochoroidal	OD	Nasal
2	76	F	Medium	Ciliochoroidal	OS	Superior
3	78	M	Medium	Macular w/basal extension	OD	Superior
4	92	F	Medium	Choroid	OS	Decentered
5	80	M	Medium	Choroid	OD	Postero-inferior
6	92	F	Large	Ciliochoroidal	OS	Decentered
7	83	M	Medium	Choroidal (amelanotic)	OD	Anterior
8	51	M	Medium	Macula	OS	Decentered
9	60	F	Large	Ciliary body	OD	Superior
10	72	F	Medium	Juxtapapillary	OD	Decentered
11	57	M	Medium	Macula	OD	Inferior
12	39	F	Medium	Macula with juxtapapillary component	OD	Inferior
Mean = 68						

Notes: Twelve patients required plaque repositioning from January 2002 to January 2004 (Group 2). Eighty-five percent of these tumors were medium-sized. On primary placement of plaque, ultrasound showed that 4/12 plaques were decentered, 3/12 plaques were displaced superiorly, 2/12 were displaced inferiorly, 1/12 anteriorly, 1/12 nasally, and 1/12 postero-inferiorly. Tumor sizes ranged from medium (10/12) to large (2/12). Mean plaque size was 18.8 mm (range: 14–20 mm). Average follow-up time after plaque placement was 53 months (range: 4–101 months) of which no patients were shown to have tumor recurrence or metastasis. Medium tumors 2.5–10 mm thickness; large tumors >10 mm thickness.

Table 2 Group 3 patient characteristics – plaque reposition (4/150)

Patient	Age	Gender	Size	Location	Eye	Plaque displacement
1	60	M	Large	Diffuse	OS	Decentered
2	42	F	Medium	Macula	OS	Inferior
3	54	M	Large	Not specified	OD	Decentered
4	66	M	Medium	Not specified	OS	Superior
Mean = 55.5						

Notes: Data from four patients that required plaque repositioning from June 2008 to August 2009 (Group 3). Tumor sizes were medium in 50% of cases and large in the other 50%. On primary placement of plaque, ultrasound showed that 2/4 plaques were suboptimally positioned, 1/4 plaques were displaced inferiorly, and 1/4 plaques were displaced superiorly. Mean plaque size was 19.75 mm (range: 16–22 mm). Average follow-up time after plaque placement was 21.25 months (range: 1–36 months) of which no patients were shown to have tumor recurrence or metastasis. Medium tumors: 2.5–10 mm thickness; large tumors > 10 mm thickness.

that >90% precision was achieved at approximately 1275 episcleral plaque surgical procedures.

Discussion

Precise plaque localization is critical to ensure that a malignant melanoma receives optimal radioactive dosage, which is calculated on the assumption of precise plaque–tumor alignment.²⁸ Correct plaque positioning ensures appropriate radiation delivery and improved local tumor control. The importance of local tumor control has been highlighted by findings that the risk of metastasis is higher for tumors that fail local treatment. Karlsson et al²⁹ showed that the risk of metastasis at 5 years following local tumor recurrence was 42% versus 18% without failure.^{29,30} In the current study, we show that there is a significant learning curve to the surgical placement of plaques in the treatment of choroidal melanoma.

With the higher risk of metastasis with failure of local tumor control, this learning curve should not be underestimated.

Over the course of two decades, apposition rates increased 21.5%; over 1200 cases were performed to achieve a >90% plaque precision rate. Given that the mean time for plaque procedure is 30 minutes, 1275 procedures corresponds to time to mastery with >90% precision at 637.5 hours. Hence, acquiring surgical techniques for optimal plaque placement can be challenging. Overall, this evolution in the learning curve illustrates the challenges of mastering precise placement of radioactive plaques for posterior uveal melanoma. It also suggests that the addition of ultrasonography for plaque placement verification is a critical and beneficial tool.²⁴

The majority of the tumors in this study with suboptimal plaque positions were posteriorly located. In addition to tumor location, ocular structures such as the optic nerve,

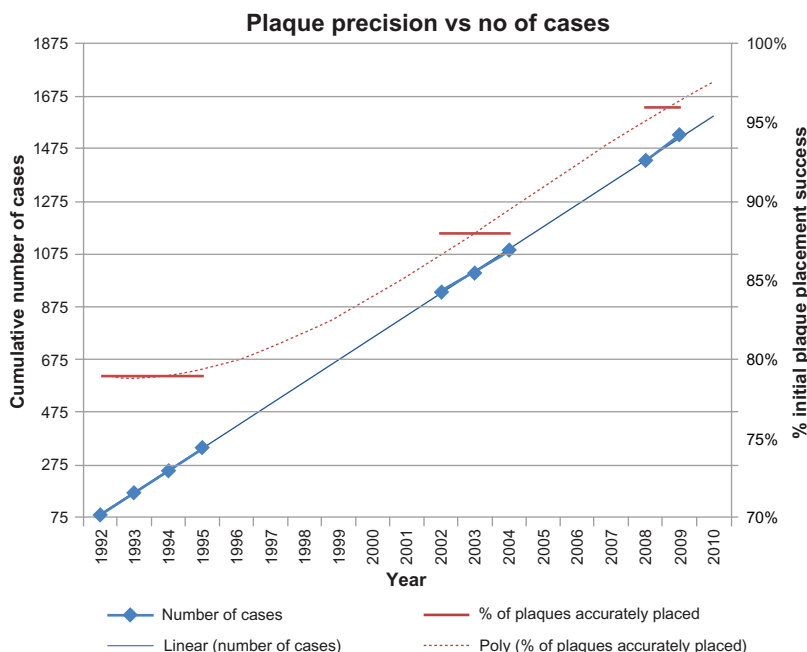


Figure 2 Cumulative number of plaque cases and precision trend.

Notes: Graph shows the trend in the cumulative number of cases involving plaque placement over a 19-year period. Mean number of cases in study window was 85 cases/year. The linear trend is matched with the precision percentage in initial plaque placement, indicating that plaque precision rates increase as surgical volume increases.

inferior oblique muscle, and posterior ciliary vessels and nerves can provide a challenge for plaque placement^{20,24,25,31} and may even lead to subsequent plaque tilting.³² Overall, intraoperative ultrasonography at plaque insertion will help verify both tumor location and plaque placement.³² Factors not affecting the apposition rates in our study include patient age, gender, and eye undergoing surgery. Juxtapapillary tumors also present a challenge in treatment, with notched plaques aiding in appropriate plaque placement. Future studies on apposition rates of notched plaques are warranted.

Limitations of this study include a small sample size and single surgeon, however the values between the three groups were found to be statistically significant ($P = 0.0007$).

In conclusion, the current study emphasizes significant learning curve associated with episcleral plaque radiotherapy treatment. With an increased risk of metastasis following failure of local tumor control, use of intraoperative ultrasound should be encouraged to ensure adequate plaque placement.

Disclosure

The authors report no conflicts of interest in this work.

References

- Snyderman C, Fernandez-Miranda J, Gardner PA. Training in neurotology: The impact of case volume on the learning curve. *Otolaryngol Clin North Am.* 2011;44(5):1223–1228.
- Sairaku A, Nakano Y, Oda N, et al. Learning curve for ablation of atrial fibrillation in medium-volume centers. *J Cardiol.* 2011;57(3):263–268.
- Starling ES, Reis LO, Vaz Juliano R, et al. Extraperitoneal endoscopic radical prostatectomy: How steep is the learning curve? Overheads on the personal evolution technique in 5-years experience. *Actas Urol Esp.* 2010;34(7):598–602. Spanish.
- Samdani AF, Ranade A, Sciubba DM, et al. Accuracy of free-hand placement of thoracic pedicle screws in adolescent idiopathic scoliosis: how much of a difference does surgeon experience make? *Eur Spine J.* 2010;19(1):91–95.
- Mills RP, Mannis MJ; American Board of Ophthalmology Program Directors' Task Force on Competencies. Report of the American Board of Ophthalmology task force on the competencies. *Ophthalmology.* 2004;111(7):1267–1268.
- Taravella MJ, Davidson R, Erlanger M, Guiton G, Gregory D. Characterizing the learning curve in phacoemulsification. *J Cataract Refract Surg.* 2011;37(6):1069–1075.
- Sagong M, Chang W. Learning curve of the scleral buckling operation: lessons from the first 97 cases. *Ophthalmologica.* 2010;224(1):22–29.
- Haustermans A. bimanual phacoemulsification: results of first 100 cases. Program and abstracts from the American Society of Cataract and Refractive Surgery (ASCRS) 2005 Symposium on Cataract, IOL and Refractive Surgery. April 15–20, 2005; Washington, DC.
- Roh S. Microphacoemulsification Technique: Learning-curve analysis using the Infiniti Visual System. Program and abstracts from the American Society of Cataract and Refractive Surgery 2005 Symposium on Cataract, IOL, and Refractive Surgery. April 15–20, 2005; Washington, DC.
- Martin KR, Burton RL. The phacoemulsification learning curve: per-operative complications in the first 3000 cases of an experienced surgeon. *Eye (Lond).* 2000;14(Pt 2):190–195.
- Thomas R, Navin S, Parikh R. Learning micro incision surgery without the learning curve. *Indian J Ophthalmol.* 2008;56(2):135–137.
- Dugas B, Lafontaine PO, Guillaubey A, et al. The learning curve for primary vitrectomy without scleral buckling for pseudophakic retinal detachment. *Graefes Arch Clin Exp Ophthalmol.* 2009;247(3):319–324.
- Olali CA, Ahmed S, Gupta M. Surgical outcome following breach rhexis. *Eur J Ophthalmol.* 2007;17(4):565–570.
- Gopal L, Sharma T, Shanmugam M, et al. Surgery for stage 5 retinopathy of prematurity: the learning curve and evolving technique. *Indian J Ophthalmol.* 2000;48(2):101–106.
- Thorey F, Klages P, Lerch M, Flörkemeier T, Windhagen H, von Lewinski G. Cup positioning in primary total hip arthroplasty using an imageless navigation device: is there a learning curve? *Orthopedics.* 2009;32(Suppl 10):14–17.
- Worthington P, Rubenstein J, Hatcher DC. The role of cone-beam computed tomography in the planning and placement of implants. *J Am Dent Assoc.* 2010;141(Suppl 3):19S–24S.
- Cunningham JP, Yu BM, Gilja V, Ryu SI, Shenoy KV. Toward optimal target placement for neural prosthetic devices. *J Neurophysiol.* 2008;100(6):3445–3457.
- Merli M, Bernardelli F, Esposito M. Computer-guided flapless placement of immediately loaded dental implants in the edentulous maxilla: a pilot prospective case series. *Eur J Oral Implantol.* 2008;1(1):61–69.
- Garretson BR, Robertson DM, Earle JD. Choroidal melanoma treatment with iodine 125 brachytherapy. *Arch Ophthalmol.* 1987;105(10):1394–1397.
- Harbour JW, Murray TG, Byrne SF, et al. Intraoperative echographic localization of iodine 125 episcleral radioactive plaques for posterior uveal melanoma. *Retina.* 1996;16(2):129–134.
- Robertson DM, Fuller DG, Anderson RE. A technique for accurate placement of episcleral iodine-125 plaques. *Am J Ophthalmol.* 1987;103(1):63–65.
- Hanna SL, Lemmi MA, Langston JW, Fontanesi J, Brooks HL Jr, Gronemeyer S. Treatment of choroidal melanoma. *Radiology.* 1990;176(3):851–853.
- Williams DF, Mieler WF, Lewandowski M, Greenberg M. Echographic verification of radioactive plaque position in the treatment of melanomas. *Arch Ophthalmol.* 1988;106(11):1623–1624.
- Pavlin CJ, Japp B, Simpson ER, McGowan HD, Fitzpatrick PJ. Ultrasound determination of the relationship of radioactive plaques to the base of choroidal melanomas. *Ophthalmology.* 1989;96(4):538–542.
- Tabandeh H, Chaudhry NA, Murray TG, et al. Intraoperative echographic localization of iodine-125 episcleral plaque for brachytherapy of choroidal melanoma. *Am J Ophthalmol.* 2000;129(2):199–204.
- Char DH. *Clinical Ocular Oncology.* 1st ed. New York: Churchill Livingstone; 1989.
- Shields JA, Shields CL, editors. *Intraocular Tumors.* Philadelphia, PA: WB Saunders; 1992.
- Jampol LM, Moy CS, Murray TG, et al; Collaborative Ocular Melanoma Study Group (COMS Group). The COMS randomized trial of iodine 125 brachytherapy for choroidal melanoma: IV. Local treatment failure and enucleation in the first 5 years after brachytherapy. COMS report no. 19. *Ophthalmology.* 2002;109(12):2197–2206.
- Karlsson UL, Augsburger JJ, Shields JA, Markoe AM, Brady LW, Woodleigh R. Recurrence of posterior uveal melanoma after 60Co episcleral plaque therapy. *Ophthalmology.* 1989;96(3):382–388.
- Vrabec TR, Augsburger JJ, Gamel JW, Brady LW, Hernandez C, Woodleigh R. Impact of local tumor relapse on patient survival after cobalt 60 plaque radiotherapy. *Ophthalmology.* 1991;98(6):984–988.
- Finger PT, Romero JM, Rosen RB, Iezzi R, Emery R, Berson A. Three-dimensional ultrasonography of choroidal melanoma: localization of radioactive eye plaques. *Arch Ophthalmol.* 1998;116(3):305–312.
- Almony A, Breit S, Zhao H, Garcia-Ramirez J, Mansur DB, Harbour JW. Tilting of radioactive plaques after initial accurate placement for treatment of uveal melanoma. *Arch Ophthalmol.* 2008;126(1):65–70.

Clinical Ophthalmology

Dovepress

Publish your work in this journal

Clinical Ophthalmology is an international, peer-reviewed journal covering all subspecialties within ophthalmology. Key topics include: Optometry; Visual science; Pharmacology and drug therapy in eye diseases; Basic Sciences; Primary and Secondary eye care; Patient Safety and Quality of Care Improvements. This journal is indexed on

Submit your manuscript here: <http://www.dovepress.com/clinical-ophthalmology-journal>

PubMed Central and CAS, and is the official journal of The Society of Clinical Ophthalmology (SCO). The manuscript management system is completely online and includes a very quick and fair peer-review system, which is all easy to use. Visit <http://www.dovepress.com/testimonials.php> to read real quotes from published authors.