



REVIEW

Recent advances in bronchoscopy [version 1; referees: 2 approved]

Elaine Dumoulin

Department of Medicine, University of Calgary, Calgary, Canada

v1 **First published:** 16 Oct 2018, 7(F1000 Faculty Rev):1646 (doi: 10.12688/f1000research.14596.1)
Latest published: 16 Oct 2018, 7(F1000 Faculty Rev):1646 (doi: 10.12688/f1000research.14596.1)

Abstract

Bronchoscopy is a very common tool for diagnosis and therapeutic purposes in dealing with diseases of the lungs and the airways. Thankfully, a multitude of new technologies have made it more accessible for the use of physicians. This article is a review of the indication of bronchoscopy as it is being used today for a variety of chest pathologies.

Keywords

Bronchoscopy, advancement, technology, interventional pulmonary medicine

Open Peer Review

Referee Status:

	Invited Referees	
	1	2
version 1 published 16 Oct 2018		

F1000 Faculty Reviews are commissioned from members of the prestigious F1000 Faculty. In order to make these reviews as comprehensive and accessible as possible, peer review takes place before publication; the referees are listed below, but their reports are not formally published.

- 1 **Erdoğan Çetinkaya**, Yedikule Chest Diseases and Thoracic Surgery Ed. & Research Hospital, Turkey
- 2 **John Abisheganaden**, Tan Tock Seng Hospital, Singapore

Discuss this article

Comments (0)

Corresponding author: Elaine Dumoulin (elaine.dumoulin@albertahealthservices.ca)

Author roles: Dumoulin E: Writing – Original Draft Preparation

Competing interests: No competing interests were disclosed.

Grant information: The author(s) declared that no grants were involved in supporting this work.

Copyright: © 2018 Dumoulin E. This is an open access article distributed under the terms of the [Creative Commons Attribution Licence](#), which permits unrestricted use, distribution, and reproduction in any medium, provided the original work is properly cited.

How to cite this article: Dumoulin E. **Recent advances in bronchoscopy [version 1; referees: 2 approved]** *F1000Research* 2018, 7(F1000 Faculty Rev):1646 (doi: [10.12688/f1000research.14596.1](https://doi.org/10.12688/f1000research.14596.1))

First published: 16 Oct 2018, 7(F1000 Faculty Rev):1646 (doi: [10.12688/f1000research.14596.1](https://doi.org/10.12688/f1000research.14596.1))

Bronchoscopy has come a long way. Designed at first as a rigid metal pipe to assist in foreign body removal, it has become a very common tool for diagnosis and therapeutic purposes when dealing with diseases of the lungs and the airways. With the option of a rigid (as pictured in [Figure 1](#)) or flexible bronchoscope and advancements in specific and precise tools, the science of bronchoscopy has evolved greatly. Tools include cold, heat, balloons, valves, and stents. Bronchoscopy is used in cancer, interstitial lung disease, vascular disease, foreign body removal, and chronic obstructive pulmonary disease management, to name just a few applications. This article is a review of the indication of bronchoscopy as it is being used today for a variety of chest pathologies.

The first indication for the use of bronchoscopy was foreign body removal. Gustav Killian used a metal pipe to remove a pork bone from a farmer's lung in 1897. This was done with

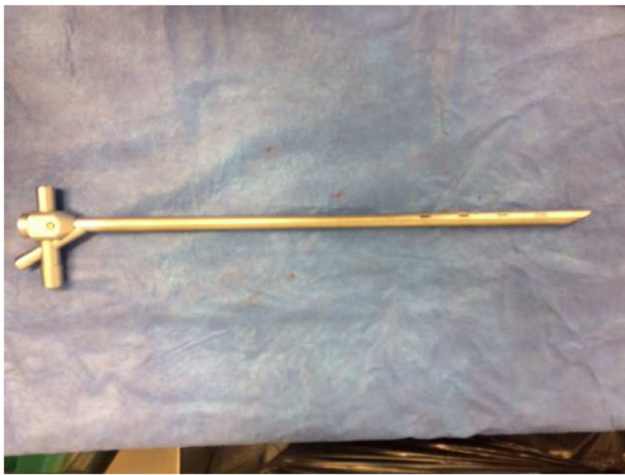

Figure 1. Rigid bronchoscope. This figure is an original image taken in ED's clinic for this publication.

topical cocaine as a local anesthetic. It was a great advancement at the time, as foreign body aspiration would likely cause infection and lead to death. With advancements in bronchoscopy, it is now possible to use a flexible bronchoscope to remove a foreign body.

A multitude of basket and devices can be used through the working channel of a flexible bronchoscope to assist with foreign body retrieval. [Figure 2](#) represents a Zero Tip grabbing an almond, commonly used type of basket.

For vegetable matter, the use of cryotherapy is a good option. Small, flexible cryoprobes are used through the working channel. The freezing probe is applied to the foreign body, which then is removed all at once with the bronchoscope¹. The use of a rigid bronchoscope remains indicated for any sharp or metal object at risk of causing bleeding or tearing the mucosa. The main difference between the procedure performed now and that performed in 1897 is that the former is done under general anesthesia in the operating room.

Another common indication of bronchoscopy is for the diagnosis and treatment of lung cancer.

When a flexible bronchoscope is combined with ultrasound technology, it is possible to perform lung cancer staging by gaining access to several lymph node stations in the mediastinum. It also increases the yield for sampling peripheral lung nodule². There are two different types of ultrasound: the linear probe and the radial probe. The linear probe is helpful for any central lesion; this includes hilar masses, mediastinal lesions, and lymph nodes. Ultrasound allows direct visualization of the lymph nodes as a transbronchial needle aspiration is performed ([Figure 3](#)).

The sample obtained allows diagnosis, staging, and molecular testing for advanced malignancy. This is used for lung cancer but also for metastatic cancer to the lungs from other primaries.



Figure 2. Zero Tip Airway Retrieval Basket (Boston Scientific, Marlborough, MA, USA). a. Zero Tip Basket b. Almond trapped in Zero Tip Basket c. Almond and Zero Tip Basket side by side. This figure is an original image taken in the author's clinic for this publication.

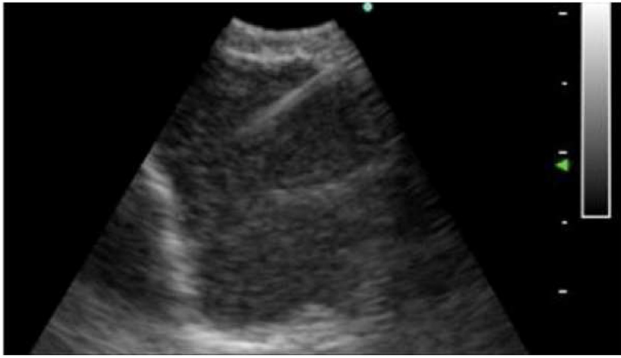


Figure 3. Lymph node sampled with a needle under ultrasound guidance. This figure is an original image taken in the author's clinic for this publication.

Sampling of the lymph nodes can be useful for other diseases such as sarcoidosis and lymphoma and infections such as tuberculosis.

The radial probe is used for peripheral lesions. The combination of a radial probe and a guide sheath allows sampling with biopsy forceps, a cytology brush, and a needle. It increases the diagnostic yield of bronchoscopy from 30 to 70% depending on the studies for peripheral lung nodules³. Not only does it improve the yield but it also has a lower risk of pneumothorax. Lung nodules can be malignant or benign, and obtaining a biopsy can help in determining the best management.

Electromagnetic navigation bronchoscopy (ENB) is another tool to aid in the diagnosis of peripheral lung nodules. The diagnostic yield of ENB varies, depending on the study and the expertise of the operator, from 33 to 96%⁴. It uses a real-time intrabody navigation system with electromagnetic fields and tracking sensors.

Both endobronchial ultrasound and ENB require a biopsy in order to obtain a diagnosis. A promising innovative technology called optical coherence tomography provides high-resolution imaging close to histology and might avoid the need for a biopsy in the future. This would reduce the risk of bleeding and pneumothorax.

For central endobronchial lesions, bronchoscopy can be used to restore the airway lumen. Multiple tools, including electrocautery, cryotherapy, laser, and mechanical debulking, have been described. Stents, either metal or silicone (Figure 4), are used to maintain patency once the airway is open. This technique enhances quality of life as a palliative measure in lung cancer⁵.

Some types of low-grade lung cancer, including carcinoid tumor, mucoepidermoid carcinoma (Figure 5), and adenoid cystic carcinoma, can be cured with the use of bronchoscopy, usually with the use of electrocautery or cryotherapy.

Some patients will present with massive hemoptysis. The etiology for massive hemoptysis can be diverse, including coagulopathies,

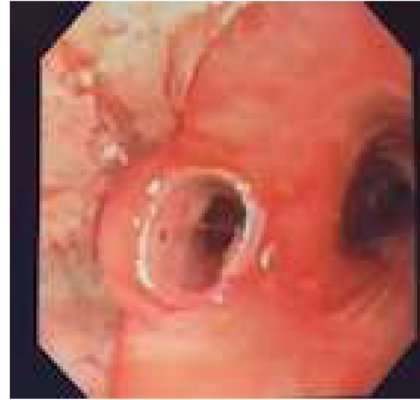


Figure 4. Silicone stent insertion with rigid bronchoscopy for left mainstem bronchus stenosis. This figure is an original image taken in the author's clinic for this publication.

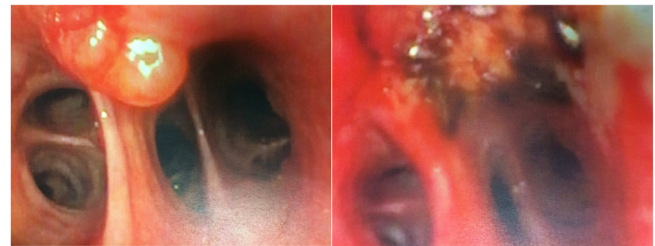

Figure 5. Before (left) and after (right) treatment of a mucoepidermoid carcinoma with electrocautery through flexible bronchoscopy. There was no recurrence at 5 years. This figure is an original image taken in the author's clinic for this publication.

vasculitis or other vascular diseases, lung cancer, bronchiectasis, and trauma. It is often a situation that can be stressful for both the patient and the pulmonologist. Bronchoscopy, most commonly rigid bronchoscopy, can be helpful to determine the location of the bleeding and can allow the protection of the airway. Patient ventilation can be maintained through the rigid bronchoscope while the bleeding is concealed. Often, it will not provide a permanent treatment, but it can temporize the bleeding and stabilize the patient until the definitive treatment is applied. Balloons and bronchial blockers are of great help in isolating the bleeding⁶.

In recent years, the role of bronchoscopy has become more common for the diagnosis of interstitial lung diseases. Cryobiopsies present an advantage over transbronchial biopsies to obtain larger samples. There is still some progress that needs to be made to standardize the procedure. It might not replace the standard of care that is open lung biopsy, but it appears to be a less intrusive, safer, and more accessible procedure⁷.

In the treatment of chronic obstructive pulmonary disease, bronchoscopy can use valves, coil implants, or thermal vapor ablation to mimic lung volume reduction surgeries. It seems to be safer than the surgical procedure, mostly for being less invasive

when patients are well selected. Patients with severe air trapping and thoracic hyperinflation seem to benefit the most from these procedures⁸.

Another advancement in bronchoscopy has been for the treatment of severe asthma. Bronchial thermoplasty appears to provide a decrease in asthma exacerbations, emergency department visits, and hospitalizations. The idea behind this procedure is to reduce the hyperactivity of the airway by affecting the smooth muscle layer with heat⁹.

Recently, a new treatment for aspergilloma was developed using bronchoscopy. In the presence of an access point to the cavity from an airway, endoscopic removal of the fungus ball (Figure 6) and cleaning of the lung cavity with the combination of a rigid and a flexible bronchoscope have been reported to improve patients' symptoms. This technique has been used for patients who, owing to medical comorbidities, are not candidates for surgery¹⁰.

Bronchoscopy has improved many lives. It offers a good combination of diagnostic and therapeutic options for a variety of lung diseases. It has led to the new medical field of interventional pulmonary medicine, in which training is oriented toward mastering all of the different bronchoscopic procedures. As the technology improves, there will be new tools and

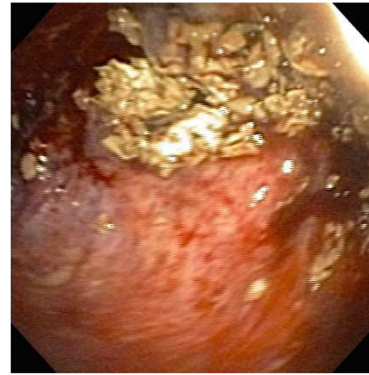

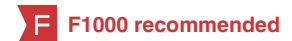Figure 6. Endoscopic view of an intracavitary aspergilloma. This figure is an original image taken in the author's clinic for this publication.

new challenges. Medicine is evolving toward less-invasive, higher-yield approaches with fewer complications, and bronchoscopy is a good example of that progress.

Grant information

The authors declare that no grants were involved in supporting this work

References



1. DiBardino DM, Lanfranco AR, Haas AR: **Bronchoscopic Cryotherapy. Clinical Applications of the Cryoprobe, Cryospray, and Cryoadhesion.** *Ann Am Thorac Soc.* 2016; **13**(8): 1405–15.
[PubMed Abstract](#) | [Publisher Full Text](#) | [F1000 Recommendation](#)
2. Liberman M, Sampalis J, Duranceau A, et al.: **Endosonographic mediastinal lymph node staging of lung cancer.** *Chest.* 2014; **146**(2): 389–97.
[PubMed Abstract](#) | [Publisher Full Text](#) | [F1000 Recommendation](#)
3. Ali MS, Trick W, Mba BI, et al.: **Radial endobronchial ultrasound for the diagnosis of peripheral pulmonary lesions: A systematic review and meta-analysis.** *Respirology.* 2017; **22**(3): 443–53.
[PubMed Abstract](#) | [Publisher Full Text](#) | [F1000 Recommendation](#)
4. Mehta AC, Hood KL, Schwarz Y, et al.: **The Evolutional History of Electromagnetic Navigation Bronchoscopy: State of the Art.** *Chest.* 2018; **154**(4): 935–947.
[PubMed Abstract](#) | [Publisher Full Text](#) | [F1000 Recommendation](#)
5. Mahmood K, Wahidi MM, Thomas S, et al.: **Therapeutic bronchoscopy improves spirometry, quality of life, and survival in central airway obstruction.** *Respiration.* 2015; **89**(5): 404–13.
[PubMed Abstract](#) | [Publisher Full Text](#) | [F1000 Recommendation](#)
6. Sakr L, Dutau H: **Massive hemoptysis: an update on the role of bronchoscopy in diagnosis and management.** *Respiration.* 2010; **80**(1): 38–58.
[PubMed Abstract](#) | [Publisher Full Text](#) | [F1000 Recommendation](#)
7. Hetzel J, Maldonado F, Ravaglia C, et al.: **Transbronchial Cryobiopsies for the Diagnosis of Diffuse Parenchymal Lung Diseases: Expert Statement from the Cryobiopsy Working Group on Safety and Utility and a Call for Standardization of the Procedure.** *Respiration.* 2018; **95**(3): 188–200.
[PubMed Abstract](#) | [Publisher Full Text](#) | [F1000 Recommendation](#)
8. Herth FJF, Slebos DJ, Criner GJ, et al.: **Endoscopic Lung Volume Reduction: An Expert Panel Recommendation - Update 2017.** *Respiration.* 2017; **94**(4): 380–8.
[PubMed Abstract](#) | [Publisher Full Text](#) | [F1000 Recommendation](#)
9. Kheir F, Majid A: **Bronchial Thermoplasty: A Nonpharmacologic Therapy for Severe Asthma.** *Clin Chest Med.* 2018; **39**(1): 261–9.
[PubMed Abstract](#) | [Publisher Full Text](#) | [F1000 Recommendation](#)
10. Stather DR, Tremblay A, Dumoulin E, et al.: **A Series of Transbronchial Removal of Intracavitary Pulmonary Aspergilloma.** *Ann Thorac Surg.* 2017; **103**(3): 945–50.
[PubMed Abstract](#) | [Publisher Full Text](#)

Open Peer Review

Current Referee Status:  

Editorial Note on the Review Process

F1000 Faculty Reviews are commissioned from members of the prestigious F1000 Faculty and are edited as a service to readers. In order to make these reviews as comprehensive and accessible as possible, the referees provide input before publication and only the final, revised version is published. The referees who approved the final version are listed with their names and affiliations but without their reports on earlier versions (any comments will already have been addressed in the published version).

The referees who approved this article are:

Version 1

- 1 **John Abisheganaden** Department of Respiratory and Critical Care Medicine, Tan Tock Seng Hospital, Singapore, Singapore
Competing Interests: No competing interests were disclosed.
- 2 **Erdoğan Çetinkaya** Department of Chest Diseases, Yedikule Chest Diseases and Thoracic Surgery Ed. & Research Hospital, Istanbul, Turkey
Competing Interests: No competing interests were disclosed.

The benefits of publishing with F1000Research:

- Your article is published within days, with no editorial bias
- You can publish traditional articles, null/negative results, case reports, data notes and more
- The peer review process is transparent and collaborative
- Your article is indexed in PubMed after passing peer review
- Dedicated customer support at every stage

For pre-submission enquiries, contact research@f1000.com

F1000Research