

# Arthroscopic Antegrade Cancellous Bone Autotransplantation for Osteochondral Lesions of the Tibial Plafond



Koji Hayashi, M.D., Ph.D., and Yasuhito Tanaka, M.D., Ph.D.

**Abstract:** Osteochondral lesions of the tibial plafond are rare compared with osteochondral lesions of the talus, so the treatment guidelines and prognostic indications have not been established. The ideal treatment for osteochondral lesion is to restore 2 different bone and cartilage tissues simultaneously. We introduce a technique of arthroscopic antegrade cancellous bone autotransplantation; fibrocartilage regeneration can be expected for the cartilaginous lesion while bony lesion is replaced with the normal bone using this technique.

Osteochondral lesions of the tibial plafond (OLTP) are rare disorder compared with osteochondral lesions of the talus (OLT), and its frequency is 2.6% of osteochondral lesions of the ankle.<sup>1</sup> Tibial plafond has the following anatomical characteristics that lead resistance to cartilage damage: tibial cartilage is stiffer and thicker than talar cartilage,<sup>2,3</sup> and there is a stable concave shape of the articular surface of the distal tibia. When left untreated, however, osteochondral lesions can further degrade and potentially lead to osteoarthritis, making repair of the lesion site necessary.<sup>4</sup>

On the other hand, treatment guidelines and prognostic indications have not been established for OLTP, unlike OLT, probably because of their infrequent occurrence. The occurrence frequency of each part of the OLTP is the highest in the medical center; the second is the medial posterior.<sup>5</sup> One cause of difficulty in

surgical treatment is that these sites are difficult to approach during surgery.

The ideal treatment for OLTP is to restore 2 different bone and cartilage tissues simultaneously, but this has not yet been achieved. In this report, we introduce a technique of arthroscopic antegrade cancellous bone autotransplantation as a solution for this issue.

## Surgical Technique

### Preoperative Planning and Patient Setup

Preoperative magnetic resonance imaging (MRI) is assessed to define the location and extent of the lesion (Fig 1). The patient is placed in a supine position under general or spinal anesthesia. The patient's lower leg is placed on a pillow, and the side plate is placed on the outer side of the thigh so that the anterior aspect of the patella and ankle face upward (Fig 2A). A tourniquet is placed around the thigh and inflated with a pressure of 250 mm Hg. A noninvasive ankle distractor (Arthrex ankle distraction strap) is attached to the ankle, and a band is wrapped around the waist; the joint space is then spread by applying the traction force through the strap (Fig 2B).

### Portal Placement

The anteromedial portal is created just medial to the tibialis anterior tendon at the joint line. The anterolateral portal is created just lateral to the peroneus tertius tendon. A blunt trocar (Stryker 3.2-mm Speed-Lock Cannula, J-Lock Obturator Blunt Chip) is introduced, and the arthroscope camera (Stryker 2.7-mm 30-Degree Ideal Eyes HD Arthroscope) follows.

From the Foot & Ankle Center, Otemae Hospital (K.H.), Osaka, Japan; and the Department of Orthopaedic Surgery, Nara Medical University (Y.T.), Nara, Japan.

The authors report that they have no conflicts of interest in the authorship and publication of this article. Full ICMJE author disclosure forms are available for this article online, as [supplementary material](#).

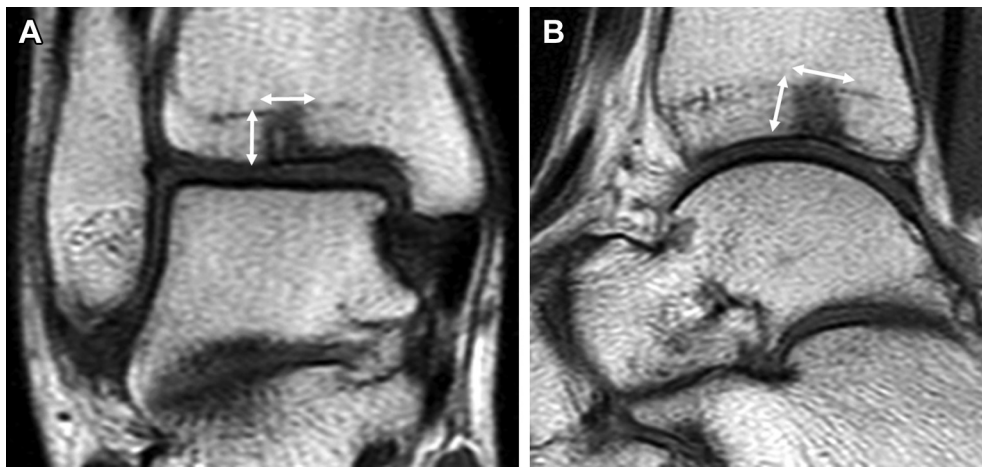
Received February 23, 2019; accepted April 1, 2019.

Address correspondence to Koji Hayashi, M.D., Ph.D., Foot & Ankle Center, Otemae Hospital, 1-5-34, Otemae, Chuo-ku, Osaka-shi, Osaka 540-0008, Japan. E-mail: [KojiSD@aol.com](mailto:KojiSD@aol.com)

© 2019 by the Arthroscopy Association of North America. Published by Elsevier. This is an open access article under the CC BY-NC-ND license (<http://creativecommons.org/licenses/by-nc-nd/4.0/>).

2212-6287/19245

<https://doi.org/10.1016/j.eats.2019.04.002>



**Fig 1.** Preoperative T1-weighted image of the right ankle. The preoperative identification of the lesion area is important for graft design. The low signal intensity on T1-weighted image indicates bone erosion, reflecting the extent of the lesion. (A) Coronal section: the width and the depth of the lesion is measured (white arrow). (B) Sagittal section: the anteroposterior diameter and the depth of the lesion is measured (white arrow).

Lactated Ringer's irrigation (Baxter Arthromatic) is used for reflux of the joint.

### Diagnostic Arthroscopy

A thorough evaluation of the joint is performed to see if there are associated pathologies, such as ligament injuries, impingement, or synovial hypertrophy (Fig 3A). Accompanying pathologies must be treated in the same surgery to prevent negative effects on healing. Synovial hypertrophy often needs to be removed using an arthroscopic shaver or radiofrequency device (Stryker 3.5-mm Small-Joint Full Radius Cutter, 2.5-mm Micro-Brush SERFAS Energy Small-Joint Probe). Evaluation of articular cartilage is done first visually to ascertain change of color tone and configuration of the articular surface. Subsequently, the degree of softening and the extent of the lesion are evaluated with a probe (Fig 3B; Video 1).

### Debridement

Several angled curettes are used to remove osteochondral lesions. Because the stiffness of both cartilage and subchondral bone is deteriorated, the boundary

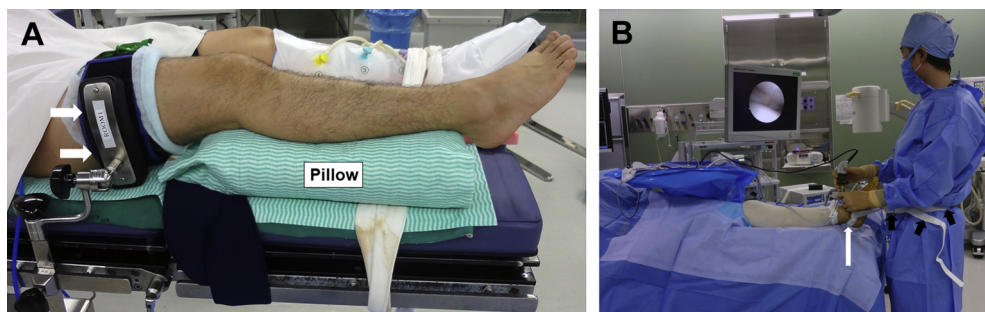
between the normal site and the lesion can be easily separated with curettes (Fig 4A; Video 1). The lesions are finally debrided by arthroscopic shaver to remove the remaining damaged cartilage and smoothen the surface of the subchondral bone (Fig 4B). After the debridement process, the whole surfaces are re-evaluated with a probe to ensure that they are stable without loose cartilage and necrotic subchondral bone tissue.

### Microfracture

Several angled microfracture picks (Smith & Nephew Small-Joint Microfracture Pick) are used to create several small holes onto the underlying intact subchondral bone. Holes are created 3-mm apart from each other and are perpendicular to the subchondral bone (Fig 5A; Video 1). After creating the final pick hole, fat droplets and sufficient bleeding are observed from the holes under released water pressure (Fig 5B; Video 1).

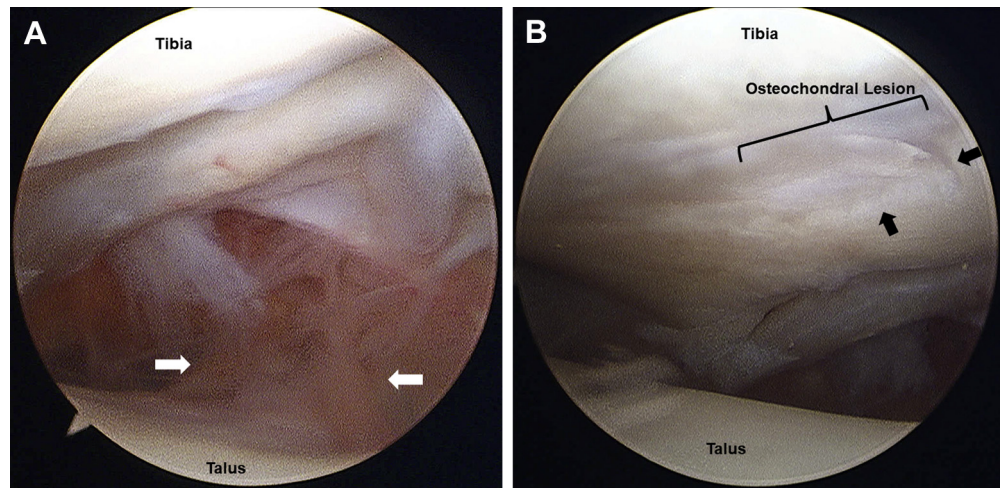
### Bone Harvest

An approximately 3-cm skin incision is made 3 cm above the anterior superior iliac spine along the iliac



**Fig 2.** The patient is in the supine position. (A) A pillow is placed under the right leg to allow ankle maneuvers, and the side plate (white arrow) is placed on the outer side of the thigh so that the patella and the anterior aspect of the ankle face upward. (B) A noninvasive ankle distractor (white arrow) is attached to the right ankle, and a band (black arrow) is wrapped around the waist, then the joint space is spread by applying the traction force through the strap.

**Fig 3.** With the patient supine and the arthroscope in the anteromedial portal of the right ankle, (A) the joint space between the tibia (superior) and talus (inferior) is appreciated with inflamed synovium (white arrow). (B) Fibrillation is observed on the surface of the lesion and a step is found at the boundary with the normal site (black arrow).



crest. The subcutaneous tissue is retracted laterally, and the periosteum is elevated subperiosteally with a periosteal elevator. Depending on the size of the lesion, a bone cylinder is extracted with 20-mm length and 6- to 10-mm diameter using the Osteochondral Autograft Transfer System (Arthrex) (Fig 6A). Once the desired amount of graft is harvested, the cortical bone piece is returned to its original site, and the wound is closed layer by layer (Fig 6B).

**Bone Preparation**

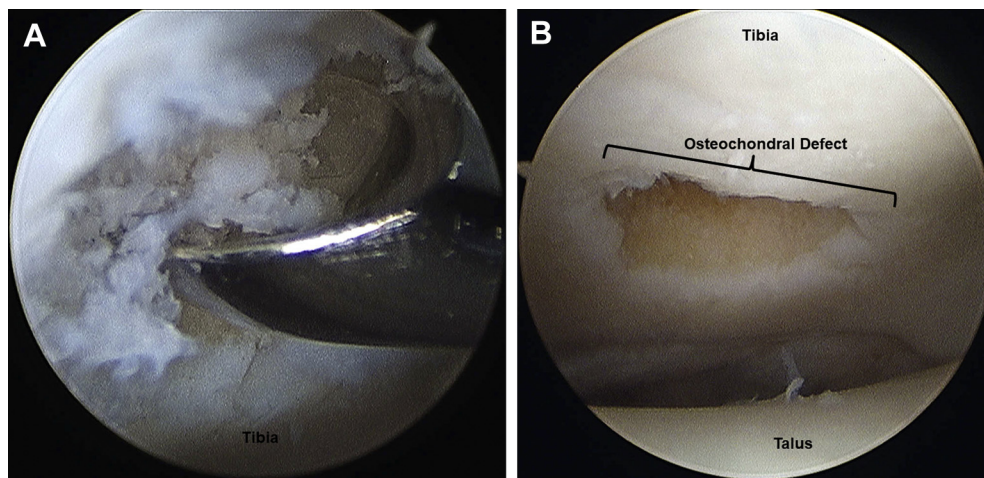
Only the cancellous element of the bone cylinder is trimmed according to the opening diameter of the lesion measured before surgery for superficial layer transplantation. Because the thickness of the graft needs to be smaller than the joint space, it is necessary to set it within 15 mm. The rest of the cancellous bone is fragmented with bone rongeur for deep layer transplantation (Fig 7).

**Bone Transplantation**

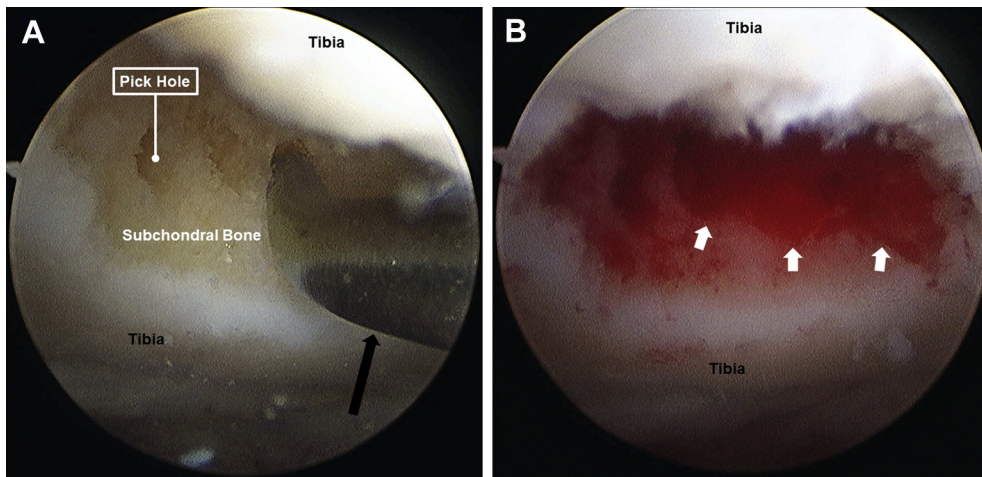
Small fragmented bones are gradually inserted into the deep layer of the osteochondral defect through a thick cannula (Stryker 5.0-mm Speed-Lock Cannula, Obturator Blunt Chip) in a state in which the reflux is stopped so that they are not scattered (Fig 8A). The reflux is resumed temporarily to secure a field of view. After stopping the reflux again, while holding the large bone block with grasping forceps, it is inserted into the joint and advanced to the aperture of the lesion (Fig 8B). The protruded part of the bone is further inserted until fitting the normal joint surface using an elevator (Figs 8C, 9, and 10; Video 1).

**Closure and Casting**

The skin is closed with superficial No. 4-0 nylon horizontal mattress sutures. Wounds are covered with dry sterile dressings, and a short-leg well-padded fiberglass cast in the neutral ankle position is applied to



**Fig 4.** With the patient supine and the arthroscope in the anterolateral portal of the right ankle, (A) a small curette is introduced through the anteromedial portal and used to remove the unstable cartilage and bone. (B) After the osteochondral lesion is completely debried, a large osteochondral defect is observed.



**Fig 5.** With the patient supine and the arthroscope in the anterolateral portal of the right ankle, (A) a microfracture pick (black arrow) is introduced through the anteromedial portal and used to create several small holes into the underlying intact subchondral bone. (B) The water pressure is released, and good bleeding is observed from the microfracture holes (white arrow).

restrict motion. The pearls/pitfalls of this technique are listed in [Table 1](#).

### Postoperative Course

The patient continues to non-weightbearing with a short-leg cast for 3 weeks. After 3 weeks, the cast is removed, and range of motion exercises and partial weight bearing are initiated gradually. Full weight-bearing is permitted after 6 weeks. The patient is allowed to start low-intensity sports activities at 3 months and high-intensity sports activities at 4 to 5 months.

### Discussion

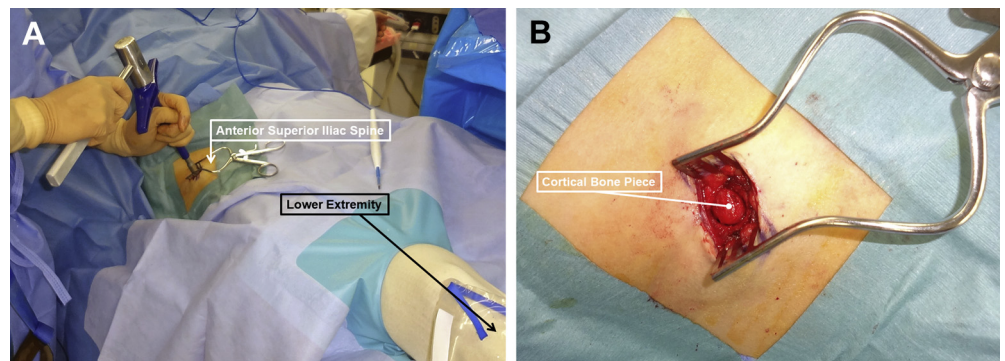
Surgical treatment of OLTP, including debridement, curettage, transmalleolar drilling, abrasion arthroplasty, and microfracture, have been reported, but most of the reports have low levels of evidence and express concern for the arthroscopic surgery because of difficulty in approaching to the lesion by open surgery. There are only 3 case series in which OLTP have been reported and only 2 series in which the outcomes of microfracture have been specifically reported.<sup>6,7</sup>

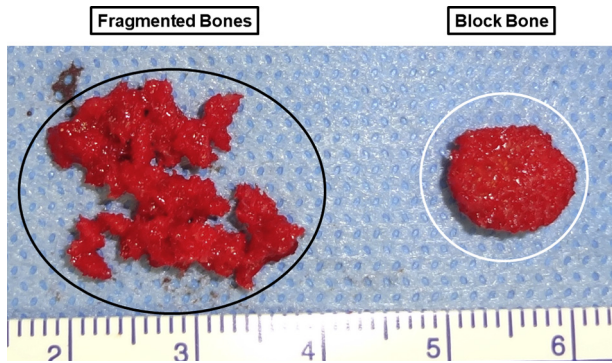
Microfracture is a first-line procedure for OLTP based on its facile technique and good clinical outcomes in OLT, but the repair tissue was inferior to normal hyaline cartilage, and both functional and MRI outcomes may deteriorate with increasing age. MRI outcomes also seem to deteriorate with increasing lesion area.<sup>7</sup>

The reports of new attempts are as follows: bone marrow–derived cell transplantation,<sup>8</sup> micronized allograft cartilage matrix transplantation,<sup>9</sup> and bone marrow aspirate concentrate combined with biologic scaffold transplantation.<sup>10</sup> These techniques have satisfactory clinical results but they are still under development because long-term and high-evidence studies are required.

Osteochondral lesions can be restored simultaneously to the normal bone and cartilage tissues only by osteochondral autotransplantation. There is a case report of retrograde osteochondral autotransplantation for OLTP<sup>11</sup>; however, this technique has not only a fundamental problem of the difference in the properties of cartilage between the donor and recipient sites, but also there are difficulties in approaching the posterior lesion and invasion to the normal site.

**Fig 6.** Iliac bone harvest from the right side. (A) Using the osteochondral autograft transfer system, a bone cylinder is extracted from 3 cm above the anterior superior iliac spine along the iliac crest of the affected side. (B) Cortical bone piece is returned to its original site because only the cancellous element of the bone is needed.

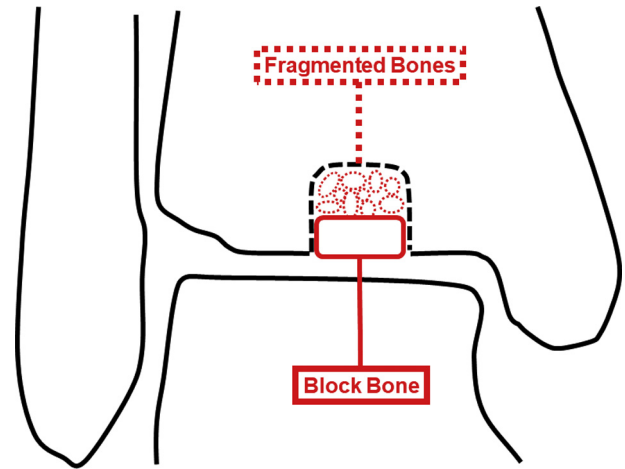




**Fig 7.** The harvested bone cylinder is formed in 2 ways. One is the block bone with the same opening diameter of the lesion for superficial layer transplantation (white circle), and the others are fragmented bones for deep layer transplantation (black circle).

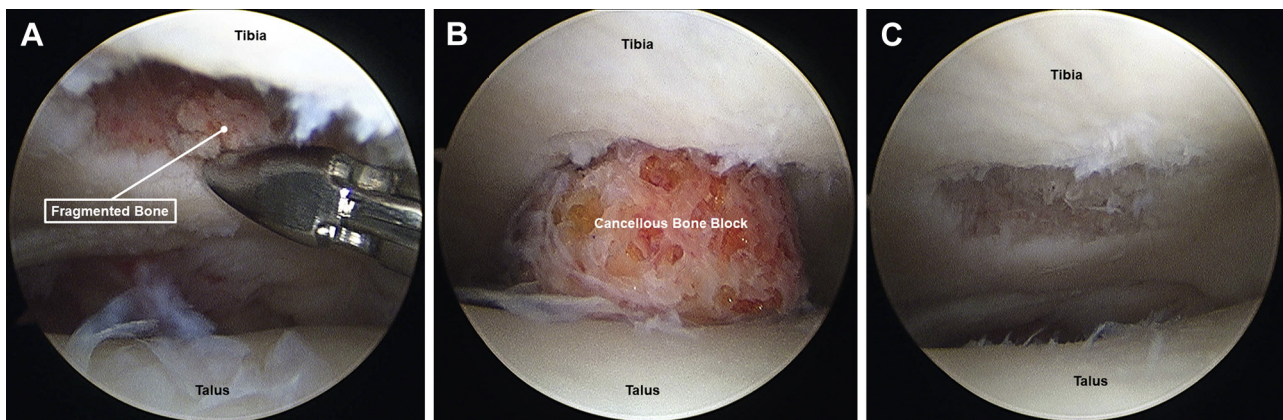
In terms of cancellous bone transplantation, which is an isolated repair of bone tissue, there are reports with regard to OLT; bone transplantation is better than curettage plus drilling in long-term clinical results,<sup>12</sup> bone transplantation alone is not recommended for the patient with advanced lesion with lack of overlying cartilage,<sup>13</sup> and platelet-rich plasma scaffold with bone transplantation may achieve acceptable short-term outcomes.<sup>14</sup> In a report of arthroscopic retrograde cancellous bone transplantation for an advanced lesion of OLTP, the cartilage defect was completely covered with cartilage-like tissue.<sup>15</sup> From the information provided here, cancellous bone transplantation is currently a controversial technique.

The ideal treatment for OLTP is to restore 2 different bone and cartilage tissues simultaneously, but this is not currently achievable. With this technique, fibrocartilage

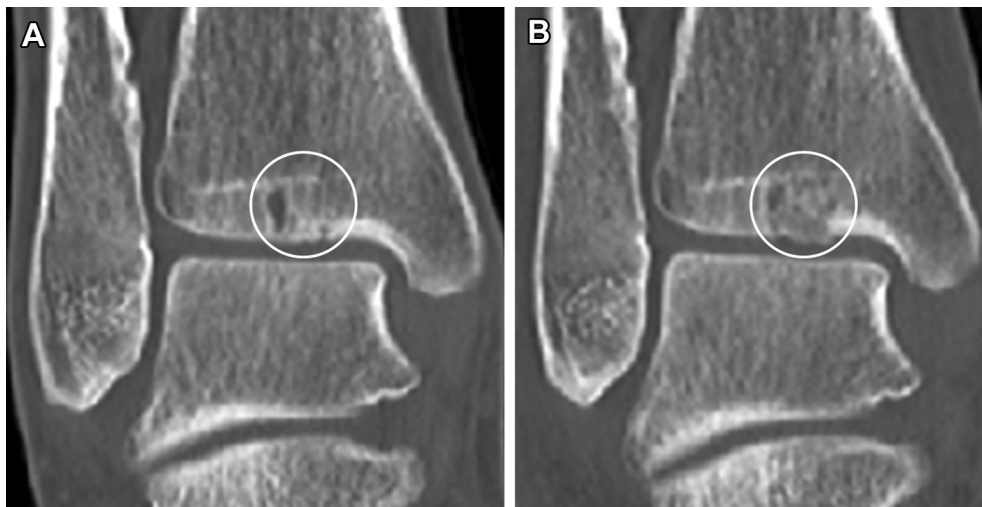

**Fig 9.** Sham of the surgical technique (right ankle). A large bone block cannot fill the deep layer of the lesion, so small fragments are used not to leave the defect. Deviation of the transplanted bone is prevented by filling the superficial layer of the lesion with a large bone block like a plug, but it is necessary to make the size of the bone fragment smaller than the joint space.

regeneration can be expected for cartilaginous lesion while bony lesion is replaced with the normal bone. The greatest advantage of this technique is that the osteochondral lesions can be restored simultaneously. Moreover, it is a useful technique because it completes the whole procedure arthroscopically without invasion of the normal site (Table 2). Finally, leakage of the fragmented bones into the joint during surgery and bone resorption of the transplanted bones in the post-operative course are risks of this technique, and there are limits in indication for the lesions larger than the joint space diameter.



**Fig 8.** Patient is supine and the arthroscope is in the anterolateral portal of the right ankle. (A) The deep layer of the osteochondral defect is filled with fragmented bones. The bones are introduced through the anteromedial portal close to the aperture of the defect using a thick cannula and are advanced as deep as possible with small grasping forceps. (B) The large bone block is introduced through the anteromedial portal with large grasping forceps and is fitted to the aperture. (C) The osteochondral defect is completely filled with bone, and the surface of the lesion corresponds to the normal joint surface.



**Fig 10.** Coronal images of the right ankle. (A) Preoperative: multiple bony cysts are recognized in the subchondral layer (white circle). (B) Postoperative: the subchondral layer is sufficiently replaced with bone tissue (white circle).

**Table 1.** Pearls and Pitfalls of Arthroscopic Antegrade Cancellous Bone Autotransplantation for Osteochondral Lesions of the Tibial Plafond

**Pearls**

- Preoperative evaluation by magnetic resonance imaging is important to prepare a block bone according to the opening diameter of the lesion.
- Strong angled curettes and picks are useful in the case of deep lesion.
- Because the arthroscopic and the bone transplantation operations need to be performed simultaneously, an expert assistant is required.

**Pitfalls**

- Surgical difficulty can increase in cases of stiff ankle where joint space does not open sufficiently.
- In cases in which the width of the Iliac crest is small, harvesting a bone cylinder with a large opening diameter can be difficult.

**Table 2.** Advantages and Disadvantages of Arthroscopic Antegrade Cancellous Bone Autotransplantation for Osteochondral Lesions of the Tibial Plafond

**Advantages**

- Bony and cartilaginous lesions can be restored simultaneously.
- Bony lesion is replaced with normal bone.
- Fibrocartilage regeneration can be expected for cartilaginous lesion.
- Any part of the articular surface can be approached.
- No osteotomy is required for approach.

**Disadvantages**

- Cartilaginous lesion is not be replaced with hyaline cartilage.
- Arthroscopic learning skills are required.
- Multiple pieces of equipment need to be prepared.

## References

1. Mologne TS, Ferkel RD. Arthroscopic treatment of osteochondral lesions of the distal tibia. *Foot Ankle Int* 2007;28:865-872.
2. Athanasiou KA, Niederauer GG, Schenck RC Jr. Biomechanical topography of human ankle cartilage. *Ann Biomed Eng* 1995;23:697-704.
3. Shepherd DE, Seedhom BB. Thickness of human articular cartilage in joints of the lower limb. *Ann Rheum Dis* 1999;58:27-34.
4. Buckwalter JA, Mankin HJ. Articular cartilage: degeneration and osteoarthritis, repair, regeneration, and transplantation. *Instr Course Lect* 1998;47:487-504.
5. Elias I, Raikin SM, Schweitzer ME, Besser MP, Morrison WB, Zoga AC. Osteochondral lesions of the distal tibial plafond: localization and morphologic characteristics with an anatomical grid. *Foot Ankle Int* 2009;30:524-529.
6. Cuttica DJ, Smith WB, Hyer CF, Philbin TM, Berlet GC. Arthroscopic treatment of osteochondral lesions of the tibial plafond. *Foot Ankle Int* 2012;33:662-668.
7. Ross KA, Hannon CP, Deyer TW, et al. Functional and MRI outcomes after arthroscopic microfracture for treatment of osteochondral lesions of the distal tibial plafond. *J Bone Joint Surg Am* 2014;96:1708-1715.
8. Baldassarri M, Perazzo L, Ricciarelli M, Natali S, Vannini F, Buda R. Regenerative treatment of osteochondral lesions of distal tibial plafond. *Eur J Orthop Surg Traumatol* 2018;28:1199-1207.
9. Desai S. Surgical treatment of a tibial osteochondral defect with debridement, marrow stimulation, and micronized allograft cartilage matrix: report of an all-arthroscopic technique. *J Foot Ankle Surg* 2016;55:279-282.
10. Johnson NR, Skinner S, Haleem AM. All-arthroscopic treatment of dependent osteochondral lesions of the ankle: surgical technique. *J Foot Ankle Surg* 2017;56:613-617.
11. Okamura K, Sugimoto K, Isomoto S, et al. Osteochondral lesion of the tibial plafond treated with a retrograde osteochondral autograft: a report of two

- cases. *Asia Pac J Sports Med Arthrosc Rehabil Technol* 2017;8:8-12.
12. Draper SD, Fallat LM. Autogenous bone grafting for the treatment of talar dome lesions. *J Foot Ankle Surg* 2000;39:15-23.
  13. Kolker D, Murray M, Wilson M. Osteochondral defects of the talus treated with autologous bone grafting. *J Bone Joint Surg Br* 2004;86:521-526.
  14. Gu W, Li T, Shi Z, et al. Management of Hepple stage V osteochondral lesion of the talus with a platelet-rich plasma scaffold. *Biomed Res Int* 2017;2017:6525373.
  15. Takao M, Innami K, Komatsu F, Matsushita T. Retrograde cancellous bone plug transplantation for the treatment of advanced osteochondral lesions with large subchondral lesions of the ankle. *Am J Sports Med* 2010;38:1653-1660.