

OPEN

Plate-assisted Bone Segment Transport With Motorized Lengthening Nails and Locking Plates: A Technique to Treat Femoral and Tibial Bone Defects

Ulrik Kähler Olesen, MD
 Tobias Nygaard, MD
 Daniel E. Prince, MD, MPH
 Matthew P. Gardner, MD
 Upender Martin Singh, MD
 Martin A. McNally, MB, BCh, MD, FRCS (Orth)
 Connor J. Green, MB, BC, BAO, MSc, MCh, FRCSI
 John E. Herzenberg, MD, FRCSC

Correspondence to Dr. Kähler Olesen: ulrik.kaehler@gmail.com

JAAOS Glob Res Rev 2019;3:e064

DOI: 10.5435/JAAOSGlobal-D-19-00064

Copyright © 2019 The Authors. Published by Wolters Kluwer Health, Inc. on behalf of the American Academy of Orthopaedic Surgeons. This is an open-access article distributed under the terms of the Creative Commons Attribution-Non Commercial-No Derivatives License 4.0 (CCBY-NC-ND), where it is permissible to download and share the work provided it is properly cited. The work cannot be changed in any way or used commercially without permission from the journal.

Abstract

Background: This article describes a new bone transport technique for femoral and tibial bone defects using lengthening nails combined with locking plates. We term it plate-assisted bone segment transport (PABST).

Methods: Nine patients with five femoral and four tibial bone defects from open fractures or malignancies were treated between 2016 and 2018. Mean femoral defect length was 9.3 cm (range 7 to 11.5). Mean tibial defect was 8.9 cm (range 4.8 to 15). The patients were evaluated for time to weight bearing, consolidation index, mechanical axis deviation, and limb length discrepancy.

Results: Seven of nine patients have fully consolidated. The mean consolidation time was 6.6 months. The consolidation index was 0.9 (femur) and 1.26 (tibia) mo/cm. Two patients required supplementary lengthening. One patient had mild varus, one mild valgus; the remainder had a normal mechanical axis. Limb length discrepancy remained acceptable in all patients. The main complications were heterotopic ossification, delayed healing, and reduced knee motion.

Conclusion: Bone transport with lengthening nails and locking plates is an effective and patient-friendly way of treating bone defects, eliminating the adverse effects of external fixation and reducing treatment time. The plate provides stability during transport and docking; it can address concomitant fractures and facilitates acute shortenings.

Internal lengthening nails have revolutionized the field of distraction osteogenesis, deformity correction, and limb lengthening¹⁻³ by eliminating the adverse effects of external fixation: pain, soft-tissue scarring, and tethering; pin tract

infection; fracture after frame removal; and the inconvenience of wearing an external device for a prolonged time, particularly on the femur.⁴⁻⁶ However, in cases with bone loss in the diaphysis of long bones, bone transport with external fixators

remains the “Gold Standard” because of concerns of infection,⁷ the condition of the soft tissues, and because dedicated transport nails are still in the early phases of development⁸ and are neither available nor designed to be used in the acute setting. Furthermore, distraction osteogenesis has traditionally been avoided by musculoskeletal oncology surgeons due to uncertainty regarding the effect of radiation- and systemic chemotherapy on the callus regenerate.^{9,10}

This article describes a surgical technique of bone transport with completely implantable device (motorized lengthening nails combined with locking plates). The plate allows stabilization of concomitant metaphyseal or condylar fractures, maintains limb length, and facilitates docking site fixation. In small defects, the limb is acutely shortened over the plate and the limb is lengthened through a separate osteotomy, sparing the patient the secondary docking procedure. The nail gives controlled distraction osteogenesis for filling defects, with limited impact on the surrounding soft tissues. We present our experience and clinical outcome in five femoral and four tibial bone defects.

Method

Five patients presented with major segmental bone loss in the femur, three after open fractures (Figures 1, 5, and 9) and two after resection of

malignant tumors (Figures 7 and 8). Four patients presented with bone loss on a traumatic (3) or a malignant (1) background in the tibia. Patients were prospectively evaluated for time to full weight bearing, mechanical axis deviation (MAD), limb length discrepancy (LLD), consolidation index, and complications.

Consolidation time was defined as the time from the corticotomy to radiographic consolidation. Radiographic consolidation of the regenerate was determined when at least three of four cortices showed sufficient corticalization on AP and lateral radiographs. Consolidation index was defined as the time (in months) from the initial surgery to radiographic consolidation divided by the transported distance (in centimeters). Knee and ankle range of motion (ROM) was measured for all patients at the end of bone transport. Long leg, standing radiographs were obtained on all patients after the transport. All six trauma patients sustained Gustilo Anderson type 3A or 3B open fractures with bone loss and soft-tissue defects.¹¹ Of the three cancer patients, two had a primary osteoblastic osteosarcoma in the tibia and femur, respectively, and one had a solitary metastatic lesion from a thyroid cancer in the femur.

Initial treatment is débridement of contaminated or devitalized tissue to healthy viable bone or resection of the tumor with an appropriate margin. A rigid locking plate is applied to

span the defect using combinations of unicortical fixation in the shaft to allow for nail placement and bicortical fixation where possible to help maintain length, alignment, and rotation. Planned bone shortening may be considered to compensate for soft-tissue loss or to accommodate available lengthening nail sizes. Limb length and alignment during the operation are assessed with a radiolucent grid. An external fixator is very useful at this point to apply the locking plate—using fixator-assisted technique for greater accuracy.¹² When possible, the plate is positioned in the metaphyseal area to allow bicortical screw fixation around the nail to enhance stability. We used PRECICE IM nails in all cases shown here (NuVasive).

Surgical Technique

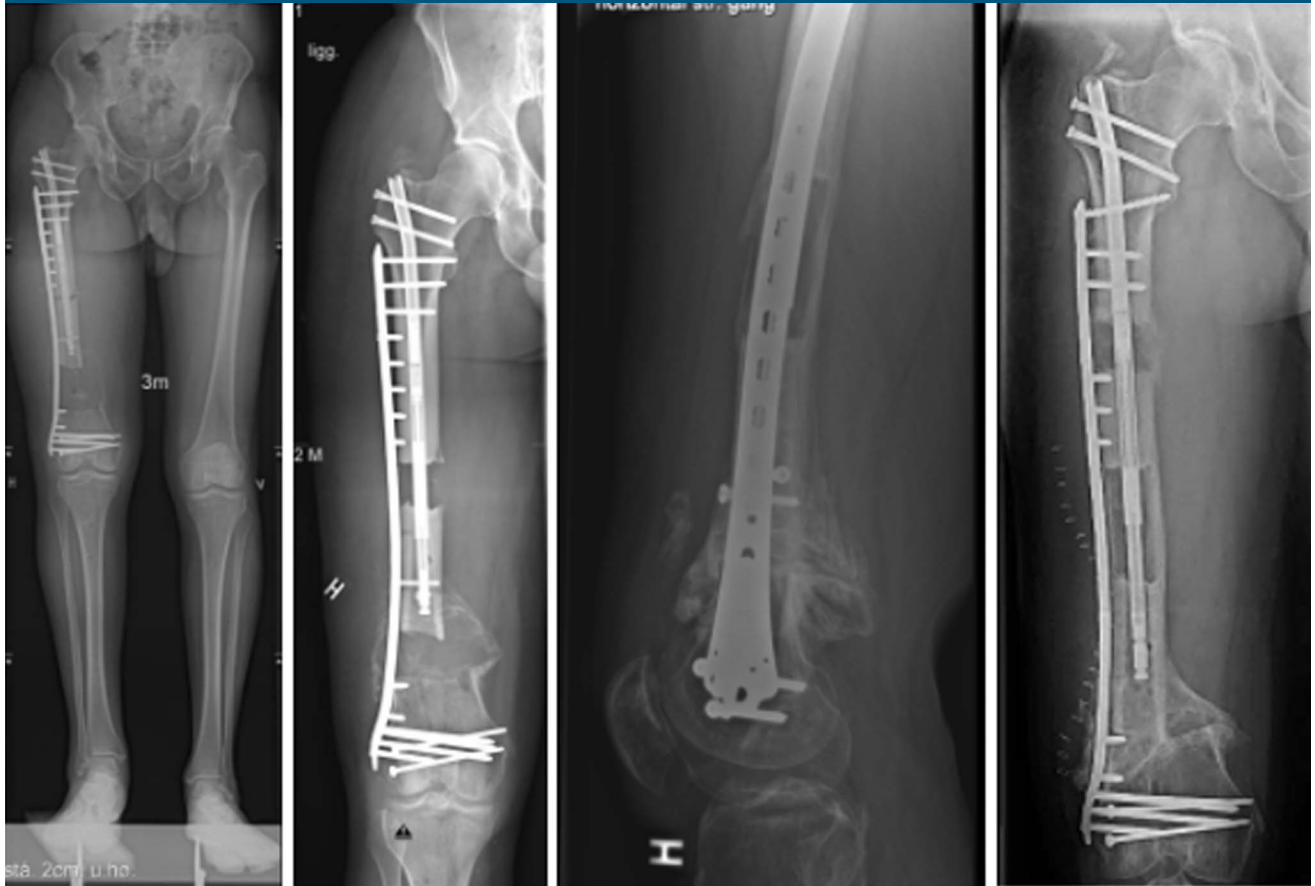In fracture cases, the bone is initially stabilized with external fixation, then internal plating; the soft tissues are débrided and local placement of an antibiotic composite is used to decontaminate the area. Alternatively a trauma nail combined with an antibiotic cement spacer and/or an antibiotic coating can be used to maintain length, rotation, and alignment until soft tissues are ready for surgery. Prophylactic systemic antibiotics are administered until soft-tissue closure.⁷ After full soft-tissue restoration and confirmation of absence of infection, transport is started: A low-energy, drill hole

From Rigshospitalet, Department of Orthopedic Surgery, Copenhagen Limb Lengthening and Bone Reconstruction Unit, Denmark (Dr. Kähler Olesen, Dr. Nygaard, and Dr. Singh); the Memorial Sloan Kettering Cancer Center, Orthopedic Service, New York City, NY (Dr. Prince); the Sinai Hospital, Rubin Institute for Advanced Orthopedics, International Center for Limb Lengthening, Baltimore, MD (Dr. Herzenberg); the Springfield Clinic, Springfield, IL (Dr. Gardner); the Nuffield Orthopedic Centre, Oxford University Hospitals, UK (Dr. McNally); and the Children’s University Hospital, Dublin, Ireland (Dr. Green).

None of the following authors or any immediate family member has received anything of value from or has stock or stock options held in a commercial company or institution related directly or indirectly to the subject of this article: Dr. Olesen, Dr. Nygaard, Dr. Prince, Dr. Gardner, Dr. Singh, Dr. McNally, Dr. Green, and Dr. Herzenberg. Dr. Herzenberg is a consultant for NuVasive.

Dr. Kähler Olesen: wrote the manuscript, analyzed the results and operated 3 (trauma) patients. Dr. Nygaard: revised the manuscript and operated 3 (trauma) patients. Dr. Gardner: revised the manuscript and operated 3 (trauma) patients. Dr. Singh: revised the manuscript and operated 1 (trauma) patient. Dr. Prince: revised the manuscript and operated 3 (tumor) patients. Dr. McNally: revised the manuscript and analyzed the results. Dr. Green: revised the manuscript, developed illustrations. Dr. Herzenberg: revised the manuscript, developed illustrations.

Figure 1



Radiographs showing an open femoral fracture (case 4) with a resultant defect of 10.5 cm, shortened 2.5 cm to allow soft-tissue closure. Antegrade transport next to lateral LISS plate and secondary lengthening. Docking site fully healed. This docking site healed with passive compression and was not grafted. After docking, the transport segment is fixed with screws and supplementary lengthening is initiated at a second stage. The plate is then fixed to the bone in the proximal end.

corticotomy is performed at the planned location, creating a vascularized transport segment before reaming the medullary canal and to allow bone reamings to enter the surrounding soft tissue at the distraction site. In the femur, the intramedullary lengthening nail is inserted in an antegrade or retrograde direction as needed. A graphical depiction of the technique in the femur is shown in Figure 2, A–G and in Figure 3, A–G for the tibia. In the tibia, a standard approach proximal to the tuberosity is used. A suprapatellar approach may be used for very proximal defects. The plate is generally located on the lateral side in both the femur and the tibia; however, in

select cases and when soft tissues are sound, it may be placed medially as seen in tibial cases 1 and 2. Blocking screws may be added to enhance the stability of the nails' path in metaphyseal bone. Plastic surgery is often relevant in tibia trauma cases with bone loss, and the tibia is generally considered relatively more difficult to treat than the femur, which is also reflected in our results. Therefore, particular precautions are advised regarding regenerate formation and soft-tissue fragility, requiring a slower rate of transport.

Nails can be predistracted to pull the fragment (shortening the nail), instead of pushing, if needed (Figures 3D and 9). If the nail stroke (eg, the

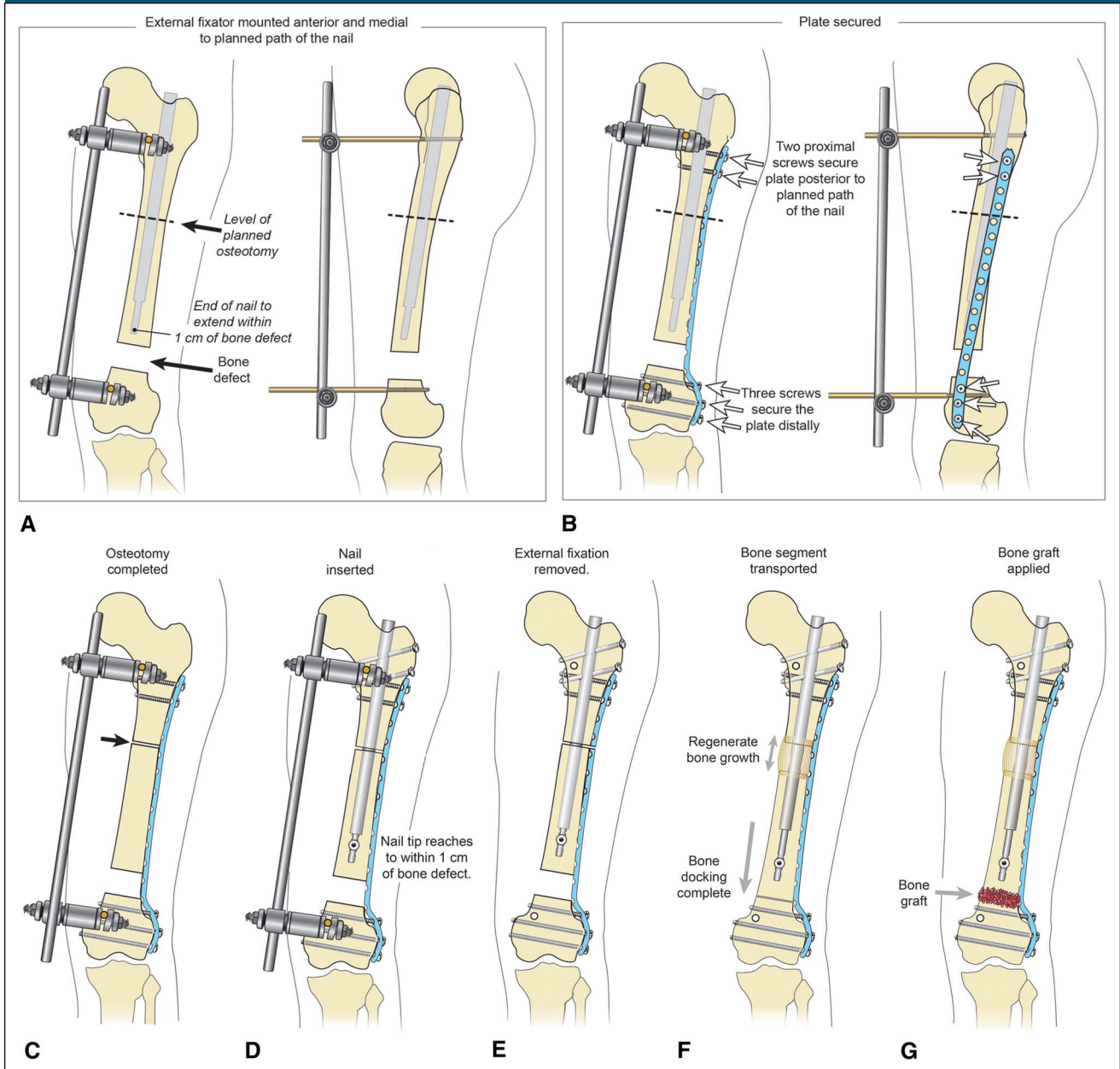
lengthening capability of the nail) is shorter than the defect, the nail can be exchanged or adapted to more lengthening by temporary fixation of the transport fragment, while recompressing the nail, and relocating it in its newly shortened position.

Calibrated radiographs and long-standing radiographs are essential in the planning of nail and plate size and number and location of screws.

Postoperative Management

The bone is transported at a rate of 0.25 to 0.33 mm three to four times per day, starting 5 to 7 days after the corticotomy. Slower rates may be used for tibias in smokers, in patients

Figure 2



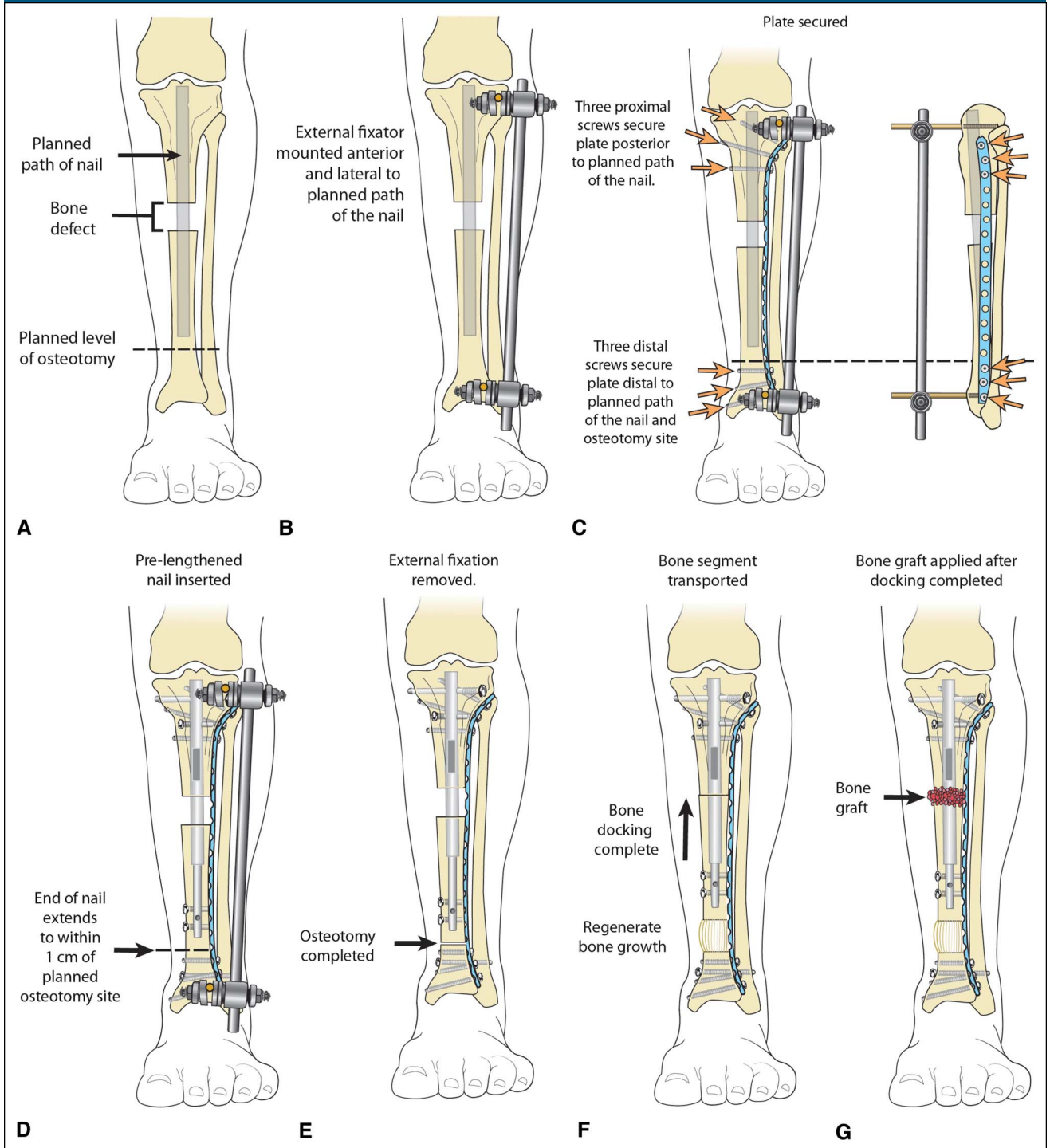
A, Schematic diagram showing a setup for antegrade bone transport. The temporary external fixator maintains alignment and length. The planned nail position is shown as greyed out. The planned osteotomy is the dotted line. **B**, The locking plate is secured to maintain length and alignment once the temporary fixator is removed. Note that the locking screws proximally are behind the planned path of the nail. **C** and **D**, The osteotomy is completed, and the nail is inserted and locked. **E–G**, The temporary external fixator has been removed. Once the bone transport is completed, bone graft is applied to the docking site. Additional, unicortical locking screws may be applied to the transport segment if desired for greater stability. Copyright 2019, Rubin Institute for Advanced Orthopedics, Sinai Hospital of Baltimore.

concurrently receiving chemotherapy, and in elderly patients. At 2-week intervals, clinical check-ups including radiographs are scheduled to monitor regenerate formation and

signs of infection. The rate of transport can be speeded up or slowed down according to bone formation, as seen on the follow-up radiographs.

When the transport segment docks, we recommend a second surgery for débridement of the bone ends, autologous cancellous bone rafting, and compression (Figure 2G). We

Figure 3



A, Schematic diagram showing a bone defect, with greyed out area indicating intended path of nail. **B**, Monolateral external fixator applied temporarily to maintain length and alignment. **C**, Locking plate inserted laterally. Proximal screws placed behind the intended nail path. **D**, Prelengthened nail inserted for distal to proximal transport. **E**, The osteotomy has been completed distally. **F**, Transport completed. **G**, Bone grafting of the proximal docking site. Copyright 2019, Rubin Institute for Advanced Orthopedics, Sinai Hospital of Baltimore.

Table 1

Patient Data						
Patient	Age/sex	Pathology	Defect Size	Shortening	Transport	Consolidation Time
FEMURS						
1	49/M	Thyroid metastasis	9.0	1.0	8.0	5
2	10/M	Osteosarcoma	7.0	2.0	5.0	5
3	28/F	Open # GA 3B	8.5	2.0	6.5	7
4	51/M	Open # GA 3B	10.5	2.5	8.0	8
5	48/M	Open # GA 3B	11.5	3.5	8.0	8
AVG	37		9.3 cm	2.2 cm	7.1 cm	6.6 mo
Span			7-11.5	1-3.5	5-8	5-8
TIBIAS						
1	77/F	Farm injury	4.8	0	4.8	9
2	24/M	MC crash	10	2	8	9
3	35/M	Plane crash	6	0	6	—
4	15/M	Osteosarcoma	15	2	8 + 3 + 4	12
AVG	38		8.9 cm	1 cm	8 cm	10 mo
Span	(15-77)		(4.8-15)	(0-2)	(4.8-13)	(9)

GA = Gustilo Anderson open fracture, LLD = limb length discrepancy

used a mix of iliac crest bone graft or intramedullary femur graft and bone marrow aspirate concentrate. Additional unicortical screws should be inserted to fix the transport segment to the plate. Alternatively, continuous pressure on the docking site to induce union can be obtained by activating the transport nail, for example, 0.33 mm biweekly (Figure 1, femur case 4). If further lengthening is required after docking, the nail can continue to lengthen or be left sleeping until the docking site is healed and a secondary corticotomy can be performed. Union of the docking site is assessed by plain radiographs or, if necessary, by CT.

During transport, the patient is allowed 10 to 20 kg of weight bearing. Because the regenerate is protected with a plate and a nail, we generally allow weight bearing as tolerated shortly after docking. However, if the regenerate is only protected with a plate, as in a retrograde transport (pulling the segment), we recommend waiting until near full consolidation of the regenerate before full weight bearing. Details from each case are

presented in the tables and in the figure legends.

Results

Femurs

Five patients, four men and one woman, with an average age of 37 years (range 10 to 51) were operated between 2016 and 2018. Average follow-up was 25 months (range 18 to 36). Mean defect size was 9.3 cm (range 7 to 11.5) and mean transport length was 7.1 cm (range 5.0 to 8.0). All patients were shortened, an average of 2.2 cm (range 1 to 3.5), to allow soft-tissue closure or to adapt to available nail lengths. All patients went on to full weight bearing at an average of 5 months (range 4 to 6).

Average consolidation index was 0.9 mo/cm. MAD remained within normal limits in four out of five cases, one had mild varus. Two patients required additional lengthening due to residual LLD addressed in a subsequent procedure (femur cases 4, 5, Figures 5 and 9). One patient had a

bilateral injury that was initially treated with acute shortening on one side and bone transport on the other. Secondary lengthening on the shortened side eliminated remaining LLD (femur case 3). Average final LLD was roughly equal: 0.9 cm (0 to 2.0). See Table 1.

Union of the docking site required repeat bone grafting in two (trauma) cases. One patient with severe laceration of the quadriceps muscle, poor healing of docking site, comminution of the femoral condyles, and joint surface destruction was referred to a second stage joint arthroplasty below the transported diaphysis (case 5). Two patients with persistently reduced knee flexion (<80°) underwent successful quadriceps release (femur case 3, 4). At final follow-up, three in five patients had normal knee ROM, case 4 had 0° to 130°, and case 5 had 0° to 110° of motion.

Tibias

Three men and one woman were operated between 2016 and 2018. Average age was 38 (15 to 77 years),

Table 1 (continued)

Patient Data							
Patient	Consolidation Index	Time to Full w/b	LLD	Time to Union	Extra Lengthening	Knee ROM	F/u
FEMURS							
1	0.6	4	1.0	12	—	Full	33
2	1.0	5	2.0	5	—	Full	36
3	1.1	5	0.5	7	—	Full	18
4	1.0	5	0.5	10	2.5	0-130	19
5	1.0	6	<0.5	(TKA)	3.5	0-110	19
AVG	0.92 mo/cm	5 mo	0.9 cm	8.5 mo	1.1 cm	0-150	25 mo
Span	0.6-1.0	4-6	1.0-4.5	5-12	0-3.5	0-Full	18-36
TIBIAS							
1	1.9	4	0	—	—	0/30	11
2	1.1	9	2	9	0	10/40	13
3	—	4	0	6	0	5/30	6
4	0.8	10	0.5	—	0	15/30	12
AVG	1.26 mo/cm	5.7 mo	0.5 cm	7.5 mo	0 cm	3/33 dgr	10.5 mo
Span	(0.8-1.9)	(4-9)	(0-2)	(6-9)	(0)		(4-13)

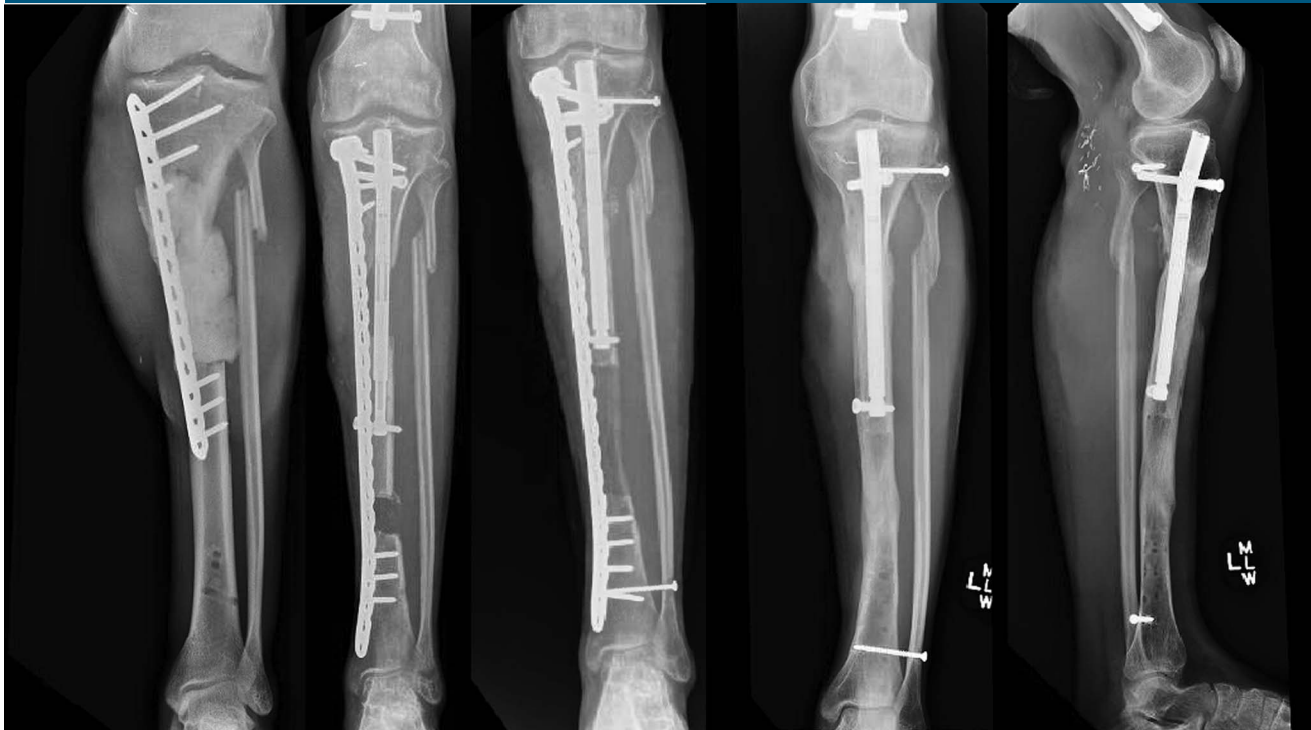GA = Gustilo Anderson, LLD = limb length discrepancy

Table 2**Surgical Modality, Device, Complications**

Patient	Modality	Plate	Device	Complications	Extra Length	Notes
FEMURS						
1	Retrograde push	95 plate	12.5/305/80	—	—	—
2	Antegrade push	LISS	8.7/150/50	—	—	—
3	Retrograde pull	LISS	8.7/150/50	HO, contracture, delayed union	Contralat. length	Bilateral injury
4	Antegrade push	LISS	10.5/245/80	HO, contracture, mild varus	Yes	—
5	Antegrade push	LISS, LAP	10.5/245/80	HO, mild varus, delayed union	Yes	Revision TKA
TIBIAS						
1	Antegrade push	Medial distal, Synthes	8.5/195/50	Delayed union	—	Combined free and rotational flap, split skin
2	Retrograde pull	Proximal medial, Synthes	8.5/150/50	Mild varus, superficial infections	—	Free flap, split skin
3	Antegrade push	Medial distal, Synthes	8.5/195/50	Slight rebound of intercalary segment when converted to nail	—	Rotational flap, split skin. Trauma nail conversion
4	Staged Bifocal retrograde pull and antegrade push	Proximal lateral tibial, Zimmer	10.7/245/80/10.7/195/50	Superficial infection, mild subtalar valgus	—	Conversion to antibiotic-coated nail

LISS = less invasive stabilization system (Synthes), LAP = locking attachment plate (Synthes), HO = heterotrophic ossification, TKA = total knee arthroplasty.

Figure 4



Radiographs of tibia case 2 (motorcycle crash) showing traumatic bone loss of 10 cm, retrograde bone transport, docking site stabilized with trauma nail.

LLD and MAD remained roughly unchanged; one patient is healing in mild varus. Three have achieved full consolidation; two await union of the docking site.

Consolidation index (1.26 mo/cm) was higher and consolidation time longer compared with femur cases. One tumor case required a three-stage transport procedure (8 + 3 + 4 cm) because of the large defect (15 cm) and acute shortening of 3 cm. All three tibial trauma patients needed plastic surgery to obtain soft-tissue cover (split skin and rotational flap or free flap) (Table 2).

The average number of procedures required to obtain normal alignment in both bones was five (plating, nailing, docking), not including soft-tissue reconstruction in trauma cases and not including supplementary lengthening. Reduced knee or ankle ROM, superficial infection, delayed healing of docking sites, and hetero-

topic ossification were the main complications. No deep infections occurred in this series of patients (Figure 4).

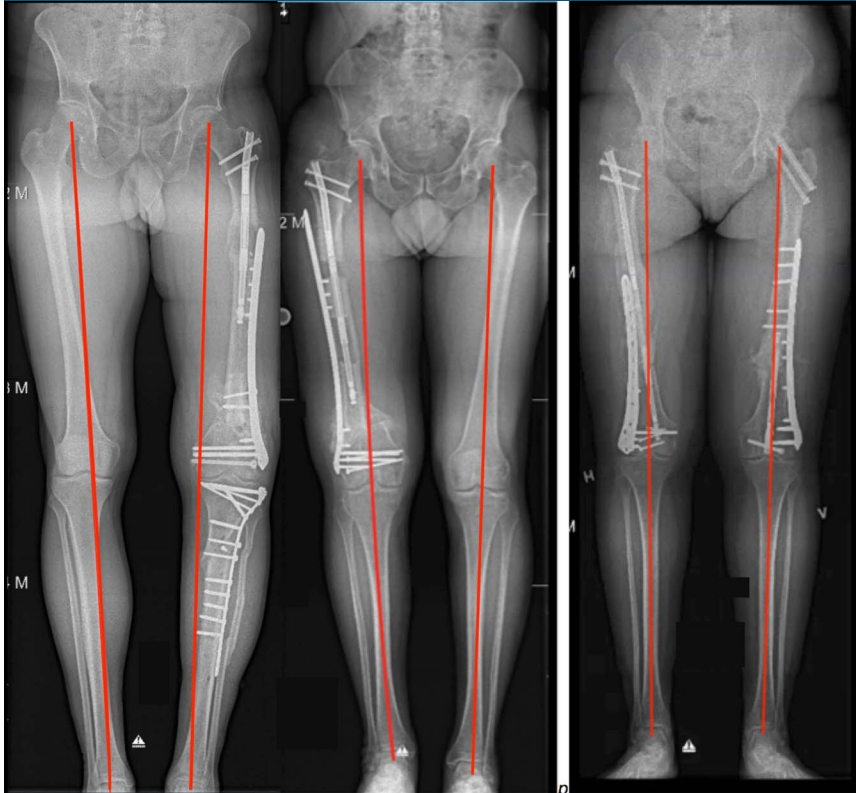
Discussion

We developed the plate-assisted bone segment transport technique (PABST) to eliminate the need for prolonged external fixation and to reduce treatment time, in particular, time to full weight bearing and free joint movement in patients with moderate sized bone defects.

A number of techniques exist to address bone loss: the induced-membrane technique of Masquelet and Begue,¹³ external bone transport (with or without intramedullary nailing), and vascularized fibular grafts being the most common.¹⁴ In tumor cases, specific diaphyseal prostheses are available. Bone transport is the most physiological and

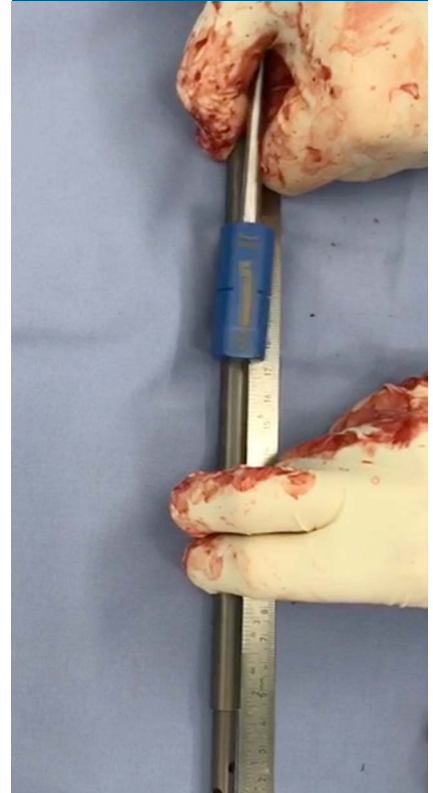durable method with an average treatment time of 1 month per cm. Our consolidation index of 0.9 mo/cm in the femur and 1.26 mo/cm in the tibia compares well with that reported for Ilizarov bone transport after infected nonunion of the tibia by McNally, Tetsworth, and colleagues in 2017^{15,16} and bone transport after resection of malignant tumors in the tibia and femur.¹⁷ The consolidation index is approximately half of what has been reported for external fixator lengthening at 1.8 to 1.9 mo/cm.^{4,18} The consolidation time after lengthening can be further reduced using the LON/LATP/LATN (Lengthening Over Nail, Lengthening And Then Plating, Lengthening And Then Nailing) techniques, where a plate or a nail is used to protect the regenerate during maturation against collapse, deviation or fracture, as described by a number of authors: Fragomen,¹⁸ Simpson,¹⁹ and Nayagam.²⁰ In

Figure 5



Radiographs showing femur cases 3, 4, and 5. After transport and subsequent lengthening, LLD < 1.0 cm. MAD normal in case 3 and 4. Case 5 with mild varus. LLD = limb length discrepancy, MAD = mechanical axis deviation.

Figure 6



Photograph showing: Re-charging (shortening) of the nail using the "Rapid Distractor" (NuVasive).

comparison, Masquelet and Begué¹³ reported an average consolidation time of 14 months for bone defects in a larger series. In another series using the Masquelet technique, eight patients with defect sizes of 3 to 9 cm demonstrated an average time to full weight bearing of 8 months, whereas consolidation time was unpredictable and failed to occur in three cases.²¹

PABST is particularly suitable for the femur. High external fixation is difficult for the patient, although deep infection risk is likely lower compared with the lower leg due to the larger soft-tissue envelope and robust vascularity.²¹ We found good to excellent results in our 9 cases and believe that this technique deserves a place in future treatments of bone loss in the femur and

tibia. The internal lengthening nail is markedly more patient-friendly than external fixator lengthening, as demonstrated by Horn, Herzenberg, and others and has particularly shorter treatment time than, for example, the Masquelet technique.¹³

We have not clinically used this technique outside the femur and tibia, but, with a little imagination, it could be applied to the humerus.²³

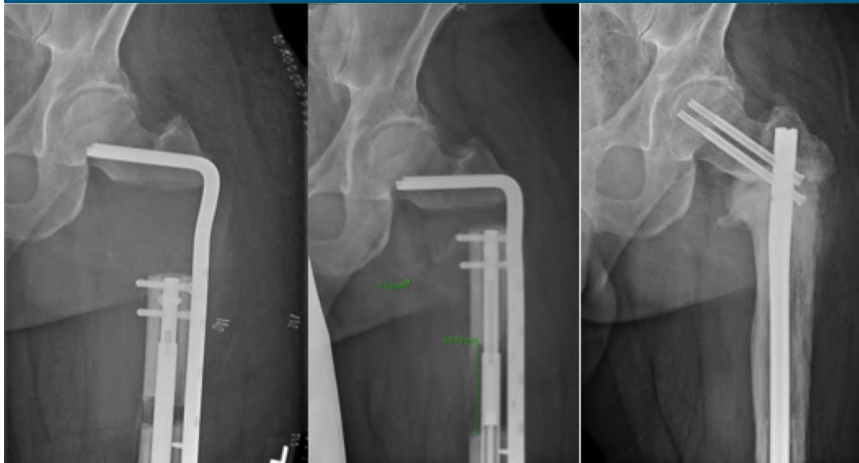Limitations of Current Implants

In our series, we had limitations with regard to the available nail sizes and the distance over which the nails can lengthen. Currently, PRECICE nail lengths of 150 to 420 mm are available with a lengthening potential of

30 to 80 mm (nail stroke). This allows most cases to be treated by combinations of acute shortening followed by gradual distraction and subsequent repeated lengthening, which may be required in tall patients or in those with very long segment defects.

When the nail stroke is too short to cover the defect, extra length can be obtained by reshortening or relengthening the nail, while temporarily fixing the transport segment to the plate and removing the screw at the tip of the nail. We did this intraoperatively using the rapid distractor device; see Figure 6. In two cases (before the rapid distractor was available), we lengthened the nail by applying the external remote controller to the leg. This procedure takes several hours and was done outside the operating room.

Figure 7



Radiographs showing retrograde (push) transport (case 1) with a 95° Stryker plate, after resection of solitary metastasis in a patient with thyroid cancer. After the transport, the nail and the plate were replaced with a standard fracture nail (Synthes LFN).

Sufficient bone is required to accommodate both nail and plate fixation above and below the defect. We advocate a minimum of 3 to 4 screws in each end of the plate. Careful preoperative planning is critical to assess the plate construct, the nail size, and the potential need for acute shortening.

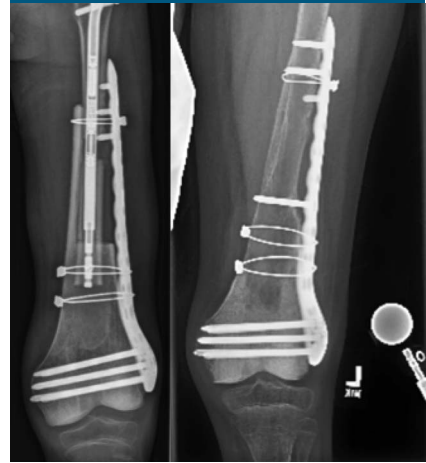
A specific custom built transport nail (Fitbone TAA nail) is commercially available⁸ and others are under development²⁴ but cannot address acute shortenings, concomitant fractures, or lesions in the metaphyseal region and cannot stabilize the transport segment after docking or when more length is needed. Such custom built nails are not readily available and so may not be possible in the acute setting. In cases of comminuted femoral trauma, some advocate stabilizing small defects with an IM nail to await spontaneous healing, particularly where vascularized fragments remain. However, this approach may take up to two years for healing and is not reliable in larger defects.²⁵ Our series only included patients with major bone loss (4.8 to 15 cm).

Assessment of consolidation of the regenerate can be difficult when a large metal plate obscures the lateral radiographic view. The recent development of radiolucent carbon plates may resolve this issue²⁶ (Figure 5).

Acute Shortening Versus Bone Transport

Acute shortening is forgiving, and relatively safer than transport,²⁷ in the femur for defects up to 4 to 5 cm and for defects up to 3 cm in the tibia and should be considered in such cases because it will spare the patient a docking procedure. In 1994, Steen's group reported notable and permanent loss of muscle power in shortenings exceeding 5 cm.¹⁶ An Oxford study found that up to 35 mm could be shortened without any permanent loss of muscle power after 2 years.²⁸ In certain clinical situations, (severe trauma, contamination, soft-tissue defects, bilateral injuries, lack of compliance etc.) we recommend acute shortening and docking while carefully monitoring the circulation and then subsequent gradual leng-

Figure 8



Radiographs showing femur case 2: Tumor case, 10-year-old child after resection of a primary osteosarcoma without metastatic disease. On completion of radiation- and chemotherapy: Anterograde transport toward a condylar allograft, serving as a spacer, lateral plating, and cerclage. Docking of bone cylinder inside condyles. A TKA is projected after skeletal maturity.

thening. In larger defects, normal length and alignment should be maintained whenever possible.

Infection

Infection is a concern in open fractures because contamination is inevitable, with infection rates reported up to 25% to 40%.⁷ With internal fixation, the risk of biofilm formation is increased, underscoring the need for prevention of infection. We elected to wait up to 6 weeks from soft-tissue closure and obtain normal blood inflammatory biomarkers (CRP, WBC) before insertion of the nail. In trauma patients, we instilled local absorbable antibiotic carriers in the bone void as dead-space management: We used calcium sulfate pellets with gentamicin (Herafill; Heraeus), Cerament V/G paste (Bonesupport AB), or antibiotic-containing cement spacers. Such a spacer will not only

help in infection prevention,²⁹⁻³² it will also create a fibrous chamber with a Masquelet-like bioactive lining, in which the bone transport can take place and prevent potential soft-tissue invagination. Oral antibiotics were continued for 6 weeks after surgery. Continuous soft-tissue assessment is essential and the use of free flaps is often relevant in the tibia to achieve soft-tissue cover over exposed bone and to prevent deep infection.

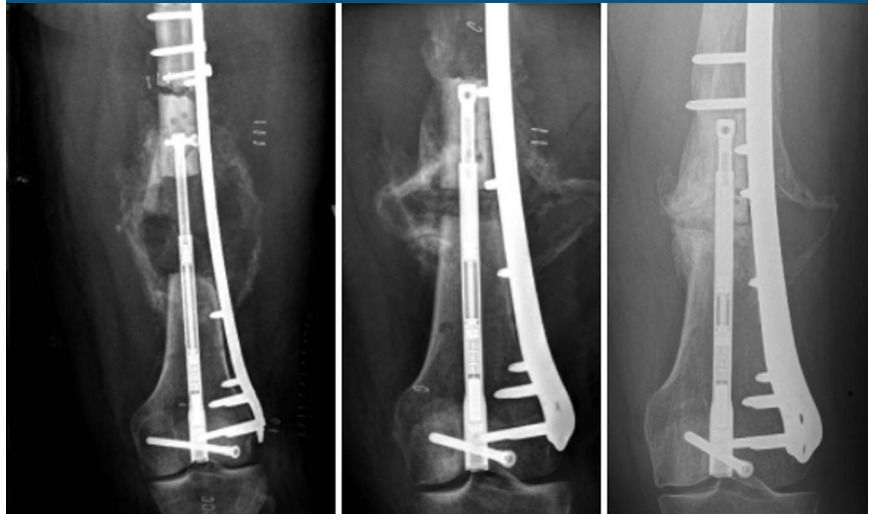Tumor Considerations

Concomitant chemo- and radiation therapy and radiation therapy are traditionally considered relative contraindications for distraction osteogenesis because bone formation may be delayed.^{9,10} However, recent studies have demonstrated that distraction osteogenesis is a safe treatment for larger bone defects in primary osteosarcomas.^{17,33} Tsuchiya et al have shown excellent, durable function after 10 years, which is particularly attractive as an alternative to endoprosthetic replacement in the younger patient population affected by primary bone sarcomas.^{34,35} A study by McCoy et al³⁶ and colleagues in 2012 also found excellent results in 20 patients treated with the Ilizarov method for an osseous defect resulting from a primary bone lesion. For selected tumor patients, distraction osteogenesis is a reliable way to substitute resected bone (Figure 6).

Complications

All trauma patients experienced a degree of heterotopic ossification, fibrosis, superficial infection, delayed healing of docking sites, or reduced joint movement. Such complications are common in open fractures—where bone disrupts the muscle and penetrates the skin—and do not relate specifically to internal bone transport by a lengthening nail and a plate.

Figure 9



Radiographs showing femur case 3. Retrograde transport (pull) using a predistracted nail in bilateral diaphyseal femoral defect where a concomitant hip fracture prevented antegrade access. A staged redistraction of the nail on the left side was performed to close the defect because the defect was longer (65 mm) than the stroke of the nail (50 mm). Two temporary screws are placed in the transport segment while the nail is redistracted. The right side was acutely shortened and later lengthened. Final result: LLD <0.5 cm. Normal MAD. LLD = limb length discrepancy, MAD = mechanical axis deviation.

However, it is essential to address soft-tissue issues with plastic surgeons (particularly in the tibia) and to address potential contracture (particularly in the femur) with vigorous physiotherapy throughout the treatment. Ultimately, a free flap, surgical débridement, quadricepsplasty, arthrolysis, and removal of ectopic bone may be necessary to maximize functional recovery. In addition, with double osteotomies in the femur (transport plus lengthening), or complex injuries in the tibia, alignment can be difficult to control, as seen with mild varus or valgus deviations in select cases. This may be corrected by secondary insertion of a trauma nail or by relocking of the plate to the bone (tibia cases 1, 3, 4, femur case 4).

Limitations

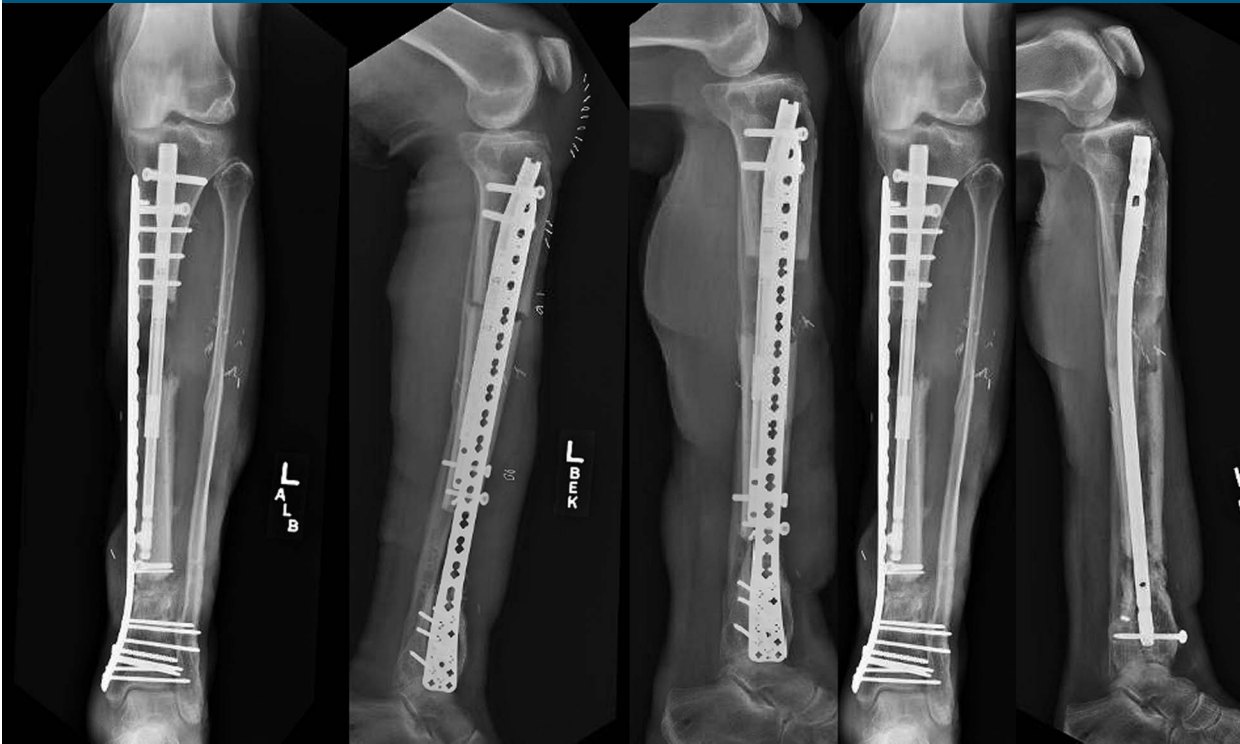This study is limited by the small number of cases and the heterogene-

ity of the patients. We present it as a description of a combined technique, which will no doubt be modified and improved in the future. Larger scale studies should explore this technique further to draw firm conclusions about its indications and feasibility.

Conclusion

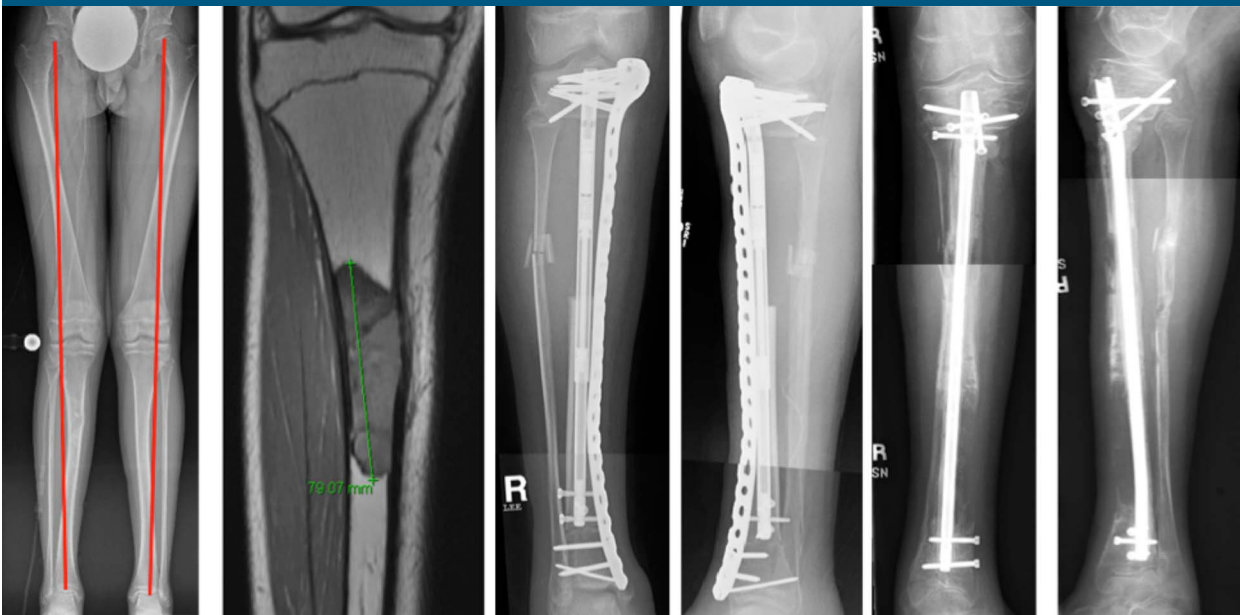The plate-assisted bone segment transport (PABST) with a lengthening nail and a locking plate technique, is a valuable addition to the arsenal for treating bone defects in the femur and tibia, improving patient comfort during treatment, avoiding the adverse effects of external fixation. Full weight bearing can be allowed shortly after docking due to the stability of the construct. Meticulous surgical planning, careful soft-tissue management, and infection control in open fractures is mandatory.

Figure 10



Radiographs showing tibia case 1, (farm injury) with a diaphyseal defect of 4.8 cm and no shortening. On completion of transport and consolidation, the lengthening nail and the plate is replaced with a trauma nail.

Figure 11



A, Radiographs of primary osteosarcoma in a 15-year-old child, with a solitary lesion in the right tibia. Tibia case 4. Long-standing radiographs reveal mild preoperative valgus. **B**, MRI of the lesion. **C**, First-stage PABST. **D**, After second-stage transport, supplementary lengthening, and implant exchange, the transport segment is docked and the regenerate awaits consolidation.

Our Tips and Tricks

- Use long-standing radiographs of both legs with a calibration device to check for length, defect size, alignment, and residual LLD.
- Maintain limb length and alignment at the time of plating if possible.
- In defects less than 4 to 6 cm in the femur and less than 3 to 4 cm in the tibia, acute shortening over the plate and lengthening in a separate osteotomy should be considered, sparing the patient the docking procedure.
- The nail may be predistracted to allow retrograde transport, pulling the transport segment.
- If bone defect is larger than the stroke of the nail, reshorten or redistract the nail, by temporary fixation of the transport fragment and resume transport.
- Likewise, if length is needed after transport, temporarily remove the screw at the tip of the nail, while fixing the transport segment, reshorten the nail, and convert to lengthening.
- Beware of sufficient bone stock to stabilize the plate, the nail, and the transport segment.
- Careful soft-tissue assessment and patience is essential, particularly in open tibial fractures where a free flap is often needed in complex injuries: Involve plastic surgeons early on.
- Use local antibiotic composites as dead-space management in open fractures. A temporary antibiotic-containing cement spacer, particularly in the tibia can also prevent soft-tissue invagination. If combined with a trauma nail it can maintain length and alignment until soft tissues are ready for bone transport.
- Consider a slightly posterior position of the plate in the proximal metaphyseal area, allowing for bicortical screws adjacent to the nail.
- Maintaining normal knee movement may be challenging in particular in femoral defects. Prevent contracture and preserve motion by vigorous physiotherapy and splinting. If persistent, treat with quadricepsplasty and/or arthrolysis.

Acknowledgments

The present work was initiated during the LLRS travelling fellowship in 2016. The authors thank their colleagues M Kahn, A Hede, AW Paulsen, and M Mørk Petersen for feedback and assistance.

References

1. Baumgart R, Betz A, Schweiberer L: A fully implantable motorized intramedullary nail for limb lengthening and bone transport. *Clin Orthop Relat Res* 1997;343:135-143.
2. Rozbruch SR, Birch JG, Dahl MT, Herzenberg JE: Motorized intramedullary nail for management of limb-length discrepancy and deformity. *J Am Acad Orthop Surg* 2014;22:403-409.
3. Dahl MT: Motorized, telescopic, intramedullary lengthening nails for limb length and deformity correction. *Tech Orthop* 2015;30:189-206.
4. Horn J, Grimsrud Ø, Steen H, et al: Femoral lengthening with a motorized intramedullary nail: A matched-pair comparison with external ring fixator lengthening in 30 cases. *Acta Orthop* 2015; 86:248-56.
5. Paley D, Harris M, Prince D, et al: Limb lengthening by implantable limb lengthening devices. *Tech Orthop* 2014;29: 72-85.
6. Landge V, Shabtai L, Gesheff M, Specht SC, Herzenberg JE: Patient satisfaction after limb lengthening with internal and external devices. *J Surg Orthop Adv* 2015;24: 174-179.
7. Olesen UK, Juul R, Bonde CT, et al: A review of forty five open tibial fractures covered with free flaps: Analysis of complications, microbiology and prognostic factors. *Int Orthop* 2015;39: 1159-1166.
8. Kold S, Stenild Christensen K: Bone transport of the tibia with a motorized intramedullary lengthening nail: A case report. *Acta Orthop* 2014;85:211-213.
9. Fan C, Cool JC, Scherer MA, et al: Damaging effects of chronic low-dose methotrexate usage on primary bone formation in young rats and potential protective effects of folic acid supplementary treatment. *Bone* 2009;44: 61-70.
10. Tsuchiya H, Uehara K, Sakurakichi K, Watanabe K, Matsubara H, Tomita K: Distraction osteogenesis after irradiation in a rabbit model. *J Orthop Sci* 2005;10: 627-33.
11. Gustilo RB, Anderson JT: Prevention of infection in the treatment of 1025 open fractures of long bones: Retrospective and prospective analyses. *J Bone Joint Surg Am* 1976;58:453-458.
12. Herzenberg JE, Bor N: Fixator-assisted nailing of femoral and tibial deformities. *Tech Orthop* 1997;12:4.
13. Masquelet AC, Begue T: The concept of induced membrane for reconstruction of long bone defects. *Orthop Clin North Am* 2010;41:27-37.
14. Minami A, Kasashima T, Kaneda K, et al: Vascularised fibular grafts: An experience of 102 patients. *J Bone Joint Surg [Br]* 2000;82-B:1022-1025.
15. McNally M, Ferguson J, Kugan R, Stubbs D: Ilizarov treatment protocols in the management of infected nonunion of the tibia. *J Orthop Trauma* 2017;31(suppl 5): S47-S54.
16. Holm I, Nordsletten L, Steen H, Follerås G, Bjerkeim I: Muscle function after mid-shaft femoral shortening: A prospective study with a two-year follow-up. *Bone Joint Surg Br* 1994;76:143-146.
17. Jacobs N, Sutherland M, Stubbs DA, McNally MA: Distraction osteogenesis for

- reconstruction of primary malignant tumour of long bones. *Bone Joint J* 2014; 96-B(suppl 10):28.
18. Rozbruch SR, Kleinman D, Fragomen AT, Ilizarov S: Limb lengthening and then insertion of an intramedullary nail: A case-matched comparison. *Clin Orthop Relat Res* 2008;466: 2923-2932.
 19. Simpson A, Cole A, Kenwright J: Leg lengthening over an intramedullary nail. *J Bone Joint Surg [Br]* 1999;81-B: 1041-1045.
 20. Nayagam S, Davis B, Thevendran G, Roche AJ: Medial submuscular plating of the femur in a series of paediatric patients: A useful alternative to standard lateral techniques. *Bone Joint J* 2014;96-B: 137-142.
 21. Olesen UK, Eckardt H, Bosemark P, Paulsen AW, Dahl B, Hede A: The Masquelet technique of induced membrane for healing of bone defects. A review of 8 cases. *Injury* 2015;46(suppl 8):S44-S47.
 22. Santolini E, Goumenos SD, Giannoudi M, Sanguineti F, Stella M, Giannoudis PV: Femoral and tibial blood supply: A trigger for non-union? *Injury* 2014;45:1665-1673.
 23. Fürmetz J, Kold S, Schuster N, Wolf F, Thaller PH: Lengthening of the humerus with intramedullary lengthening nails: Preliminary report. *Strat Traum Limb Reconstr* 2017;12:99-106.
 24. Krettek C, El Naga A: All internal segmental bone transport and optional lengthening with a newly developed universal cylinder-Kombi-Tube module for motorized nails: Description of a surgical technique. *J Orthop Trauma* 2017;31: S39-S41.
 25. Mitchell SE, Keating JF, Robinson CM: The treatment of open femoral fractures with bone loss. *J Bone Joint Surg Br* 2010;92: 1678-1684.
 26. Zimel MN, Hwang S, Riedel ER, Healey JH: Carbon fiber intramedullary nails reduce artifact in postoperative advanced imaging. *Skeletal Radiol* 2015;44: 1317-1325.
 27. Tetsworth K, Paley D, Sen C, et al: Bone transport versus acute shortening for the management of infected tibial non-unions with bone defects. *Injury* 2017;48: 2276-2284.
 28. Barker KL, Simpson AH: Recovery of function after closed femoral shortening. *J Bone Joint Surg Br* 2004;86: 1182-1186.
 29. Ferguson J, Diefenbeck M, McNally M: Ceramic biocomposites as biodegradable antibiotic carriers in the treatment of bone infections. *J Bone Joint Infect* 2017;2: 38-51.
 30. Li HK, Rombach I, Zambellas R, et al: Oral versus intravenous antibiotics for bone and joint infection. *N Engl J Med* 2019;380: 425-436.
 31. McNally MA, Ferguson JY, Atkins BL: Single-stage treatment of chronic osteomyelitis with a new absorbable, gentamicin-loaded, calcium sulphate/hydroxyapatite biocomposite. *Bone Joint J* 2016;98-B:1289-1296.
 32. Morgenstern M, Vallejo A, McNally MA, et al: The effect of local antibiotic prophylaxis in open limb fractures: A systematic review and meta-analysis. *Bone Joint Res* 2018;7:447-456.
 33. Lesensky J, Prince DE: Distraction osteogenesis reconstruction of large segmental bone defects after primary tumor resection: Pitfalls and benefits. *Eur J Orthop Surg Traumatol* 2017;27:715-727.
 34. Tsuchiya H, Shirai T, Morsy AF, et al: Safety of external fixation during postoperative chemotherapy. *J Bone Joint Surg Br* 2008;90:924-928.
 35. Watanabe K, Tsuchiya H, Yamamoto N, et al: Over 10-year follow-up of functional outcome in patients with bone tumors reconstructed using distraction osteogenesis. *J Orthop Sci* 2013;18:101-109.
 36. McCoy TH, Kim HJ, Cross MB, et al: Bone tumor reconstruction with the Ilizarov method. *J Surg Oncol* 2013;107:343-352.