



STA-A3 Bypass Using Radial Artery Graft for Progressive Cerebral Infarction of Bilateral ACA Region after STA-MCA Bypass Surgery for Moyamoya Disease

Yudai Hirano¹ Hideaki Ono¹ Tomohiro Inoue² Kenta Ohara³ Takeo Tanishima¹ Akira Tamura¹ Isamu Saito¹

¹Department of Neurosurgery, Fuji Brain Institute and Hospital, Fujinomiya-shi, Shizuoka, Japan

²Department of Neurosurgery, NTT Medical Center Tokyo, Tokyo, Japan

³Department of Neurosurgery, The University of Tokyo Hospital, Tokyo, Japan

Address for correspondence Hideaki Ono, MD, Department of Neurosurgery, Fuji Brain Institute and Hospital, 270-12 Sugita, Fujinomiya-shi, Shizuoka, 418-0021, Japan (e-mail: hideono@fuji-nouken.or.jp).

AJNS 2022;17:352–356.

Abstract

Direct revascularization surgery, such as superficial temporal artery (STA)-middle cerebral artery (MCA) bypass, is effective in preventing ischemia and hemorrhage for moyamoya disease. On the other hand, when ischemia of the anterior cerebral artery (ACA) region progresses after ipsilateral STA-MCA bypass, it is difficult to perform revascularization from the viewpoint of the donor artery. A 55-year-old woman with right hemiparesis was diagnosed with cerebral infarction due to moyamoya disease. Left STA-MCA bypass was performed with no postoperative complications, but memory impairment and decreased motivation were observed 2 months after the operation. Magnetic resonance imaging and angiography revealed new infarction in the bilateral ACA area and deterioration in the signal intensity of bilateral ACAs. Revascularization of the bilateral ACA regions was considered necessary, but the left STA was already used in the previous surgery. Therefore, STA-radial artery (RA)-A3 bypass using RA graft combined with right STA-MCA bypass was performed. STA-A3 bypass using an RA graft may be the optimal treatment for ischemia of the ACA region that progresses after STA-MCA bypass.

Keywords

- ▶ moyamoya disease
- ▶ anterior cerebral artery
- ▶ bypass surgery
- ▶ radial artery

Key Messages

When the ischemia of the ACA region progresses after ipsilateral STA-MCA bypass, it is difficult to perform revascularization from the viewpoint of donor artery. We performed STA-RA-A3 bypass using a RA graft for the progressive infarction in the ACA region with success.

Introduction

Moyamoya disease is a condition mainly caused by chronic stenosis of the internal carotid artery (ICA) at its terminal portion. For the decrease in blood flow in the middle cerebral artery (MCA) region, direct and indirect revascularization have been conducted.^{1,2} When the stage of moyamoya

DOI <https://doi.org/10.1055/s-0042-1750305>.
ISSN 2248-9614.

© 2022. Asian Congress of Neurological Surgeons. All rights reserved.

This is an open access article published by Thieme under the terms of the Creative Commons Attribution-NonDerivative-NonCommercial-License, permitting copying and reproduction so long as the original work is given appropriate credit. Contents may not be used for commercial purposes, or adapted, remixed, transformed or built upon. (<https://creativecommons.org/licenses/by-nc-nd/4.0/>)

Thieme Medical and Scientific Publishers Pvt. Ltd., A-12, 2nd Floor, Sector 2, Noida-201301 UP, India

disease progresses and the blood flow in the anterior cerebral artery (ACA) region decreases after superficial temporal artery (STA)-MCA bypass, the ipsilateral STA has already been used for revascularization and it is difficult to harvest a donor vessel. Herein, we report the clinical course and surgical procedure of a patient which the ischemia of the ACA region progressed after STA-MCA bypass and we performed contralateral STA-radial artery (RA)-A3 bypass using a RA graft.

Case Report

History

A 55-year-old woman with past medical history of hypertension, diabetes mellitus and dyslipidemia, was aware of right hemiparesis. The neurological findings at the time of admission showed moderate right hemiparesis. Diffusion-weighted magnetic resonance (MR) imaging (DWI) showed ischemic stroke in the bilateral frontal lobe, especially in the left side (►Fig. 1A). Cerebral angiography showed that the terminal part of the bilateral ICA was narrowed, bilateral M1 stenosis was severe, and the blood flow to the MCA areas was poor. Bilateral ACA area was supplied via left A1, and the

stenosis of the left A1 was mild (►Fig. 1B, C). Based on the above results, this patient was diagnosed with moyamoya disease in the third stage of Suzuki's angiographic classification. Since the ischemia of the left cerebral hemisphere was more severe than the right, we decided to conduct left STA-MCA anastomosis first and then the right side, to prevent cerebrovascular events. We conducted left STA-MCA anastomosis, and postoperative course was good with no ischemic or hemorrhagic complications and MR angiography showed good patency of the bypass (►Fig. 1D). The patient was followed at outpatient clinic receiving medical treatment.

About 2 months after the operation, symptoms such as ambiguous memory, inability to calculate, and decreased motivation appeared. DWI showed acute infarction in the bilateral ACA region, especially in the left side (►Fig. 1E). In addition, MR angiography showed deterioration in signal intensity of bilateral ACAs (►Fig. 1F). Since medical treatment had already been conducted, revascularization of bilateral ACA region was considered necessary. We decided to perform revascularization surgery to the bilateral ACA area in addition to the right STA-MCA bypass. We conducted STA-RA-A3 bypass using RA graft so the bilateral ACA areas are refluxed from the right side.

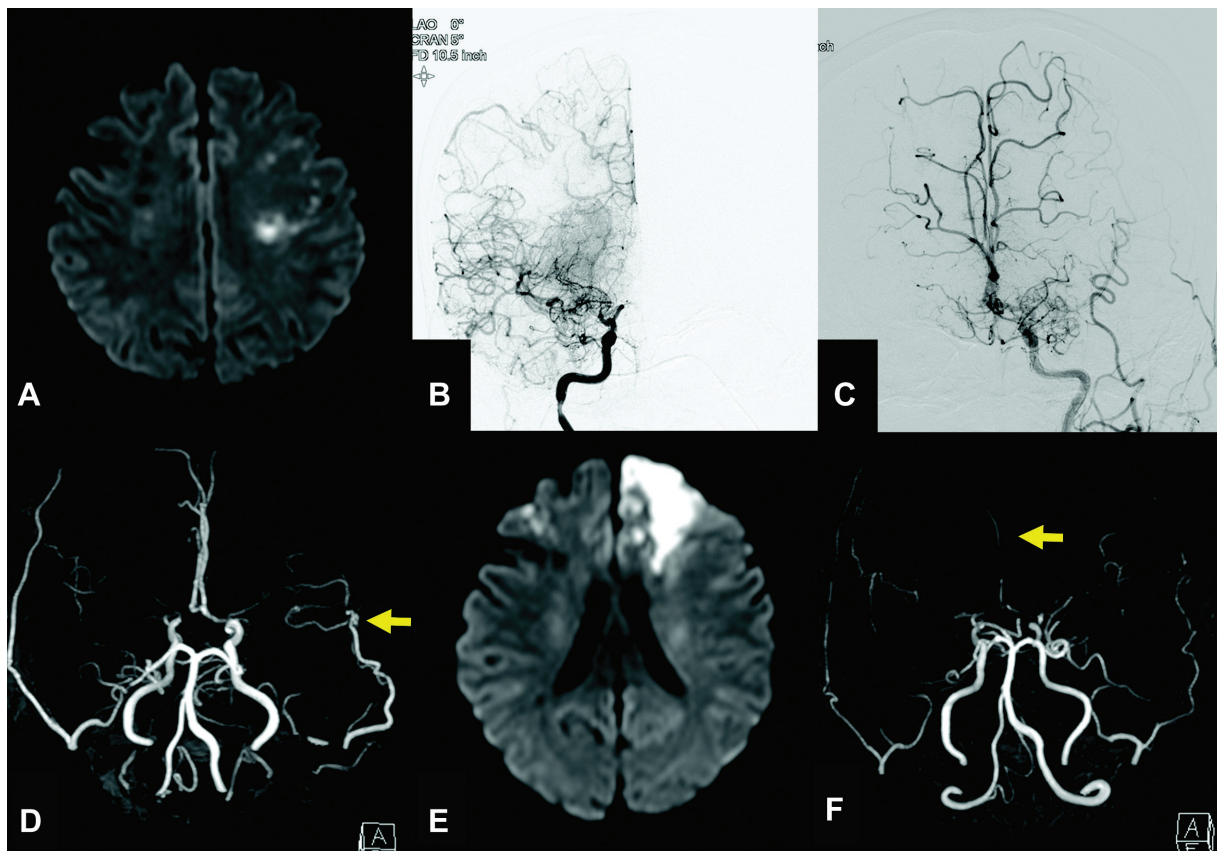


Fig. 1 Preoperative and postoperative imaging of the first surgery: (A) Preoperative diffusion-weighted imaging (DWI) showed ischemic stroke in the bilateral frontal lobe, especially in the left side. (B) Preoperative right internal carotid angiography showed that the terminal part of the right internal carotid artery (ICA) was narrowed and the right M1 stenosis was severe. (C) Preoperative left internal carotid angiography showed that the left M1 stenosis was severe and the blood flow to the middle cerebral artery (MCA) areas was poorer than the right side. Bilateral anterior cerebral artery (ACA) area was supplied via left A1, and the stenosis of the left A1 was mild. (D) Postoperative magnetic resonance (MR) angiography showed good patency of left superficial temporal artery (STA)-MCA bypass (arrow). (E) DWI performed 2 months after the first operation showed acute infarction in the bilateral ACA region, especially in the left side. (F) MR angiography showed deterioration in signal intensity of bilateral ACAs (arrow).

Neuroanesthesia was induced and the patient was placed in the supine lateral position. We designed a curved skin incision along the parietal branch of right STA. The parietal branch of STA was harvested under the microscope. The skin incision was extended to the midline, the skin flap was flipped, and the frontal branch of STA was exposed approximately 2 cm from the back side of the flap. At the same time, we prepared to harvest the RA of the left forearm. The frontal and temporal craniotomies were made. After making dural incisions, STA parietal branch was anastomosed to the temporal M4 (→Fig. 2A). After opening the interhemispheric fissure, the right A3 was confirmed and RA was anastomosed

to the A3 (→Fig. 2B). And then, the proximal part of the RA and the STA frontal branch were anastomosed end to end. The patency of the bypass flow was confirmed by the microvascular Doppler and the operation was completed (→Fig. 2C).

Postoperative DWI showed no ischemic stroke and cerebral angiography demonstrated that blood flow in the right ACA region was supplied via STA-RA-A3 bypass, and the flow of the left ACA region was also supplied from the bypass through the anterior communicating artery (ACoA) to some extent (→Fig. 2D). Transient right hemiparesis appeared, but the symptom improved soon and the patient was transferred

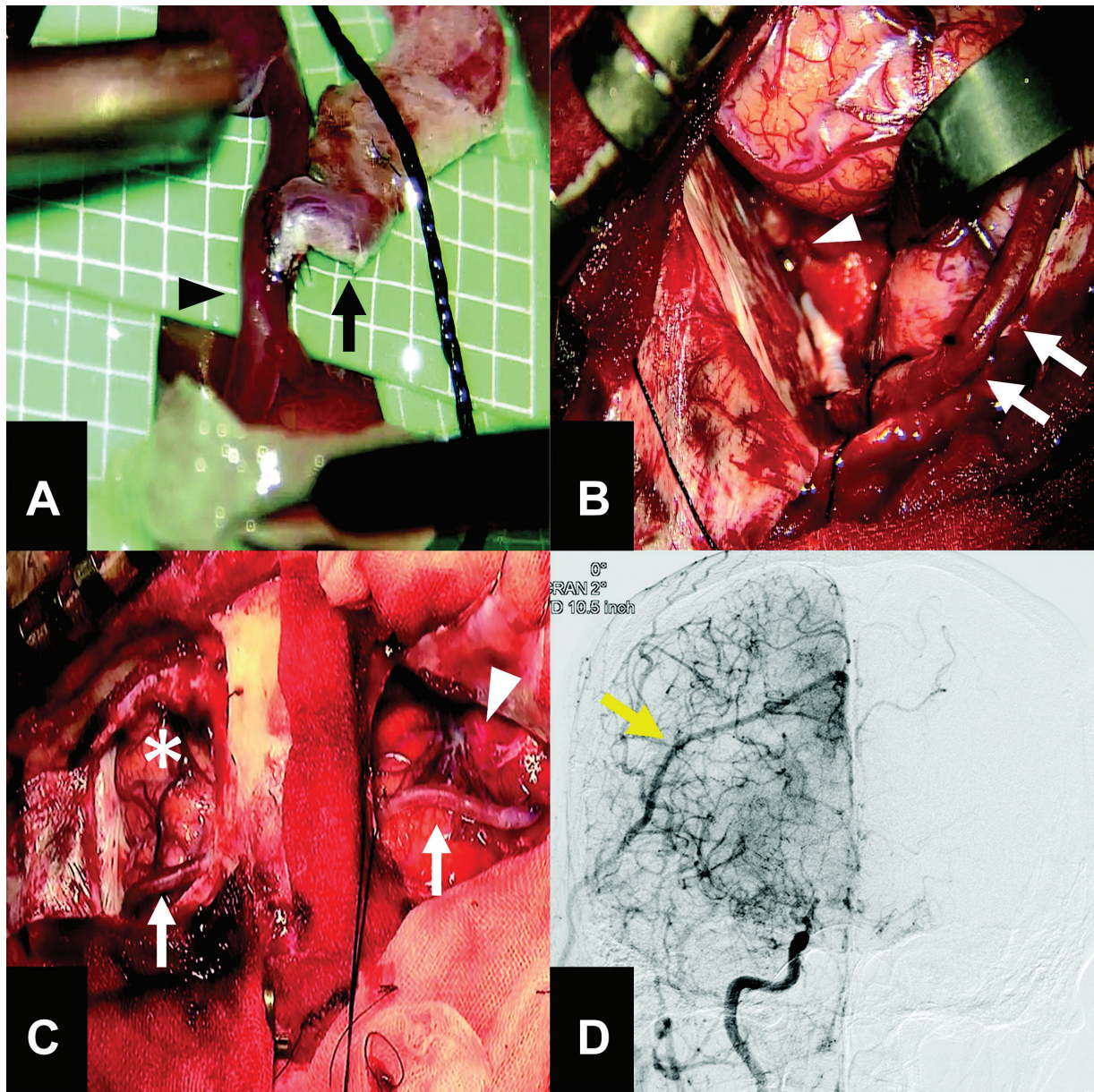


Fig. 2 Intraoperative photographs and postoperative imaging of the second surgery: (A) Superficial temporal artery (STA) parietal branch (arrow) and the temporal M4 (arrowhead) were anastomosed with 10-0 nylon. (B) The radial artery (RA, arrows) and the right A3 (arrowhead) were anastomosed with 8-0 nylon. (C) Final view of the surgery. The RA (arrows) connecting the STA and A3 is visible through the temporal (arrowhead) and frontal (asterisk) craniotomies. (D) Postoperative cerebral angiography showed good bypass patency (arrow) and cerebral blood flow in the right anterior cerebral artery (ACA) region was supplied via STA-RA-A3 bypass and the flow of the left ACA region was supplied from the bypass through the anterior communicating artery to some extent.

to a hospital for rehabilitation. A few months after the operation, the patient was able to carry out daily activities on her own. The patient was followed in the outpatient hospital without any sign of stroke recurrence on MR imaging for more than 4 years.

Discussion

Moyamoya disease is a condition mainly caused by the stenosis of the terminal parts of the bilateral ICA, and often develops into cerebral ischemia and hemorrhage.^{3,4} Direct revascularization such as STA-MCA bypass¹ and indirect revascularization as encephalo-duro-arterio-myo-synangiosis procedure² have been established as surgical procedures for the prevention of vascular events for moyamoya disease.

In this case, the patient suffered frontal lobe infarction in the ACA region 2 months after STA-MCA bypass surgery. There are few reports of this type of infarction, although cerebral ischemia is a known complication of bypass surgery for moyamoya disease.^{5,6} In the previous report, the infarction of ACA region occurred 3 to 4 days after the surgery, and the mechanism was considered that postoperative development of bypass flow had stimulated occlusive changes in the carotid fork and diminished moyamoya vessels, resulting in hypoperfusion in the ACA region.⁶ In our case, the infarction developed 2 months after the surgery and the progression of stenosis of A1 on the ipsilateral side of the surgery caused a new cerebral infarction in the bilateral ACA region. The mechanism of this case is considered that the stage of moyamoya disease itself progressed and the hemodynamics of the collateral circulation changed after the bypass surgery as previously reported in the past.^{7,8} Since the patient was resistant to the best medical treatment, we considered that revascularization to the ACA region was necessary.

Both direct revascularization and indirect revascularization have been reported as the surgical method of revascularization of the ACA region in moyamoya disease.^{9,10} For direct revascularization such as STA-ACA bypass, the most common method is to harvest the frontal branch of STA as much as possible and anastomose it to the cortical branch of ACA.¹¹ There have been some reports of bypass surgery for atherosclerotic lesions of the ACA area in the past. A3-A3 side to side bypass is effective for ischemia associated with stenosis of the ACA on one side,¹² but the procedure is not effective for ischemia of the ACA region on both sides. A method of directly bypassing STA and ACA has been reported,¹³ but the length of the donor is often insufficient when sutured deep into the ACA region. Therefore, the RA,¹⁴ the occipital artery,¹⁵ and the contralateral STA¹⁵ have been proposed as a method for intervening grafts. In this case, the left STA has already been used in previous surgery and direct revascularization from the ipsilateral side to the ACA region is difficult. Since the STA-MCA on the right side was planned to be performed, RA graft was used to make adequate flow to A3 from the right side that intended to provide blood flow to the opposite ACA region via the ACoA. In general, compared

with atherosclerotic cerebrovascular disease, moyamoya disease has a low frequency of collateralization via the ACoA.¹⁶ Fortunately, the ACoA was developed in this patient, and the blood flow was expected to be covered by the collateralization.

It is unclear whether STA-ACA anastomosis is required at the same time as STA-MCA bypass for all cases of adult moyamoya disease. As mentioned earlier, in pediatric cases, there is a high possibility that stage progression and pathological changes will occur, and it is expected to have an effect of improving intelligence by performing revascularization over a wide area. It seems highly invasive to perform STA-ACA bypass in all adult cases because the disease often does not progress. A long donor is required to make a bypass to the ACA region, but long harvesting of the STA frontal branch may cause postoperative wound problems due to the ischemia of the scalp. The current problem is that it is unpredictable when the stage progresses or cerebrovascular events occur. According to past reports, the existence of hypertension and dyslipidemia has been proposed as risk factors for causing cerebrovascular events in asymptomatic moyamoya disease.¹⁷ In addition, diabetes was an independent predictor of recurrent ischemic stroke in surgically treated moyamoya disease groups.¹⁸ In another report, asymptomatic adult moyamoya disease does not appear to be a much more stable disease. In particular, decreased cerebrovascular reactivity indicate progression of moyamoya disease and require regular close observation.¹⁹ This patient also had hypertension, diabetes, and dyslipidemia, which might cause the stage progression. However, since the pathophysiology has not been clarified at present, there is no choice but to carry out detailed postoperative follow-up, and detailed and large-scale analysis of risk factors is awaited in the future.

Conclusion

STA-A3 bypass using a RA graft may be optimal treatment for ischemia of the ACA region that progresses after STA-MCA bypass. Further analysis is waited for risk factors for ischemic progression in moyamoya disease that will make it possible to select the optimal treatment method.

Funding

None.

Conflict of Interest

None declared.

Declaration of Patient Consent

The authors certify that they have obtained all appropriate patient consent forms. In the form, the patient(s) has/have given his/her/their consent for his/her/their images and other clinical information to be reported in the journal. The patients understand that their names and initials will not be published and due efforts will be made to conceal their identity, but anonymity cannot be guaranteed.

References

- 1 Karasawa J, Kikuchi H, Furuse S, Kawamura J, Sakaki T. Treatment of moyamoya disease with STA-MCA anastomosis. *J Neurosurg* 1978;49(05):679–688
- 2 Kinugasa K, Mandai S, Kamata I, Sugiu K, Ohmoto T. Surgical treatment of moyamoya disease: operative technique for encephalo-duro-arterio-myo-synangiosis, its follow-up, clinical results, and angiograms. *Neurosurgery* 1993;32(04):527–531
- 3 Miyamoto S, Yoshimoto T, Hashimoto N, et al; JAM Trial Investigators. Effects of extracranial-intracranial bypass for patients with hemorrhagic moyamoya disease: results of the Japan Adult Moyamoya Trial. *Stroke* 2014;45(05):1415–1421
- 4 Suzuki J, Kodama N. Moyamoya disease—a review. *Stroke* 1983;14(01):104–109
- 5 Kazumata K, Ito M, Tokairin K, et al. The frequency of postoperative stroke in moyamoya disease following combined revascularization: a single-university series and systematic review. *J Neurosurg* 2014;121(02):432–440
- 6 Kuroda S, Houkin K, Nunomura M, Abe H. Frontal lobe infarction due to hemodynamic change after surgical revascularization in moyamoya disease—two case reports. *Neurol Med Chir (Tokyo)* 2000;40(06):315–320
- 7 Houkin K, Kamiyama H, Abe H, Takahashi A, Kuroda S. Surgical therapy for adult moyamoya disease. Can surgical revascularization prevent the recurrence of intracerebral hemorrhage? *Stroke* 1996;27(08):1342–1346
- 8 Robertson RL, Burrows PE, Barnes PD, Robson CD, Poussaint TY, Scott RM. Angiographic changes after pial synangiosis in childhood moyamoya disease. *AJNR Am J Neuroradiol* 1997;18(05):837–845
- 9 Iwama T, Hashimoto N, Miyake H, Yonekawa Y. Direct revascularization to the anterior cerebral artery territory in patients with moyamoya disease: report of five cases. *Neurosurgery* 1998;42(05):1157–1161, discussion 1161–1162
- 10 Suzuki Y, Negoro M, Shibuya M, Yoshida J, Negoro T, Watanabe K. Surgical treatment for pediatric moyamoya disease: use of the superficial temporal artery for both areas supplied by the anterior and middle cerebral arteries. *Neurosurgery* 1997;40(02):324–329, discussion 329–330
- 11 Ishikawa T, Kamiyama H, Kuroda S, Yasuda H, Nakayama N, Takizawa K. Simultaneous superficial temporal artery to middle cerebral or anterior cerebral artery bypass with pan-synangiosis for Moyamoya disease covering both anterior and middle cerebral artery territories. *Neurol Med Chir (Tokyo)* 2006;46(09):462–468
- 12 Ikeda A, Okada T, Shibuya M, et al. Revascularization of the anterior cerebral artery. Report of two cases. *J Neurosurg* 1985;62(04):603–606
- 13 Lee SC, Ahn JH, Kang HS, Kim JE. Revascularization for symptomatic occlusion of the anterior cerebral artery using superficial temporal artery. *J Korean Neurosurg Soc* 2013;54(06):511–514
- 14 Kiyofuji S, Inoue T, Hasegawa H, Tamura A, Saito I. A3-A3 anastomosis and superficial temporal artery-radial artery graft-A3 bypass to treat bilateral ACA steno-occlusive hemodynamic ischemia with cognitive and executive dysfunction: a technical note. *Acta Neurochir (Wien)* 2014;156(11):2085–2093, discussion 2093
- 15 Nagm A, Horiuchi T, Yanagawa T, Hongo K. Risky cerebrovascular anatomic orientation: implications for brain revascularization. *World Neurosurg* 2016;96:610.e15–610.e20
- 16 Czabanka M, Acker G, Jussen D, et al. Collateralization and ischemia in hemodynamic cerebrovascular insufficiency. *Acta Neurochir (Wien)* 2014;156(11):2051–2058, discussion 2058
- 17 Hirano Y, Miyawaki S, Imai H, et al. Association between the onset pattern of adult moyamoya disease and risk factors for stroke. *Stroke* 2020;51(10):3124–3128
- 18 Noh HJ, Kim SJ, Kim JS, et al. Long term outcome and predictors of ischemic stroke recurrence in adult moyamoya disease. *J Neurol Sci* 2015;359(1-2):381–388
- 19 Yang J, Hong JC, Oh CW, et al. Clinicoepidemiological features of asymptomatic moyamoya disease in adult patients. *J Cerebrovasc Endovasc Neurosurg* 2014;16(03):241–246