

## Aortic endograft explantation in the setting of prior heterotopic renal allograft

Khurram Rasheed, MD, and Michael C. Stoner, MD, Rochester, NY

### ABSTRACT

It is rare to require explantation of an aortic endograft placed for endovascular aneurysm repair (EVAR). Sustained aneurysm growth in the setting of prior endovascular repair, despite secondary interventions and use of adjuncts, is the most common cause of EVAR explantation. An infected endograft and aneurysm rupture after EVAR represent more urgent or emergent indications for explantation and have a significantly greater associated morbidity and mortality. This case of endograft explantation is of even greater complexity, given the patient's specific history of aneurysm repair in the concomitant setting of a functioning renal allograft. (*J Vasc Surg Cases and Innovative Techniques* 2018;4:275-7.)

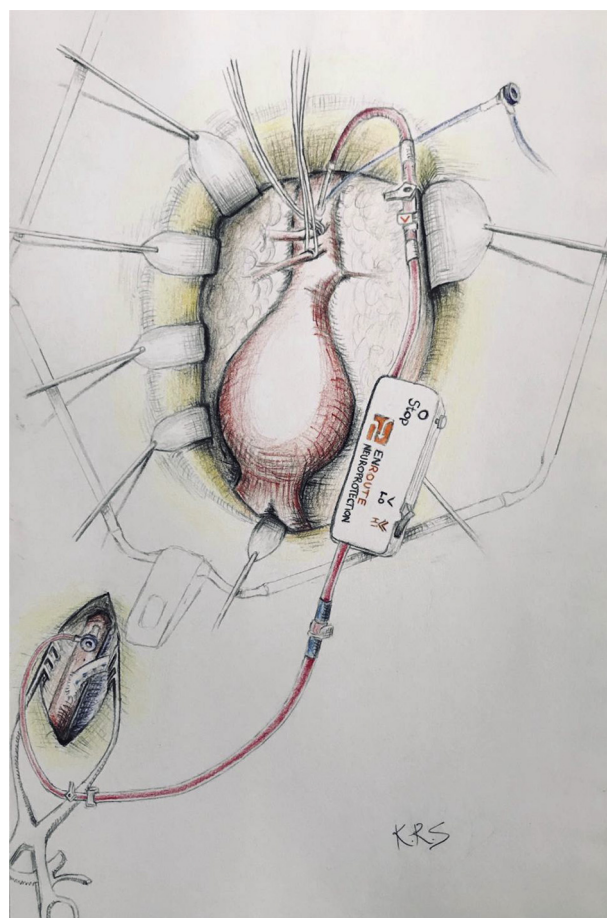
**Keywords:** Aortic aneurysm; Renal transplant; Distal perfusion; TCAR; Silk Road

### CASE REPORT

This is a case of a 66-year-old white man with a past medical history of abdominal aortic aneurysm, atrial fibrillation, coronary artery disease with ischemic cardiomyopathy, chronic renal failure, congestive heart failure, hypertension, and hyperlipidemia. Past surgical history includes four-vessel coronary artery bypass grafting, and he received a deceased donor renal transplant more than two decades ago, implanted on the right external iliac artery.

In regard to his abdominal aortic aneurysm repair, 3 years earlier he underwent endovascular aneurysm repair (EVAR) of a 5.6-cm infrarenal aortic aneurysm with a Zenith Renu 28- × 108-mm aortouni-iliac endograft (Cook Medical, Bloomington, Ind). The aortouni-iliac endograft was performed because of a critical stenosis of the left common iliac artery not amenable to endovascular intervention. The repair was completed with a 13- × 57-mm right iliac extension limb, short of the renal transplant, and a right-left femoral crossover bypass graft. The endograft was deployed distal to the superior mesenteric artery, covering the diminutive native renal arteries.

The patient presented to the clinic after undergoing annual endograft surveillance with duplex ultrasound, notable for increased residual sac size. This was confirmed on computed tomography angiography, which demonstrated a type IA



**Fig 1.** Schematic of intraoperative setup.

From the Division of Vascular Surgery, University of Rochester.

Author conflict of interest: M.C.S. serves as a case proctor for Silk Road Medical.

Presented at the Forty-fifth Annual Symposium of the Society for Clinical Vascular Surgery, Lake Buena Vista, Fla, March 18-22, 2017.

Correspondence: Michael C. Stoner, MD, Division of Vascular Surgery, University of Rochester, 601 Elmwood Ave, Box 652, Rochester, NY 14624 (e-mail: [michael\\_stoner@urmc.rochester.edu](mailto:michael_stoner@urmc.rochester.edu)).

The editors and reviewers of this article have no relevant financial relationships to disclose per the Journal policy that requires reviewers to decline review of any manuscript for which they may have a conflict of interest.

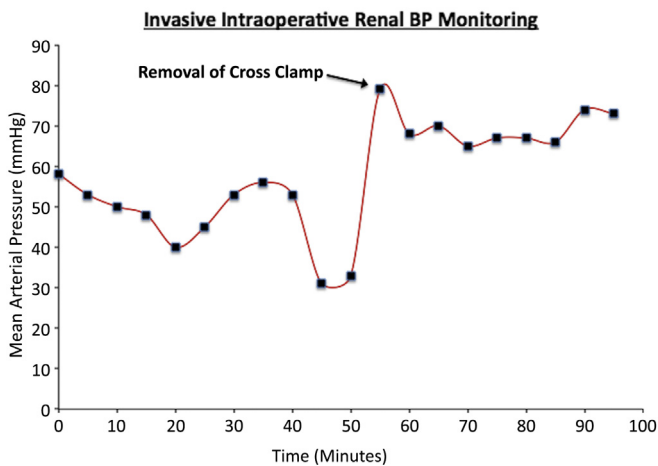
2468-4287

© 2018 The Author(s). Published by Elsevier Inc. on behalf of Society for Vascular Surgery. This is an open access article under the CC BY-NC-ND license (<http://creativecommons.org/licenses/by-nc-nd/4.0/>).

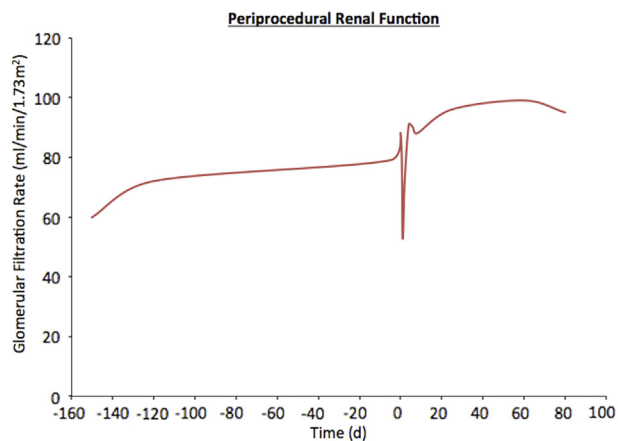
<https://doi.org/10.1016/j.jvscit.2018.08.009>

endoleak, with his aneurysm growing in size to 5.9 cm. This demonstrated an increase in size compared with prior surveillance studies, warranting surgical intervention.

Multiple strategies were entertained to protect the renal allograft from ischemic injury. A fix with a proximal aortic endocuff was not feasible as it would entail coverage of the visceral vessels. Anatomic constraints precluded fenestrated or branched



**Fig 2.** A pressure waveform was transduced at the external iliac artery, allowing continuous operative pressure monitoring. BP, Blood pressure.



**Fig 3.** Renal function represented as glomerular filtration rate over time. Day 0 notes the day of surgery.

endograft repair. EVAR explantation with a temporary right axillary-femoral artery bypass was considered.

A retroperitoneal approach with an incision through the tenth interspace was made to allow exposure of the visceral and infrarenal aorta. The left renolumbar vein was ligated, as was the atretic left renal artery since it was perfusing a nonfunctioning kidney. Dissection was carried to expose the distal descending thoracic aorta and the visceral arteries down to the aortic bifurcation. A longitudinal incision over the right groin was made to expose the prior femoral crossover graft and the right external iliac artery. At this juncture, the Enroute Transcarotid Neuroprotection System (Silk Road Medical, Sunnyvale, Calif) was used as a passive shunt, securing it at the distal thoracic aorta proximally and onto the right external iliac distally (Fig 1). Benchtop testing demonstrated a peak flow rate of 400 mL/min at the expected pressure gradients. A pressure waveform was transduced at the external iliac artery and allowed continuous pressure monitoring during the case (Fig 2).

The aortic sac was opened and the endograft was ligated at its proximal sealing stent. A 24- × 12-mm bifurcated Dacron graft was used. The proximal anastomosis posed a challenge, requiring several hemostatic maneuvers along with Creech aortic stitches to keep the anastomosis intact. Distally, the endograft was transected at the level of the iliac limb to which the bypass graft was directly sewn in an end-to-end fashion. Flow was then restored to the right side and confirmed with the pre-existing arterial transducer (Fig 2). On the left, the graft was sewn end to side to the external iliac artery. The femoral crossover graft was subsequently ligated, and perfusion was confirmed within the mesenteric vessels, bypass graft, and both feet. The perfusion cannulas were then removed and access sites repaired. The retroperitoneal incision was closed in standard fashion, and the chest was closed over a 36F thoracotomy tube.

The patient's perioperative renal function remained stable, with no significant changes in creatinine concentration, glomerular filtration rate, or urine output (Fig 3). The patient consented to publication of the details of the case and related images included in the report.

## DISCUSSION

EVAR explantation with open aneurysm repair is rare but with significant morbidity and mortality. One experience reported 5% explantation rate during a median length of 41 months, with endoleak not amenable to further endovascular repair being the most common cause at 82%.<sup>1</sup> EVAR explantation is a morbid procedure with elective 30-day mortality rate reported up to 10% and considerably greater if urgent or emergent, 37% to 56%.<sup>1,2</sup>

This report describes a unique and novel use of the Enroute Transcarotid Neuroprotection System as an intraoperative shunt to maintain distal perfusion to a critical organ in the setting of proximal aortic cross-clamping during EVAR explantation to mitigate organ injury and overall risk of morbidity and mortality. In other settings, such as thoracoabdominal aortic aneurysm repair, the use of inline shunts through a proximally sewn sidearm and distal perfusion cannula has been described to maintain visceral or pelvic perfusion with improved outcomes.<sup>3,4</sup> Although the use of a temporary inline shunt was considered, there were two major limitations: first, a lack of continuous pressure monitoring; and second, the risk of disrupting the renal allograft-iliac anastomosis with a traditional cannula.

The benefit of using the Silk Road device, as an adjunct, was its expediency in the setup, adding little time to the procedure. In addition, it allowed improved safety with objective monitoring of renal perfusion while the aorta was cross-clamped and also nullified any thromboembolic risk. On completion, given its minimally invasive design, device removal is simple. In this case, there was a transient drop in renal function postoperatively that resolved within 24 hours.

The application and benefits of extant technology available to vascular surgeons outside of its particular indications for use are highlighted in this case. The efficacy of using the Silk Road device as a temporary intraprocedural shunt was demonstrated by preserved allograft function postprocedurally and during short-term and midterm follow-up. In the instance in which an inline shunt with the capacity for continuous blood pressure monitoring may be advantageous, the Enroute Transcarotid Neuroprotection System offers an elegant solution.

## REFERENCES

1. Turney EJ, Steenberge SP, Lyden SP, Eagleton MJ, Srivastava SD, Sarac TP, et al. Late graft explants in endovascular aneurysm repair. *J Vasc Surg* 2014;59:886-93.
2. Moulakakis KG, Dalainas I, Mylonas S, Giannakopoulos TG, Avgerinos ED, Liapis CD. Conversion to open repair after endografting for abdominal aortic aneurysm: a review of causes, incidence, results, and surgical techniques of reconstruction. *J Endovasc Ther* 2010;17:694-702.
3. Cambria RP, Davison JK, Giglia JS, Gertler JP. Mesenteric shunting decreases visceral ischemia during thoracoabdominal aneurysm repair. *J Vasc Surg* 1998;27:745-9.
4. Ouriel K. The use of an aortoiliac side-arm conduit to maintain distal perfusion during thoracoabdominal aortic aneurysm repair. *J Vasc Surg* 2003;37:214-8.

Submitted Jun 11, 2018; accepted Aug 17, 2018.