

Case report: Multimodality imaging of van Neck-Odelberg disease

Luca Macarini, Tania Lallo, Paola Milillo, Silvana Muscarella, Roberta Vinci, Luca P Stoppino

Department of Diagnostic Imaging, University of Foggia, Ospedali Riuniti Hospital, Viale L. Pinto, 1-71100 - Foggia, Italy

Correspondence: Dr. Luca P. Stoppino, Department of Diagnostic Imaging, University of Foggia, Ospedali Riuniti Hospital, Viale L. Pinto, 1-71100 - Foggia, Italy. E-mail: l.stoppino@unifg.it

Abstract

Synchondrosis ischiopubic syndrome (SIS), also known as van Neck–Odelberg disease, is a syndrome characterized by an atypical ossification pattern of the ischiopubic synchondrosis. Its radiological features may mimic stress fracture, neoplasm, osteomyelitis, or posttraumatic osteolysis, causing problems in diagnosis, sometimes leading to unnecessary workup. We report two cases in which the correlation between the clinical and multimodality imaging data enabled the correct diagnosis of SIS.

Key words: Hip pain; ischiopubic synchondrosis; van Neck–Odelberg disease

Introduction

Ischiopubic synchondrosis (IPS) is the junction between the inferior ischial and pubic rami and is principally composed of hyaline cartilage.^[1,2] It is a temporary joint, occurring in childhood prior to fusion of the ischial and pubic bones. With skeletal maturation, like all synchondroses, it becomes thinner and then obliterates, either due to bony union or synostosis.^[2] IPS closure is somewhat variable and is typically completed before puberty. In early childhood, enlargement of this synchondrosis is bilateral; however, in older children, it is commonly unilateral. Usually, the fusion of the ischial and pubic bones develops without any clinical symptoms. However, sometimes children may have pain in the hip, in the groin, or in the gluteal region, resulting in limitation in the movement of the hip joint and limping.^[3-8] These clinical features of the synchondrosis ischiopubic syndrome (SIS) are nonspecific and create problems in the differential diagnosis of equivocal findings on plain radiographs. Odelberg (1923) and van Neck (1924)

described radiographic changes of SIS as swelling and demineralization of the ischiopubic fusion zone and referred to this entity as “osteochondritis ischiopubica.”^[9,10] We report here two children with acute hemipelvis pain who were correctly diagnosed to have SIS.

Case Reports

Case 1

An 8-year-old boy with left foot dominance presented with acute pain in the right ischiopubic region, with a limp for 1 month. There was no history of trauma. There was no palpable swelling of the IPS, and contractures of the adductor muscles were not observed with either rectal or external palpation. He had never been treated with antibiotics. Laboratory tests revealed a slight increase in the C-reactive protein (CRP) and the erythrocyte sedimentation rate (ESR). Anti-streptolysin-O (ASO) titer was normal. Anteroposterior radiographs of the pelvis showed an enlarged right IPS characterized by focal areas of osteolysis [Figure 1 A,B]. Pelvic MRI performed on a 1.5-T scanner (Philips Intera Achieva, Philips Medical Systems, Best, The Netherlands) showed edema of the perilesional soft tissue and muscles and “fibrous bridging,” a hypointense band-like structure perpendicular to the pubic axis [Figure 2 A-C]. A CT scan study, using a 64-detector row unit (Aquilion 64, Toshiba Medical Systems, Tokyo, Japan) better defined the areas of demineralization at the edges of the synchondrosis with associated sclerosis and irregular edges [Figure 3]. A remarkable improvement in symptoms was observed after 3 weeks of anti-inflammatory therapy and bed rest. One

Access this article online

Quick Response Code:



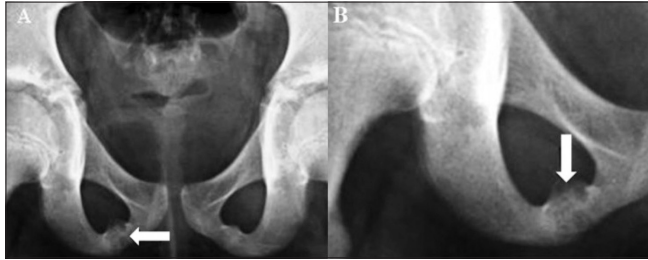
Website:
www.ijri.org

DOI:
10.4103/0971-3026.82286

month later, a second MRI showed a decrease in perilesional edema [Figure 4].

Case 2

A 12-year-old right-footed male presented with left hip pain and inability to walk. He denied traumatic events and reported difficulty in playing football. Moreover, he had never been treated with antibiotics or anti-inflammatory drugs. Laboratory tests were unremarkable except for a slight increase in CRP. ASO titer was also normal.

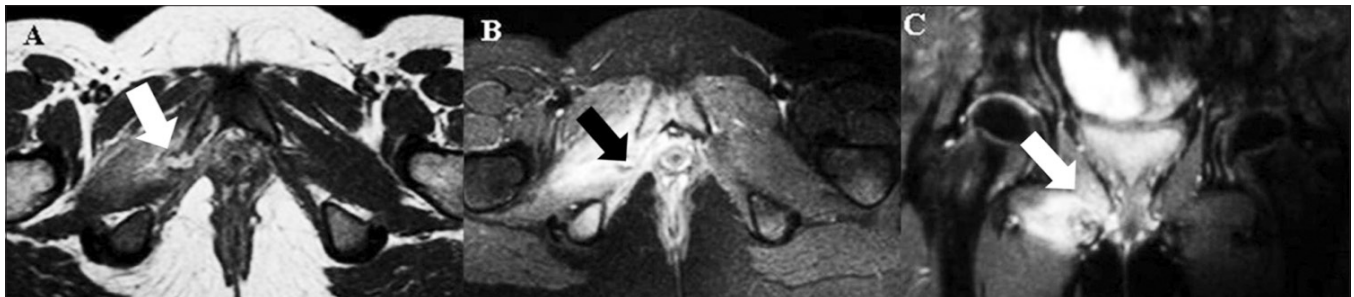


Figures 1 (A,B): Anteroposterior pelvic radiograph (A) showing both ischiopubic rami and a magnified view (B) of the right ramus show an enlarged right ischiopubic synchondrosis (IPS) with osteolysis and lucencies (arrows)

Radiographs of the pelvis showed rarefaction of the left IPS with irregular and puffy bone edges [Figure 5]. A CT scan demonstrated diastasis with sclerotic borders [Figure 6]. MRI revealed fusiform enlargement of the left IPS without any soft tissue involvement [Figure 7]. After anti-inflammatory treatment and bed rest for 2 weeks, there was complete regression of symptoms.

Discussion

A radiolucent swelling at the ischiopubic fusion zone in the prepubescent skeleton was firstly described by Odelberg (1923) and Van Neck (1924) as “osteochondritis ischiopubica.”^[9,10] At present, this finding is considered a normal ossification pattern^[11] since closure of the IPS is variable and can occur at an age from 4 to 16 years. Asymmetry in closure is the rule rather than the exception. In fact, in older children, before complete ossification, a unilateral enlarged IPS is commonly seen.^[12] As reported in literature, unbalanced mechanical stress, such as kicking or jumping, may induce an inflammatory reaction and a delayed complete ossification of this synchondrosis.^[2,3,13,14] The IPS is composed of hyaline cartilage; and its cell layers, before fusion, show a strong enhancement on hematoxylin



Figures 2 (A-C): Axial turbo spin-echo (TSE) T2W (A), axial, fat-saturated, TSE T2W (B) and coronal, fat-saturated TSE T2W (C) MRI images demonstrate hyperintensity due to edema in the adjacent soft tissues (white arrows) and hyperintense signal in the right IPS centered by a hypointense band (black arrow)

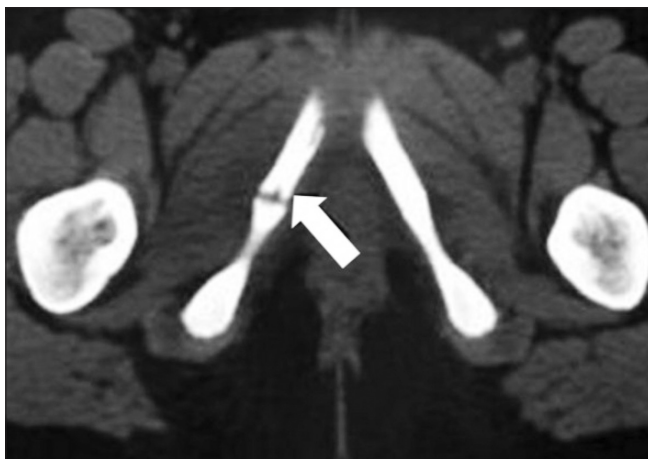


Figure 3: Axial CT scan shows IPS enlargement with irregular edges (arrow)

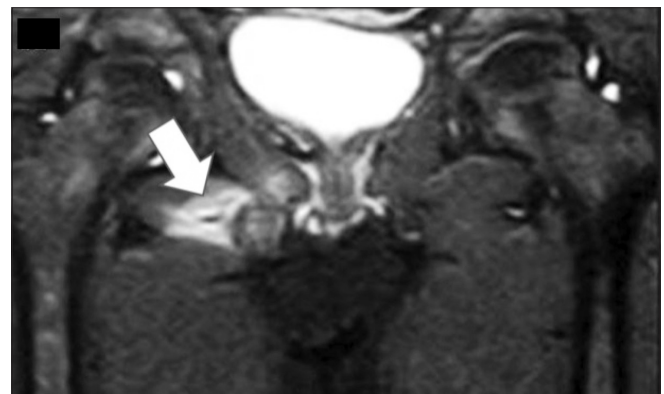

Figure 4: Coronal, fat-saturated TSE T2W MRI image after therapy (4 weeks later) shows a mild decrease in the perilesional edema (arrow)

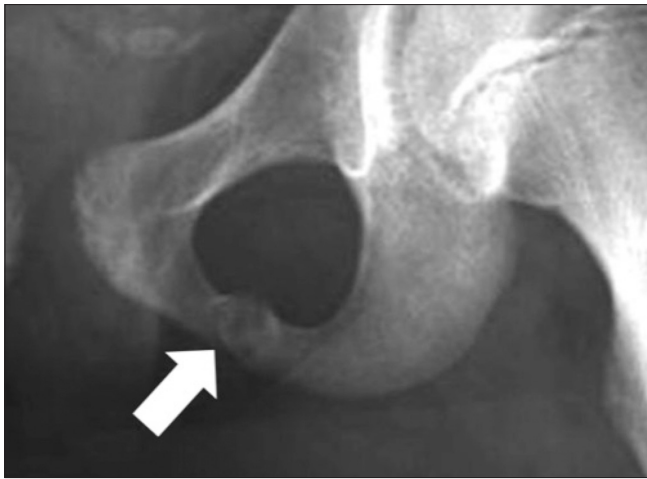

Figure 5: Anteroposterior pelvic radiograph shows enlargement of the left IPS with radiolucency (arrow)

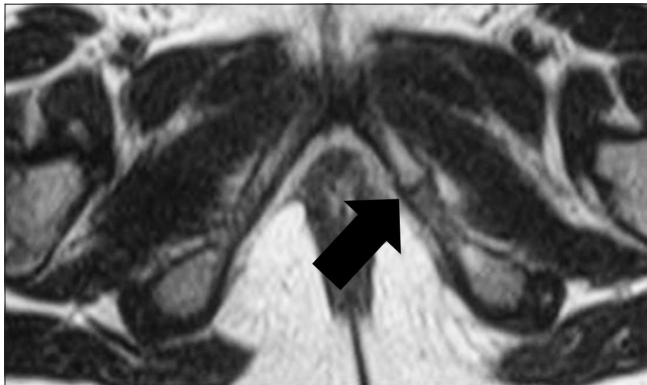


Figure 7: Axial TSE T2W MRI image demonstrates fusiform enlargement of the left IPS without any soft tissue involvement (arrow)

and eosin staining. This is typical of joints subjected to mechanical stress.

SIS involves hip pain, sometimes involving the gluteal region, causing marked limping and spontaneous tension of the adductors not related to trauma. In fact, in our two patients, we observed a slight limp and limitation in flexion and extension. In both the boys, the side of IPS correlated with foot dominance,^[15] which probably may suggest that SIS is a physiologic reaction to forces exerted on the nondominant limb during physical activity.

Its tumor-like appearance on conventional radiographs may be mistaken for stress fracture, tumor, or inflammation. The radiographs and CT scans are usually typical showing increased size with lucencies and sclerosis, as seen in our patients. The typical MRI features such as signal alteration of the bone marrow and fusiform swelling of the adjacent soft tissue were also seen in our patients. We also detected a hypointense band-like structure perpendicular to the pubic axis, defined by Herneth *et al.* as “fibrous bridging,” a typical MRI feature of this structure.^[2,16,17]

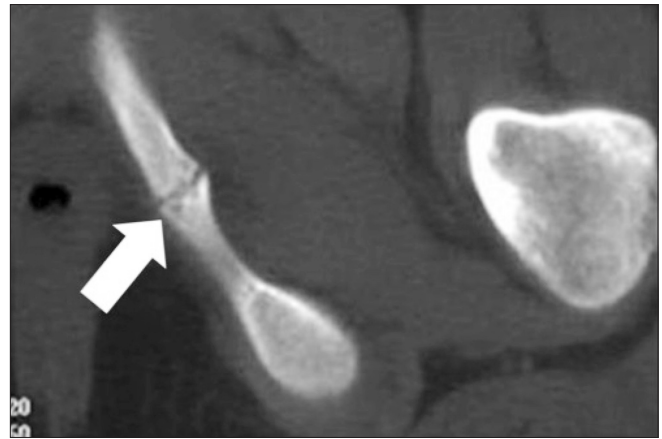


Figure 6: Axial CT scan shows delayed closure of the left IPS and irregular bone margins (arrow)

Differential diagnosis can be difficult with pubic rami stress fractures, which are very common lesions and occur in athletes, or after radiation therapy.^[2,16,17] A stress fracture typically presents with hyperintense marrow edema on T2W images and a hypointense irregular fracture line perpendicular to the long axis of the superior pubic ramus. Tumors such as Ewing’s sarcoma usually present with permeative bone destruction and extension into the soft tissues. However, according to Kloiber *et al.*,^[18] initial radiographs were useful as a baseline study to identify further demineralization and destruction that occurred in osteomyelitis. In osteomyelitis, bone destruction and abnormal soft tissue are seen^[18] with peripheral enhancement and abscess formation.^[19]

Knowledge of this condition is essential to make sure that it is not mistaken for stress fracture, infection, or tumor, in symptomatic children.

References

1. Ceroni D, Mousny M, Anooshiravani-Dumont M, Buerge-Edwards A, Kaelin A. MRI abnormalities of the ischiopubic synchondrosis in children: A case report. *Acta Orthop Belg* 2004;70:283-6.
2. Herneth AM, Trattnig S, Bader TR, Ba-Ssalamah A, Ponhold W, Wandl-Vergesslich K, *et al.* MRI imaging of the ischiopubic synchondrosis. *Magn Reson Imaging* 2000;18:519-24.
3. Keats TE. Plain film radiography: Sources of diagnostic errors. In: Resnick D, editor. *Diagnosis of Bone and Joint Disorders*. San Diego: W B Saunders; 1996. p. 27.
4. Kozlowski K, Hochberger O, Povysil B. Swollen ischiopubic synchondrosis: A dilemma for radiologist. *Australas Radiol* 1995;39:224-7.
5. Neitzschman HR. Radiology case of the month. Hip trauma. Normal physiologic asymmetric closure of the ischiopubic synchondroses. *J La State Med Soc* 1997;149:186-8.
6. Nowakowski A, Napiontek M. Aseptic necrosis of ischiopubic synchondrosis (osteochondrosis ischiopubica) as the cause of diagnostic difficulties in pathology of the infantile hip. *Chir Narzadow Ruchu Ortop Pol* 1990;55:43-5.

7. Caffey J. The neck, spine, and pelvis. In: Silverman FN, editor. *Caffey's Pediatric X-Ray Diagnosis*. Chicago: Year book; 1984. p. 334-6.
8. Thomas PS, Renton P, Hall C, Kalifa G, Dubousset J, Lalande G. Chapter 8. In: Carty H, editor. *Imaging Children*. Edinburgh: Churchill Livingstone; 1995. p. 845-1291.
9. van Neck M. Osteochondrite du pubis. *Arch Franco-Belg Chir* 1924;27:238-41.
10. Olderberg A. Some cases of destruction in the ischium of doubtful etiology. *Acta Chir Scand* 1924;56:273.
11. Rajewski F. Van Neck disease or a variation of ischio-pubic synchondrosis development?. *Chir Narzadow Ruchu Ortop Pol* 1992;57:346-8.
12. Pratje A. Über die postembryonale Entwicklung des Hüftbeines. *Z Morphol Anthropol* 1934;34:321-42.
13. Ubner L. Closure rhythm and closure disorders depend on the pathology of the hip joint (contribution to the clinical aspects of the growing pelvis). *Z Orthop Ihre Grenzgeb* 1965;100:38-91.
14. Duben W. Umbauzonen an der kindlichen Sitz-Schambeinverbindung und ihre differential diagnostische Bedeutung. *Chirug* 1950;21:148-52.
15. Herneth AM, Philipp MO, Pretterklieber ML, Balassy C, Winkelbauer FW, Beaulieu CF. Asymmetric closure of ischiopubic synchondrosis in pediatric patients: Correlation with foot dominance. *Am J Roentgenol* 2004;182:361-5.
16. Haettich B, Lebreton C, Prier A, Kaplan G. Magnetic resonance imaging of fluorosis and stress fractures due to fluoride. *Rev Rhum Mal Osteoartic* 1991;58:803-8.
17. Major NM, Helms CA. Pelvic stress injuries: The relationship between osteitis pubis (symphysis pubis stress injury) and sacroiliac abnormalities in athletes. *Skeletal Radiol* 1997;26:711-7.
18. Kloiber R, Udjus K, McIntyre W, Jarvis J. The scintigraphic and radiographic appearance of the ischiopubic synchondroses in normal children and in osteomyelitis. *Pediatr Radiol* 1988;18:57-61.
19. Oliveira F. Differential diagnosis in painful ischiopubic synchondrosis (IPS): A case report. *Iowa Orthop J* 2010;30:195-200.

Cite this article as: Macarini L, Lallo T, Milillo P, Muscarella S, Vinci R, Stoppino LP. Case report: Multimodality imaging of van Neck-Odelberg disease. *Indian J Radiol Imaging* 2011;21:107-10.

Source of Support: Nil, **Conflict of Interest:** None declared.

Author Help: Reference checking facility

The manuscript system (www.journalonweb.com) allows the authors to check and verify the accuracy and style of references. The tool checks the references with PubMed as per a predefined style. Authors are encouraged to use this facility, before submitting articles to the journal.

- The style as well as bibliographic elements should be 100% accurate, to help get the references verified from the system. Even a single spelling error or addition of issue number/month of publication will lead to an error when verifying the reference.
- Example of a correct style
Sheahan P, O'leary G, Lee G, Fitzgibbon J. Cystic cervical metastases: Incidence and diagnosis using fine needle aspiration biopsy. *Otolaryngol Head Neck Surg* 2002;127:294-8.
- Only the references from journals indexed in PubMed will be checked.
- Enter each reference in new line, without a serial number.
- Add up to a maximum of 15 references at a time.
- If the reference is correct for its bibliographic elements and punctuations, it will be shown as CORRECT and a link to the correct article in PubMed will be given.
- If any of the bibliographic elements are missing, incorrect or extra (such as issue number), it will be shown as INCORRECT and link to possible articles in PubMed will be given.