

Haematuria in association with Lynch syndrome

Marwan Ma'ayeh, Richard Power,
Deirdre Mary Fanning

Urology and Transplantation Beaumont
Hospital, Beaumont Hospital, Dublin,
Ireland

Abstract

A 40-year-old Caucasian male presented to the Emergency Department complaining of intermittent painless frank haematuria. Past medical history was significant for Hereditary Non-Polyposis Colon Cancer (HNPCC) and a prophylactic total colectomy. Computed tomography urogram showed thickening in the posterior wall of the bladder. Cystoscopy showed a small bladder mass. Histology showed a papillary urothelial neoplasm of low malignant potential. HNPCC, also known as Lynch Syndrome, is an autosomal dominant disorder responsible for 3-5% of colorectal cancers. There are certain cancers known to be associated with HNPCC; colorectal cancer, endometrial, ovarian, stomach, pancreas, biliary tract, small bowel, brain, renal pelvic and ureteric tumours, sebaceous gland adenomas and keratocanthomas. An association with bladder tumours is not well established.

Case Report

A 40-year-old Caucasian male presented to the Emergency Department complaining of intermittent painless frank haematuria over the preceding six weeks. He had no associated lower urinary tract symptoms. He was systemically well.

Past medical history was significant for hypercholesterolemia, Type 2 Diabetes Mellitus and Hereditary Non-Polyposis Colon Cancer (HNPCC). He had undergone a prophylactic total colectomy six years previously. Medications included perindopril, glucophage and atorvastatin. He has no known drug allergies. He had a positive family history of HNPCC. His father had resection of colorectal cancer on two occasions, and was subsequently diagnosed with HNPCC. None of the index patient's father's siblings underwent genetic testing, but reportedly there were cases of colorectal cancer amongst them. Genetic testing of the index patient and his six siblings showed two of the five to have Lynch gene positivity. Consequently the patient's older brother underwent a prophylactic total

colectomy aged 44 years. A first cousin of the index patient is Lynch gene positive and has undergone a prophylactic total colectomy. The patient's three children have, to date, not undergone genetic testing. He was a non-smoker and consumed approximately ten units of alcohol a week. He was married with three children. Clinical examination of the abdomen was unremarkable. Rectal examination revealed a non tender benign prostate. There were no haematological or serum biochemical abnormalities. Mid-stream urine did not show evidence of blood or infection. Computed tomography urogram showed thickening in the posterior wall of the bladder on the right side at the level of the seminal vesicles (Figure 1). Both kidneys appeared normal. A rigid cystoscopy was performed. This showed a small bladder mass over the right lateral bladder wall. The bladder mass was completely resected. Histology showed a papillary urothelial neoplasm of low malignant potential (PUNLMP). Specifically thickened bland urothelium, which focally had papillary architecture and elsewhere had an inverted growth pattern, with no visible muscularis propria and no evidence of invasion was seen. An interval rigid cystoscopy at three months showed no evidence of recurrent disease. He shall be followed with annual cystoscopic surveillance.

Discussion

HNPCC, also known as Lynch Syndrome, is an autosomal dominant cancer susceptibility disorder responsible for 3-5% of colorectal cancers.¹ It is caused by germline mutations in four mismatch repair (MMR) genes; nearly 90% in *MLH1* and *MSH2*, with the remaining 10% in *MSH6* and *PMS2*.¹ Carriers of the abnormal gene have a risk of up to 70% of developing colorectal cancer by the age of 70.² While most of these mutations are hereditary, sporadic cases are known to exist.³ There are certain cancers known to be associated with HNPCC. These include, in addition to colorectal cancer; endometrial, ovarian, stomach, pancreas, biliary tract, small bowel, brain, renal pelvic and ureteric tumours, sebaceous gland adenomas and keratocanthomas.⁴ While an association between HNPCC and bladder tumours is not as well established as the association with the above listed tumours, there are reports in the literature that suggest an association. One such case study from Japan showed a possible association between Lynch Syndrome and two cases of bladder cancer.⁵ A study from the Netherlands showed a correlation between Lynch Syndrome and urothelial bladder tumours, which was more significant when one specific MMR gene mutation – the *MSH2* gene – was causing the syndrome.⁶ In

Correspondence: Deirdre Fanning, Urology and Transplantation Beaumont Hospital, Beaumont Hospital, Dublin 9, Ireland.
Tel: +353.863862930.
E-mail : fanningdee@yahoo.co.uk

Key words: colon cancer, urological cancer, surgical oncology, hematuria, urology.

Received for publication: 28 December 2011.

Revision received: 21 February 2012.

Accepted for publication: 1 March 2012.

Contributions: MM, patient care and case report drafting; RP, patient care and case report revising; DF, patient care, case report drafting and revising.

Conflict of interest: the authors declare no potential conflicts of interest.

This work is licensed under a Creative Commons Attribution NonCommercial 3.0 License (CC BY-NC 3.0).

©Copyright M. Ma'ayeh et al., 2012
Licensee PAGEPress, Italy
Clinics and Practice 2012; 2:e41
doi:10.4081/cp.2012.e41

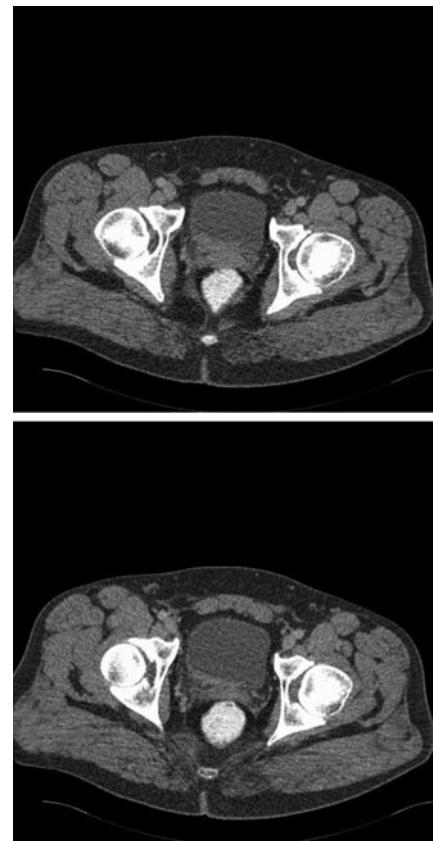


Figure 1. Transverse section of computed tomography abdomen and pelvis showing thickening of the right aspect of the posterior bladder wall at the level of the seminal vesicles.

contrast analysis of the Swedish family cancer database, showed that Lynch Syndrome patients have an increased risk of cancers in the ureter, but not in the urinary bladder.⁷ Further large-scale evaluation is necessary to establish a link between HNPCC and bladder tumours.

PUNLMP represents an indolent pathology which has a low propensity to recur, a negligible risk of progression and never results in tumour-related death.⁸ PUNLMP's should be treated similarly to low grade, non-invasive urothelial carcinoma.⁹

References

1. Lynch HT, Boland CR, Gong G, et al. Phenotypic and genotypic heterogeneity in the Lynch syndrome: diagnostic, surveillance and management implications. *Eur J Hum Genet* 2006;14:390-402.
2. Vasen HF, de Vos tot Nederveen Cappel WH. Cancer: Lynch syndrome -- how should colorectal cancer be managed? *Nat Rev Gastroenterol Hepatol* 2011;8:184-6.
3. Papadopolous N, Lindblom A. Molecular basis of HNPCC: mutations of MMR genes. *Hum Mutat* 1997;10:89-99.
4. Lindor NM, Petersen GM, Hadley DW, et al. Recommendations for the care of individuals with an inherited predisposition to Lynch syndrome: a systematic review. *JAMA* 2006;296:1507-17.
5. Kawaoka T, Miyagawa Y, Tsujihata M, et al. [Two cases of bladder cancer with hereditary nonpolyposis colon cancer.] *Hinyokika* 2011;57:319-21.[Article in Japanese].
6. van der Post RS, Kiemeny LA, Ligtenberg MJ, et al. Risk of urothelial bladder cancer in Lynch syndrome is increased, in particular among MSH2 mutation carriers. *J Med Genet* 2010;47:464-70.
7. Bermejo JL, Eng C, Hemminki K. Cancer characteristics in Swedish families fulfilling criteria for hereditary nonpolyposis colorectal cancer. *Gastroenterology* 2005;129:1889-99.
8. Pan CC, Chang YH, Chen KK, et al. Prognostic significance of the 2004 WHO/ISUP classification for prediction of recurrence, progression, and cancer-specific mortality of non-muscle invasive urothelial tumours of the urinary bladder: a clinicopathologic study of 1,515 cases. *Am J Clin Pathol* 2010;133:788-95.
9. Jones TD, Cheng L. Papillary urothelial neoplasm of low malignant potential: evolving terminology and concepts. *J Urol* 2006;175:1995-2003.