

Successful neurosurgical separation of conjoined spinal cords in pygopagus twins: illustrative cases

Chisato Yokota, MD,^{1,4} Naoki Kagawa, MD, PhD,¹ Yohei Bamba, MD, PhD,^{1,5} Yuko Tazuke, MD, PhD,² Yasuji Kitabatake, MD, PhD,³ Tomoyoshi Nakagawa, MD,¹ Ryuichi Hirayama, MD, PhD,¹ Hiroomi Okuyama, MD, PhD,² and Haruhiko Kishima, MD, PhD¹

Departments of ¹Neurosurgery, ²Pediatric Surgery, and ³Pediatrics, Osaka University Graduate School of Medicine, Suita, Osaka, Japan; ⁴Department of Neurosurgery, Suita Municipal Hospital, Suita, Osaka, Japan; and ⁵Department of Neurosurgery, Iseikai Hospital, Higashi-yodogawaku, Osaka, Japan

BACKGROUND Conjoined twins represent a rare congenital malformation. Pygopagus twins are fused at the sacrum and perineum, with union of the spine. The authors report a successful separation of a unique case of pygopagus twins sharing a U-shaped spinal cord, which the authors identified through aberrant nerves by intraoperative physiological spinal root examination.

OBSERVATIONS The 6-month-old male pygopagus conjoined twins, who were diagnosed in the prenatal period, underwent separation. They had a single dural sac containing a U-shaped continuous spinal cord; their filum terminale appeared completely fused and the anatomical border of the spinal cord was not distinguishable. A triggered electromyogram (tEMG) was used on each nerve root to determine which belonged to one twin versus the other, to detect nerve cross, and to identify functional midline cleavage. Finally, the twins were separated after spinal division. Both twins recovered uneventfully with no lower limb neurological deficits or walking impairment for 16 months.

LESSONS Pygopagus twins with a conjoined spinal cord are very rare, but a good long-term functional prognosis can be expected with successful separation. Intraoperative tEMG is useful in spinal separation surgery for twins with a conjoined spinal cord.

<https://thejns.org/doi/abs/10.3171/CASE218>

KEYWORDS conjoined twins; pygopagus; spinal separation

Conjoined twins represent a rare congenital malformation. Their frequency is known to be approximately 1 in 30,000 to 1 in 250,000 live births; >60% of all conjoined twin pregnancies are stillborn. The twins are classified by the most prominent site of union, which is well associated with mortality and functional prognosis.^{1–3} Only 6% to 19% of all conjoined twins termed as “pygopagus” are fused at the sacrum and perineum with union of the spine, rectum, urinary tract, and reproductive organs.¹ There are also abnormalities of the spine and spinal cord that require separation at the functional border. Several successful surgical separations of pygopagus twins have been reported, but only limited cases have involved conjoined spinal cords. There are a few reported cases of successful surgical separations, including spinal cords, using detailed intraoperative nerve monitoring. In addition, if aberrant nerves exist around the transitional zone, it is difficult to identify the separation plane. We report a unique case of pygopagus twins with a conjoined spinal cord in which we identified aberrant

nerves using intraoperative physiological spinal root examination and achieved successful separation.

Illustrative Cases

A 32-year-old woman was referred to our hospital at 9 weeks of gestation because of the suspicion of conjoined twins. Transvaginal ultrasound at the time of referral showed conjoined twins fused at the sacral area. Prenatal magnetic resonance imaging (MRI) was performed at 16 weeks of gestation. It demonstrated pygopagus conjoined twins with fused sacral vertebrae, spinal canal, and dural sac (Fig. 1A). The twins were otherwise normal throughout pregnancy.

The twins were delivered by elective cesarean section at 35 weeks. Their conditions at birth were satisfactory, with a combined birth weight of 4690 g, and both were male. A photograph of the conjoined twins hospitalized at 5 months of age for preoperative examination is presented in Fig. 1B. They were fused at the lumbosacral level with

ABBREVIATIONS 3D = three-dimensional; AH = abductor hallucis; AT = anterior tibial; CSF = cerebrospinal fluid; GAS = gastrocnemius; MRI = magnetic resonance imaging; tEMG = triggered electromyogram.

INCLUDE WHEN CITING Published March 1, 2021; DOI: 10.3171/CASE218.

SUBMITTED January 4, 2021. **ACCEPTED** January 8, 2021.

© 2021 The authors, CC BY-NC-ND 4.0 (<http://creativecommons.org/licenses/by-nc-nd/4.0/>).

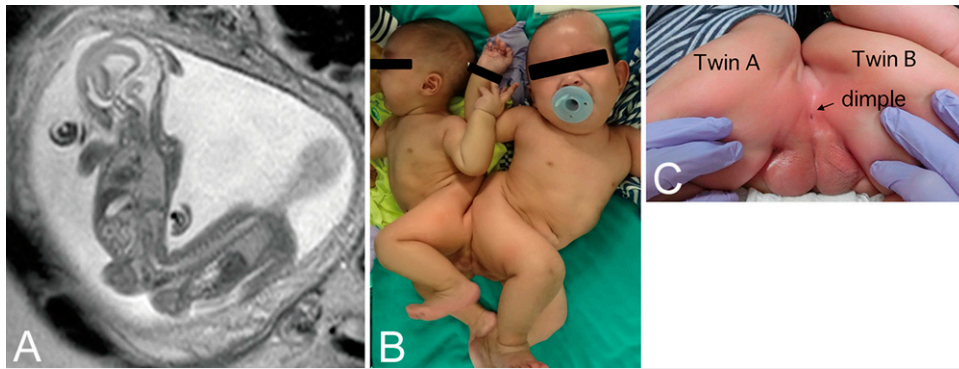


FIG. 1. A: Fetal MRI of pygopagus conjoined twins at 16 weeks of gestation. Fused buttocks and spinal canal were revealed. **B:** Photograph of pygopagus conjoined twins at 5 months of age. **C:** Preoperative perineal surface anatomy. The twins had shared skin between the back and perineum with a sacral dimple.

abnormal perineal anatomy, which showed one anus, one penis, and separate testicles. On physical examination, no motor or sensory deficit, foot deformity, or muscle atrophy was observed. Rectal radiography revealed separate gastrointestinal tracts joining in a common rectum. Urography revealed separate bladders and urinary tracts with a conjoined urethral orifice. MRI revealed a single dural sac containing a U-shaped continuous spinal cord; the filum terminale appeared fused at the first sacral vertebra, and the anatomical border of the spinal cord was not clearly delineated (Fig. 2A). Three-dimensional (3D) computed tomography images revealed fusion in the sacral region from the first sacral vertebra downward (Fig. 2B). For preoperative planning, a 3D model of the fused vertebrae and sacrum was produced using a 3D printer. This model assisted in understanding the fused bone shaping and the plane of cutting (Fig. 2C). Our multidisciplinary team, including specialists from pediatrics, anesthesiology, urology, pediatric surgery, plastic surgery, and neurosurgery, used these findings for preoperative planning, and the separation was anticipated at the age of 6 months.

Problems in growth and development were not observed during follow-up, and separation was performed as scheduled. With the patients under anesthesia, paired subdermal stainless steel needle electrodes were placed after operative site disinfection. The anterior tibial (AT), gastrocnemius (GAS), and abductor hallucis (AH) muscles were recorded in the bilateral lower extremities of each twin. Needle electrodes in the anal sphincter were not placed because of anal separation after spinal separation.

The fused sacrum was exposed via a common dorsal incision. On the basis of the 3D model and preoperative planning, the sacrum was separated at the anatomical midline, and the line of the fused sacral region from the first sacral vertebra was assessed. The sacrum and coccyx below the level of the second sacral vertebra were removed. Under magnification, the dura was opened dorsally. Adhesions between the arachnoid, dura, filum terminale, and nerve roots were divided. The filum terminale and all nerve roots appeared continuous with no adhesive bands, and it was difficult to distinguish the border between each nerve. A triggered electromyogram (tEMG) was sequentially recorded on each nerve root to distinguish which belonged to one twin versus the other (Fig. 3A). It was observed that the right GAS electrodes fired in conjunction when twin B's right leg muscles proximal to line b were stimulated (Fig. 3B), whereas the left AT electrodes fired in conjunction when twin A's left leg muscles proximal to lines a and b were stimulated (Fig. 3D). When the area between lines a and b was stimulated, however, it was observed that the right AT and AH electrodes of twin B and the left AH electrodes of twin A fired in conjunction (Fig. 3C). At first, these observations on nerve root stimulation did not guide the neurosurgeons in the identification of a safe cleavage plane. Therefore, after subdivision into bundles as small as possible, the nerve roots were sequentially stimulated to locate the area of least tEMG activity in both twins. All nerve roots were subdivided into individual nerve fibers and separated sequentially one by one on the boundary where both electromyogram activities were minimized. The filum terminale, however, was separated at the anatomical border

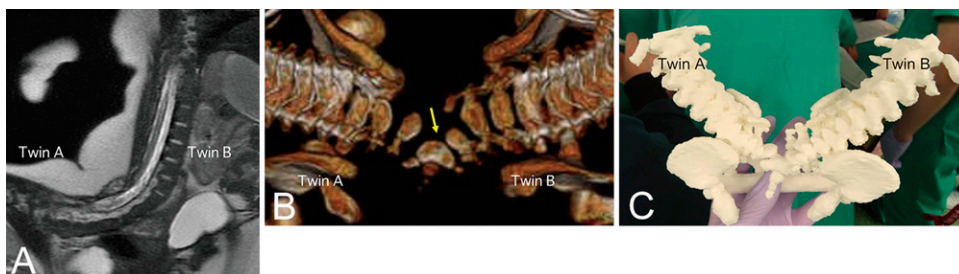


FIG. 2. Anatomy of spine and spinal cord. A: Sagittal T2-weighted MRI demonstrating fused dural sac and spinal cords. **B:** 3D computed tomography image demonstrating fusion in the sacral region from the first sacral vertebra downward (arrow). **C:** 3D printer model of fused vertebrae and sacrum for preoperative planning.

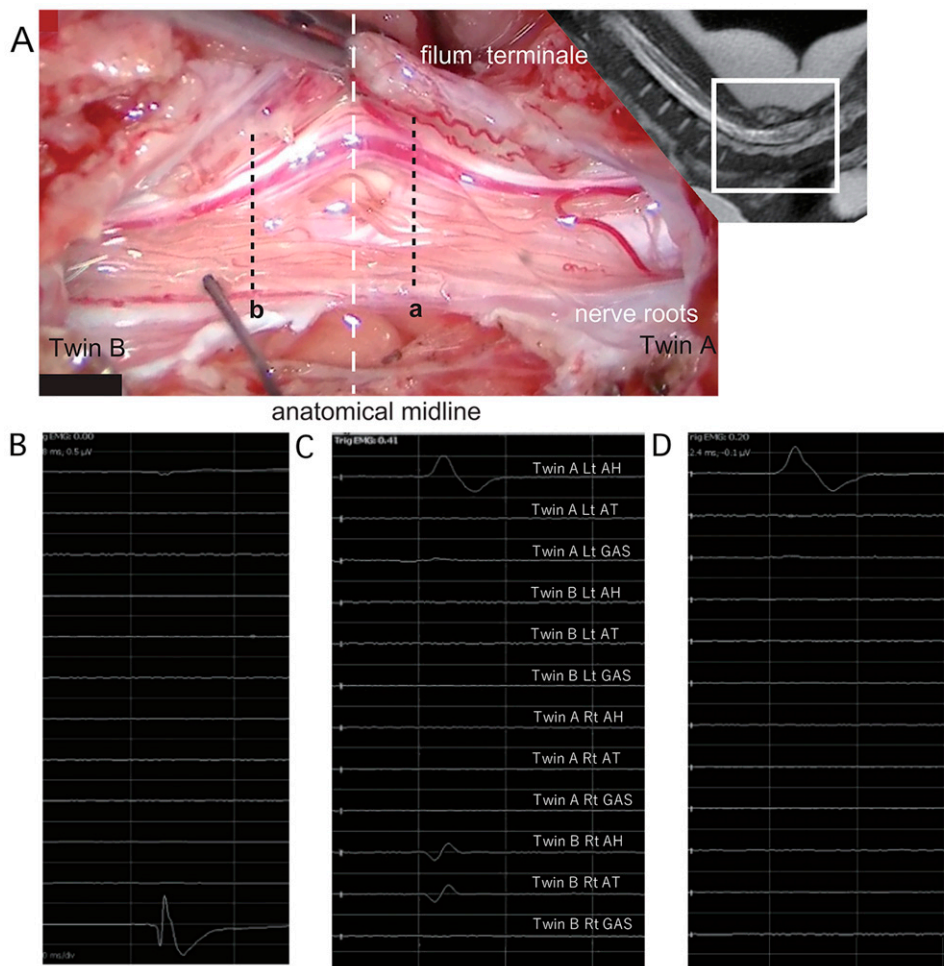


FIG. 3. Intraoperative view and screenshots of tEMG with nerve root stimulation. **A:** Points of nerve stimulation where tEMG activity was mainly recorded and the corresponding preoperative MRI image (*boxed area*). The filum terminale and all nerve roots appeared continuous between twin A and twin B. **B:** Right GAS electrodes fired in conjunction with twin B's right leg muscles when the area proximal to *line b* was stimulated. **C:** Right AT and AH electrodes of twin B and left AH electrodes of twin A fired in conjunction with both twin B's right leg muscles and twin A's left leg muscles when the area between *lines a* and *b* was stimulated. **D:** Left AT electrodes fired in conjunction with twin A's left leg muscles when the area proximal to *line a* was stimulated.

because no tEMG activity was recorded when it was stimulated near that point. After separation, each filum terminale moved rostrally. After each myeloplasty using 8-0 Prolene, the ventral dura mater was equally divided at the anatomical border, and each dural closure was performed. After dural closure, the anal, rectal, and urinary tract separations were performed, followed by final division of the remaining soft tissues, and the twins were fully separated. Both twins underwent temporary colostomy and urethroplasty followed by final fascial and skin closure.

Both twins recovered uneventfully with no neurological deficits of the lower limbs and no urinary problems, including incontinence and retention requiring catheterization. Postoperative MRI scans showed that each spinal cord was equally separated, without postoperative complications such as cerebrospinal fluid (CSF) leak or spinal cord tethering (Fig. 4). Both twins underwent anoplasties and colostomy closures 4 months after the separation.

During the years of follow-up, satisfactory development was observed in both children, without neurogenic bowel dysfunction,

including defecatory function and fecal incontinence. No deformities, laterality of motor or sensory function in the legs, or abnormal reflexes have ever been observed. Both children could stand with support at 10 months, walk with support at 14 months, and walk alone at 16 months.

Discussion

Conjoined twins is a rare congenital malformation, and only 6% to 19% are of the pygopagus type.^{1,4,5} The separation of a fused dural sac, including the spinal cord, has scarcely been reported in the literature. Although some early studies showed the incidence, conjoining patterns, and survival, no intraoperative neurophysiological data and neurological development after separation have been documented in detail. This study is the first to clarify the physiological examination data for twins and the existence of aberrant nerves in conjoined spinal cords. We emphasize that intraoperative neurophysiological examination may be useful for successful separation and a good neurological prognosis.

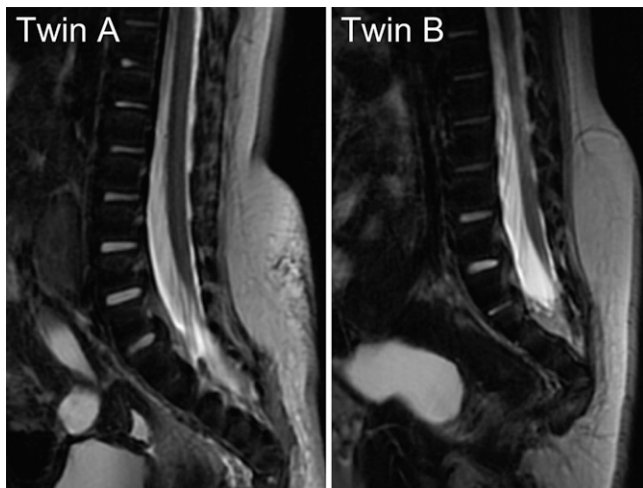


FIG. 4. Postoperative lumbar MRI scans of both twins.

The fused site of the spinal cord has been described as V-shaped, Y-shaped, and U-shaped.^{4–7} It is more difficult to distinguish the cleavage plane of twins in the U-shaped fusion, as in this case, because of the obscurity of the anatomical midline. Because the spinal cords were fused smoothly, we could not detect the cleavage plane by preoperative MRI or by intraoperative observation under magnification. Awasthi et al. reported that nonneural and nonfunctional adhesive bands have been observed between twins' cords.⁵ However, there are several reports that a fused conus should be divided in the functional midline when both twins are expected to survive.^{4,8} These adhesive bands were not observed in our case. Therefore, we tried to detect the functional midline cleavage using intraoperative tEMG.

According to previous reports, tEMG has sometimes been useful in determining the cleavage plane.^{9,10} However, in our case, we could not identify the innervation border in the crossing nerve roots. Interestingly, twins A and B showed simultaneous tEMG responses when we stimulated the nerve roots crossing between them in the common dural sac. To explain why the crossing nerve roots could activate the limb responses of twins A and B, we referred to the mechanism of the motor axon pathfinding to the limbs. The motor neuron, which resides in the lateral motor column in the developing lumbar spinal cord, innervates the limbs in accordance with the navigation of the repulsive and attractive signals from limb buds.¹¹ This mechanism is so robust that additional limbs experimentally induced by the ectopic fibroblast growth factor signals in the chick embryo could be innervated from the motor neuron of the flank-level spinal cord.¹² Therefore, considering that lower limb buds would arise closely from each spinal cord in pygopus twins, it is possible that some motor axons of one twin might aberrantly innervate the limbs of the other. Although there are no previous reports concerning the aberrant innervation of pygopus twins, cross-innervation might be a very rare phenomenon that occurs only when the anatomical conditions are appropriate to permit ligand-receptor signaling, which navigates motor neuron axons to the limbs of the counterpart. Aberrant nerves detected by tEMG may be a minor population associated with motor and sensory function of the lower extremities or with bladder function.

In addition to tEMG, the sphincter muscle function test and bulbocavernosus reflex are used as a physiological examination in spina bifida operations such as spinal lipoma or tethered cord syndrome, but

these methods were not used in this operation because of the abnormal perineal anatomy with conjoined anus and penis. A 1-year follow-up study showed no neurogenic bladder or anal sphincter dysfunction. A long-term follow-up study is understandably needed, but neurological deterioration due to retethering may be unlikely to occur because postoperative MRI scans in these cases showed that each spinal cord was equally separated and elevated without adhesive findings.

Detailed preoperative planning and multidisciplinary specialist teams consisting of pediatrics, anesthesiology, urology, pediatric surgery, plastic surgery, and neurosurgery also influenced the clinical outcome and prognosis. The 3D model was greatly useful in preoperative planning.¹¹ In our case, a neurosurgical procedure including spinal cord separation and closure of the dural sac was performed before rectal and urinary tract separation. To maintain favorable spinal function, it is important to prevent postoperative complications such as CSF infection and leakage.¹¹

Observations

We encountered a rare case of pygopus twins with U-shaped conjoined spinal cords separated successfully using intraoperative physiological root examination. Detailed intraoperative monitoring detected aberrant nerves and identified the functional midline cleavage.

Lessons

Intraoperative neurophysiological examination and avoidance of complications can be useful for successful separation and satisfactory neurological prognosis.

References

- Spitz L. Conjoined twins. *Prenat Diagn.* 2005;25:814–819.
- Spitz L. Surgery for conjoined twins. *Ann R Coll Surg Engl.* 2003; 85(4):230–235.
- Willabee BA, Mulder M, Perez EA, et al. Predictors of in-hospital mortality in newborn conjoined twins. *Surgery.* 2019;166(5):854–860.
- Hirokazu T, Takayuki I, Yoshinori H, et al. Separation surgery of pygopus asymmetrical conjoined twins sharing U-shaped spinal cord: case report and literature review. *Childs Nerv Syst.* 2013; 29(4):699–706.
- Awasthi R, Iyengar R, Rege S, Jain N. Surgical management of pygopus conjoined twins with spinal bifida. *Eur Spine J.* 2015; 24(suppl 4):S560–S563.
- Hockley AD, Gornall P, Walsh R, et al. Management of pygopus conjoined twins. *Childs Nerv Syst.* 2004;20(8-9):635–639.
- Winder M, Law A. Separation of pygopus conjoined twins: a New Zealand neurosurgical experience. *J Clin Neurosci.* 2006;13(9): 968–975.
- Fieggen G, Millar A, Rode H, et al. Spinal cord involvement in pygopus conjoined twins: case report and review of the literature. *Childs Nerv Syst.* 2003;19(3):183–187.
- Fowler CL, Pulito AR, Warf BC, Vandenbrink KD. Separation of complex pygopus conjoined twins. *J Pediatr Surg.* 1999;34(4): 619–622.
- Cromeens BP, McKinney JL, Leonard JR, et al. Pygopus conjoined twins: a neurophysiologic intraoperative monitoring schema. *J Clin Neurophysiol.* 2017;34(2):e5–e8.
- Bonanomi D, Pfaff SL. Motor axon pathfinding. *Cold Spring Harb Perspect Biol.* 2010;2(3):a001735.
- Turney BW, Rowan-Hull AM, Brown JM. The innervation of FGF-induced additional limbs in the chick embryo. *J Anat.* 2003;202(1):83–92.

Disclosures

The authors report no conflict of interest concerning the materials or methods used in this study or the findings specified in this paper.

Author Contributions

Conception and design: Kagawa, Yokota, Tazuke, Kishima. Acquisition of data: Kagawa, Yokota, Bamba, Tazuke, Kitabatake, Okuyama, Kishima. Analysis and interpretation of data: Kagawa, Yokota, Kishima. Drafting the article: Kagawa, Yokota, Bamba, Kishima. Critically revising the article: Kagawa, Yokota, Kishima. Reviewed submitted version of manuscript: Kagawa, Yokota, Nakagawa, Hirayama, Kishima. Approved the final version of the manuscript on

behalf of all authors: Kagawa. Statistical analysis: Kagawa. Administrative/technical/material support: Kagawa, Kishima. Study supervision: Kagawa, Tazuke, Kishima.

Correspondence

Naoki Kagawa: Osaka University Graduate School of Medicine, Suita, Osaka, Japan. nkagawa@nsurg.med.osaka-u.ac.jp.