

# Preliminary experience with EBA ONE intramedullary nail for the treatment of pertrochanteric fractures

Danila Oldani<sup>1</sup>, Pietro Maniscalco<sup>2</sup>

<sup>1</sup> Orthopaedic Clinic, Department of Medicine and Surgery, University Hospital of Parma, Parma, Italy; <sup>2</sup> Orthopedics and Traumatology Department, Guglielmo da Saliceto Hospital, Piacenza, Italy

**Summary.** *Background and aim of the study:* The Authors report their preliminary experience with a new fixation device for treatment of pertrochanteric fractures. The EBA ONE nail, produced by Citieffe in Bologna - Italy. *Materials:* Between April 2019 and August 2019 in Orthopedics and Traumatology Department of Piacenza, 11 patients (all female) with stable and unstable pattern of fractures, were treated with the EBA ONE intramedullary nail. *Results:* Despite the limited number of cases and the absence of a complete follow-up, the initial results are very encouraging. None of the reported complications were linked to the fixation device or to the surgical technique. *Conclusions:* The minimal, simple and intuitive instrumentation set and the simplicity of the surgical procedure make this fixation device valuable for use in stable fractures. The possibility to distal locking the nail, either statically or dynamically, and the availability of a longer nail make this device also effective in more complex fractures. ([www.actabiomedica.it](http://www.actabiomedica.it))

**Key words:** pertrochanteric fractures, Evans's classification, intramedullary nail, EBA ONE

## Introduction

Fractures of the proximal femur trochanteric region are common and are associated with increased mortality and morbidity, especially in the elderly population (1-3).

Their incidence, generally occurring after a simple fall and being associated with bone fragility, increases with age (4).

The proximal femur fractures are divided into two large groups: the lateral and the medial ones. The medials are so-called articular and include fractures of the head and neck of the femur and are generally treated with cannulated screws, endoprosthesis or arthroplasty based on the degree of decomposition, level, patient's age and associated comorbidities. The lateral fractures are those between the extrarticular portion of the base of the femoral neck and the transverse line tangent to the distal end of the small trochanter (pertrochanteric, intertrochanteric or subtrocanteric) and can be synthe-

sized with intramedullary nails or, less frequently, with plaques.

Numerous classifications exist, such as that of Evans (5) which divides lateral fractures into two categories: stable (type I 2-fragment composite, type II broken down into 2 fragments) and unstable (type 3 with 3 fragments without posterolateral support, type IV a 3 fragments without medial support and type V with 4 fragments) (Fig.1) or the most recent classification AO-OTA (6) which classifies them as fractures 31-A. These fractures are divided into three groups, each of which is in turn divided into subgroups based on the obliquity of the fracture rhyme and the degree of comminution. Group 1 fractures are simple fractures with two fragments and good support in the medial cortex. Type 2 fractures they are plurifragmentary and affect the medial and dorsal cortices (small trochanter). Type 3 fractures are the oblique reverse ones, where the lateral cortex is also involved (Fig. 2).

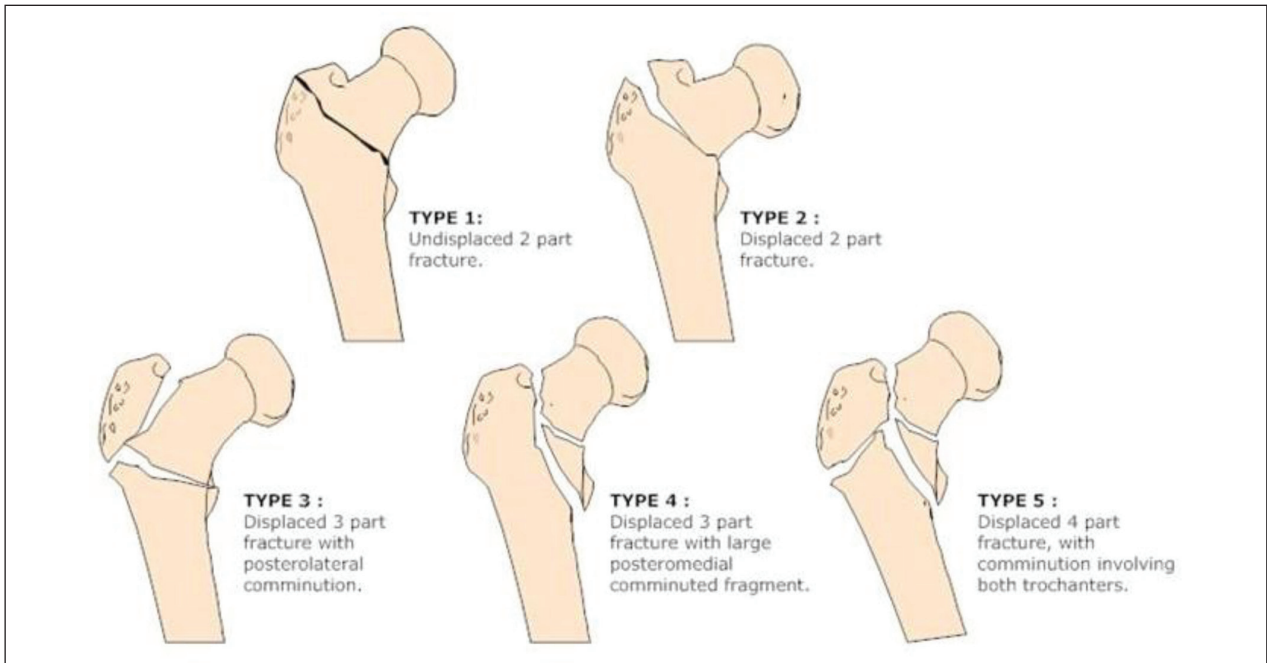


Figure 1. Evan's classification

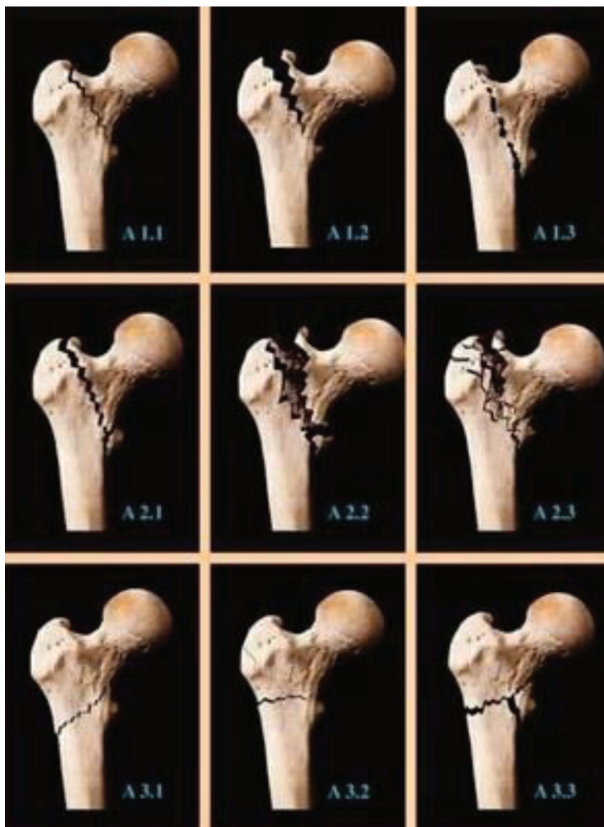


Figure 2. AO classification

Surgery is still considered as the gold standard of treatment in this elderly, frail patient cohort (7, 8), with the time to surgery parameter to be a determinant in terms of mortality rate and functional recovery (9).

A number of studies have reported improved outcomes when surgery is conducted within 48 hours from the point of admission (10, 11).

**Materials and Methods**

Between April 2019 and August 2019 11 patients (all female) who sustained a pertrochanteric fracture, following accidental fall, were operated.

The mean age was 87 years (range 75-97 years).

Fractures stability was assessed according to the Evan's classification (5).

All patient were operated within 48 hours of arrival at the hospital. Prophylactic intravenous first generation cephalosporin was administered before operation and all patient received anticoagulant prophylactic therapy with molecular weight heparin.

Post-operatively, all patients had weight-bearing as tolerated and evaluated by physiotherapist the first post-operative day or when medically stable.

The EBA ONE nail is a single cephalic screw nailing system available both in the standard and long version, and is indicated for the treatment of pertrochanteric fractures, stable and unstable, intertrochanteric and subtrochanteric fractures.

The nail is cannulated for Guide-Wire controlled insertion and is made of a titanium alloy ASTM F136. The lateral surface of the stem is leveled so as to favor a balancing of the stress peaks in the middle lateral direction and allow an optimal distribution of the synthesis medium: this peculiarity facilitates the nail insertion maneuver (Fig. 3).

The proximal diameter is 15.5 mm, distal diameter is 10 mm, anti-rotational system of the integrated cephalic screw and for the standard version length 170 mm.

Three different cervico-diaphyseal angles are available (120°, 125° and 130°), to better adapt to anatomical variations of the femoral neck.

Proximally to the hole of the cephalic screw there is another hole, dedicated to the insertion of a k-wire parallel to the cephalic screw which thus allows the



Figure 3. Eba One Nail

compaction of the fracture without the need for removal of the wire.

The diapason tip reduces the rigidity of the nail and the risk of perimplantation fractures under the nail.

The oblong hole allows for static or dynamic distal locking by inserting a single screw, that help prevent rotation in complex fractures.

## Results

The surgical technique was the same in all patient. Operation were performed on fracture table under spinal anesthesia and image intensifier control. After close reduction of the fractures a small incision (3-4 cm) started proximal to the greater trochanteric apex was made. The entry point was made just on the tip of the greater trochanter. The nail was inserted into the femoral diaphysis without reaming. The hip screw was inserted under the midline of the femoral neck and was moved up the subarticular surface of the femoral head (Fig. 4).

Distal locking was made in 4 cases.

The mean operative time was 24 minutes (range 15-35 minutes). No one had need to place blood drains.

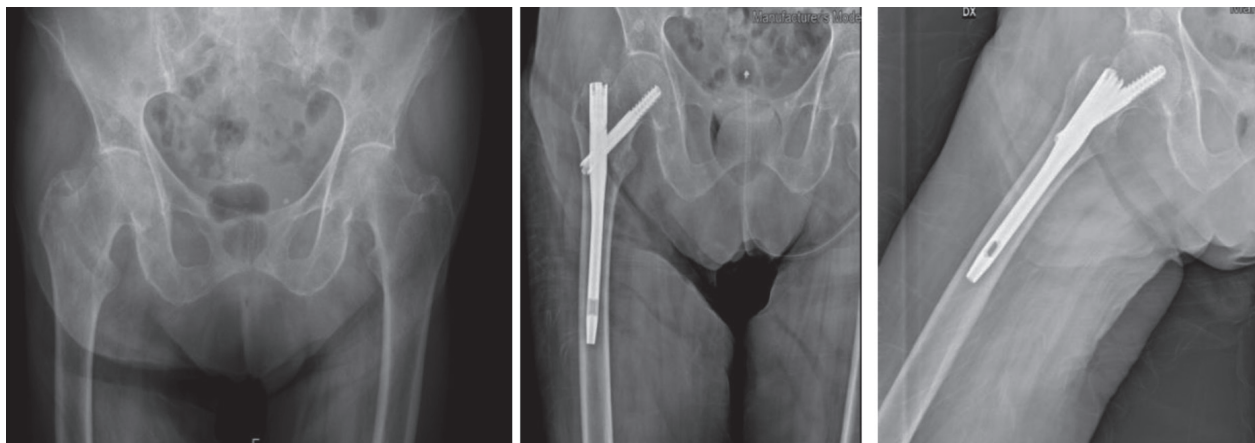
There were no intraoperative or immendiantly postoperative complication.

## Discussion

Proximal femoral fractures in elderly patients represent a very significant problem in industrialized countries in terms of increment of hospital cost, due to the aging of the population (12).

The goal of treatment is fracture reduction and stable osteosynthesis to allow immediate mobilization. For many years, the sliding hip screw and plate had been the gold standard in treating pertrochanteric fractures (13-15). Nowadays, there is an increasing interest in intramedullary nailing, especially for the unstable pertrochanteric fractures (16).

Guidelines suggest to treat hip fractures within 48 hours of presentation and also the Ministry of Health



**Figure 4.** A 78-year-old female with right intertrochanteric fracture fixed with Eba One nail

defined quantitative and qualitative standards of hospital healthcare that establishes 60% as the minimum proportion, per surgery facility within 48 hours, of patients with femur fracture >65 years of age (12).

The choice of the correct means of synthesis and the speed in the execution of the intervention are the most important factor for the therapeutic success.

Kaufer (17) argues that the implant's stability depends on 5 variables: bone quality, fragment geometry, reduction, implant, and implant placement. While all 5 variables are of importance, bone quality and fragment geometry are the product of the patient and the trauma and cannot be significantly modified by the treating surgeon. Reduction, implant placement, and implant selection are the variables which the surgeon can manipulate. Implant placement is probably the most important of the 5 variable.

When addressing the distal locking issue, some authors have stated that distal locking is not necessary for most intertrochanteric fracture (AO/OTA 31-A1 And A2); they then used their samples to confirm that unlocked nailing was safe and not associated with increased complications (18-20). Ciaffa et al (21), in a recent study, showed that unlocked nails were equivalent to static distal locked nails in terms of clinical outcomes, complication and healing time. On the contrary, unlocked nail were associated with a decrease in intraoperative variable such as operation and fluoroscopy time, surgical incision length, blood loss and also in a residual thigh pain.

The attitude at the Orthopedics and Traumatology Department of Piacenza is that distal locking is indicated only in cases of comminution of lateral wall of a greater trochanter and a large of posteromedial fragment extended distally below the lever of lesser trochanter.

## Conclusion

The EBA ONE medullary nailing system is a mean comparable to those that exist on the market, such as the most famous Gamma nail.

Is designed to facilitate minimally invasive surgery and to help increase efficiency with the aid of the state-of-the-art instrumentation and an optimized surgical technique.

The initial experience with this nail was positive: there were no immediate intraoperative and postoperative complications.

The minimal, simple and intuitive instrumentation set and the simplicity of the surgical procedure make this fixation device valuable for use in stable fractures. The possibility of the distal locking, either statically or dynamically, and the availability of a longer nail make this device also effective in more complex fractures.

**Conflict of interest:** Each author declares that he or she has no commercial associations (e.g. consultancies, stock ownership, equity interest, patent/licensing arrangement etc.) that might pose a conflict of interest in connection with the submitted article



## References

- Rossini M, Piscitelli P, Fitto F, et al. Incidenza e costi delle fratture di femore in Italia. *Reumatismo* 2005;57:97102.
- International Osteoporosis Foundation Osteoporosis in the European Community: a call for action. IOF 2001.
- Orthopaedic Trauma Association Committee for Coding and Classification. Fracture and dislocation compendium. *J Orthop Trauma* 1996;10 (suppl. 1):31-2.
- Scottish Intercollegiate Guidelines Network. Prevention and Management of hip fracture in old people. A national clinical guideline.
- Evans EM. The treatment of trochanteric fractures of the femur. *J Bone Joint Surg Br* 1949, 31:190-203.
- Muller ME, Nazarian S, Koch P, et al. The comprehensive classification of fractures of long bones. 1st ed. Berlin, Heidelberg, New York: Springer-Verlag, 1990
- Bhandari M, Devereaux PJ, Einhorn TA, Thabane L, Schemitsch EH, Koval KJ. Hip fracture evaluation with alternatives of total hip arthroplasty versus hemiarthroplasty (HEALTH): protocol for a multicentre randomised trial *BMJ Open* 2015;5(2):e006263.
- Park KS, Oh CS, Yoon TR. Comparison of minimally invasive total hip arthroplasty versus conventional hemiarthroplasty for displaced femoral neck fractures in active elderly patients. *Chonnam Med J* 2013;49:81-6.
- Daugaard CL, Jørgensen HL, Riis T, Lauritzen JB, Duus BR, van der Mark S. Is mortality after hip fracture associated with surgical delay or admission during weekends and public holidays? A retrospective study of 38,020 patients. *Acta Orthop* 2012;83:609-13.
- Nordström P, Gustafson Y, Michaëlsson K, Nordström A. Length of hospital stay after hip fracture and short term risk of death after discharge: a total cohort study in Sweden. *BMJ* 2015;350:h696.
- Holt G, Smith R, Duncan K, Hutchison JD, Gregori A. Epidemiology and outcome after hip fracture in the under 65s- Evidence from the Scottish Hip Fracture Audit. *Injury* 2008;39:1175-81.
- Navone P, Nobile M, et al. Proximal femoral fractures in elderly people: time to surgery. The experience of Milan's "ASST Pini/CTO" Injury, *Int J. Care Injured* 2017; 48:s39-43
- Doppelt SH: The sliding compression screw - today's best answer for stabilization of intertrochanteric hip fractures. *Orthop Clin North Am* 1980; 11:507-23.
- Waddell JP: Sliding screw fixation for proximal femoral fractures. *Orthop Clin North Am* 1980; 11:607-22.
- Wolfgang GL, Bryant MH, O'Neill JP: Treatment of intertrochanteric fracture of the femur using sliding screw plate fixation. *Clin Orthop* 1982; 163:148-58.
- Makridis KG, Georgaklis V, Georgioussis M Comparing two intramedullary devices for treating trochanteric fractures: a prospective study. *Journal of Orthopaedic Surgery and Research* 2010; 5:9
- Kaufer H, Sonstegard D. Stable fixation of intertrochanteric fractures. *J Bone Joint Surg Am* 1974 Jul;56(5):899-907.
- Li X, Zhang L, Hou Z, Meng Z, Chen W, Wang P, et al. Distal Locked and unlocked nailing for perthrochanteric fractures – A prospective comparative randomized study. *Int Orthop* 2015;39:1645 -52.
- Skála-Rosenbaum J, Bartoňček J, Bartoska R. Is distal locking with IMHN necessary in every perthrochanteric fracture? *Int Orthop* 2010;34(7):1041 -7.
- Vopat BG, Kane PM, Truntzer J, McClure P, Paller D, Abbood E, et al. Is distal locking of long nails for intertrochanteric fractures necessary? A Clinical study. *J Clin Orthop Trauma* 2014;5:233-9
- Ciaffa V, Vicenti G, Mori CM, Unlocked versus dynamic and static distal locked femoral nails in stable and unstable intertrochanteric fractures. A prospective study. *Injury* 2018; 49 (3): 19-25

Received: 1 October 2019

Accepted: 3 November 2019

Correspondence:

Dr. Danila Oldani

Orthopaedic Clinic, Department of Medicine and Surgery,  
University Hospital of Parma, Parma, Italy

Tel. 3202742752

E-mail: danila.oldani@studenti.unipr.it