

The Use of Radiofrequency in Aesthetic Surgery

Erez Dayan, MD*
A. Jay Burns, MD†
Rod J. Rohrich MD‡
Spero Theodorou, MD§

Summary: The use of radiofrequency for soft tissue tightening has increased over the past 10 years. Both minimally invasive and noninvasive devices are frequently in use. This article describes the different types of radiofrequency technology and the current evidence behind their safety and efficacy. (*Plast Reconstr Surg Glob Open* 2020;8:e2861; doi: 10.1097/GOX.0000000000002861; Published online 17 August 2020.)

NONINVASIVE AND MINIMALLY INVASIVE SKIN TIGHTENING

Minimally invasive and noninvasive correction of skin laxity have long been elusive goals of aesthetic surgery. Patient demand for nonsurgical skin tightening with little downtime and preservation of the epidermis has increased 600% in the past 15 years.¹ Numerous nonsurgical technologies have emerged, which function to reduce fat (ie, cryolipolysis, deoxycholic acid) and resurface skin (lasers, chemical peels, dermabrasion).^{2,3} However, the need for safe and efficacious skin tightening has not been met by these devices.

Traditionally, ablative and nonablative lasers were the primary mechanisms to improve skin laxity nonsurgically, by injuring the epidermis and dermis with resulting dermal collagen remodeling and secondary skin tightening. In properly selected patients, lasers can provide excellent skin resurfacing and dermal remodeling.^{2,3} However, the energy and subsequent heat required to generate significant skin tightening at the dermal level cannot be accomplished without injury to the epidermis—leading to complications, such as burns and irreversible pigmentation changes.⁴ For this reason, lasers are limited to lighter Fitzpatrick skin types, excluding darker-skinned patients.

Newer technologies such as high-frequency ultrasound have come to market to tighten skin noninvasively using thermal energy. The best-known example is Ultherapy, which was cleared in 2009 by the Food and Drug Administration (FDA) for noninvasive eyebrow lift, noninvasive neck and submental lift, and to improve lines and wrinkles of the décolletage. However, results have been mild and patients often complain of pain associated with treatment.⁵⁻⁷

From the *Avance Plastic Surgery Institute, Reno/Tahoe, Nev., †Resurrect Skin MD, Dallas, Tex.; ‡Dallas Plastic Surgery Institute, Dallas, Tex.; and §bodySCULPT, New York, N.Y.

Received for publication May 13, 2019; accepted March 25, 2020.

Copyright © 2020 The Authors. Published by Wolters Kluwer Health, Inc. on behalf of The American Society of Plastic Surgeons. This is an open-access article distributed under the terms of the [Creative Commons Attribution-Non Commercial-No Derivatives License 4.0 \(CCBY-NC-ND\)](#), where it is permissible to download and share the work provided it is properly cited. The work cannot be changed in any way or used commercially without permission from the journal.

DOI: 10.1097/GOX.0000000000002861

RADIOFREQUENCY ENERGY

Radiofrequency energy is a form of electromagnetic current that can be delivered through various tissue types (ie, skin, fat, and muscle) to generate thermal energy.⁸ Radiofrequency (RF) has been used in nearly all medical specialties, including cardiology, urology, sleep medicine, and oncology.⁸ It was initially used in medicine in the 1920s for electrocautery.⁹ Over the past 15 years, its use in aesthetic surgery has increased (Table 1). However, the use of RF to contract collagen is not a new concept.⁴ For example, orthopedic surgeons have used RF to contract areas such as shoulder ligaments responsible for instability for over a decade.¹⁰⁻¹³

SCIENCE BEHIND RADIOFREQUENCY

In 2002, the FDA approved the first monopolar RF device for facial wrinkle reduction (ThermaCool; Thermage, Inc., Hayward, Calif.).¹⁴ Since 2002, more sophisticated RF devices have been developed to deliver RF energy in different manners (ie, bipolar, multipolar, and fractional) with more safety features. Unlike lasers, RF does not target specific chromophores by selective photothermolysis.⁸ Instead, RF generates heat as a result of different tissue resistance or impedance to the electromagnetic current. This means that heat is produced when the tissues' inherent resistance converts the electrical current to thermal energy as dictated by the following formula (Ohm's law): Energy (J) = Current² × Resistance × Time.¹⁵ For example, adipose tissue has a high tissue impedance and will generate more heat than muscle which has lower impedance for a given amount of time.⁸ In fact, when RF energy is directed to subdermal adipose tissue, it has been shown to generate temperatures 7-fold higher than those generated by the dermis, leading to fat necrosis with epidermal preservation.¹⁶

Disclosure: Dr. Dayan received book royalties from Thieme Publishers. He is a consultant in InMode; a co-investigator in Allergan, MTF, Galderma, and InMode; and a developer of coreaesthetics.com. Dr. Burns is a board member in HintMD. He is a consultant in Sciton, InMode, and Allergan. Dr. Rohrich received book royalties from Thieme Publishers and instrument royalties from Micrins. He is a co-investigator in InMode, Galderma, MTF, Bellus, and Allergan. Dr. Theodorou is a consultant in InMode.

Table 1. Key Studies Evaluating Radiofrequency Treatments

	Device	n	No. Treatments	Area	Complications		Findings
Fitzpatrick et al ²⁷	ThermaCool TC (Thermage, Inc., Hayward, Calif.)	86	Single	Lateral canthal, forehead	0.36% secondary burns	6 mo	83.2% had improvement by 1 point on FWCS, 50% satisfied with improvement in periorbital wrinkling, eyebrow lift of ≥ 0.5 mm in 61.5% of patients
Bassichis et al ²⁸	ThermaCool TC (Thermage, Inc.)	24	Single	Upper face	None recorded	12 mo	0.5 mm in 87.5% patients, 64% did not perceive a cosmetic benefit
Nahm et al ²⁰	ThermaCool TC (Thermage, Inc.)	10	Single	Left side of face only	No major complications noted	3 mo	Statistically significant elevation 4.3 mm of mid-brow and 2.4 mm of lateral brow with 1.9 mm increase at the level of palpebral crease
Jacobson et al ³⁰	ThermaCool TC (Thermage, Inc.)	24	1–3 monthly	Lower face/neck	No major complications noted	3 mo	Notable improvement of neck, nasolabial folds, marionette lines, and jawline
Alster and Tanzi ³¹	ThermaCool TC (Thermage, Inc.)	50	Single	Lower face/neck	No major complications noted	6 mo	Significant improvement in cheek and neck skin laxity in majority of patients. Satisfaction scores paralleled the clinical improvements observed.
El-Domyati et al ³²	Biorad (GSD Biorad, Guangdong, China)	6	12 treatments (3 mo of treatment at 2-wk intervals)	Face	No major complications noted	6 mo	All 6 patients had improvement of periorbital and forehead regions 70%–75% at 3 mo following treatment
Javate et al ³³	Pelleve (Ellman International, Inc., Oceanside, N.Y.)	32	8 weekly treatments	Face (periorbital, frontal, midface)	No major complications noted	6 mo	Progressive improvement in Fitzpatrick wrinkle classification ($P < 0.01$)
Taub et al ³⁴	Pelleve (Ellman International, Inc.)	17	6 treatments	Face	No major complications noted	6 mo	25%–30% improvement 2 wk after first treatment with an average improvement of 50% after last treatment
Theodorou et al ³⁷	Bodytite (InMode, Lake Forest, Calif.)	40	Single	Upper arms	2 minor complications (1 burn, 1 seroma)	3 y	>90% patient satisfaction at 6 mo
Dayan et al ³⁹	Bodytite, Fractional RF combination (InMode, Lake Forest, Calif.)	247	Single	face, lower neck	No major complications noted	5 y	Statistically significant 0.8 point improvement on Baker Face Neck Score

FWCS, Fitzpatrick wrinkle classification system.

When RF energy is applied to the underlying skin and soft tissue, it generates contraction by 2 mechanisms: (1) immediate cleavage of hydrogen bonds in the collagen triple helix causing shortening and thickening of the collagen fibrils and (2) initiation of a wound healing cascade to trigger neoangiogenesis, neocollagenesis, and elastin reorganization over the following 3–4 months. This dual mechanism was shown 15 years ago when the ThermaCool TC RF device pilot study treated bovine tendon and human abdominal skin.¹⁷ Electron microscopy evaluation of RF-heated collagen further demonstrates breakage of intramolecular bonds in the collagen fibrils, leading to increased diameter and shortening.¹⁷ Also messenger ribonucleic acid studies show upregulation of collagen gene expression after treatment with RF to the skin.¹⁸

Clinical studies and animal studies demonstrate that subdermal temperatures from 65°C to 68°C and skin surface temperatures ranging from 38°C to 42°C are required to obtain optimal contraction. Further, it is postulated that heated fibroblasts may be stimulated to produce collagen.¹³ Importantly, if temperatures exceed a critical heat threshold, there is the potential for collagen ablation and full-thickness

injury.^{17,19} There is no single shrinkage temperature of collagen contraction.²⁰ Rather, the delivery of RF energy is a function of time and temperature to allow for maximal epidermal protection while optimally heating the dermal collagen. For example, studies suggest that for millisecond exposures, the shrinkage temperature is above 85°C, whereas for exposures of several seconds, the shrinkage temperature is in the range of 60°C–65°C (2–15). For every 5°C decrease in temperature, a 10× increase in time is required to achieve a comparable collagen contraction.²⁰ RF volumetric dermal heating is favorable because it avoids targeting specific dermal targets and instead leverages various tissue impedances to generate desired heat and contraction.²¹ This nonspecificity means that RF is safe to use in all Fitzpatrick skin types.

RADIOFREQUENCY DELIVERY: MONOPOLAR, BIPOLAR RF DELIVERY, AND COMBINATION SYSTEMS

There are 2 major electrode configurations available in current RF devices: monopolar and bipolar. Monopolar

devices deliver current using one active electrode that transmits the electromagnetic current toward a grounding pad.²² In some cases, a cooling spray is used to protect the epidermis from the volumetric dermal heating. The energy can be delivered by conductive or capacitive coupling. Conductive coupling is based on energy concentrated at the distal portion of the electrode being delivered to the target tissue. This leads to heat production at the skin surface in contact with the electrode, which can produce epidermal injury. Capacitive coupling disperses energy across a surface to create a uniform zone of heat.²³

Monopolar RF energy has been successfully used to accomplish noninvasive skin tightening of the face, periorbital, abdomen, and extremities.²⁴ The first monopolar RF device was the ThermoCool device (Thermage, Inc.), which was introduced in 2001 and approved by FDA for the noninvasive treatment of periorbital rhytids and wrinkles in 2002, for full face treatment in 2004, and for body contouring in 2006.^{25,26} Among the largest studies of monopolar RF in aesthetic applications was by Bassichis et al, who conducted a blinded, multicenter trial where 86 patients received a single treatment in lateral canthal and forehead areas.²⁸ A total of 83% of patients had improvement by at least one point on the Fitzpatrick Wrinkle Classification System, and 50% were satisfied with the improvement in periorbital wrinkling. Eyebrow lift of ≥ 0.5 mm was noted in approximately 62% of patients. Overall complication rates were low, with an incidence of 0.36% secondary burns. This is consistent with the study by Bassichis et al²⁸ who also evaluated ThermoCool for rejuvenation of the upper third of the face by assessing changes in brow position. They found that treatment led to statistically significant brow elevation of 0.5 mm in 87.5% of patients. Despite this, 64% of patients did not perceive a cosmetic benefit and no complications were recorded. Nahm et al²⁹ also studied the use of monopolar RF for brow elevation in 10 patients. This study treated one side of the face with a single pass using the ThermoCool device. By 3 months posttreatment, there was a statistically significant average elevation of 4.3 mm of the mid-brow and 2.4 mm of the lateral brow with a 1.9 mm increase at the level of the palpebral crease.²⁹ Jacobson et al³⁰ treated 24 patients with the ThermoCool device for lower face and neck laxity. They showed notable improvement of neck, nasolabial folds, marionette lines, and jawline up to 3 months following treatment. Alster and Tanzi³¹ showed similar findings, with improvement in moderate cheek laxity and nasolabial folds. El-Domyati et al³² used a different monopolar RF device (Biorad, Guangdong, China) to treat patients for 3 months at 2-week intervals. All 6 patients had notable improvements in skin tightening of the periorbital and forehead regions that continued 3 months after treatment. Skin tightening improved from 35% to 40% at the end of treatment to 70% to 75% at 3 months following treatment.³² Javate et al³³ and Taub et al³⁴ independently evaluated a 4-MHz monopolar system (Pelleve; Ellman International, Inc., Oceanside, N.Y.), showing favorable results. Javate et al³³ evaluated patients 1, 3, and 6 months after treatment, and statistically significant changes were noted clinically and according to electron microscopy evaluation. Similarly, Taub et al³⁴ used the

device to reach a target surface temperature of 40°C–42°C, noting an overall 25%–30% improvement 2 weeks after the first treatment, with an average improvement of 46% 6 months after final treatment.³⁴

Monopolar devices typically have mild and self-limited adverse effects mainly limited to transient erythema and edema.⁸ Weiss et al³⁵ published a thorough review of adverse effects following ThermoCool consistent with mild side effects. There were rare cases of superficial crusting, slight contour deformities, subcutaneous erythematous papules, and neck tenderness. The overall rate of adverse side effects was 2.7%, but none of these side effects were experienced when using a lower energy multiple-pass treatment algorithm.³⁵

Bipolar devices differ from monopolar because they pass electrical current only between 2 positioned electrodes. The tissue to be heated and tightened is between these 2 electrodes, and the depth of penetration is approximately half the distance between the electrodes.¹ Thus, bipolar radiofrequency devices offer a shallower depth of penetration when compared with monopolar. However, this configuration does provide more controlled or localized distribution of energy and less discomfort.³⁶ No grounding pad is necessary with these systems because current does not flow through the rest of the body. Although this heat is targeted between the 2 electrodes, monopolar devices are believed to lead to a more uniform volumetric heating. Theodorou et al³⁷ reported outcomes on 40 patients undergoing bipolar RF-assisted liposuction (Bodytite; InMode, Lake Forest, Calif.) without any major complications and 2 minor complications, including a superficial burn and a seroma that resolved with aspiration. Patient satisfaction was high at 6 months, with >90% of patients satisfied to extremely satisfied.³⁸ Three independent plastic surgeons evaluated pre- and postoperative photographs and indicated that the improvement in arm contouring was good to excellent 80% of the time.³⁸ Dayan et al³⁹ reported similar findings with bipolar radiofrequency (InMode, Lake Forest, Calif.) in a variety of body areas, including arms, supraumbilical regions, thighs, and axillary rolls (Figs. 1, 2). The clinical skin contraction obtained was reported at 40% improved. Minor complications included erythema, prolonged swelling past 2 months, and subdermal banding.³⁹ Dayan et al³⁹ further published the largest study to date using a combination bipolar radiofrequency protocol (Morpheus8 and Facetite; InMode, Lake Forest, Calif.). In 247 patients with lower face and neck laxity, the pretest mean Baker Face Neck Score was 2.66 (SD, 0.72) and the posttest mean value was 1.86 (SD, 0.64). This mean difference ($\mu = 0.81$; SD, 0.46) was statistically significant [$t(237) = 27.34$; $P < 0.001$], and the effect size was large ($D = 1.76$).

HYBRID AND COMBINATION RF TECHNOLOGIES

Hybrid RF systems use monopolar and bipolar mechanisms (Accent RF; Alma Lasers, Ltd., Caesarea, Israel). The monopolar handpiece achieves deep volumetric heating of the skin through alternating current of the electromagnetic field. The bipolar handpiece is used for

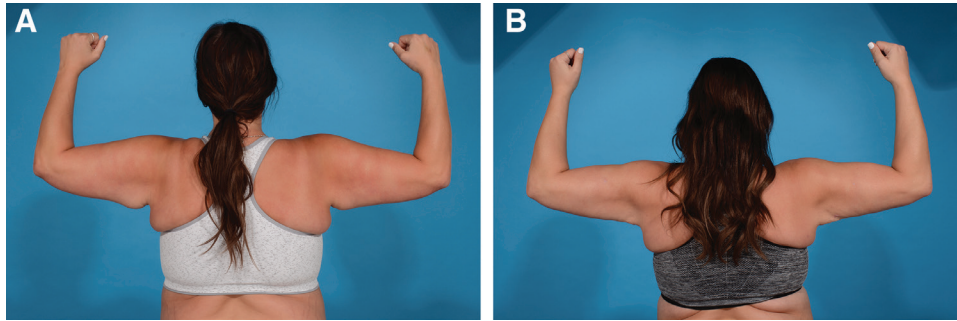


Fig 1. Photographs showing pre- (A) and post-radiofrequency–assisted liposuction (B) of the arms.

more superficial localized (nonvolumetric) heating based on tissue impedance.^{40,41} Studies evaluating the use of hybrid monopolar/bipolar RF for the treatment of facial rhytids and skin laxity found that 56% of participants had improvement.⁴¹ When stratified by age, the young patients had higher satisfaction scores when compared with the older patients.⁴¹ This may be explained by inherent changes of collagen cross-linking leading to irreducible multivalent cross-links as tissues age.⁴² A split face study by Alexiades-Armenakas et al¹⁴ compared the combined monopolar/bipolar RF for the treatment of facial rhytids and laxity. Although there was a slightly greater degree of improvement with the bipolar handpiece, this difference did not reach statistical significance.

A number of combination technologies have been developed to change tissue impedance and improve safety and efficacy of heat generation. One of the most widely studied bipolar RF devices uses electro-optical synergy (ELOS) with broadband light (Syneron Aurora) or with a diode laser (Syneron Polaris) (Syneron Medical Ltd., Yokneam

Elite, Israel).⁴³ This technology is termed ELOS.^{4,15} Most commonly, the ELOS systems include intense pulsed light (IPL), diode laser, or infrared light. The concept is that combination optical and bipolar RFs allow for lower energy delivery to achieve target heating, thus minimizing discomfort and complications.^{15,21,43} Photothermolysis is used to preheat the target tissues, which in turn changes tissue impedance and susceptibility to RF. The RF also allows for deeper penetration into the dermis than nonablative lasers, which tend to disperse in the soft tissue.^{1,4} Early systems such as Aurora SR and Polaris WR (Syneron Medical Ltd.) used the bipolar configuration with an IPL and a 900-nm diode laser, respectively. The Aurora SR system was studied by El-Domyati et al³³ to evaluate histologic and clinical changes in periorbital region of 6 subjects over 6 treatments. At 3 months, improvements in skin tightening, texture, wrinkles, and overall satisfaction were 75%–80%, 70%–75%, 95%–100%, and 95%–100%, respectively.³³ Histologic analysis confirmed these findings with increased epidermal thickening, a 53% reduction

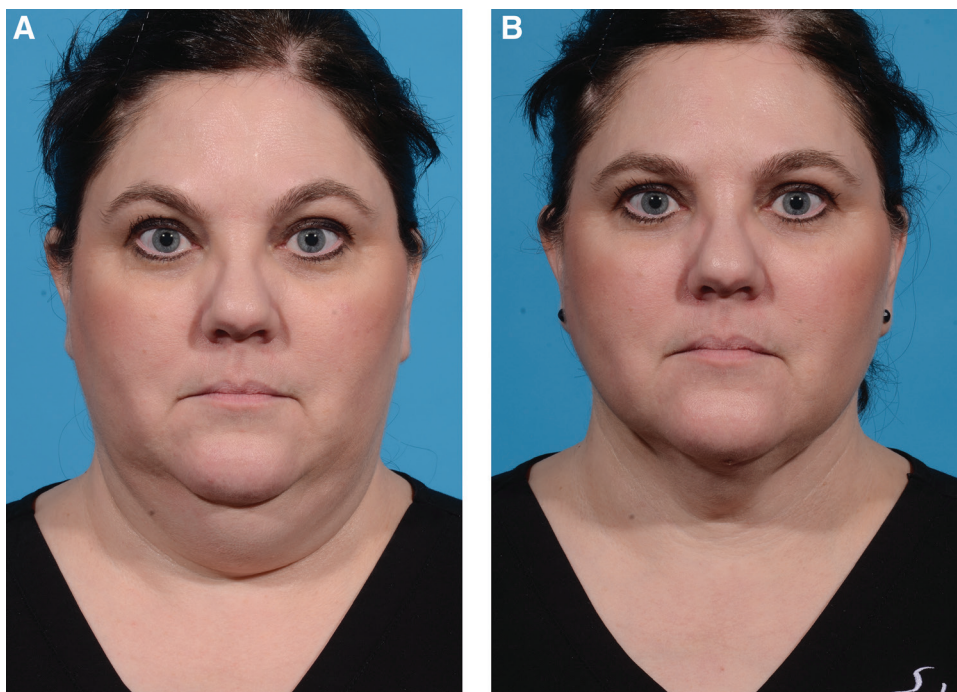

Fig 2. Photographs showing pre- (A) and post-radiofrequency–assisted liposuction (B) of the lower face and neck.

in elastin content, and a 28% increase in newly synthesized collagen fibers.³² Sadick et al⁴⁴ conducted a clinical study using Aurora SR, which reported similar findings on 108 patients. Overall skin improvement was 75.3%, which included wrinkle improvement, pore size, and pigmentation, among other factors, and skin laxity improved 62.9%. Patient satisfaction was 92% at 15 weeks posttreatment. The Polaris WR system was also studied for facial rhytids and skin laxity.⁴⁵ The combination of RF and diode laser energy accomplished improvements in skin laxity and rhytids, most notably in the periorbital region, with continued skin laxity improvement at 6 months posttreatment. Newer ELOS platforms incorporate both the IPL and diode laser with RF.

Another combination technology includes vacuum with bipolar RF, termed functional aspiration controlled electrothermal stimulation (Aluma; Lumenis Inc., Santa Clara, Calif.).⁴⁶ The vacuum folds the skin and subcutaneous fat to ensure contact and positioning of the dermis in optimal alignment with the RF energy path. This avoids heating nontargeted structures (ie, muscle). Some theorize that the mechanical stress on fibroblasts from the vacuum may increase collagen formation and clinical efficacy.⁴⁷ The vacuum-assisted bipolar RF technology was studied by Gold et al⁴⁵ in 46 patients with facial aging. The mean elastosis score (Fitzpatrick-Goldman Classification) decreased from 4.5 (pretreatment) to 2.5 (6 months posttreatment). Despite overall clinical success, the investigators noted that patient satisfaction levels declined during the follow-up period.⁴⁶ The authors postulate that this may be a common finding with RF treatments as the effect is incrementally progressive over the number of months required for wound healing and neocollagenesis. Side effects of the vacuum-assisted RF are similarly infrequent to standard RF and include erythema, burns, blistering, edema, and transient hyperpigmentation.⁴⁴ Today, newer devices are combining all of these technologies (laser, vacuum, and RF) to achieve higher satisfaction of nonablative facial rejuvenation.

FRACTIONAL RADIOFREQUENCY

A nonablative approach of fractional RF is available, which uses either needles (Morpheus8; InMode, Lake Forest, Calif.) or electrodes to deliver thermal injury to the subdermis while leaving islands to tissue intact in between untreated.⁴⁶ As in fractional laser resurfacing, the unaffected areas serve to expedite recovery time. The fractional energy is delivered in a bipolar fashion with the tips of the needles carrying a positive charge and the faceplate of the disposable handpiece carrying a negative charge. The mechanical puncture of the needles also has been shown to improve skin texture and fine rhytids. Improvements in skin laxity and elastosis have been shown clinically with different fractional RF devices.^{48,49} Combination treatments with bipolar RF and fractional RF for lower face and neck laxity by Dayan et al³⁹ demonstrated improvement in Baker Face Neck Classification improvement of 1.4 (SD, ± 1.1) in 247 patients, with 93% satisfaction rate.

CONCLUSIONS

Aesthetic indications of RF continue to expand from facial rejuvenation to body contouring. More recently, RF has been used to target cellulite, acne vulgaris, and excess adiposity.⁵⁰ In our experience, RF bridges an important treatment gap for 3 group of patients: (1) those who are candidates for an excisional procedure but do not desire it; (2) patients who are not candidates for excisional procedures but cannot obtain sufficient skin tightening with other noninvasive techniques (ie, cryolipolysis, high-intensity focused ultrasound); or (3) patients who had a previous excisional procedure and present with recurrent laxity.

Radiofrequency energy has been shown to be a safe and effective method to obtain soft tissue tightening in both clinical and histologic studies. Few contraindications exist but may include elderly patients with thin skin, autoimmune or collagen vascular diseases, smoker, patients taking anti-inflammatory medications (which may impair collagen remodeling), and the presence of a pacemaker or other implantable device.⁵⁰

RF does not replace or compare with ablative procedures.⁴ An important role of the clinician is to identify limitation of the technology and have a keen eye for patient selection and management of expectations.⁴ We know that younger patients typically respond more favorably to RF treatment. This may be possibly explained by covalent bonding of collagen that occurs as we age. Despite high patient satisfaction,^{25,28} the results of nonablative RF technology are typically not always predictable and usually modest.^{9,14,22,28,42} Although RF does not improve laxity to the degree of surgery, it does have the advantage of avoiding surgery-associated cost, downtime, and potential complications. We believe that RF is one option in the array of aesthetic treatments. It may in fact be the best option for the appropriately selected patient who is not a candidate and does not desire excisional procedures. Further work is needed to elucidate a number of core questions related to RF, including optimal energy levels and time of treatment as well as improved methods to measure clinical outcomes.

Erez Dayan, MD

Avance Plastic Surgery Institute
5570 Longley Lane
Suite A
Reno, NV 89511

E-mail: drdayan@avanceinstitute.com

PATIENT CONSENT STATEMENT

The patient provided written consent for the use of her image.

REFERENCES

1. Elsaie ML. Cutaneous remodeling and photorejuvenation using radiofrequency devices. *Indian J Dermatol.* 2009;54:201–205.
2. Goldberg DJ, Cutler KB. Nonablative treatment of rhytids with intense pulsed light. *Lasers Surg Med.* 2000;26:196–200.
3. Hruza GJ, Dover JS. Laser skin resurfacing. *Arch Dermatol.* 1996;132:451–455.
4. Atiyeh BS, Dibo SA. Nonsurgical nonablative treatment of aging skin: radiofrequency technologies between aggressive marketing and evidence-based efficacy. *Aesthetic Plast Surg.* 2009;33:283–294.

5. Friedmann DP, Fabi SG, Goldman MP. Combination of intense pulsed light, sculptr, and ultherapy for treatment of the aging face. *J Cosmet Dermatol*. 2014;13:109–118.
6. Kornstein AN. Ultherapy shrinks nasal skin after rhinoplasty following failure of conservative measures. *Plast Reconstr Surg*. 2013;131:664e–666e.
7. Liu H, Zhong G, Liang L, et al. A new way to reduce the pain of ultherapy treatment. *J Cosmet Dermatol*. 2020;19:1973–1974.
8. Greene RM, Green JB. Skin tightening technologies. *Facial Plast Surg*. 2014;30:62–67.
9. Fisher GH, Jacobson LG, Bernstein LJ, et al. Nonablative radiofrequency treatment of facial laxity. *Dermatol Surg*. 2005;31(9 pt 2):1237–1241; discussion 1241.
10. Miniaci A, Codsí MJ. Thermal capsulorrhaphy for the treatment of shoulder instability. *Am J Sports Med*. 2006;34:1356–1363.
11. Miniaci A, McBirmie J. Thermal capsular shrinkage for treatment of multidirectional instability of the shoulder. *J Bone Joint Surg Am*. 2003;85:2283–2287.
12. Ruiz-Esparza J. Nonablative radiofrequency for facial and neck rejuvenation. A faster, safer, and less painful procedure based on concentrating the heat in key areas: the ThermoLift concept. *J Cosmet Dermatol*. 2006;5:68–75.
13. Ruiz-Esparza J, Gomez JB. The medical face lift: a noninvasive, non-surgical approach to tissue tightening in facial skin using nonablative radiofrequency. *Dermatol Surg*. 2003;29:325–332; discussion 332.
14. Alexiades-Armenakas M, Dover JS, Arndt KA. Unipolar versus bipolar radiofrequency treatment of rhytides and laxity using a mobile painless delivery method. *Lasers Surg Med*. 2008;40:446–453.
15. Alster TS, Lupton JR. Nonablative cutaneous remodeling using radiofrequency devices. *Clin Dermatol*. 2007;25:487–491.
16. Youn A. Nonsurgical face lift. *Plast Reconstr Surg*. 2007;119:1951; author reply 1951–1951; author reply 1952.
17. Zelickson BD, Kist D, Bernstein E, et al. Histological and ultrastructural evaluation of the effects of a radiofrequency-based nonablative dermal remodeling device: a pilot study. *Arch Dermatol*. 2004;140:204–209.
18. Dierickx CC. The role of deep heating for noninvasive skin rejuvenation. *Lasers Surg Med*. 2006;38:799–807.
19. Drew PJ, Watkins A, McGregor AD, et al. The effects of temperature and time on thermal bond strength in tendons. *Lasers Med Sci*. 2001;16:291–298.
20. Ruiz-Esparza J. Near [corrected] painless, nonablative, immediate skin contraction induced by low-fluence irradiation with new infrared device: a report of 25 patients. *Dermatol Surg*. 2006;32:601–610.
21. Ee HL, Barlow RJ. Lasers, lights and related technologies: a review of recent journal highlights. *Clin Exp Dermatol*. 2007;32:135–137.
22. Burns JA. Thermage: monopolar radiofrequency. *Aesthet Surg J*. 2005;25:638–642.
23. Laubach HJ, Makin IR, Barthe PG, et al. Intense focused ultrasound: evaluation of a new treatment modality for precise micro-coagulation within the skin. *Dermatol Surg*. 2008;34:727–734.
24. Biesman BS, Pope K. Monopolar radiofrequency treatment of the eyelids: a safety evaluation. *Dermatol Surg*. 2007;33:794–801.
25. Finzi E, Spangler A. Multipass vector (mpave) technique with nonablative radiofrequency to treat facial and neck laxity. *Dermatol Surg*. 2005;31(8 pt 1):916–922.
26. Narins DJ, Narins RS. Non-surgical radiofrequency facelift. *J Drugs Dermatol*. 2003;2:495–500.
27. Fitzpatrick R, Geronemus R, Goldberg D, et al. Multicenter study of noninvasive radiofrequency for periorbital tissue tightening. *Lasers Surg Med*. 2003;33:232–242.
28. Bassichis BA, Dayan S, Thomas JR. Use of a nonablative radiofrequency device to rejuvenate the upper one-third of the face. *Otolaryngol Head Neck Surg*. 2004;130:397–406.
29. Nahm WK, Su TT, Rotunda AM, et al. Objective changes in brow position, superior palpebral crease, peak angle of the eyebrow, and jowl surface area after volumetric radiofrequency treatments to half of the face. *Dermatol Surg*. 2004;30:922–928; discussion 928.
30. Jacobson LG, Alexiades-Armenakas M, Bernstein L, et al. Treatment of nasolabial folds and jowls with a noninvasive radiofrequency device. *Arch Dermatol*. 2003;139:1371–1372.
31. Alster TS, Tanzi E. Improvement of neck and cheek laxity with a nonablative radiofrequency device: a lifting experience. *Dermatol Surg*. 2004;30(4 pt 1):503–507; discussion 507.
32. El-Domyati M, el-Ammawi TS, Medhat W, et al. Radiofrequency facial rejuvenation: evidence-based effect. *J Am Acad Dermatol*. 2011;64:524–535.
33. Javate RM, Cruz RT Jr, Khan J, et al. Nonablative 4-MHz dual radiofrequency wand rejuvenation treatment for periorbital rhytides and midface laxity. *Ophthalmic Plast Reconstr Surg*. 2011;27:180–185.
34. Taub AF, Tucker RD, Palange A. Facial tightening with an advanced 4-MHz monopolar radiofrequency device. *J Drugs Dermatol*. 2012;11:1288–1294.
35. Weiss RA, Weiss MA, Munavalli G, et al. Monopolar radiofrequency facial tightening: a retrospective analysis of efficacy and safety in over 600 treatments. *J Drugs Dermatol*. 2006;5:707–712.
36. Montesi G, Calvieri S, Balzani A, et al. Bipolar radiofrequency in the treatment of dermatologic imperfections: clinicopathological and immunohistochemical aspects. *J Drugs Dermatol*. 2007;6:890–896.
37. Theodorou SJ, Del Vecchio D, Chia CT. Soft tissue contraction in body contouring With radiofrequency-assisted liposuction: a treatment gap solution. *Aesthet Surg J*. 2018;38:S74–S83.
38. Abraham MT, Mashkevich G. Monopolar radiofrequency skin tightening. *Facial Plast Surg Clin North Am*. 2007;15:169–77, v.
39. Dayan E, Chia C, Burns AJ, et al. Adjustable depth fractional radiofrequency combined with bipolar radiofrequency: a minimally invasive combination treatment for skin laxity. *Aesthet Surg J*. 2019;39(suppl_3):S112–S119.
40. Emilia del Pino M, Rosado RH, Azuela A, et al. Effect of controlled volumetric tissue heating with radiofrequency on cellulite and the subcutaneous tissue of the buttocks and thighs. *J Drugs Dermatol*. 2006;5:714–722.
41. Friedman DJ, Gilead LT. The use of hybrid radiofrequency device for the treatment of rhytides and lax skin. *Dermatol Surg*. 2007;33:543–551.
42. Hsu TS, Kaminer MS. The use of nonablative radiofrequency technology to tighten the lower face and neck. *Semin Cutan Med Surg*. 2003;22:115–123.
43. Narurkar VA. Lasers, light sources, and radiofrequency devices for skin rejuvenation. *Semin Cutan Med Surg*. 2006;25:145–150.
44. Sadick NS, Alexiades-Armenakas M, Bitter P Jr, et al. Enhanced full-face skin rejuvenation using synchronous intense pulsed optical and conducted bipolar radiofrequency energy (ELOS): introducing selective radiophotothermolysis. *J Drugs Dermatol*. 2005;4:181–186.
45. Doshi SN, Alster TS. Combination radiofrequency and diode laser for treatment of facial rhytides and skin laxity. *J Cosmet Laser Ther*. 2005;7:11–15.
46. Gold MH, Goldman MP, Rao J, et al. Treatment of wrinkles and elastosis using vacuum-assisted bipolar radiofrequency heating of the dermis. *Dermatol Surg*. 2007;33:300–309.
47. Bogle MA, Uebelhoer N, Weiss RA, et al. Evaluation of the multiple pass, low fluence algorithm for radiofrequency tightening of the lower face. *Lasers Surg Med*. 2007;39:210–217.
48. Hruza G, Taub AF, Collier SL, et al. Skin rejuvenation and wrinkle reduction using a fractional radiofrequency system. *J Drugs Dermatol*. 2009;8:259–265.
49. Lee HS, Lee DH, Won CH, et al. Fractional rejuvenation using a novel bipolar radiofrequency system in Asian skin. *Dermatol Surg*. 2011;37:1611–1619.
50. Levy AS, Grant RT, Rothaus KO. Radiofrequency physics for minimally invasive aesthetic surgery. *Clin Plast Surg*. 2016;43:551–556.