

Long-Term Follow-up for Immature Teeth Treated with Regenerative Endodontic Procedures That Underwent Orthodontic Treatment

 Mohammed Ahmed ALHARBI,  Su-Min LEE

ABSTRACT

Although regenerative endodontic procedures (REPs) have become one of the widely accepted treatment modalities for necrotic immature teeth with apical periodontitis, little is known about the long-term outcomes and the effect of orthodontic tooth movement on this procedure. This report presents a case that underwent two REPs and orthodontic treatment over a period of seven years. A 9-year-old male was referred for evaluation of traumatized maxillary central incisors. Based on clinical and radiographic examinations, a diagnosis of pulp necrosis with acute apical abscess was established. REP was performed for both teeth, and the patient was brought in for follow-up annually. Orthodontic treatment was performed during the follow-up period. Annual follow-up visits demonstrated complete resolution of signs and symptoms of disease with the thickening of the roots. At the six-year follow-up visit, the patient presented with a sinus tract and periapical radiolucency. A second REP was performed for both teeth. The one-year recall visit after the second REP revealed complete resolution of clinical symptoms and radiographic signs of healing of apical pathology with further development of the roots. In conclusion, the effect of orthodontic treatment on teeth undergoing REP should be investigated and yearly follow-up visits should be recommended for patients undergoing REP as this case showed signs of deterioration six years after the treatment.

Keywords: Long-term follow up, orthodontic treatment, regenerative endodontic procedure

HIGHLIGHTS

- Long term follow-up is required for cases undergoing REP.
- Teeth underwent REP can fail after initial positive outcome.
- REP can be repeated with successful outcome.
- The effect of orthodontic tooth movement on teeth underwent REP should be thoroughly investigated.

INTRODUCTION

Regenerative endodontic procedures (REPs) have been proposed as the treatment of choice for immature permanent teeth with necrotic pulp and apical periodontitis (1). Treating such cases exhibits considerable challenges including adequately cleaning and filling root canals with open apices (2). Over 300 published cases of REPs have shown favourable results (3-

5). Despite their promising short-term outcomes, the long-term prognoses are still unknown. This case report presents a seven-year long follow-up of a patient who was treated twice with REP and underwent orthodontic treatment.

CASE PRESENTATION

A 9-year-old male patient was presented to the Endodontic clinic with his mother complaining of pain in his upper front teeth. His medical history was non-contributory, and he had no known drug allergies. The patient's dental history revealed a trauma that chipped his maxillary central incisors two years prior to the visit.

Clinical evaluation revealed a mild vestibular swelling labial to maxillary central incisors which exhibited complicated crown fractures with normal physiologic mobility. They were sensitive to percussion and palpation. Neither responded to the cold test (Endo ice, Coltene, Altstätten SG, Switzerland) nor to the electric pulp testing (Digital Pulp Tester; Parkell, Inc, Edgewood, NY). Control teeth responded positively to both tests. All probing depths were within normal limit. The periapical radiographs revealed that both teeth had thin root dentinal walls and open api-

Please cite this article as: Alharbi MA, Lee SM. Long-Term Follow-up for Immature Teeth Treated with Regenerative Endodontic Procedures That Underwent Orthodontic Treatment. *Eur Endod J* 2021; 6: 242-6

From the Department of Endodontics (M.A.A. ✉ maealharbi@kau.edu.sa), Faculty of Dentistry, King Abdulaziz University, Jeddah, Saudi Arabia; Department of Endodontics (S.M.L.), School of Dental Medicine, University of Pennsylvania, Philadelphia, USA

Received 30 May 2020,
Accepted 27 October 2020

Published online: 07 July 2021
DOI 10.14744/eej.2020.29591

This work is licensed under a Creative Commons Attribution-NonCommercial 4.0 International License.



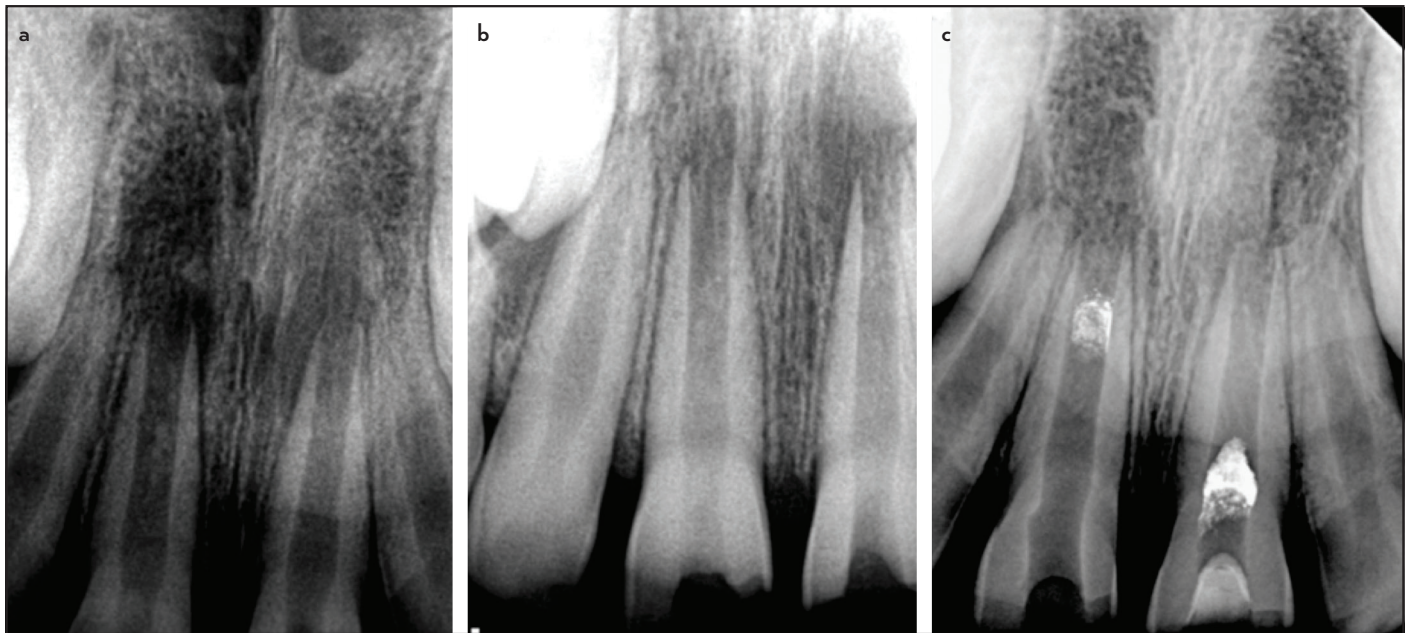


Figure 1. (a, b) Pre-operative periapical (PA) radiographs with straight and shifted projections, respectively showing immature roots of teeth 11 and 21 associated with radiolucency indicative of apical periodontitis. (c) PA radiograph at 11 months after starting the treatment. The PA radiograph shows the loss of temporary restorations and the increase of size of periapical radiolucency with no changes in the dimensions of the roots

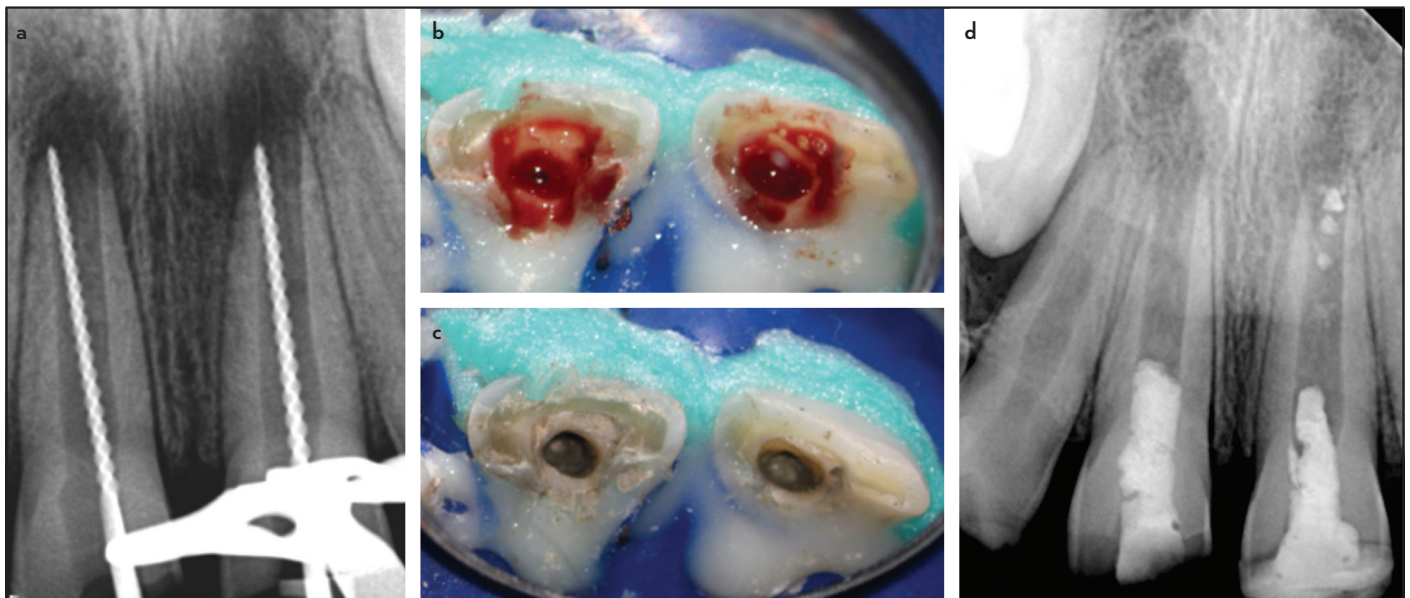


Figure 2. Regenerative endodontic procedure and radiographic imaging. (a) Radiograph for working length determination. (b) Bleeding from periapical tissue was evoked into the canal by over-instrumentation. (c) MTA was placed over blood clot below the cemento-enamel junction level. (d) Immediate post-operative radiograph with permanent composite resin restorations

ces with periapical radiolucent area (Fig. 1a and b). Based on clinical and radiographic examination, tooth 11 and 21 were diagnosed with necrotic pulp and acute apical abscess. Findings and treatment options were discussed with the patient and his mother. They both agreed to REP and signed the consent.

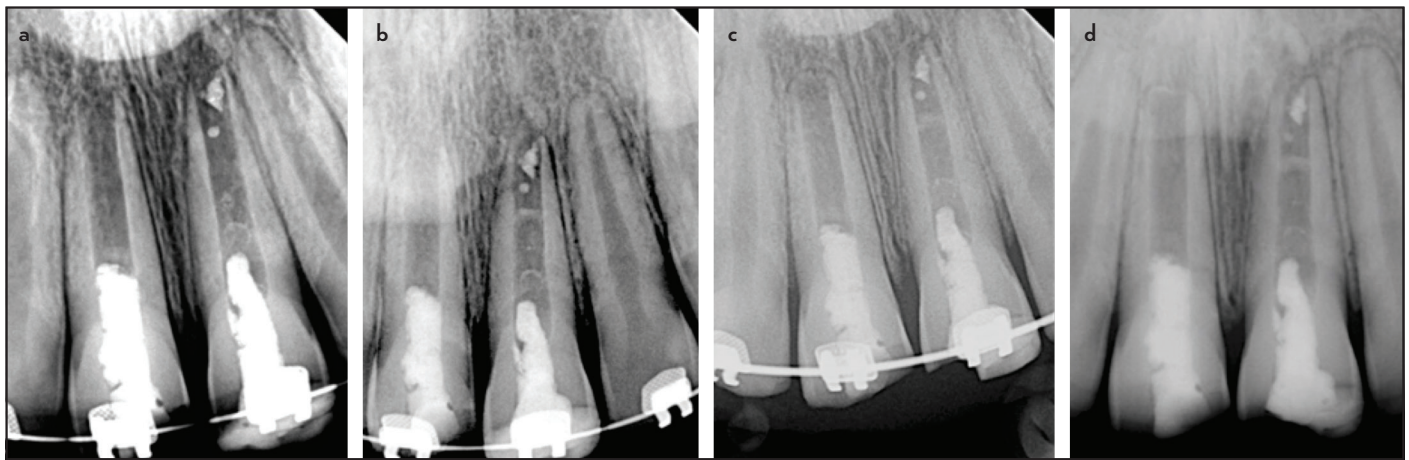
After achieving local anesthesia, the rubber dam was placed. All of procedures were performed under a surgical operating microscope (Pico, Carl Zeiss, Oberkochen, Germany). Access was made and the necrotic status of both teeth were confirmed. Minimal instrumentation was performed. Canals were

irrigated with 4% sodium hypochlorite with passive ultrasonic irrigation, followed by 17% ethylenediaminetetraacetic acid. Triple antibiotic paste containing equal parts of metronidazole, ciprofloxacin, and clindamycin was placed. Access cavities were sealed with Cavit (ESPE, Seefeld, Germany). The patient was scheduled to complete the treatment in two weeks. However, he missed the second session of REP.

Eleven months later, the patient returned to the clinic. Clinical examination and radiographs revealed the absence of temporary restorations and persistent periapical radiolucency (Fig. 1c). All procedures were repeated, as mentioned previ-

TABLE 1. Case report events timeline

The event	Timeline
First clinical visit (examination, diagnosis, treatment planning, signing the consent, and starting the first step of REP.	May 2012
The patient returned to continue the treatment. First step of REP was repeated.	April 2013
Second visit of REP was completed.	May 2013
Final composite restoration was placed.	May 2013
Follow up visit.	April 2014
Follow up visit.	March 2015
Follow up visit.	Jan 2016
Follow up visit.	Feb 2017
Patient presented with sinus tract. First step of 2 nd REP was started.	April 2018
Second step of REP was completed, and final composite restoration was placed	April 2018
Follow up visit.	March 2019

**Figure 3.** Follow up radiographs acquired at (a) 2 years, (b) 3 years, (c) 4 years, (d) and 5 years following the primary regenerative endodontic procedure

ously. In two weeks, he became asymptomatic. No vasoconstrictor-containing anesthesia (3% Mepivastasin; 3M ESPE, St Paul, MN) was used. Working length was determined by radiographs (Fig. 2a). Irrigation was done as mentioned. Bleeding was induced by lacerating the apical tissues (Fig. 2b). Mineral Trioxide Aggregate (MTA; Dentsply, York, PA) was placed directly over the blood clot (Fig. 2c), followed by a moist cotton pellet and Cavit. When the patient returned one week later, the setting of MTA was verified. Composite restoration (3M Filtek P60; 3M ESPE, St Paul, MN) was placed (Fig. 2d), and the patient was scheduled for follow-ups.

A year later, the patient was asymptomatic. Radiographs showed resolution of the apical radiolucency (Fig. 3a). His orthodontist planned to start treatment. However, they were advised not to apply forces until further proof of root development. At 3, 4, and 5-year recall visits, there was evidence of thickening of dentinal walls and apical closure (Fig. 3b-d).

The patient and his mother returned to the clinic six years after completing REP with a fractured composite filling and a sinus tract associated with tooth 21 (Fig. 4a). After discussing the findings and the treatment options, the patient and his mother elected to revisit the REP. Re-access was made and MTA was removed. All subsequent procedures in the first appointment were followed, as discussed earlier (Fig. 4b). Two weeks later, the sinus tract healed. All the procedures at the second session were completed as mentioned earlier except the placement of

EndoSequence BC Root Repair Material (BC-RRM; Brasseler, Savannah, GA) instead of MTA (Fig. 4c). Due to the discoloration that the MTA induced.

One year after completing the second REP, the patient presented with complete healing of the periapical radiolucency, increased thickness and width of the roots, and almost complete apical closure (Fig. 4d). The tooth color was stable and satisfactory at the follow up visit. All the clinical events and follow up visits are summarized in Table 1.

DISCUSSION

It is widely accepted in trauma literature that revascularization potential teeth with immature roots have an excellent capacity for revascularization as those teeth undergo sterile necrosis due to severing the blood supply (6). Most of the time, those revascularization potential teeth maintain intact crowns without apparent avenues for microbes to gain access to the root canal space. The sterile tissue works as a matrix that allows the new tissue to grow. On the other hand, once the root canal system becomes infected and covered with biofilms, the case becomes more challenging. A recent review reported that trauma accounted for around 50% of the failed REP cases as the aetiology for the initiation of the REP (7). A possible mechanism is that dental trauma can disrupt the apical papilla and the Hertwig epithelial root sheath. This would also explain why cases with dens evaginatus reported significantly better results (4). Furthermore, another study demonstrated an association between

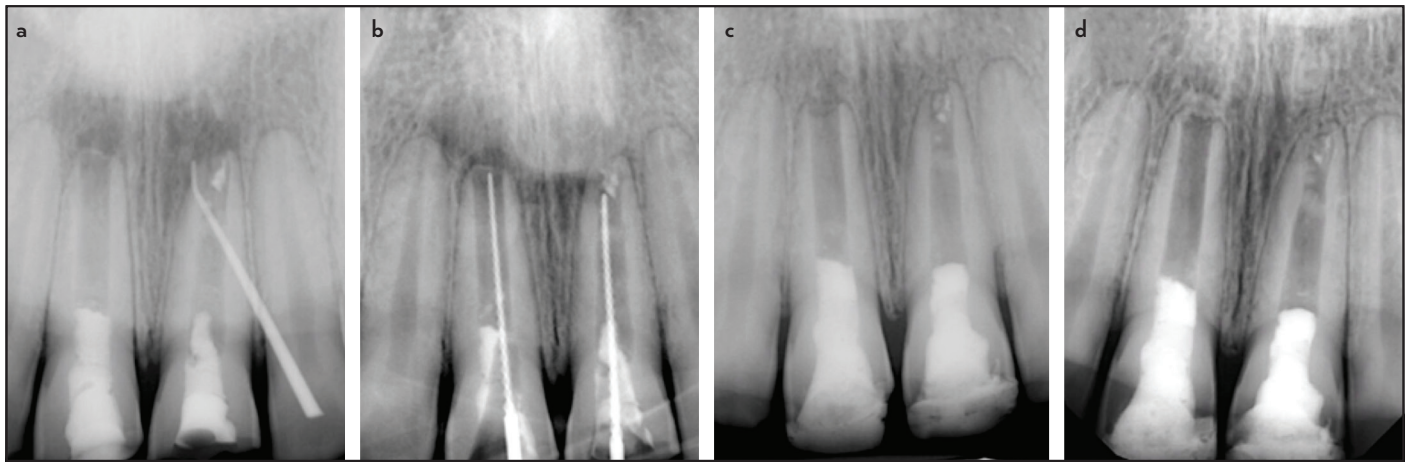


Figure 4. (a) PA radiograph showing a gutta-percha point tracing the sinus tract and radiolucent areas associated with tooth 11 and 21 at 6 years recall visit. (b) Radiograph for working length determination for the 2nd REP attempt. (c) Immediate post-operative radiograph. (d) 7 years recall radiograph (one year after the 2nd REP) showing resolution of periapical radiolucency with re-establishment of normal periodontal ligament space and lamina dura and apical closure

the successful outcome of REP and the length of the history of pulp necrosis (8). In all of the successful cases, the pulp did not undergo necrosis for more than six months unlike the presented case which was more than two years.

According to the literature, orthodontic tooth movement might not interfere with the development of a healthy normal immature tooth (9). Romer's group demonstrated higher levels of hypoxia-inducible factor-1 α in the dental pulp under the initial phase of orthodontic movements. This increase activates several genes that collectively stimulate neoangiogenesis. This is considered as a survival mechanism to ensure maintaining proper vascularization for the dental pulp (10). This same mechanism might not be active in REP cases since the regenerated tissues are not fully mature.

A recent study reported that around 40% of the failed REP cases were recognized at least two years after initiating the treatment (7). Those failed cases deteriorated after various stages of initial positive outcomes. Interestingly, our case showed the recurrence of apical periodontitis after the resolution of apical radiolucency and thickening of the roots at the six-year follow-up. The presented case emphasizes the importance of annual follow-ups on all REP cases to detect any signs of failure as soon as possible. Additionally, most of the reported cases were retreated with either conventional root canal treatment or one-step apexification. Few reported cases were treated with a second REP attempt (11-13). However, those cases did not show positive results from the first REP treatment and presented with persistent signs and symptoms of apical pathology. In the current case report, the teeth underwent a successful second REP with complete apical closure at the one-year recall, seven years from the first session. This can be attributed to the ability of survived stem cells from apical papilla tissue despite the long period of infection and moderate inflammatory cell infiltration (14).

CONCLUSION

The present case report demonstrates, the recurrence of apical periodontitis after achieving an initially successful outcome

from the first REP six years after completing the treatment. Furthermore, the case showed a successful outcome from the second REP attempt. This may suggest that teeth treated with REP should receive follow-ups for a more extensive period. In addition, the effect of orthodontic tooth movement on teeth that have undergone REP should be thoroughly investigated, as the majority of patients undergoing REP are young growing and may require orthodontic treatment.

Disclosures

Informed consent: The patient signed the consent form for the treatment provided.

Conflict of interest: Both authors have nothing to disclose.

Peer-review: Externally peer-reviewed.

Financial Disclosure: Not applicable.

Authorship contributions: Concept – M.A.A.; Design – M.A.A.; Supervision – M.A.A.; Funding - None; Materials - None; Data collection &/or processing – M.A.A.; Analysis and/or interpretation – S.M.L.; Literature search – S.M.L.; Writing – M.A.A.; Critical Review – S.M.L.

REFERENCES

- Hargreaves KM, Diogenes A, Teixeira FB. Treatment options: biological basis of regenerative endodontic procedures. *J Endod* 2013; 39(3 Suppl):S30–43.
- Schilder H. Filling root canals in three dimensions. *Dent Clin North Am* 1967; 723–44.
- Nagata JY, Gomes BP, Rocha Lima TF, Murakami LS, de Faria DE, Campos GR, et al. Traumatized immature teeth treated with 2 protocols of pulp revascularization. *J Endod* 2014; 40(5):606–12.
- Lin J, Zeng Q, Wei X, Zhao W, Cui M, Gu J, et al. Regenerative endodontics versus apexification in immature permanent teeth with apical periodontitis: a prospective randomized controlled study. *J Endod* 2017; 43(11):1821–7.
- Bukhari S, Kohli MR, Setzer F, Karabucak B. Outcome of revascularization procedure: a retrospective case series. *J Endod* 2016; 42(12):1752–9.
- Kling M, Cvek M, Mejare I. Rate and predictability of pulp revascularization in therapeutically reimplanted permanent incisors. *Endod Dent Traumatol* 1986; 2(3):83–9.
- Almutairi W, Yassen GH, Aminoshariae A, Williams KA, Mickel A. Regenerative endodontics: a systematic analysis of the failed cases. *J Endod* 2019; 45(5):567–77.

8. Nosrat A, Homayounfar N, Oloomi K. Drawbacks and unfavorable outcomes of regenerative endodontic treatments of necrotic immature teeth: a literature review and report of a case. *J Endod* 2012; 38(10):1428–34.
9. Mavragani M, Bøe OE, Wisth PJ, Selvig KA. Changes in root length during orthodontic treatment: advantages for immature teeth. *Eur J Orthod* 2002; 24(1):91–7.
10. Römer P, Wolf M, Fanghänel J, Reicheneder C, Proff P. Cellular response to orthodontically-induced short-term hypoxia in dental pulp cells. *Cell Tissue Res* 2014; 355(1):173–80.
11. Peng C, Yang Y, Zhao Y, Liu H, Xu Z, Zhao D, et al. Long-term treatment outcomes in immature permanent teeth by revascularisation using MTA and GIC as canal-sealing materials: a retrospective study. *Int J Paediatr Dent* 2017; 27(6):454–62.
12. Chaniotis A. Treatment options for failing regenerative endodontic procedures: report of 3 cases. *J Endod* 2017; 43(9):1472–8.
13. Priya M H, Tambakad PB, Naidu J. Pulp and periodontal regeneration of an avulsed permanent mature incisor using platelet-rich plasma after delayed replantation: a 12-month clinical case study. *J Endod* 2016; 42(1):66–71.
14. Chrepa V, Pitcher B, Henry MA, Diogenes A. Survival of the apical papilla and its resident stem cells in a case of advanced pulpal necrosis and apical periodontitis. *J Endod* 2017; 43(4):561–7.