



Original Article

Hepatoprotective effect of hydromethanolic leaf extract of *Musanga cecropioides* (Urticaceae) on carbon tetrachloride-induced liver injury and oxidative stress

Lucky L. Nwidi, PhD^{a,*}, Yibala I. Oboma, MSc^b, Ekramy Elmorsy, PhD^c and Wayne G. Carter, PhD^d

^a Department of Experimental Pharmacology and Toxicology, Faculty of Pharmaceutical Sciences, University of Port Harcourt, Choba, Nigeria

^b Department of Forensic Medicine and Clinical Toxicology, Faculty of Medicine, Mansoura University, Egypt

^c Department of Medical Laboratory Science, Faculty of Basic Medical Sciences, College Health Sciences, Niger Delta University, Wilberforce Island, Bayelsa State, Nigeria

^d School of Medicine, University of Nottingham, Royal Derby Hospital Centre, Derby, UK

Received 8 February 2018; revised 5 April 2018; accepted 12 April 2018; Available online 17 May 2018



المخلص

أهداف البحث: تكتسب منتجات مضادات الأكسدة الطبيعية شعبية كعلاجات لمختلف إصابات الكبد المرضية. ويُستخدم مستخلص أوراق موسانجا سيكريبيوديز أرتيكشيا في الطب التقليدي لعلاج اليرقان واعتلالات كبدية أخرى في أيبيو بنيجيريا. قُتِمت هذه الدراسة التأثيرات الوقائية للكبد والمضادة للأكسدة للمستخلص الإيثانولي لورق موسانجا سيكريبيوديز ضد التسمم الكبدي في الفئران والناتج عن رابع كلوريد الكربون.

طرق البحث: تم إحداث تلف الكبد عن طريق إعطاء رابع كلوريد الكربون مذابا في البارافين السائل (٢ مل / كغ من الوزن. ١: ١ داخل الصفاق) بعد المعالجة المسبقة بالمستخلص الإيثانولي لورق موسانجا سيكريبيوديز لمدة ٧ أيام. تم تقييم السمية الكبدية الحادة باستخدام ستة وثلاثين فأرا من فصيلة ويستار مقسمة إلى ست مجموعات (أ- و) تحتوي كل منها على ستة حيوانات. كانت المجموعة "أ" الضابط السليبي، وتلقى فئران المجموعات "ب-هـ" رابع كلوريد الكربون والمستخلص الإيثانولي لورق موسانجا سيكريبيوديز بالتركيز (١ مل/كجم فقط، ٧.٠، ١٤.٤ و ٢٨٢.٢ على التوالي، وتلقى فئران المجموعة "و" سيليمازين ١٠٠ مجم/كجم يوميا لمدة سبعة أيام عن طريق الغشاء القموي. بعد ٤٨ ساعة تم قتل الفئران ومعايرتها بمؤشرات السمية الكبدية النسيجية والكيميائية الحيوية.

النتائج: خفض المستخلص الإيثانولي لورق موسانجا سيكريبيوديز بشكل ملحوظ ارتفاع الأسبارتايت أمينو ترانزفيريز والألانين أمينو ترانزفيريز والألكالين فوسفاتيز والبيلبيروبين المترافق والبيلبيروبين الكلي الناتج عن التسمم برابع كلوريد الكربون في الفئران. لم يكن هناك تغيير كبير في مؤشرات الدم أو تغيرات الوزن بعد تناول المستخلص الإيثانولي لورق موسانجا سيكريبيوديز. كشفت الفحوصات النسيجية عن وجود أجسام انقسامية في الفئران المعالجة بالمستخلص الإيثانولي لورق موسانجا سيكريبيوديز بتركيز (١٤.٤ مجم / كجم)، وهو مؤشر على عمليات إصلاح الأنسجة.

الاستنتاجات: لورق موسانجا سيكريبيوديز تأثير واثق للكبد متناسب مع الجرعة، وبالتالي فإن استخدام مستخلصات ورقه لعلاج التهاب الكبد يتطلب الحذر.

الكلمات المفتاحية: تسمم الكبد؛ حماية الكبد؛ التشريح المرضي؛ جهد الأكسدة؛ ورقة موسانجا سيكريبيوديز

Abstract

Objective: Natural antioxidant products are gaining popularity as treatments for various pathological liver injuries. *Musanga cecropioides* (Urticaceae) leaf extract is used in ethnomedicine for the management of jaundice and other hepatic ailments in Ibibio, Nigeria. This study evaluated the hepatoprotective and antioxidant effects of *M. cecropioides* hydromethanolic leaf (MCHL) extract against carbon tetrachloride (CCl₄)-induced hepatotoxicity in rats.

Methods: Liver damage was induced by administering CCl₄ dissolved in liquid paraffin (2 mL/kg bw 1:1 intraperitoneally) after pretreatment with MCHL extract for 7

* Corresponding address: Department of Experimental Pharmacology and Toxicology, Faculty of Pharmaceutical Sciences, University of Port Harcourt, Choba, East-West Road, Rivers State, Nigeria.

E-mail: lucky.nwidi@uniport.edu.ng (L.L. Nwidi)

Peer review under responsibility of Taibah University.



days. Thereafter, acute hepatotoxicity was evaluated in 36 Wistar rats divided into six groups (A–F) of six animals each. Group A served as the negative control; B received CCl₄ 1 mL/kg only; C–E received 70.7, 141.4, and 282.8 mg/kg MCHL extract, respectively; and F received silymarin 100 mg/kg daily for 7 days by oral gavage. After 48 h, the rats were sacrificed, and samples obtained from them were assayed for histological and biochemical biomarkers of hepatotoxicity.

Results: The MCHL extracts significantly ($p < 0.001$ – 0.05) reduced the increase in aspartate aminotransferase (AST), alanine aminotransferase (ALT), alkaline phosphatase (ALP), conjugated bilirubin (CBIL), and total bilirubin (TBIL) levels induced by CCl₄ intoxication. There was no significant alteration in haematological indices or weight following administration of the MCHL extracts. Histopathological examinations revealed mitotic bodies in the 141.4 mg/kg MCHL extract-treated rats, an indication of tissue repair processes.

Conclusion: The MCHL extract has a dose-specific hepatoprotective effect; hence, the utilisation of this extract for the management of hepatitis requires caution.

Keywords: Hepatotoxicity; Hepatoprotection; Histopathology; *Musanga cecropioides* leaf; Oxidative stress

© 2018 The Authors.

Production and hosting by Elsevier Ltd on behalf of Taibah University. This is an open access article under the CC BY-NC-ND license (<http://creativecommons.org/licenses/by-nc-nd/4.0/>).

Introduction

Musanga cecropioides (Cecropiaceae) is commonly called African cork wood tree or umbrella tree. The local names are Aga agbawo (Yoruba), Ulu (Igbo), and Odzuma (Ghana). It is an erect, rapidly growing tree of the deciduous tropical West African rainforest. It is abundant in swampy forests, riverside, or lakeside at altitudes of 700–1200 m. The tree grows up to 20 m in height with an umbrella-shaped crown, straight and cylindrical trunk (up to 2 m in girth), and stilt adventitious roots of up to 3 m above ground level. The botany of *M. cecropioides* has already been reported.^{1–4}

In the traditional medicine of the Ibibio of the South–South region of Nigeria, infusion of the *M. cecropioides* leaf and stem bark is used for the treatment of fever, jaundice, acute gastric poisoning, and liver diseases. A *M. cecropioides* decoction is used in the management of menstruation pain, induction of labour, and lowering of elevated blood pressure and high blood sugar levels, and as a dehydrant, expectorant, anthelmintic, anti-dysenteric, and analgesic; it is also commonly used in ethnomedicine to treat asthenia in infants and restore appetite.³ The sap is drunk as a blood-purifier; for cleansing the stomach; for management of blennorrhoea, cough, and chest infections; as a galactagogue; and commonly as a wash for persons with sleeping sickness, leprosy, and fever to relieve aches and pains and rheumatism.^{3,5}

Pharmacological studies have established the uterotonic,⁶ oral hypotensive,^{3,7} hypoglycaemic, and antidiabetic effects⁸ of *M. cecropioides*. The compounds isolated from *M. cecropioides* include kalaic acid, triterpenoid acids,⁶ and bioactive compounds such as alkaloids, flavonoids, tannins, free and bound anthraquinone, saponin, and cardiac glycosides; anthocyanosides and cyanogenic glycosides were reported to be absent.⁹ *M. cecropioides* leaf extract contains isovitexin, vitexin, chlorogenic acid, catechin, and procyanidins.¹⁰

Despite its enormous and profound uses, no scientific evidence is available to justify the use of *M. cecropioides* leaf extract in Ibibio traditional medicines. This study was therefore designed to validate the claim of hepatoprotective efficacy of *M. cecropioides* hydromethanolic leaf (MCHL) extract in the treatment of liver diseases and to elucidate the possible mechanism(s) of actions. In this investigation, an experimental rat model of carbon tetrachloride (CCl₄)-induced acute liver injury was utilised, as it is known to generate lipid radicals that initiate the chain reactions of lipid peroxidation within and outside hepatic cells, causing liver damage.

Materials and Methods

General reagents and chemicals

CCl₄, silymarin, diethyl ether, and methanol were purchased from Sigma–Aldrich, St. Louis, Missouri, USA. Diagnostic kits for serum alanine aminotransferase (ALT), aspartate aminotransferase (AST), alkaline phosphatase (ALP), conjugated bilirubin (CBIL), and total bilirubin (TBIL) were purchased from Randox Laboratories Ltd. London, UK. Other chemicals and solvents were of the highest (analytical) grade commercially available and obtained from either Sigma–Aldrich or Merck, UK.

Plant collection and extraction

Fresh leaves of *M. cecropioides* were collected from Itak Ikpa Local Government area of Akwa Ibom State, Nigeria. The plants were collected by Mr. Etefia Okonand and identified by Mrs. Margaret Bassey of the Botany Department of University of Uyo, Uyo, Nigeria. The leaf was collected in January 2015 from the wild and the extract was stored for two months before use. A voucher specimen (UUH 2001) of the leaf was deposited at the herbarium of the Department of Pharmacognosy, University of Uyo, Uyo, Nigeria.

Preparation of *M. cecropioides* leaf extract

Fresh leaves of *M. cecropioides* were air-dried and powdered. The dry powder (300 g) was subjected to cold extraction via maceration in 50% methanol (solvent). The dry powder was soaked for a period of 72 h. The resultant mixture was shaken twice daily for proper extraction. Methanol was separated from the marc by filtration through a double-layer gauge. The filtrate was evaporated to dryness *in vacuo* at 55 °C. The yield obtained was 4.5%. The extract was stored in a refrigerator for up to four weeks for use in assays.

Phytochemical screening

The extract was qualitatively screened for the presence of alkaloids, saponins, anthraquinones, tannins, flavonoids, and cardiac glycosides by using standard methods described in the literature.¹¹

Experimental animals

Thirty-six healthy adult Wistar rats of either sex and with an average weight of 230–250 g were purchased from the animal house of the Department of Pharmacology, Niger Delta University, Bayelsa State. The animals were acclimatised for one week prior to the experiment. They were maintained under standard laboratory conditions (a 12:12-h dark/light period, 23 ± 2 °C temperature, and $55 \pm 5\%$ humidity). The animals were fed with a standard diet (normal commercial pellet diet) and with water *ad libitum*. All animal experiments conformed with the National Institute of Health Guide for Care and Use of Laboratory Animal (Pub No. 85-23, revised 1985) and were approved by the Niger Delta University Ethical Committee on the use of laboratory animals on February 20, 2015, via a circular (NDU/2014/007).

In vivo pharmacological study

Acute toxicity studies

The median lethal dose (LD₅₀) was determined by the method described by Lorke¹² with modification from the report of Perek et al.¹³ The Wistar albino rats used in this study were starved for 24 h with free access to water except for 2 h prior to experimentation. Varying doses (1000, 2000, 3000, and 5000 mg/kg i.p.) of the MCHL extract were administered to four groups of rats ($n = 3$) to establish the range of doses of the extract that would elicit toxic effects. The mice were observed for 24 h after treatment for signs of excitement, sluggishness, nervousness, alertness, convulsions, ataxia, or even death. The LD₅₀ was estimated by determining geometric means of the dose that caused 100% mortality and the dose that did not cause lethality.

Experimental design

Wistar albino rats of both sexes were randomised into six groups, each comprising six rats (three males and three females). The protocol used for the study was as follows: Group A was termed the negative control and received distilled water (0.2 mL/kg, p.o.) once daily for six days. Group B received distilled water (0.2 mL/kg bw by oral dosing). Groups C–E received 70.7, 141.4, and 282.8 mg/kg p.o. MCHL extract, respectively, once daily for seven days. Group F was treated with silymarin 100 mg/kg once daily by gavage for seven days. On the seventh day, groups B to F were treated with a mixture of freshly prepared CCl₄ in liquid paraffin (1 mL/kg bw, 1:1 intraperitoneally), the dose effective in a pilot study, 1 h after administration of the last treatment dose was administered. The body weights of all rats were recorded daily throughout the seven days of

treatment. Blood was obtained by cardiac puncture and collected into an EDTA vacutainer for determination of haematological parameters by using an automated SYS-MEX – KX21 Hematological Analyzer (SYSMEX Corporation, Japan). The haemoglobin (Hb) concentration, packed cell volume (PCV), red blood cell (RBC) count, mean corpuscular haemoglobin (MCH), mean corpuscular haemoglobin concentration (MCHC), mean corpuscular volume (MCV), white blood cell (WBC) count, and platelet count (PLC) were thus determined. For a biochemical assessment, blood was spun at 3000 rpm for 10 min at 4 °C to separate serum; serum was stored in vacutainer vials at 4 °C until analysis. Livers were immediately extracted and perfused with ice-cooled normal saline (0.9% sodium chloride) before utilisation in further analyses.

Estimation of biochemical parameters

The serum collected was used to determine ALT, AST, ALP, albumin (ALB), CBIL, TBIL, and total protein (TP) by using Randox diagnostic kits. These analyses were performed at the Department of Chemical Pathology, Niger Delta Teaching Hospital (NDUTH), Okolobiri, Bayelsa State, Nigeria.

The hepatoprotective activity (%) was determined using the following formula:

Hepatoprotective activity (%)

$$= [1 - ((HALA - W)/(RN - W))] \times 100$$

where MC, C, and W are the measured variables in rats treated with MCHL extract plus CCl₄, CCl₄, and distilled water, respectively.

Measurement of hepatic antioxidants/markers of lipid peroxidation

Liver tissues from the experimental animals were perfused with ice-cold saline and transported from the laboratory of Faculty of Pharmacy Pharmacology, Niger Delta University, on dry ice to the School of Medicine, University of Nottingham, Royal Derby Hospital Centre, Derby, UK, and stored at –80 °C until used for the assay of hepatic antioxidant enzymes. Liver pieces (100 mg) were diced and homogenised in 100 mL of 5 mM Tris/HCl buffer (pH 7.4), 1 mM EDTA and complete mini protease inhibitor cocktail (Roche). The homogenates were centrifuged at 10,000 rpm for 10 min at 4 °C and the clear supernatant used for the estimation of antioxidant parameters (glutathione [GSH], superoxide dismutase [SOD], catalase [CAT], and thiobarbituric reacting substances [TBARS]).

GSH levels

GSH levels were determined based on the method described by Ellman,¹⁴ with slight modifications. A homogenate (0.2 mL) was mixed with 25% TCA and centrifuged at 3000 rpm for 10 min. The supernatant (0.2 mL) was mixed with 10 mM 5,5'-dithiobis-(2-nitrobenzoic acid (DTNB) in the presence of phosphate buffer (0.1 M, pH 7.4) and absorbance was read at 420 nm.

CAT activity measurements

A CAT assay was performed according to the method described by Aebi¹⁵ with slight modifications. The assay relies upon the ultraviolet absorption of hydrogen peroxide that can be measured at 240 nm. The decomposition of hydrogen peroxide in the presence of CAT on a quartz plate allows quantitation of catalase activity. Assays were performed in the presence of 50 mM phosphate buffer. Hydrogen peroxide decomposition was monitored in a 96-well quartz plate using a Spectramax (Thermo Fisher) microplate reader. CAT activity was expressed as units/mg protein.

SOD activity measurements

Liver cytosolic SOD activity was measured according to the method described by Kakkar et al.¹⁶ Cytosol (0.05 mL) was mixed with sodium pyrophosphate buffer (0.052 M, pH 8.3, 1.2 mL), phenazine methosulphate (0.186 mM, 0.1 mL), nitroblue tetrazolium chloride (0.3 mM, 0.3 mL), and NADH (0.78 mM, 0.2 mL). The reaction was stopped after 90 s by the addition of glacial acetic acid. The colour intensity of the chromogen was extracted in butanol solution (2.0 mL) with vigorous shaking. The mixture was then centrifuged at 3000 rpm for 10 min, the supernatant was extracted, and the absorbance at 560 nm was determined using the Spectramax microplate reader.

Determination of TBARS

Lipid peroxidation was determined spectrophotometrically by measuring the level of the lipid peroxidation product, malondialdehyde (MDA), as described by Draper and Hadley.¹⁷ MDA reacts with thiobarbituric acid (TBA) to form a red/pink-coloured complex, which absorbs maximally in an acid solution at 532 nm. Spectrophotometric measurements were recorded using the Spectramax microplate reader.

Histopathological studies

A portion of the liver was cut into pieces of approximately 6 mm³ in size and fixed in 10% phosphate-buffered formaldehyde solution. These liver pieces were embedded in paraffin wax before thin sections of 5 µm in thickness were

stained with haematoxylin-eosin (H&E). These thin liver sections were made into permanent slides and examined under a high-resolution microscope (Olympus BX60MF, Japan), after which photomicrographs were taken at a magnification of 400×.

Statistical analysis

All statistical measures were performed using PRISM 5 (GraphPad Software Inc., San Diego, California USA). Unless specified otherwise, results are expressed as the mean ± standard error of the mean (SEM) values. One-way analysis of variance (ANOVA) was used to compare group data, followed by Tukey's multiple comparisons test. A *p* value of <0.05 was considered significant.

Results

In vivo pharmacological assay

Haematological analysis

The effect of MCHL extract on haematological indices of rats with CCl₄-induced hepatotoxicity is shown in Table 1. Treatment with the 70.7 mg/kg and 141.8 mg/kg doses of the extract significantly (*p* < 0.05) increased the WBC count and lymphocyte and neutrophil counts, respectively, compared to the corresponding counts in the control group. No significant effects were observed on the other haematological parameters investigated.

Effect of MCHL extract on hepatic enzyme markers

The effects of administration of MCHL extracts on liver biomarker enzymes are shown in Table 2. ALT, AST, and ALP levels significantly (*p* < 0.001) increased by 49%, 64%, and 38% respectively. TP and ALB levels significantly (*p* < 0.001) decreased by 30% and 132% respectively in the 70.7 mg/kg MCHL extract-treated group. CBIL and TBIL significantly increased by 187% and 163%, respectively, following intoxication with CCl₄ compared to the values in the negative control group (*p* < 0.05 and *p* < 0.01, respectively). However, following pretreatment with MCHL extracts at doses of 70.7, 141.4, and 282.8 mg/kg and silymarin at 100 mg/kg, TP levels significantly (*p* < 0.01–0.001) increased compared to those in the CCl₄ group; the percentage hepatoprotection observed

Table 1: Phytochemical constituents of *Musanga cecropioides* hydromethanolic leaf extracts.

Phytochemicals	Test	Observations	Inference
Alkaloids	2 mL of MCHL extract + 2 mL of Dragendoff reagent	Dark orange precipitate	+
Saponins	2 mL of extract shaken vigorously to observe the reaction	Persistent froth unbroken upon standing	++
Antraquinone	2 mL of extract + 10 mL of benzene, followed by the addition of 5 mL of 10% ammonia solution to the filtrate	Presence of reddish colour	–
Tannins	2 mL of MCHL extract + FeCl ₃	Resultant solution turns woolly brown	+
Flavonoid	2 mL of MCHL extract + 2 mL of 10% lead acetate	Yellowish green precipitate	+
Cardiac glycosides	2 mL of MCHL extract mixed with 2 mL of chloroform + CH ₂ SO ₄ carefully added	Deep reddish-brown colour at the interface and a steroid ring	+

(+) to (++) = detected in scant to moderate quantities.

MCHL: *Musanga cecropioides* hydromethanolic leaf.

Table 2: The effect of *Musanga cecropioides* hydromethanolic leaf extracts on CCl₄-induced hepatotoxicity, as indicated by haematological indices.

Parameter	Group A	Group B	Group C	Group D	Group E	Group F
PCV (%)	50 ± 6.7	40 ± 9.8	45 ± 3.0	42 ± 9.1	44 ± 6.1	43 ± 5.1
Hb (g/dl)	14 ± 1.7	12 ± 2.7	14 ± 1.0	13 ± 2.0	12 ± 2.8	12 ± 1.5
WBC (×10 ³ cells/μL)	13 ± 4.0	6.7 ± 2.3 ^a	6.9 ± 2.5 ^a	12 ± 4.1	12 ± 1.5	11 ± 2.3
PLT (×10 ³ cells/μL)	1002 ± 290	323 ± 361	325 ± 301	458 ± 226	734 ± 673	273 ± 178
RBC (×10 ⁶ cells/μL)	8.0 ± 1.0	6.5 ± 1.9	7.6 ± 0.6	7.3 ± 1.7	7.3 ± 0.9	7.5 ± 1.0
MCV (%)	62 ± 2.5	59 ± 3.6	59 ± 3.4	58 ± 2.6	60 ± 5.9	57 ± 3.1
MCH (pg)	18 ± 0.9	17 ± 1.5	17 ± 1.4	18 ± 2.6	16 ± 3.0	16 ± 2.3
MCHC (g/dl)	28 ± 0.7	30 ± 1.7	29 ± 1.2	31 ± 4.1	29 ± 0.8	29 ± 1.1
NEU (%)	38 ± 8.2	51 ± 8.0	44 ± 12	56 ± 11 ^a	37 ± 8.3	45 ± 13
LYM (%)	63 ± 8.7	42 ± 7.1	48 ± 13	39 ± 13 ^a	56 ± 8.8	49 ± 1.5
MEB (%)	4.7 ± 1.6	6.6 ± 1.1	7.5 ± 2.9	5.8 ± 2.8	7.0 ± 2.9	6.7 ± 2.5

Values represent mean ± SEM, n = 6. Results are displayed relative to positive control values; ^ap < 0.05; statistical analysis was performed using one-way ANOVA. Group A received 0.2 mL/kg distilled water; B received CCl₄ 1 mL/kg; C received 70.7 mg/kg MCHL extract + 1 mL CCl₄; D received 140.4 mg/kg MCHL extract + 1 mL CCl₄; E received 282.8 mg/kg MCHL extract + 1 mL CCl₄; G received 100 mg/kg silymarin.

Abbreviations: PCV: packed cell volume, Hb: haemoglobin, WBC: white blood cells, PLT: platelets, RBC: red blood cells, MCV: mean corpuscular volume, MCH: mean corpuscular haemoglobin, MCHC: mean corpuscular haemoglobin concentration, NEU: neutrophils, LYM: lymphocytes; MEBs: monocytes, eosinophils, and basophils.

was 102%, 100%, 137%, and 137%, respectively. Similarly, ALT, AST, ALP, CBIL, and TBIL levels decreased significantly ($p < 0.05$ – 0.001) following pretreatment with the MCHL extract. In the group treated with the 70.7 mg/kg MCHL extract, the percentage hepatoprotection for ALT, AST, ALP, CBIL, and TBIL was 130%, 128%, 127%, 130%, and 124%, respectively. The corresponding values for the group treated with the 141.4 mg/kg MCHL extract were 182%, 140%, 104%, 127%, and 116%. The group treated with the highest dose of the MCHL extract (282.8 mg/kg) showed no significant hepatoprotection for these enzyme biomarkers. The percentage hepatoprotection afforded by the pure drug silymarin at 100 mg/kg was 168%, 102%, 116%, 105%, 127%, 103%, and 100% for TP, ALT, AST, ALP, ALB, CBIL, and TBIL, respectively.

Phytochemical studies

A preliminary phytochemical screening of the MCHL extract revealed the presence of alkaloids, saponins,

anthraquinone, tannins, flavonoids, and cardiac glycosides. The extract contained these bioactive agents in moderate amounts as shown in Table 3.

Acute toxicity

The MCHL extract was found to be toxic at doses of >2000 mg/kg. At 24 h, the numbers of dead/live animals after treatment with 100, 200, 300, and 500 mg/kg were 0/3, 3/3, 3/3, and 3/3, respectively. The LD₅₀ was found to be 1414.2 mg/kg. This justifies the use of MCHL extract doses of 70.7, 141.8, and 282.8 mg/kg as the 1/20th, 1/10th, and 1/5th LD₅₀ dose used in this study.

Histopathological examination

The effects of 70.7, 141.8, and 282.8 mg/kg MCHL extracts and 100 mg/kg silymarin on the liver histology of CCl₄-intoxicated rats are shown in Figure 1. The section of the control rat liver shows normal sinusoidal spaces with a

Table 3: Effect of MCHL extract on biochemical parameters.

Treatment	Dose	TP	ALT	AST	ALP	ALB	CBIL	TBIL
	(mg/kg)	(g/dl)	(IU/L)	(IU/L)	(IU/L)	(g/dL)	(mg/dL)	(mg/dL)
Control	0.0	17.7 ± 0.7	52.3 ± 2.4	41.7 ± 3.8	56.7 ± 1.2	8.6 ± 0.3	10.9 ± 0.2	16.7 ± 0.9
Positive Control	1 mL/kg CCl ₄	13.6 ± 0.03 ^{***}	102.9 ± 1.1 ^{***}	116.7 ± 0.9 ^{***}	91.0 ± 3.2 ^{***}	3.7 ± 0.3 ^{***}	31.3 ± 0.2 ^{***}	44.0 ± 0.6 ^{***}
MCHL extract	CCl ₄ + 70.7	17.8 ± 0.7 ^{***}	67.3 ± 0.3 ^{***}	62.6 ± 0.8 ^{***}	66.0 ± 1.2 ^{***}	8.3 ± 0.7 ^{***}	17.0 ± 1.1 ^{***}	22.0 ± 0.9 ^{***}
	CCl ₄ + 141.4	18.2 ± 0.3 ^{***}	43.1 ± 1.7 ^{***}	30.2 ± 1.8 ^{***}	55.3 ± 3.0 ^{***}	8.2 ± 0.2 ^{***}	16.5 ± 0.2 ^{***}	20.2 ± 0.6 ^{***}
	CCl ₄ + 282.8	16.2 ± 0.2 [*]	93.1 ± 1.7	100.2 ± 1.6	82.2 ± 3.9	5.6 ± 0.3	28.8 ± 2.0	42.9 ± 3.1
Silymarin	CCl ₄ + 100	16.4 ± 0.3 [*]	53.3 ± 0.1 ^{***}	53.7 ± 0.3 ^{***}	55.0 ± 2.6 ^{***}	7.3 ± 0.6 ^{***}	10.2 ± 0.1 ^{***}	17.2 ± 0.6 ^{***}

Values represent means ± SEM, n = 6. Significant results of extracts and pure drug are displayed relative to positive control values; and positive control displayed relative to healthy (negative) control; results with significant changes from controls are marked with asterisks. For significance: ^{*}p < 0.05; ^{**}p < 0.01 and ^{***}p < 0.001. Statistical analysis was performed using one-way ANOVA.

Abbreviations: MCHL extract, *Musanga cecropioides* hydromethanolic extract; TP: total protein; ALT: alanine aminotransferase; AST: aspartate aminotransferase; ALP: alkaline phosphatase; ALB: albumin; CBIL: conjugated bilirubin; TBIL: total bilirubin.

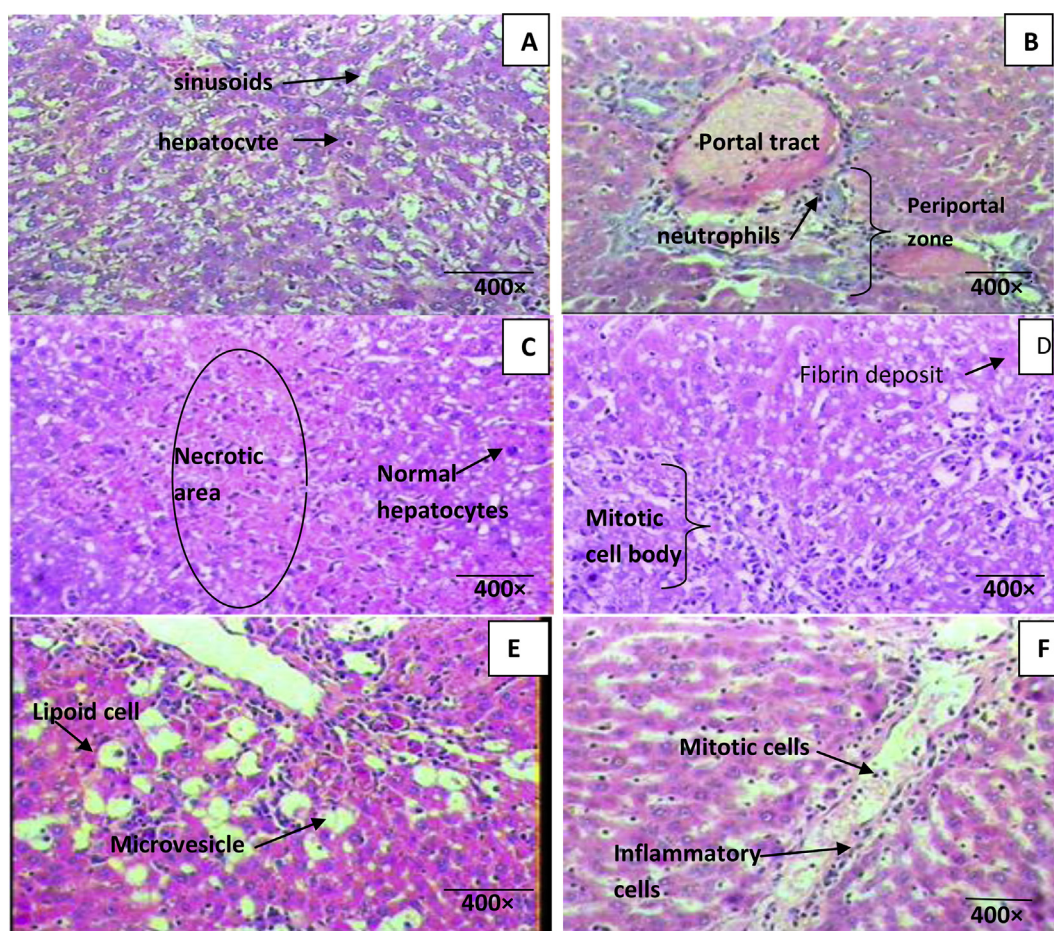


Figure 1: Photomicrographs showing the effect of MCHL extract and silymarin on liver histopathology of CCl₄-treated rats; stains: haematoxylin & eosin; magnification, ×400. **A.** Vehicle-treated control liver tissue showing normal liver architecture with prominent hepatocytes and numerous sinusoids. **B.** CCl₄-treated control group section or liver biopsy showing ballooning degeneration, massive fatty infiltration, and recruitment of inflammatory cells (predominantly neutrophils) within the portal tract and periportal zone, indicating insult. **C.** Section from the group treated with the MCHL extract (70.7 mg/kg dose) and CCl₄ showing an area of localized and complete necrosis amidst viable hepatocytes. **D.** Section from the group treated with the MCHL extract (141.4 mg/kg dose) and CCl₄ showing fibrin deposition and numerous mitotic bodies, indicating healing. **E.** Section from the group treated with the MCHL extract (282.8 mg/kg dose) and CCl₄ showing moderate hepatic distension with multiple microvesicles, few lipid cells, and inflammatory cells within the portal tract, indicating injury. **F.** Section from the group treated with silymarin (100 mg/kg) and CCl₄ showing an area of necrosis with numerous mitotic bodies, indicating hepatocyte regeneration. MCHL: *Musanga cecropioides* hydromethanolic leaf; CCl₄: carbon tetrachloride.

non-congested portal tract, differentiated blood vessels, and viable hepatocytes (Figure 1A). Liver sections of rats intoxicated with CCl₄ indicate marked extensive necrosis, steatosis, ballooning degeneration, gross mononuclear infiltration, and loss of cellular boundaries of the hepatocytes (Figure 1B). Pretreatment with the 70.7 mg/kg MCHL extract showed minor amelioration of the histopathological architecture truncated by CCl₄ intoxication. Hepatocytes with an area of localized and complete necrosis amidst viable hepatocytes were seen, indicating that the hepatocyte insult (induced by CCl₄) was not yet fully resolved at this dose of MCHL extract (Figure 1C). Following pretreatment with the 141.4 mg/kg MCHL extract, areas of fibrin deposition and numerous mitotic bodies were observed, indicating a healing process and signs of hepatoprotection at this dose (Figure 1D). Hepatocytes of the rats treated with 282.8 mg/kg MCHL

extract showed multiple microvesicles, few lipid cells, and numerous inflammatory cells within the portal tract, indicating injury and that this dose is not fully hepatoprotective (Figure 1E). Following treatment with the pure drug, silymarin, at 100 mg/kg, liver tissue with numerous mitotic bodies was observed, demonstrating hepatocyte regeneration and that silymarin is hepatoprotective.

Effect of MCHL extracts on hepatic antioxidants and markers of lipid peroxidation

To assess the effects of pretreatment with the MCHL extract (70.7, 141.4, and 282.8 mg/kg) on oxidative stress markers following acute CCl₄ intoxication in rats, we assayed liver homogenates for antioxidant capacity by measuring CAT, GSH, SOD, and TBARS.

Liver GSH, CAT, and SOD levels were significantly ($p < 0.001$) reduced by 48%, 41%, and 31%, respectively, after CCl_4 intoxication compared to the corresponding levels in the positive controls. However, only pretreatment with MCHL (141.4 mg/kg) significantly ($p < 0.01$ – 0.05) increased GSH, CAT, and SOD levels to 53%, 41%, and 21% while silymarin (100 mg/kg) treatment significantly ($p < 0.01$ – 0.001) increased GSH, CAT, and SOD levels by 75%, 50%, and 22%, respectively, compared to the levels in the CCl_4 -intoxicated group. The effects of other doses of the extract were not significant (Figure 2).

Lipid peroxidation activity in the liver significantly ($p < 0.001$) increased to 70% after CCl_4 intoxication compared to that in the negative control; however, pretreatment with the 141.1 mg/kg MCHL extract significantly ($p < 0.05$) decreased the lipid peroxidation level by 18%. On the other hand, pretreatment with silymarin significantly ($p < 0.001$) reduced lipid peroxidation by 26% of that in the positive controls. The lowest and highest doses of the extract had no significant effect on lipid peroxidation levels.

Body weight evaluation

The effects of MCHL extracts on body weight gain in the rats are shown in Figure 3. The MCHL extracts led to a dose-dependent and non-significant ($p > 0.05$) increase in body weight gain compared to the initial depression in weight following the CCl_4 insult.

Discussion

Hepatotoxic insults commonly occur due to environmental factors, industrial chemicals, drugs, and diseases such

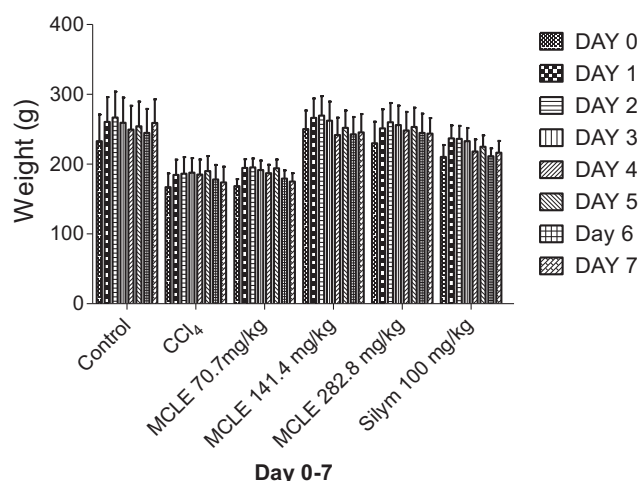


Figure 3: The effect of CCl_4 , MCHL extract, and silymarin on weight gain in rats through the course of the experiment. Data presented above demonstrates that there were no significant effects of the MCHL extract on the weights of the animals. MCHL: *Musanga cecropioides* hydromethanolic leaf; CCl_4 : carbon tetrachloride.

as viral hepatitis, which account for the profound morbidity and mortality from liver diseases.^{18–20} The participation of hepatic cells in a variety of metabolic activities including biotransformation and excretion of chemical agents makes the liver more vulnerable and susceptible to toxicity from these agents.²¹ Liver damage is predicated on lipid peroxidation and cell necrosis.²² This may be an emerging threat in the Niger Delta environment, where there is a

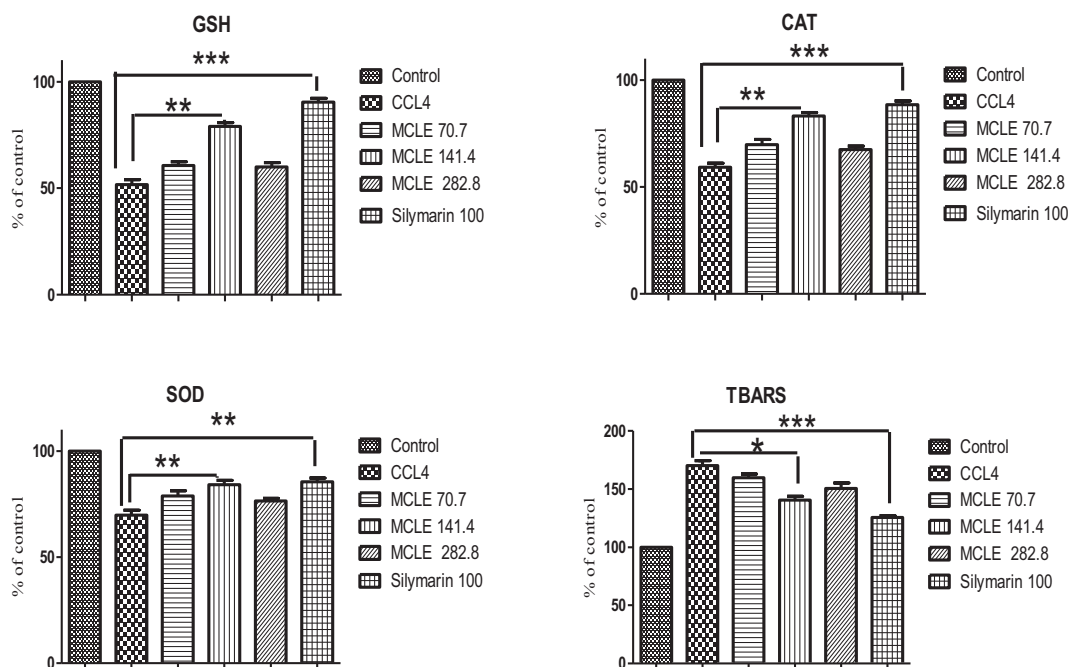


Figure 2: Effects of MCHL extract on markers of oxidative stress. Levels of oxidative stress markers (GSH, CAT, SOD, and TBARS) were measured in homogenised liver samples. Histograms represent mean \pm SEM values, with significant changes marked with asterisks. For significance: * $p < 0.05$; ** $p < 0.01$; *** $p < 0.001$. GST: glutathione; CAT: catalase; SOD: superoxide dismutase; TBARS: thiobarbituric acid reactive substances; MCHL: *Musanga cecropioides* hydromethanolic leaf; CCl_4 : carbon tetrachloride.

massive release of hydrocarbon toxicants from petroleum exploration and exploitation and natural gas-flaring activities are ubiquitous. Some of the hydrocarbons released are likely to be hepatotoxins, as anicteric hepatotoxicity has been reported as a potential health effect of long-term occupational exposure in the petroleum refining and distribution industry in Nigeria.²³ The paucity of prognosis of hepatotoxicity is aggravated by poor treatment or untreated infective hepatitis, late presentation at hospitals for treatment, alcoholism, and drug abuse and misuse, which account for the condition becoming a medical emergency.²⁴

There is an acute lack of availability of effective drugs that can stimulate liver function and protect the liver from damage or help regenerate hepatic cells.²⁵ Herbal drugs have received considerable attention recently because of their safety, efficacy, and cost-effectiveness.²⁶ One of the important and well-documented uses of plant products is their use as hepatoprotective agents.^{27–29} There is a growing need for safe hepatoprotective agents; hence, several medicinal plants have been extensively studied for the management of liver disorders.^{26,29,30} The literature indicates that hepatoprotection is possible with plant extracts rich in antioxidants.^{31,32} Some plant extracts have already been reported to possess strong antioxidant activities,³³ and their protective effects are considered, in large part, to be related to the various constituent antioxidants.³⁴

Anecdotal information from a personal communication to Nwidi LL indicated that an infusion of MCHL extract is taken by the Effik people of Akwa Ibom state in Nigeria for liver regeneration. The effects on haematological indices revealed that the MCHL extract does not exhibit any profound effects on haematological parameters. Intoxication with CCl₄ significantly ($p < 0.05$) reduced the WBC count and the MCHL extract-treated groups exhibited a dose-dependent increase in leucocytes compared to that in the positive controls. This finding suggests that the extract probably contains agent(s) that upregulate the proliferation of leucocytes. The presence of such agents has been reported in *Viscum album* (mistletoe).^{35,36} This suggests that the extract may have immune-boosting effects on the animals, possibly via an increase in vascular permeability. The MCHL extract produced no significant dose-dependent increase in the PLC. However, decreased platelet survival has been reported in liver cirrhosis,³⁷ and an increase in PLC has been reported to stimulate hepatic regeneration.³⁸ Although increases in some haematological indices such as RBC count, PCV, Hb, MCV, MCH, and MCHC were observed, these were not statistically significant ($p > 0.05$). Since plants contain a combination of biomolecules, it can, therefore, be inferred that some of the active components in this plant might, in part, act on the bone marrow to stimulate the production and differentiation of haematopoietic stem cells.^{39,40}

The liver plays a significant role in detoxification and metabolic biosynthetic processes such as synthesis of plasma proteins and gluconeogenesis.^{41,42} The liver hepatocyte-regenerative capacity if overwhelmed might result in a gradual loss of tissue function, leading to liver disorders.⁴³ Acute hepatocellular injury can be induced by various hepatotoxins, including CCl₄ and high-dose acetaminophen.^{31,44–46} CCl₄ is biologically inactive and a stable

compound.⁴⁷ However, it becomes a highly reactive halogenated aromatic hydrocarbon when it undergoes biotransformation by cytochrome P₄₅₀ in the hepatic endoplasmic reticulum to form a highly reactive and unstable trichloromethyl radical.^{48,49} The latter in the presence of oxygen is metabolised to peroxides and chloroform, which overwhelm the antioxidant capacity of the liver, leading to oxidative denaturation of unsaturated fatty acids of lipid membranes and thereby causing severe liver damage and membrane leakage.⁵⁰ This is the fundamental mechanism of lipid peroxidative degradation of membranes by CCl₄.⁵¹ Damaged liver cells release liver-specific enzymes into the bloodstream, such as AST, ALT, and ALP, which are used as biomarkers of liver damage and indicators for evaluating the effectiveness of therapeutic agents.^{52,53}

To validate the protective effects of MCHL extract on the liver enzymes, CCl₄-induced hepatotoxicity was investigated. Significant elevations in the levels of ALT, AST, and ALP, and serum CBIL and TBIL were observed, reflecting cellular damage and hepatotoxicity.^{46,54} Pretreatment with the MCHL extract before application of CCl₄ led to a significant decrease in the levels of liver biomarker enzymes AST, ALT, and ALP and serum TBIL and CBIL ($p < 0.001$). This finding is in agreement with reports that serum levels of biomarker enzymes return to near-normal levels with the healing of the hepatic parenchyma and the regeneration of hepatocytes.⁵⁵ This suggests that the MCHL extract accelerates the healing mechanism of the liver.

Adeneye et al. (2009) evaluated the hepatoprotective effect of the stem bark of *M. ceropioides* and observed that graded doses (125–500 mg/kg) attenuated CCl₄-induced or acetaminophen-induced hepatocellular injury in a dose-dependent fashion.⁴⁴ This finding supports our findings, in that it suggests that the bioactive agents affording hepatoprotection are similar and present within both the stem bark and the leaves; however, this will need to be evaluated in future studies.

Reports indicate that TP and albumin are downregulated following CCl₄ intoxication, suggesting liver damage.⁵⁶ Pretreatment with MCHL extracts increased the levels of serum TP ($p < 0.001$), and albumin ($p < 0.01–0.001$). Stimulation of protein synthesis has been postulated as a contributing hepatoprotective mechanism, which accelerates tissue production and regeneration.⁵⁷

Damage to the liver might impair its ability to excrete normal amounts of bilirubin or cause obstruction of excretory ducts of the liver.⁵⁸ Pretreatment with either MCHL extract or silymarin effectively limited the elevation of the biliary markers, ALP, and bilirubin levels (CBIL and TBIL). This suggests that the MCHL extract enhances the hepatic cell-secretory mechanism and has hepatoprotective potential.

The percentage hepatoprotection afforded by 70.7 and 141.4 mg/kg MCHL extract/silymarin 100 mg/kg for each biomarkers is as follows: ALT, 130% and 182%/102%; AST, 128% and 140%/116%; ALP, 127% and 104%/105%; CBIL, 130% and 127%/103%; and TBIL, 124% and 116%/100%, respectively. This result indicates that the MCHL extract (70.7 and 141.4 mg/kg) has a more potent hepatoprotective effect than that of silymarin (100 mg/kg). However, the highest dose of the MCHL extract (282.8 mg/kg) extract did

not show significant hepato-protection for these enzyme biomarkers.

Insults to the liver cytoarchitecture and histomorphological alterations following acute exposure of the hepatocytes to CCl_4 are expected. The commonly reported structural changes in the hepatocytes are sinusoidal dilation, congestion, inflammation, intense degeneration, vacuolisation, pyknotic nuclei of necrotic cells with eosinophilic cytoplasm, nodular cellular damage, and hypertrophic cell structures.^{59–61} In this study, gross alteration of the liver cytoarchitecture was noted in the CCl_4 -treated group. Cytoarchitectural irregularities were observed in the parenchymal structure, with an indistinguishable classical lobular structure. Treatment with the 141.4 mg/kg MCHL extract ameliorated the CCl_4 -induced damage and induced the generation of mitotic bodies, which is indicative of a regenerative process⁶² and suggestive of hepatoprotective potential. However, the highest dose of the extract was not effective, and perhaps the extract has pro-oxidant properties at high doses.

The level of TBARS, the end product of lipid peroxidation, was upregulated in the CCl_4 -intoxicated group but pretreatment with the MCHL extract (141.4 mg/kg) significantly ($p < 0.05$) decreased TBARS levels, which was presumably a reflection of cell membrane repair observed in the hepatocytes of the extract-treated group as evidenced in the cytoarchitecture of the liver. In response to oxidative stress, the cells affected are protected against oxidative insults via upregulation of the endogenous antioxidant system including GSH, CAT, and SOD.³⁰ SOD catalyses the oxidative dismutation of superoxide radicals to molecular oxygen and hydrogen peroxide, and CAT converts hydrogen peroxide to molecular oxygen and water.⁶⁹ The antioxidant system can easily be overwhelmed by an excess of lipid peroxides and reactive oxygen species and a resultant decline in the antioxidant system may render hepatocytes vulnerable to toxic insults.⁶³ A decrease in the levels of the antioxidant-system enzymes, CAT, SOD, and GSH in CCl_4 intoxication studies has been reported.^{30,41,64} GSH is an endogenous scavenger of free radicals and its serum level is a sensitive biomarker of antioxidant status.^{65,66} The pathophysiological consequences of a decline in GSH level have been widely investigated; a decline in the liver GSH level hinges frequently on hepatic fatty infiltration in different experimental models^{67–69} A decrease in the levels of GSH, glutathione (GST), and glutathione peroxidase (GPx) induces the production of reactive oxygen species and oxidative stress with subsequent cascading effects on the functional and structural integrity of cell and organelle membranes.⁶⁴ The reduction of the serum GSH level associated with CCl_4 intoxication in the hepatotoxic group may, in part, be related to free radical generation. Pretreatments with the MCHL extract mediate an increase in the GSH level, which may be due to scavenging of free radicals by the extract. The 43% decrease in GSH levels in CCl_4 -intoxicated rats was significantly countered in a dose-dependent manner by pretreatment with the MCHL extract, as indicated by the histomorphological data and suggests tissue injury repair. The MCHL extract stimulated the recovery of antioxidant potential in the circulation, as indicated by the marked elevation of GSH level and a

decrease in oxidative stress-induced damage in the histopathology data. It has been established that the liver maintains GSH even under the condition of elevated lipid peroxidation due to a supportive and compensatory mechanism.^{66,70}

No significant effect was observed on the body weights of the treated rats throughout the duration of the study. The effectiveness of the MCHL extract against hepatitis may be attributable to the presence of phytochemical constituents such as phenolic acids and flavonoids.^{9,10} Phenolics are widely reported to present excellent antioxidant effects against peroxyl and hydroxyl radicals while flavonoids act as hydrogen donors and metal chelators.^{71,72} Currently, further investigation is ongoing in our laboratories to elucidate the bioactive agents and the biochemical mechanism responsible for antioxidant and hepatoprotection by the MCHL extract.

Conclusion

Our study further supports the ethnomedicinal use of the components of *M. cecropioides* in treating jaundice and hepatitis. The stem bark,⁴⁴ or leaf extract reported herein, may provide suitable hepatoprotection to liver toxins if utilised at an appropriate dose. The MCHL extract may be hepatotoxic at high doses; hence, caution should be exercised when choosing a dose for the management of liver injury.

Conflict of interest

The authors disclose receipt of the following financial assistance for the research, authorship, and or/publication of this article: Niger Delta University 3-month sabbatical fellowship and International Visiting Fellowship of the University of Nottingham, United Kingdom to WGC to host LLN and EE.

Authors' contributions

Conception and design, collection and assembly of data, drafting of the article and final approval of the article, administrative, technical and logistic support: LLN. Analysis and interpretation of data, statistical expertise: EE. Histopathological analysis and interpretation of results: YIO. Critical revision of the article for the important intellectual content, provision of study materials and obtaining of funding: WGC. All authors have critically reviewed and approved the final draft and are responsible for the content and similarity index of the manuscript.

Acknowledgements

We would like to acknowledge the technical support of Mr. Obi Cosmas, the technologist attached to the Pharmacology Department, and Mr. Obi Sompto for sourcing experimental animals for this project.

References

1. Adeneye AA, Ajagbonna OP, Mojiminiyi FB, Odigie IP, Ojobor PD, Etarrh RR, Adeneye AK. The hypotensive mechanisms for the aqueous stembark extract of *Musanga*

- cecropioides* in sprague-Dawley rats. **J Ethnopharmacol** 2006a; 106: 203–207.
2. Kamanyi A, Bopelet M, Tatchum TR. Contractile effect of some extracts from the leaves of *Musanga cecropioides* (Cecropiaceae) on uterine smooth muscle of the rat. **Phytother Res** 1992; 6: 165–167.
 3. Burkill HM. *Musanga cecropioides*. **Useful plants of West African**, 1; 1985. p. 12.
 4. Ayinde BA, Omogbai EKI, Onwukaeme DN. Pharmacognostic characteristics and hypotensive effects of the stem bark of *Musanga cecropioides*. **W Afr J Pharmacol Drug Res** 2003; 19: 37–41.
 5. Lontsi D, Sondengam BL, Bodo B, Martin MT. Kalaic acid, a new Ursane – type Saponin from *Musanga cecropioides*. **Planta Med** 1998; 1998(64): 189–191.
 6. Dongmo AB, Kamanyi A, Bopelet M. Saponins from the leaves of *Musanga cecropioides* constitute a possible source of potent hypotensive principle. **Phytother Res** 1996; 10: 23–27.
 7. Adeneye AA, Ajagbonna OP, Adeleke TI, Bello SO. Preliminary toxicity and phytochemical studies of the stem bark aqueous extract of *Musanga cecropioides* in rats. **J Ethnopharmacol** 2006b; 105: 374–379.
 8. Adeneye AA, Ajagbonna OP, Ayodele OW. Hypoglycemic and antidiabetic activities of the stem bark aqueous extracts of *Musanga cecropioides* in normal and alloxan-induced diabetic rats. **Fitoterapia** 2007; 78: 502–505.
 9. Kadiri AB, Ajayi GO. Phyto-anatomical characteristics of the West African {umbrella tree} *Musanga cecropioides* M. Smithii R. Br. (Moraceae). **Indian J Sci Technol** 2009; 2: 1–5.
 10. Buniyamin A, Ayinde D, Onwukaeme N, Eric KO. Isolation and characterization of two phenolic compounds from the stem bark of *Musanga cecropioides* R. Brown (Moraceae). **Acta Pol Pharm Drug Res** 2007; 64: 183–185.
 11. Trease GE, Evans WC. *A textbook of pharmacognosy*. London: Baillière Tindall; 2001. p. 600.
 12. Lorke D. A new approach to practical acute toxicity testing. **Arch Toxicol** 1983; 54: 275–289.
 13. Pareek A, Godavarthi A, Issarani R, Nagori BP. Antioxidant and hepatoprotective activity of *Fagonia schweinfurthii* (Hadidi) Hadidi extract in carbon tetrachloride induced hepatotoxicity in HepG2 cell line and rats. **J Ethopharm** 2013; 150: 973–981.
 14. Ellman GL. Tissue sulphhydryl groups. **Arch Biochem Biophys** 1958; 82: 70–77.
 15. Aebi HE. Catalase. In: Bergmeyer HU, et al., editors. *Methods of enzymatic analysis*. 3rd ed. New York: Academic Press; 1983. pp. 673–684.
 16. Kakkar P, Das B, Viswanathan PN. A modified spectrophotometric assay of superoxide dismutase. **Indian J Biochem Biol** 1984; 21: 130–132.
 17. Draper HH, Hadley M. Malondialdehyde determination as index of lipid peroxidation. **Meth Enzymol** 1990; 186: 421–431.
 18. Chitturi S, Farrell G. Drug-induced liver disease. In: Schiff ER, Sorrell MF, Maddrey WC, editors. *Schiff's diseases of the liver*. 9th ed. Philadelphia: Lippincott, Williams & Wilkins; 2002. pp. 1059–1128.
 19. Kaplowitz N. Drug-induced liver injury. **Clin Infect Dis** 2004; 38: S44–S48.
 20. Bhatt S, Kumar H, Sharma M, Saxena KK, Garg G, Singh G. Evaluation of hepatoprotective activity of *Aloe vera* in drug induced hepatitis. **World J Pharm Pharmaceut Sci** 2015; 4: 935–944.
 21. Wakawa HY, Franklyne EA. Protective effects of *Abrus precatorius* leaf extract against carbon tetrachloride-induced liver injury in rats. **J Nat Sci Res** 2015; 5: 15–19.
 22. Obidah W, Garba GK, Fate JZ, Wakawa HY. Protective effect of *Bixa orellana* seed oil on carbon tetrachloride induced liver damage in rats. **JOLORN** 2010; 11: 19–23.
 23. Ezejiofor TIN, Ezejiofor AN, Orisakwe OE, Nwigwe HC, Osuala FO, Iwuala MO. Anicteric hepatotoxicity: a potential health risk of occupational exposures in Nigerian petroleum oil refining and distribution industry. **J Occup Med Toxicol** 2014; 9: 3.
 24. Adesunkanmi ARK, Akinkuolie AA, Badru OS. A five year analysis of death in accident and emergency room of a semi-urban hospital. **W Afr J Med** 2002; 21: 99–104.
 25. Wakawa HY, Musa H. Protective effect of *Erythrina senegalensis* (DC) leaf extract on CCl₄-induced liver damage in rats. **Asian J Bio Sci** 2013; 6: 234–238.
 26. Brai BIC, Adisa RA, Odetola AA. Hepatoprotective properties of aqueous leaf extract of *Persea americana*, mill (lauraceae) 'avocado' against CCl₄-induced damage in rats. **Afr J Tradit, Complementary Altern Med** 2014; 11: 237–244.
 27. Ujowundu CO, Nwokedinobi N, Kalu FN, Nwaoguikpe RN, Okechukwu RI. *Ocimum gratissimum* in diesel petroleum induced hepatotoxicity in albino wistar rats. **J Appl Pharmaceut Sci** 2011; 1: 56–61.
 28. Aluko BT, Oloyede OI, Afolayan AJ. Hepatoprotective activity of *Ocimum americanum* L. leaves against paracetamol – induced liver damage in rats. **Am J Life Sci** 2013; 1: 37–42.
 29. Sangi S, El-feky SA, Ali SS, Ahmedani EI, Tashtoush MH. Hepatoprotective effects of oleuropein, thymoquinone and fruit of *phoenix dactylifera* on CCl₄ induced hepatotoxicity in rats. **World J Pharm Pharmaceut Sci** 2014; 3: 3475–3486.
 30. Aloah GS, Obeagu EI, Odo CE, Kanu SN, Okpara KE, Udezuluigbo CN, Ugwu GU. Hepatoprotective potentials of methanol extracts of *Gossweilerodendron balsamifarium* and lipid profile of albino rats. **Eur J Pharm Med Res** 2015; 2: 124–129.
 31. El-Sayed MGA, Elkomy A, Samer S, ElBanna AH. Hepatoprotective effect of *pimpinella anisum* and *foeniculum vulgare* against carbon tetrachloride induced fibrosis in rats. **World J Pharm Pharmaceut Sci** 2015; 4: 78–88.
 32. Sur TK, Hazra A, Hazra AK, Bhattacharyya D. Antioxidant and hepatoprotective properties of Indian Sunderban mangrove *Bruguiera gymnorrhiza* L. leave. **J Basic Clin Pharm** 2016; 7: 75–79.
 33. Koa EY, Kim D, Roh SW, Yoonec WJ, Jeon YJ, Ahn G, Kim KN. Evaluation on antioxidant properties of sixteen plant species from Jeju Island in Korea. **EXCLI J** 2015; 14: 133–145.
 34. Kuan-Hung L, Yan-Yin Y, Chi-Ming Y, Meng-Yuan H, Hsiao-Feng L, Kuang-Chuan L, Hwei-Shen L, Pi-Yu C. Antioxidant activity of herbaceous plant extracts protect against hydrogen peroxide-induced DNA damage in human lymphocytes. **BMC Res Notes** 2013; 6: 490. <https://doi.org/10.1186/1756-0500-6-490>.
 35. Al-Mamary MA. Antioxidant activity of commonly consumed vegetables in Yemen. **Mal J Nutr** 2002; 8: 179–189.
 36. Ladokun O, Ojezele M, Arojojoye O. Comparative study on the effects of aqueous extracts of *Viscum album* (mistletoe) from three host plants on hematological parameters in albino rats. **Afr Health Sci** 2015; 15: 606–612.
 37. Aoki Y, Hirai K, Tanikawa K. Mechanism of thrombocytopenia in liver cirrhosis: kinetics of indium-111 tropolone labelled platelets. **Eur J Nucl Med** 1993; 20: 123–129.
 38. Murata S, Matsuo R, Ikeda O, Ikeda O, Myronovych A, Watanabe M, Hisakura K, Nakano Y, Hashimoto I, Ohkohchi N. Platelets promote liver regeneration under conditions of Kupffer cell depletion after hepatectomy in mice. **World J Surg** 2008; 32: 1088.
 39. Idown AT, Obboh BO, Garuba PNF. Hematological properties of aqueous extracts of *Phyllanthus amarus* (schum and Thonn.) and *Xylopiya aethiopia* (dunal) A. Rich in Albino rats. **Ethno Med** 2009; 3: 99–103.
 40. Onome MI, Omaruyi E, Oyewo EB. Effect of aqueous leaf extract of *Acalypha wilkesiana* on hematological parameters in male wistar Albino rats. **Br J Pharmaceut Res** 2013; 3: 465–471.
 41. Colark E, Ustuner MC, Tekin N, Colark E, Burukoglu D, Degirmenci I, Gunes HV. The hepatocurative effects of *Cynara*

- scolymus* L. leaf extract on carbon tetrachloride-induced oxidative stress and hepatic injury in rats. **SpringerPlus** 2016; 5: 1–9.
42. Chellappan DK, Ganasen S, Btunalai S, Canasamy M, Krishnappa P, Dua K, Chellian J, Gupta G. The protective action of the aqueous extract of *Auricularia polytricha* in paracetamol-induced hepatotoxicity in rats. **Recent Pat Drug Deliv Formulation** 2016; 10: 72–76.
 43. Xu L, Gao J, Wang Y, Yu W, Zhao X, Yang X, Zhong Z, Qian Z. *Myrica rubra* extracts protect the liver from CCl₄-induced damage. **Evid Base Compl Altern Med** 2011, 518302. <https://doi.org/10.1093/ecam/nep196>.
 44. Adeneye AA. Protective activity of stem bark aqueous extract of *Musanga cecropioides* in carbon tetrachloride –and acetaminophen–induced acute hepatotoxicity in rats. **Afr J Tradit, Compl Altern Med** 2009; 2: 131–138.
 45. Nithianantham K, Shyamala M, Chen Y, Latha LY, Jothy SL, Sasidharan S. “Hepatoprotective potential of *Clitoria ternatea* leaf extract against paracetamol induced damage in mice.” **Molecules** 2011; 16: 10134–10145.
 46. Abeer H, Hibah MA, Jihan MB, Amany KI, Seham EA. “Evaluation of hepatoprotective activity of *Adansonia digitata* extract on acetaminophen-induced hepatotoxicity in rats.” **Evid Base Compl Altern Med** 2016; 2016, 4579149. <https://doi.org/10.1155/2016/4579149>. 7 pages.
 47. Khan RA, Khan MR, Sahreen S. Carbon tetrachloride-induced hepatotoxicity: protective effect of rutin on p53, CYP2E1 and the antioxidative status in rat. **BMC Complement Altern Med** 2012; 12: 178.
 48. Shweita SA, Abd El-Gabar M, Bastawy M. Carbon tetrachloride-induced changes in the activity of phase II drug-metabolizing enzyme in the liver of male rats: role of antioxidants. **Toxicology** 2001; 165(2–3): 217–224.
 49. Shweita SA, Abd El-Gabar M, Bastawy M. Carbon tetrachloride changes the activity of cytochrome P450 system in the liver of male rats: role of antioxidants. **Toxicology** 2001; 169(2): 83–92.
 50. Weber LWD, Boll M, Stampfl A. Hepatotoxicity and mechanism of action of haloalkanes: carbon tetrachloride as a toxicological model. **Crit Rev Toxicol** 2003; 33: 105–136.
 51. Srivastava SP, Chen N, Holtzman J. The in vitro NADPH-dependent inhibition by CCl₄ of the ATP-dependent calcium uptake of hepatic microsomes from male rats. Studies on the mechanism of the inactivation of the hepatic microsomal calcium pump by the CCl₃ radical. **J Biol Chem** 1990; 265: 8392–8399.
 52. Mir A, Anjum F, Riaz N, Iqbal H, Wahedi HM, Zaman J, Khattak K, Khan MA, Malik S. Carbon tetrachloride (CCl₄)-induced hepatotoxicity in rats: curative role of *Solanum nigrum*. **J Med Plants Res** 2010; 2010(4): 525–532. <https://doi.org/10.5897/JMPR10.482>.
 53. Wallace AD, Meyer SA. Hepatotoxicity. In: Smart RC, Hodgson E, editors. *Molecular and biochemical toxicology*. 4th ed. Hoboken: Wiley; 2010. pp. 671–692.
 54. Gutiérrez RMP, Solís RV. Hepatoprotective and inhibition of oxidative stress in liver of *Prostechea michuacana*. **Record Nat Prod** 2009; 3: 46–51.
 55. Jain R, Nandakumar K, Srivastava V, Vaidya SK, Patet S, Kumar P. Hepatoprotective activity of ethanolic and aqueous extract of *Terminalia bellerica* in rats. **Pharmacologyonline** 2008; 2: 411–427.
 56. Navarro VJ, Senior JR. Drug-related hepatotoxicity. **N Engl J Med** 2006; 354: 731–739.
 57. Tadeusz J, Teresa J, Krzysztof N. The role of polyphenol in modulation of physical properties of model membranes. **Curr Top Biophys** 2001; 25: 33–38.
 58. Gaw A, Cowan RA, O’Reilly D St J, Stewart MJ, Shepherd J. *Clinical biochemistry an illustrated colour text*. 2nd ed. Edinburgh: Harcourt Brace; 1999. p. 165.
 59. Hsiao G, Lin YH, Lin CH, Chou DS, Lin WC, Sheu JR. The protective effects of PMC against chronic carbon tetrachloride-induced hepatotoxicity *in vivo*. **Biol Pharm Bull** 2001; 24: 1271–1276.
 60. Mehmetçik G, Özdemirler G, Kocak-Toke RN, Çevikbas U, Uysal M. Effect of pretreatment with artichoke extract on carbon tetrachloride-induced liver injury and oxidative stress. **Exp Toxicol Pathol** 2008; 60: 475–480.
 61. Cuciureanu M, Căruntu I-D, Păduraru O, Stoica B, Jerca L, Crauciuc E, Nechifor M. The protective effect of montelukast sodium on carbon tetrachloride induced hepatopathy in rat. **Prostag Other Lipid Mediat** 2009; 88: 82–88.
 62. Battochio AP, Coelho KL, Sartoli MS, Coelho CA. Hepatoprotective effect of water soluble extract of *Coleus barbatus* on cholestasis on young rats. **Acta Cir Bras** 2008; 23: 220–229.
 63. Ajiboye TO. In vivo antioxidant potentials of *Piliostigma thonningii*(Schum) leaves: studies on hepatic marker enzyme, antioxidant system, drug detoxifying enzyme and lipid peroxidation. **Hum Exp Toxicol** 2010; 30: 55–62. <https://doi.org/10.1177/0960327110366785>.
 64. Adebayo AH, Abolaji AO, Kela R, Oluremi SO, Owolabi OO, Ogungbe OA. Hepatoprotective activity of *Chrysophyllum albidum* against carbon tetrachloride induced hepatic damage in rats. **Can J Pure Appl Sci** 2011; 2: 1597–1602.
 65. Spolarics Z, Meyenhofer M. Augmented resistance to oxidative stress in fatty rat livers induced by a short-term sucrose-rich diet. **Biochim Biophys Acta** 2000; 1487: 190–200.
 66. Piemonte F, PasStose A, Tozzi G, Taqliacozzi D, Santorelli FM, Carrozzo R, Cassali C, Damiano M, Fderici G, Bertini E. Glutathione in blood of patients with Freidereich’s ataxia. **Eur J Clin Invest** 2001; 31: 1007–1011.
 67. Al-Asmari AK, Al-Elaiwi AM, Athar MT, Tariq M, Al-Eid A, Al-Asmary SM. Review of hepatoprotective plants used in saudi traditional medicine. **Evid Base Compl Altern Med** 2014; 1: 22.
 68. El-Hadary AE, Ramadan MF. Potential protective effect of cold-pressed *coriandrum sativum* oil against carbon tetrachloride-induced hepatotoxicity in rats. **J Food Biochem** 2015; 40: 190–200.
 69. Awogbindin IO, Tade OG, Metibemu SD, Olorunsogo OO, Farombi EO. Assessment of flavonoid content, free radical scavenging and hepatoprotective activities of *Ocimum gratissimum* and *Spondias mombin* in rats treated with dimethylnitrosamine. **Arch Bas App Med** 2014; 2: 45–54.
 70. Valencia E, Marin A, Hardy G. Glutathione nutritional and pharmacological viewpoints: Part II. **Nutrition** 2001; 17: 485–486.
 71. Ayaz M, Junaid M, Subhan F, Ullah F, Sadiq A, Ahmad S, Imran M, Kamal Z, Hussain S, Shal SM. Heavy metals analysis, phytochemical, phytotoxic and anthelmintic investigations of crude methanolic extract, subsequent fractions and crude saponins from Polygonum hydropiper L. **BMC Complement Altern Med** 2014; 14: 465.
 72. Kamal Z, Ullah F, Ayaz M, Sadiq A, Ahmad S, Zeb A, Hussain A, Imran M. Anticholinesterase and antioxidant investigations of crude extracts, subsequent fractions, saponins and flavonoids of *Atriplex laciniata* L.: potential effectiveness in Alzheimer’s and other neurological disorders. **Biol Res** 2015; 48: 21.

How to cite this article: Nwidu LL, Oboma YI, Elmorsy E, Carter WG. Hepatoprotective effect of hydromethanolic leaf extract of *Musanga cecropioides* (Urticaceae) on carbon tetrachloride-induced liver injury and oxidative stress. **J Taibah Univ Med Sc** 2018;13(4):344–354.