


## VIEWPOINT

## Point-of-care lung ultrasound in the diagnosis and monitoring of paediatric patients with spontaneous pneumothorax in SARS-CoV-2 infection

Anna M Musolino,<sup>1</sup> Elena Boccuzzi ,<sup>1</sup> Maria C Supino,<sup>1</sup> Barbara Scialanga,<sup>1</sup> Francesco De Sanctis,<sup>2</sup> Danilo Buonsenso,<sup>3,4</sup> Serena Sinibaldi<sup>5</sup> and Paolo Tomà<sup>6</sup>

<sup>1</sup>Pediatric Emergency Unit, Department of Emergency and General Pediatrics, <sup>2</sup>Department of Imaging, Bambino Gesù Children's Hospital, IRCCS, <sup>3</sup>Department of Woman and Child Health and Public Health, A. Gemelli University Polyclinic Foundation, IRCCS, <sup>4</sup>Department of Basic Biotechnological Sciences, Intensivological and Perioperative Clinics, Catholic University of the Sacred Heart, Rome, <sup>5</sup>Anesthesiology and Pediatric Intensive Care, and <sup>6</sup>Pediatric Unit, Department of Emergency and General Pediatrics, Bambino Gesù Children's Hospital, IRCCS, Palidoro, Italy

Point-of-care lung ultrasound is a widely used tool in the diagnosis and management of patients with pulmonary diseases and now with SARS-CoV-2 infection. We describe two cases of pneumothorax which are, as far as we know, among the first reported in COVID-19 patients younger than 18 years. The diagnostic and monitoring role of point-of-care lung ultrasound has been extremely useful in the management of patients.

Point-of-care lung ultrasound (POC-LUS) is a widely used tool for its simplicity of application after adequate training, its high sensitivity and specificity in detecting many pathological findings and for the possibility of reducing exposure to ionising radiation.

The spread of the new SARS-CoV-2 infection has provided point-of-care ultrasound (POCUS) performers with new insights into the application of POC-LUS. Based on the acquired experience on LUS, echo assessment and follow-up have also been attempted in patients with SARS-CoV-2. The usefulness of POC-LUS has been defined for triaging of confirmed COVID patients to detect pneumonia and monitoring the evolution of lung involvement during the disease and so the effect of the therapies.<sup>1,2</sup>

Computed tomography (CT) remains the gold-standard imaging test in pneumothorax (PTX) assessment but it is limited by the need to transport critically ill patients and its high radiation exposure. Therefore, the first investigation performed for a long time was chest X-ray (CXR) because it was simple, fast, inexpensive and feasible also bedside, although its limited diagnostic sensitivity in supine position and small PTXs. Indeed, POC-LUS is described to be even more accurate than CXR.<sup>3,4</sup> These are the reasons why POC-LUS is gaining increasing interest and application in the diagnosis of PTX as a first bedside approach instead of CXR.

**Correspondence:** Dr Elena Boccuzzi, Pediatric Emergency Unit, Department of Emergency and General Pediatrics, Bambino Gesù Children's Hospital, IRCCS, Piazza di Sant'Onofrio 4, 00165 Rome, Italy. Fax: +39 0668 67954; email: elena.boccuzzi@opbg.net

Conflict of interest: None declared.

Accepted for publication 1 February 2021.

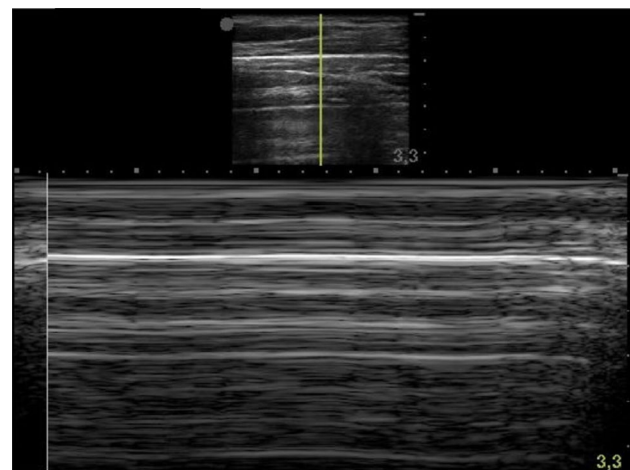
### Cases

#### Case 1

A 16-year-old boy was transferred to our emergency department due to breathing difficulties after performing a throat swab for SARS-CoV-2 polymerase chain reaction reported as positive. He complained of sudden no better localised chest pain during running, which subsequently subsided after the onset of subcutaneous emphysema.

Physical examination revealed a moderate respiratory distress and subcutaneous emphysema of the neck and upper chest.

POC-LUS was performed in supine position highlighting bilateral 'lung point' in B mode and 'barcode sign' in M-mode on anterior chest (Fig. 1) between the parasternal and anterior axillary line, thus defining the diagnosis of small extended bilateral



**Fig 1** 'Barcode sign' seen in M-mode on anterior chest.

PTX. CXR and chest CT confirmed apical bilateral PTX and showed pneumomediastinum without other pathological lung findings. He underwent conservative therapy for PTX. Regular POC-LUS evaluations were performed describing a significant quick reduction in PTX extension, until the patient was discharged.

## Case 2

A 17-year-old boy with a known but asymptomatic infection by SARS-CoV-2 for 10 days was brought to our emergency department via ambulance presenting with a 1-h history of sudden appearance of chest pain. On presentation, moderate respiratory distress was evident and breath sounds were reduced on the left.

He underwent POC-LUS in supine position that showed absence of lung sliding, absence of B lines and barcode sign in M mode on the left both on anterior and lateral chest, while the presence of lung point in B mode was only detected on the lateral surface of the thorax after the mid-axillary line, thus defining the diagnosis of large extended left-sided PTX, confirmed by CXR. Because of worsening of the respiratory distress and LUS and CXR findings (apical PTX up to 5 cm and contralateral displacement of the mediastinal image), the patient underwent pleural drainage with aspiration.

From the next day, he reported cough and asthenia. Chest CT was performed after 5 days due to poor clinical and LUS improvement: thin parenchymal bands with pleural junction, a limited parenchymal consolidation with bronchiolectasis and a minimal pleural effusion of few millimetres were evident in the lower left lobe. The patient was monitored by regular POCUS showing a progressive reduction of PTX until the drainage was removed after 10 days and the patient was discharged a week later.

## Methods and Limitations

POC-LUS was performed with an ultrasound pocket device (Sonosite iViz; FUJIFILM Sonosite, Amsterdam, Netherlands) and a linear probe covered with transparent plastic disposable material and ultrasound transmission gel in single use package.

Only two paediatric emergency medicine physicians with more than 5 years of LUS experience performed the valuations on the patients, to limit both the variability of the reports and the infectious risk of the medical staff. They were equipped with adequate personal protective equipment as indicated by the World Health Organization.

## Discussion

Basing primarily on case reports and case series, pneumothorax and/or pneumomediastinum are reported to be rare complications of SARS-CoV-2 pneumonia in adult population. One of the largest case series gives an incidence of PTX of less than 1%.<sup>5</sup>

As far as we know, most of the largest clinical and radiological studies about COVID-19 in children do not report cases of PTXs and/or pneumomediastinum<sup>6</sup> and only two cases have already been documented.<sup>7</sup> Although children of all ages are sensitive to COVID-19, manifestation of SARS-CoV-2 infection in younger population is generally milder than adults.<sup>8</sup> That is probably the

reason why the radiological findings are also less evident.<sup>7</sup> Indeed, CXR and CT findings in children's COVID-19 are not specific, thus the imaging should be indicated not to screen patients but to assess lower infection and the more complex cases, respectively.<sup>7</sup>

Our cases had no other symptoms prior the chest pain; the former revealed he had the infection only upon admission while the latter had a known SARS-CoV-2 positivity. Patient 1 was always symptoms-free while patient 2 began reporting cough and asthenia the next day after the drainage.

LUS, CXR and CT showed no lung parenchyma involvement other than bilateral PTX and pneumomediastinum in patient 1 who underwent conservative therapy; patient 2 developed tension PTX undergoing pleural drainage and later a basal parenchymal consolidation with bronchiectasis and pleural effusion were described, although without typical ground-glass opacities nor diffuse interstitial damage. Both had no history of recent trauma, no diagnosed lung disease nor previous PTX to evaluate pre-existing pathological lung findings.

We cannot exclude that spontaneous PTX was purely coincidental with SARS-CoV-2 infection in the first patient while in the second it can be assumed that the pulmonary findings were at the basis of the onset of PTX as described for adult, although the pulmonary involvement was not severe. However, we are unable to establish with certainty whether the pulmonary findings can be definitively associated with COVID infection.

In both reported cases, POC-LUS findings were consistent with radiological ones and the tool proved extremely useful for diagnostic setting and monitoring of PTX evolution during hospitalisation. It is also proving to be of great value in post-discharge follow-up.

## Conclusion

The role of POC-LUS in PNX is crucial as a valid diagnostic aid to support clinical evaluation since the diagnosis in patients with mild to moderate breathing difficulties up to the follow-up post-discharge, reducing the exposure to ionising radiation. Furthermore, it allows avoiding to move sick patients out of the isolation zone because it can be easily performed at the bedside with a pocket device by trained paediatric emergency medicine physicians equipped with the necessary personal protective equipment to limit the risk of contagion.

It is necessary to promote training on POCUS which is becoming increasingly attractive and useful in many fields.

At the best of our knowledge, our cases of spontaneous PTXs are among the first ones reported in literature in paediatric COVID patients while no other cases of pneumomediastinum are described.

The role of the SARS-CoV-2 infection on the onset of PTX has yet to be analysed and we hope to have soon more data on this to define the association.

## References

- 1 Soldati G, Smargiassi A, Inchingolo R *et al.* Is there a role for lung ultrasound during the COVID-19 pandemic? *J. Ultrasound Med.* 2020; **39**: 1459–62.

- 2 Musolino AM, Supino MC, Buonsenso D *et al.* Lung ultrasound in children with COVID-19: Preliminary findings. *Ultrasound Med. Biol.* 2020; **46**: 2094–8.
- 3 Volpicelli G. Sonographic diagnosis of pneumothorax. *Intensive Care Med.* 2011; **37**: 224–32.
- 4 Volpicelli G, Elbarbary M, Blaivas M *et al.* International evidence-based recommendations for point-of-care lung ultrasound. *Intensive Care Med.* 2012; **38**: 577–91.
- 5 Martinelli AW, Ingle T, Newman J *et al.* COVID-19 and pneumothorax: A multicentre retrospective case series. *Eur. Respir. J.* 2020; **56**: 2002697.
- 6 Kumar J, Meena J, Yadav A, Yadav J. Radiological findings of COVID-19 in children: A systematic review and meta-analysis. *J. Trop. Pediatr.* 2020: fmaa045. <https://doi.org/10.1093/tropej/fmaa045>
- 7 Caro-Dominguez P, Cheng Shelmerdine S, Toso S *et al.* Thoracic imaging of coronavirus disease 2019 (COVID-19) in children: A series of 91 cases. *Pediatr. Radiol.* 2020; **50**: 1354–68.
- 8 Viner RM, Mytton OT, Bonell C, *et al.* Susceptibility to SARS-CoV-2 infection among children and adolescents compared with adults: a systematic review and meta-analysis. *JAMA Pediatr.* 2021; **175**: 143–56.



Owl of the Night by William Wang (7) from Operation Art 2020