

Gastroenteritis and cardiogenic shock in a healthcare worker: a case report of COVID-19 myocarditis confirmed with serology

Sanjay Sivalokanathan ^{1,*†}, Michael Foley ^{2,†}, Graham Cole², and Taryn Youngstein ²

¹Cardiovascular Clinical Academic Group, St George's, University of London and St George's University Hospitals NHS Foundation Trust, Cranmer Terrace, Tooting, London SW17 0RE, UK; and ²Department of Cardiology, Hammersmith Hospital, Imperial College Healthcare NHS Trust, London, W12 0HS, UK

Received 9 July 2020; first decision 28 September 2020; accepted 28 December 2020

Background

Coronavirus disease 2019 (COVID-19) myocarditis is emerging as a component of the hyperactive inflammatory response secondary to severe acute respiratory syndrome coronavirus 2 (SARS-CoV-2). Isolated gastrointestinal symptoms are uncommon presenting features in adults with COVID-19 myocarditis. The availability of antibody testing is a valuable addition to the confirmation of COVID-19, when repeated reverse transcriptase–polymerase chain reaction of nasopharyngeal swabs are negative.

Case summary

A young healthcare worker presented with dizziness and pre-syncope, 4 weeks after his original symptoms that included fever, lethargy, and diarrhoea. Despite 2 weeks of isolation, followed by a quiescent spell, his symptoms had returned. Shortly after, he presented in cardiogenic shock (left ventricular ejection fraction 25%), that required vasopressor support, at the height of the COVID-19 pandemic. Cardiac magnetic resonance imaging suggested florid myocarditis. Three nasopharyngeal swabs (Days 1, 3, and 5) were negative for SARS-CoV-2, but subsequent serology (Day 13) confirmed the presence of SARS-CoV-2 IgG. Treatment with intravenous immunoglobulin and glucocorticoids led to full recovery.

Discussion

Our case study highlights the significance of the use of the available serological assays for diagnosis of patients presenting late with SARS-CoV-2. Importantly, it supports further research in the use of immunomodulatory drugs for the hyperinflammatory microenvironment induced by COVID-19.

Keywords

COVID-19 myocarditis • Heart failure • Septic cardiomyopathy • Multisystem inflammatory syndrome in children • Case report

Learning points

- To appreciate the utility of serological assays for severe acute respiratory syndrome coronavirus 2 (SARS-CoV-2) IgG in those for whom viral nasopharyngeal nucleic acid testing is negative.
- To highlight that the inflammatory effects of SARS-CoV-2 infection can occur late after initial viral symptoms have abated and may need immunosuppression.
- To be aware of the role of cardiac magnetic resonance in coronavirus disease 2019 myocarditis.

* Corresponding author. Tel: +44 208 725 2994, Email: sanjay.sivalokanathan@nhs.net

† These authors contributed equally and are co-first authors.

Handling Editor: Matteo Cameli

Peer-reviewers: Albert Galyavich and Luca Arcari

Compliance Editor: Debbie Falconer

Supplementary Material Editor: Anthony Paulo Sunjaya

© The Author(s) 2021. Published by Oxford University Press on behalf of the European Society of Cardiology.

This is an Open Access article distributed under the terms of the Creative Commons Attribution Non-Commercial License (<http://creativecommons.org/licenses/by-nc/4.0/>), which permits non-commercial re-use, distribution, and reproduction in any medium, provided the original work is properly cited. For commercial re-use, please contact journals.permissions@oup.com

Introduction

Coronavirus disease 2019 (COVID-19) is an infectious disease caused by severe acute respiratory syndrome coronavirus 2 (SARS-CoV-2). There are over 73 million confirmed cases across the globe, with evidence of a hyperactive immune response that frequently (7–20%) affects the myocardium and promotes cardiovascular injury.^{1–3} We report the case of a healthcare worker, with presenting features similar to that of paediatric inflammatory multisystem syndrome temporally associated with SARS-CoV-2 (PIM-TS), with the diagnosis only being confirmed through antibody testing.

diarrhoea, and new-onset of dizziness. On arrival to hospital, he was clinically shocked (blood pressure 75/50, heart rate 120 beats per minute), febrile (39°C), and tachypnoeic (>30 breaths per minute), with an oxygen saturation level of 97% on 3 L per minute of supplemental oxygen. Physical examination revealed a raised jugular venous pressure and coarse crepitations on auscultation. A bedside echocardiogram revealed global moderate-to-severe left ventricular (LV) systolic dysfunction [ejection fraction (EF) 35–40%].

He was transferred to critical care and was commenced on milrinone and noradrenaline. Within 24 h, given worsening of myocardial function (EF 25%) and strong suspicion of viral myocarditis, a single dose of 2 g/kg of intravenous immunoglobulin was administered, and

Timeline

28 days before admission	Initial symptoms: fever, diarrhoea, and lethargy. Symptoms subsided after 5 days.
5 days before admission	Recurrence of symptoms: fever and diarrhoea.
Admission (2 May 2020)	Re-presented to the emergency department with fever, diarrhoea, and new-onset dizziness. Given his occupation, there was increased suspicion of coronavirus disease 2019 (COVID-19). Transferred to critical care for haemodynamic support. Milrinone and noradrenaline were commenced. He did not require any other organ support. Echocardiogram revealed global left ventricular impairment (estimated at 35%), with biochemical evidence of myocardial injury [brain natriuretic peptide (BNP) > 35 000 ng/L; troponin 490 ng/L].
Days 1–4	Two nasopharyngeal swabs (Days 1 and 3) were negative for severe acute respiratory syndrome coronavirus 2 (SARS-CoV-2). Within 24 h of admission, there was worsening of myocardial function and was commenced on intravenous immunoglobulin (2 g/kg), and hydrocortisone (50 mg QDS). Chest computed tomography showed evidence of pneumonia, not characteristic of COVID-19 pneumonia, and therefore broad-spectrum antibiotics were started.
Day 5	Transferred to another institution, with another nasopharyngeal swab (Day 5) returning negative.
Day 7	Commenced on a weaning regime (weekly reduction) of Prednisolone (0.75 mg/kg/day).
Day 10	Inotropes were stopped. Cardiac magnetic resonance (CMR) showed improvement in myocardial function, whilst confirming myocarditis.
Day 12	Given haemodynamic stability, beta-blocker, angiotensin-converting enzyme (ACE) inhibitor, and a mineralocorticoid receptor antagonist (MRA) were commenced.
Day 13	Once available, SARS-CoV-2 IgG was positive.
Day 14	Discharged from hospital, with 40 mg of Prednisolone.
Day 19 (20 May 2020)	Troponin and BNP had normalized, with teleconsulting revealing absence of dizziness, and improved exercise tolerance.
Day 29	Repeat CMR demonstrated significant improvement in the extent of patchy late gadolinium enhancement, with normal biventricular size and systolic function.
Day 208 (24 November 2020)	He remains on a slowly weaning (reduced by 1 mg every 3 weeks), low dose (4 mg) of Prednisolone as well as a beta-blocker, ACE inhibitor, and MRA.

Case presentation

In early May 2020, a 37-year-old Caucasian healthcare worker, with no past medical history, presented to the emergency department with dizziness and pre-syncope. One month prior to admission, he described fever associated with lethargy and diarrhoea. His symptoms lasted 5 days with steady improvement. Swabs were not routinely available to healthcare professionals, and he began self-isolation on the suspicion that this illness was caused by COVID-19, particularly given his occupational exposure risk. He initially recovered but 2 weeks later he had a recurrence of symptoms with further fever,

hydrocortisone (50 mg QDS) started. He was anticoagulated with a heparin infusion, and high-dose Vitamin B & C (Pabrinex[®]) was initiated.

Laboratory investigations revealed leucocytosis ($36 \times 10^9/L$), lymphopenia ($0.6 \times 10^9/L$), elevated troponin (490 ng/l), brain natriuretic peptide (>35 000 ng/l), ferritin (8681 µg/L), and a D-dimer of 2782 ng/mL. He had an acute kidney injury (creatinine of 130 µmol/L), was coagulopathic (international normalized ratio of 1.5), and had a transaminitis (alanine transaminase of 538 U/L). His procalcitonin was 14.78 µg/L. Blood, urine, and stool cultures revealed no bacterial growth. He had a total of three nasopharyngeal swabs (Day 1, Day 3,

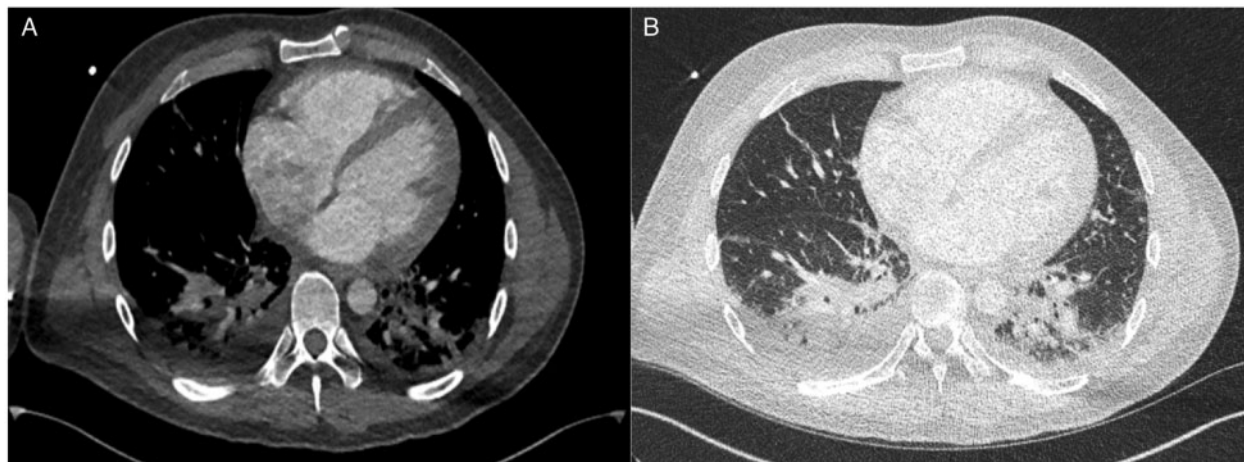


Figure 1 Computed tomography chest illustrating bilateral basal consolidation.

and Day 5 of admission) which were all negative for SARS-CoV-2. No other viral pathology, including influenza and HIV, was detected and the serum autoimmune panel was normal. The electrocardiogram revealed sinus tachycardia. Computed tomography of the chest revealed extensive bilateral lower lobe consolidation, with small pleural effusions, not typical of COVID-19 pneumonia (Figure 1). On account of his imaging and a clinical suspicion of a superimposed bacterial pneumonia, he was commenced on linezolid, clarithromycin, and piperacillin-tazobactam.

Serial echocardiograms demonstrated worsening biventricular function, with a reduction in global LV ejection fraction (LVEF) from 35% to 21% (Day 3 of admission) and worsening of right ventricular (RV) function and morphology (Video 1). The subsequent echocardiograms (Day 3) revealed LV wall thickening, bi-atrial dilatation, and increased pulmonary artery systolic pressures. There was an initial improvement in myocardial function (Day 5) with an LVEF of 29%. On Day 7, prednisolone (0.75 mg/kg/day) was substituted for hydrocortisone, which coincided with a rapid recovery in myocardial function. By Day 11, there was biochemical (troponin—108 ng/L) and radiological improvement in cardiac function. Cardiac magnetic resonance (CMR) imaging showed evidence of myocarditis with LV wall thickening, inhomogeneity of T1/T2 mapping values, and patchy non-infarct pattern late gadolinium enhancement (LGE) in the inferolateral and apical septal walls (Figure 2, Video 2). This also demonstrated a recovery of overall LV systolic function (LVEF 70%), with normalization of RV volumes and function.

Following full recovery of cardiac function and cessation of all organ support, the serum antibody test result became available, which confirmed the presence of SARS-CoV-2 IgG. He was started on an angiotensin-converting enzyme inhibitor, a beta-blocker, and a mineralocorticoid receptor antagonist. The patient remained asymptomatic on discharge and remains on a slowly weaning regimen of prednisolone. Whilst his repeat CMR demonstrated resolution of ventricular function, small areas of patchy

LGE persisted, illustrating the potential longer-term effects of COVID-19.⁴

Discussion

Presentations of COVID-19 infection are diverse, with a broad range of clinical severity. Extrapulmonary manifestations have been frequently described, and commonly involve cardiovascular complications.⁵ Myocardial injury, defined by an increase in troponin, is thought to affect 20–30% of patients and is strongly associated with mortality.⁵ Notably, COVID-19 related myocarditis, has been suggested to be the outcome of either direct cardiomyocyte viral infiltration or a response to the hosts 'cytokine storm'. This feature of the late, hyperinflammatory phase of the disease is associated with critical illness and is seemingly more prevalent in children and young adults.^{5,6}

The significant neutrophilia and procalcitonin raised the possibility of a bacterial cause with consequent septic cardiomyopathy. However, his occupational exposure, biphasic illness, significant lymphopenia and negative microbiological screen suggested viral myocarditis. CMR was particularly useful in the confirmation of the diagnosis. COVID-19 is associated with multiple mechanisms of myocardial injury which can be a challenge to delineate on clinical grounds. CMR was able to demonstrate the typical patchy LGE associated with myocarditis and also demonstrated that there was no myocardial infarction and no characteristic Takotsubo features.

There were several features that were consistent with PIM-TS, where acute heart failure is attributed to myocardial oedema or stunning.⁶ Notably, gastrointestinal symptoms are prominent presenting traits, with the majority being diagnosed serologically.³ Negative nasopharyngeal antigen testing with positive serum antibody is typical of PIM-TS and may reflect the aberrant development of acquired immunity to SARS-CoV-2.⁷ Importantly, multiple negative viral antigen

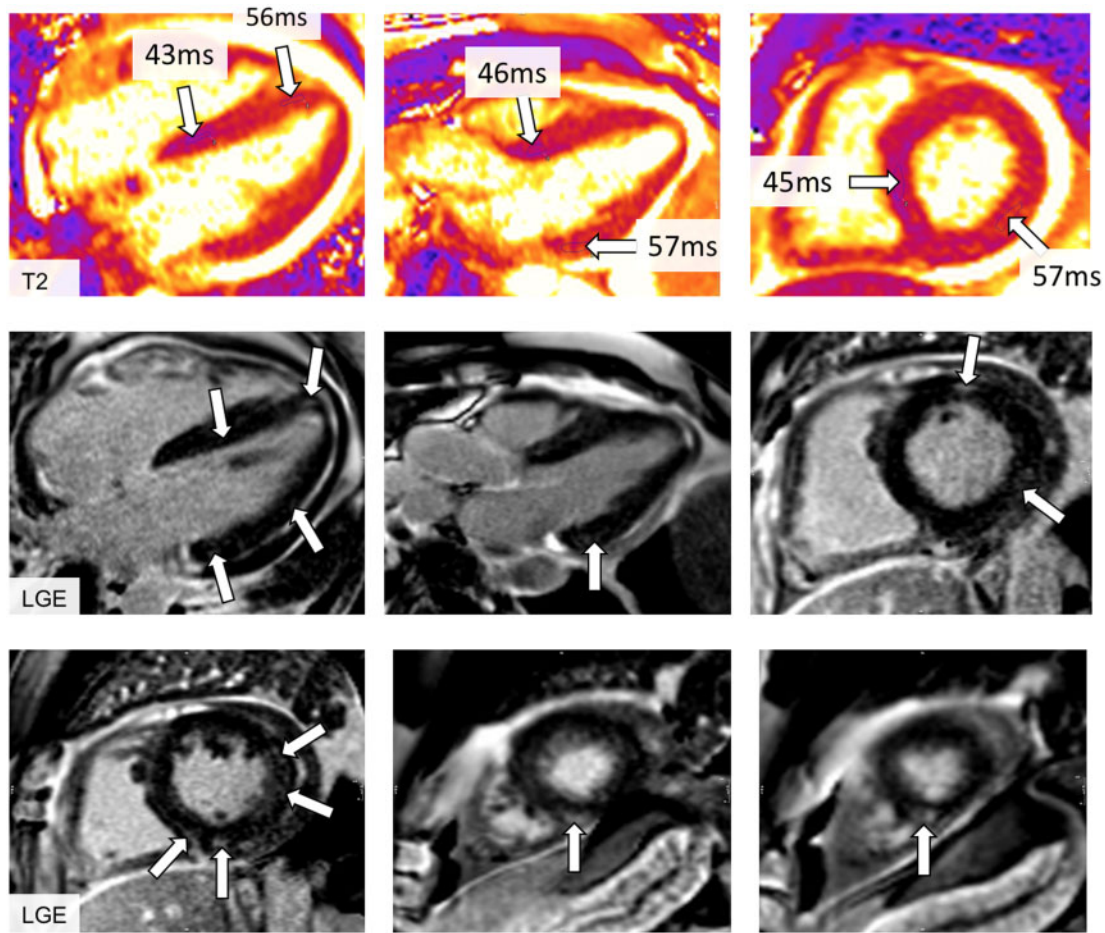
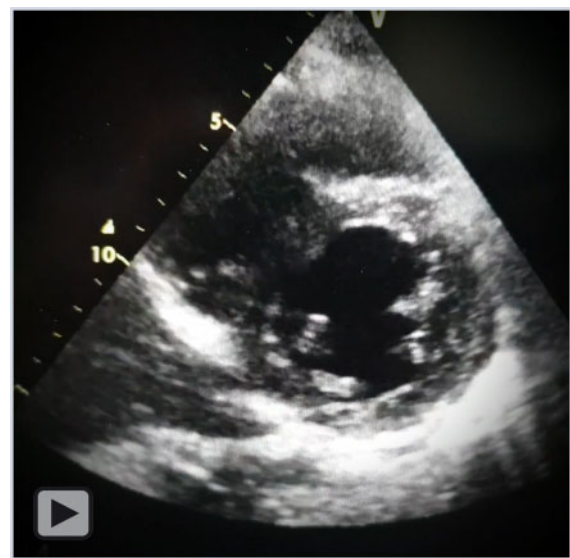

Figure 2 Matching T2 and late gadolinium enhancement images confirming myocarditis.

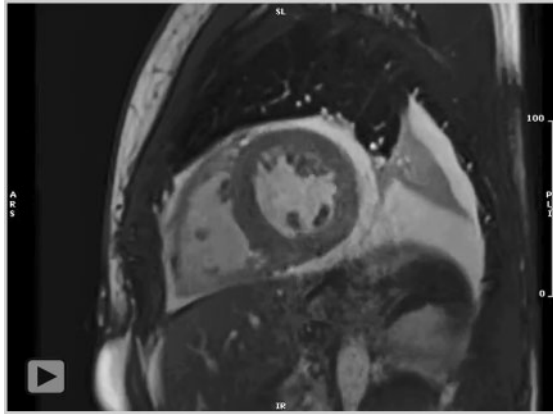
tests does not exclude the diagnosis.⁷ Current data suggest that reverse transcriptase–polymerase chain reaction positivity declines by Week 3 and becomes undetectable thereafter. Serological testing is therefore an important emerging tool in the diagnosis of those who present late. His occupation was a factor in ongoing clinical suspicion and testing.⁷

With the presence of a hyperinflammatory microenvironment, the use of immunomodulators may appear justified. However, preceding evidence has suggested otherwise. The use of corticosteroids, in patients with Middle East respiratory syndrome-CoV and SARS-CoV, has been associated with worse outcomes, including prolonged hospitalisation, higher need for ventilation, renal replacement therapy and need for intensive care. This may be due to inhibition of appropriate immune responses and delay in pathogen clearance.^{8,9}

In the absence of validated treatment strategies and with a case-fatality rate of 49% in critically unwell patients, the inflammatory mediators of COVID-19 have become plausible targets in achieving faster recovery or lowering risk of death.¹⁰ Most recently, the use of dexamethasone has shown to reduce mortality, by one fifth, in patients receiving oxygen alone.¹¹



Video 1 Echocardiogram demonstrating low biventricular systolic function.



Video 2 Cardiac magnetic resonance illustrating myocardial oedema.

Conclusions

COVID-19 myocarditis should be considered in those with a history of a viral prodrome, symptoms of cardiac dysfunction and elevated troponin. Occupation remains a significant potential risk factor. With a protracted but suspicious illness and a negative microbiology and autoantibody screen, SARS-CoV-2 antibody testing may support a diagnosis of late inflammatory COVID-19 in the presence of multiple negative antigen swab tests. CMR was crucial in the delineation of COVID myocarditis given the ability to exclude infarction and demonstrate myocardial oedema. In patients with a hyper-inflammatory response and myocarditis, immunosuppressive therapy should be considered.

Lead author biography



Sanjay Sivalokanathan is an NIHR academic clinical fellow in Cardiology at St. George's University of London under the guidance of both Professor Sanjay Sharma and Dr Aneil Malhotra. He is undergoing training in Internal Medicine and Cardiology in South London.

Supplementary material

Supplementary material is available at *European Heart Journal - Case Reports* online.

Acknowledgements

We are grateful to Drs. Aneil Malhotra, Amanda Varnava, Inithan Ganesaratnam, Simon Pearse, and Shawki EL-Ghazali for their respective contributions to this manuscript.

Slide sets: A fully edited slide set detailing this case and suitable for local presentation is available online as [Supplementary data](#).

Consent: The authors confirm that written consent for submission and publication of this case report including images and associated text has been obtained from the patient in line with COPE guidance.

Conflict of interest: None declared.

Funding: None declared.

References

- Dong E, Du H, Gardner L. An interactive web-based dashboard to track COVID-19 in real time. *Lancet Inf Dis* 2020;**20**:533–534.
- Nishiga M, Wang DW, Han Y, Lewis DB, Wu JC. COVID-19 and cardiovascular disease: from basic mechanisms to clinical perspectives. *Nat Rev Cardiol* 2020;**17**: 543–558.
- Siripanthong B, Nazarian S, Muser D, Deo R, Santangeli P, Khanji MY et al. Recognizing COVID-19-related myocarditis: the possible pathophysiology and proposed guideline for diagnosis and management. *Heart Rhythm* 2020;**17**: 1463–1471.
- Puntmann VO, Carerj ML, Wieters I, Fahim M, Arendt C, Hoffmann J et al. Outcomes of cardiovascular magnetic resonance imaging in patients recently recovered from coronavirus disease 2019 (COVID-19) [published online ahead of print, 2020 Jul 27]. *JAMA Cardiol* 2020;**5**:e203557.
- Zhou F, Yu T, Du R, Fan G, Liu Y, Liu Z et al. Clinical course and risk factors for mortality of adult inpatients with COVID-19 in Wuhan, China: a retrospective cohort study. *Lancet* 2020;**395**:1054–1062.
- Whittaker E, Bamford A, Kenny J, Kaforou M, Jones CE, Shah P et al.; for the PIMS-TS Study Group and EUCLIDS and PERFORM Consortia. Clinical characteristics of 58 children with a pediatric inflammatory multisystem syndrome temporally associated with SARS-CoV-2. *JAMA* 2020;**324**:259.
- Sethuraman N, Jeremiah SS, Ryo A. Interpreting diagnostic tests for SARS-CoV-2. *JAMA* 2020;**323**:2249–2251.
- Li H, Chen C, Hu F, Wang J, Zhao Q, Gale RP et al. Impact of corticosteroid therapy on outcomes of persons with SARS-CoV-2, SARS-CoV, or MERS-CoV infection: a systematic review and meta-analysis. *Leukemia* 2020;**34**:1503–1511.
- Russell CD, Millar JE, Baillie JK. Clinical evidence does not support corticosteroid treatment for 2019-nCoV lung injury. *Lancet* 2020;**395**:473–475.
- Scala S, Pacelli R. Fighting the host reaction to SARS-CoV-2 in critically ill patients: the possible contribution of off-label drugs. *Front Immunol* 2020;**11**: 1201.
- Ledford H. Coronavirus breakthrough: dexamethasone is first drug shown to save lives. *Nature* 2020;**582**:469–469.