

The efficacy and safety outcomes of the 0.19 mg fluocinolone acetonide implant after prior treatment with the 0.7 mg dexamethasone implant in patients with diabetic macular edema

P Singh¹
A Chedid¹
SK Deuchler¹
T Kohnen²
M Müller²
FH Koch¹

¹Retina and Vitreous Unit, University Eye Clinic, Frankfurt am Main, Germany; ²Ophthalmology University Eye Hospital, Frankfurt am Main, Germany

Purpose: There are little or no published data comparing the outcomes of ILUVIEN® (0.19 mg fluocinolone acetonide [FAc]) and OZURDEX® (0.7 mg dexamethasone [DEX]) implants in patients with diabetic macular edema (DME), and this case sought to compare their outcomes.

Methods: This case was extracted from a monocentric audit involving a pool of 25 patients (33 eyes) with DME and treated with a single FAc implant between October 2013 and December 2016. This case, a 61-year-old male with a pseudophakic lens, is from a patient that had received 4 intravitreal injections of a DEX implant prior to FAc implant and then was monitored for 3 years until re-treatment with a second FAc implant. Parameters measured included visual acuity (VA), central retinal thickness (CRT), and intraocular pressure (IOP).

Results: After the DEX implants, CRT transiently improved. In March 2014, the decision was taken to administer an FAc implant, and this led to a reduction in CRT below 300 µm (from a baseline of 748 µm), and this was sustained for 30 months. VA remained above 65 Early Treatment Diabetic Retinopathy Study letters to month 36, after which time a second FAc implant (in April 2017) was administered due to recurrence of edema and CRT decreased to below 300 µm and VA improved to 70 letters. Side effects included elevated IOP, which was effectively managed with IOP-lowering drops.

Conclusion: A single injection of FAc implant led to sustained improvements in CRT and VA that lasted for between 30 and 36 months, which is in contrast to the DEX implant where re-treatment was generally required within 6–7 months. After 36 months, re-treatment with the FAc implant again led to improved VA and CRT, and responses that were similar to those achieved with the first FAc implant.

Keywords: fluocinolone acetonide, diabetic macular edema, microdosing

Background

The diagnosis of diabetes continues to grow, from 388 million sufferers in 2013 to a projected 592 million in 2030, with an expected corresponding increase in the complications of diabetes.¹ Diabetic retinopathy is a common visual complication in the diabetic population, estimated to affect 30% of patients¹ and around 10% of the prevalent population have vision-threatening states such as diabetic macular edema (DME) or proliferative diabetic retinopathy.¹ This therefore represents a significant socioeconomic cost for health care systems across the globe and highlights the need for developing new treatment strategies. On the counter side of this argument, however, it also means that health care providers need to be selecting the optimal therapy for treating their patients as well as using any therapy cost-effectively.²

Correspondence: P Singh
Retina and Vitreous Unit, University Eye Clinic, Theodor-Stern-Kai 7, 60590 Frankfurt am Main, Germany
Email singhpankaj@me.com

In DME, the main treatment modalities include laser photocoagulation, intravitreal anti-VEGFs, and intravitreal corticosteroids or corticosteroid implants.³ In the last decade, the use of intravitreal anti-VEGFs or corticosteroids has revolutionized DME management with the emergence of randomized clinical trials showing these therapies led to a significant proportion of patients experiencing an improvement in both visual acuity (VA) and retinal anatomy.^{4,5}

The ILUVIEN (fluocinolone acetonide [FAc]) implant received its first European medicinal license approval in 2012 and is therefore a relatively recent development for the treatment of DME, where it is indicated for the treatment of vision impairment associated with chronic DME considered insufficiently responsive to available therapies (ie, for the treatment of persistent or recurrent DME despite treatment).⁶ The evidence for the efficacy and safety of FAc implant comes from the Fluocinolone Acetonide for Diabetic Macular Edema (FAME) trials in which the FAc implant, which provides a daily microdose of fluocinolone acetonide, was shown to provide a substantial visual benefit that lasted for up to 3 years.⁷

Since its approval in 2012, there have been a growing number of patients completing 3 years of therapy, and this has been observed at recent conferences such as Association for Research in Vision and Ophthalmology (ARVO) in Baltimore between the 7th and 11th May, 2017.⁸ The current case reports the outcomes after 3 years of treatment with the FAc implant. This is novel as it allows the comparison of outcomes achieved with longer-acting corticosteroid implants – the dexamethasone and FAc implants. In addition, this case

reports the outcomes achieved with the FAc implant after the patient had been re-treated with a second FAc implant 3 years after the first FAc implant had been administered. This case was presented at ARVO 2017,⁹ and the current article presents the patient outcomes.

Case presentation

A 61-year-old male with type 2 diabetes mellitus was diagnosed with DME on January 5, 2009 (Table 1). Comorbidities included hypertension and dyslipidemia. Between May 2009 and March 2010, the patient underwent 3 core vitrectomy surgeries, and was concurrently being treated with anti-VEGF (Avastin) and short-acting steroids (DEX implant and intravitreal injection of triamcinolone [IVTA]). On 2 separate occasions in March and April 2010, the patient was treated with laser focal therapy. Phacoemulsification was performed in August 2010 before a fourth core vitrectomy surgery was performed in December 2010. Ranibizumab was administered twice (March 2011 and April 2011) before the patient was treated with his first DEX implant in October 2011 (Table 2 and Figure 1).

Core vitrectomy or 2 ports pars plana vitrectomy is used at the University Eye Clinic of Frankfurt not only to remove vitreous opacities, but also to inject a combination of different drugs into the vitreous cavity without any volume restrictions and without risk of vision-threatening intraocular pressure (IOP) rise. Furthermore, the core vitrectomy itself serves other purposes as it allows a posterior vitreous detachment to be achieved under visual control, which is prognostically important for

Table 1 Left eye DME history prior to injection of the FAc implant

Date (DD/MM/YYYY)	DME treatment	CRT and VA values ^a
05/01/2009	DME diagnosed	
22/05/2009	Core vitrectomy + avastin + DEX implant + triamcinolone	
18/09/2009	Core vitrectomy + avastin + DEX implant + triamcinolone	
16/03/2010	Core vitrectomy + avastin + DEX implant + triamcinolone	
16/03/2010	Focal laser	
26/04/2010	Focal laser	
13/08/2010	Phacoemulsification, implantation of PC-IOL + avastin	
17/12/2010	Core vitrectomy + avastin + DEX implant + triamcinolone + cryocoagulation	
09/03/2011	Ranibizumab	
04/04/2011	Ranibizumab	
10/10/2011	DEX implant	622 μ m, 60 ETDRS letters
22/05/2012	DEX implant	676 μ m, 50 ETDRS letters
15/11/2012	DEX implant	592 μ m, 60 ETDRS letters
07/01/2013	Panretinal photocoagulation	
29/01/2013	Panretinal photocoagulation	
01/03/2013	Panretinal photocoagulation	
09/08/2013	DEX implant	760 μ m, 60 ETDRS letters
17/03/2014	FAc implant	748 μ m, 50 ETDRS letters

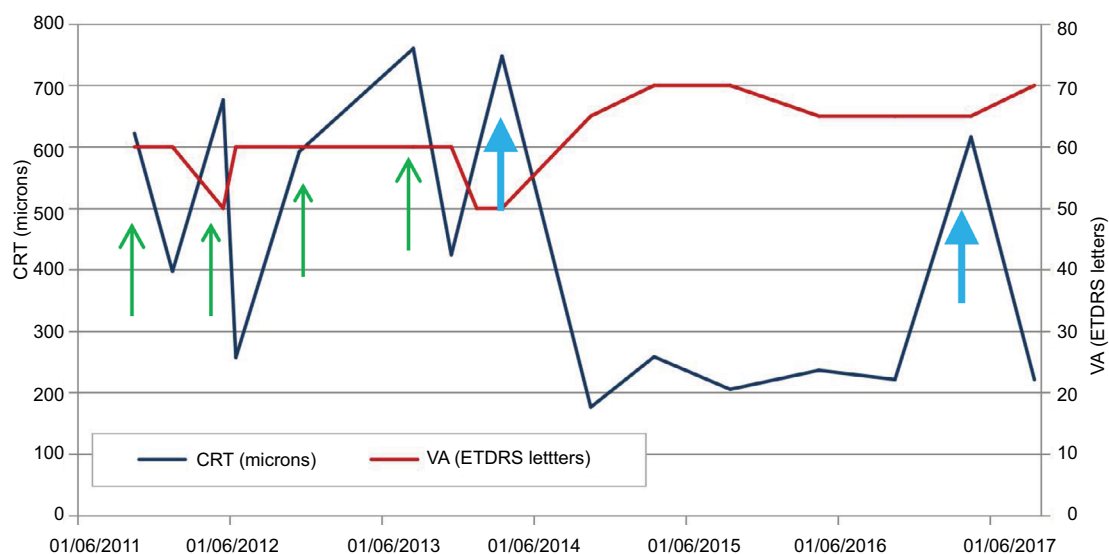
Notes: ^aPlease see Figure 1 where CRT and VA values for the DEX and FAc implants are plotted against time.

Abbreviations: CRT, central retinal thickness; DME, diabetic macular edema; DEX, dexamethasone; ETDRS, Early Treatment Diabetic Retinopathy Study; FAc, fluocinolone acetonide; IOL intraocular lens; VA, visual acuity.

Table 2 CRT, VA, and OCT images following the administration of steroid implants to the left eye

Date	CRT (microns)	VA (letters)	Steroid implant	OCT image
10/10/2011	622	60	DEX implant	
17/01/2012	397	60		
22/05/2012	676	50	DEX implant	
22/06/2012	257	60		
15/11/2012	592	60	DEX implant	
09/08/2013	760	60	DEX implant	
29/11/2013	424	60		
16/01/2014	588	50		
17/03/2014	748	50	FAC implant	
14/10/2014	176	65		
17/03/2015	258	70		
09/09/2015	205	70		
05/04/2016	236	65		
11/10/2016	221	65		
11/04/2017	616	65	FAC implant	
14/09/2017	221	70		

Abbreviations: CRT, central retinal thickness; DEX, dexamethasone; FAC, fluocinolone acetonide; OCT, optical coherence tomography; VA, visual acuity.

**Figure 1** VA and CRT over time following treatment with repeated injections of the DEX (n=4) and FAC implant (n=2).

Notes: Intravitreal injections of DEX and FAC implants are shown in green and blue, respectively. The patient was re-treated with a second FAC implant in April 2017.

Abbreviations: CRT, central retinal thickness; DEX, dexamethasone; ETDRS, Early Treatment Diabetic Retinopathy Study; FAC, fluocinolone acetonide; OCT, optical coherence tomography; VA, visual acuity.

diabetic patients. Repeated core vitrectomy allows for the serial washout of proinflammatory molecular mediators from the vitreous cavity with the objective of achieving optimal effects with intravitreal injected pharmacological agents.

On the date the first DEX implant was injected, VA was 60 letters converted from Snellen fraction to an ETDRS letter score¹⁰ and CRT was 622 microns (Table 1). A second and third implant were administered in May 2012 (50 letters and

676 microns) and November 2012 (60 letters and 592 microns) at which points VA remained relatively stable irrespective of treatment, and recurrence of edema was seen within 6–7 months of the DEX implant being injected (Table 2 and Figure 1). Between January 2013 and March 2013, panretinal photocoagulation was administered 3-times before a fourth DEX implant was injected in August 2013. CRT at this point was 760 microns and VA still remained unchanged (60 letters).

In March 2014, the first FAc implant was injected after CRT had again rebounded within 7 months of the fourth DEX implant being given (to 748 microns) and VA had started to worsen (50 letters). Figure 1 highlights the impact of FAc implant in this patient with CRT remaining below 300 microns until October 2016 (30 months) and VA being stable between 65 and 70 letters. After 3 years, edema had recurred (616 microns) and the patient was re-treated with a second FAc implant and the macula was dry in September 2017 and VA had improved further to 70 letters.

No additional therapies were given in combination with FAc implant. Side effects included the elevation of IOP, which was effectively managed with IOP-lowering drops, and remained below 21 mmHg.

Conclusion

DEX and FAc implants led to similar improvements in peak CRT and VA, with the main difference between therapies being the sustained duration of effect lasting up to 36 months with a single FAc implant. After 30 months, the first signs of recurrent edema were observed, but without change in VA, indicating that re-treatment with a second implant was required in this patient. After injection of a second FAc implant, CRT markedly improved along with a slight improvement in VA to 70 letters. This improvement has a direct benefit to the patient as this is the VA required to hold a driving license in Europe. It is also notable that the improvements in VA and CRT were achieved after extensive DME prior therapies, including repeated injections of the short-acting DEX implant. Indeed, the control achieved with the DEX implant was only maintained for up to 6 or 7 months (Figure 1) before CRT rebounded to values ≥ 600 microns. In stark contrast, FAc implant led to sustained drying of the macula and sustained/improved VA to levels not achieved with the previous treatments with the DEX implant. This observation needs to be confirmed in a larger group of vitrectomized patients and also in nonvitrectomized patients.

This case clearly shows that the patient had been heavily treated with therapies (laser, intravitreal injections, and

vitrectomy) prior to being treated with the FAc implant (Table 1). The patient history, therefore, clearly shows they were not treatment naïve and had persistent or recurrent DME despite receiving prior treatments. It also raises questions as to the effect of these prior treatments on the outcomes with the FAc implant and whether these outcomes could be further optimized by earlier treatment in the disease process, as has been suggested in recent publications.¹¹ In the current case, the patient received 4 injections of the DEX implant prior to FAc implant, and this was because the FAc implant was only launched in Europe in 2013 and was not commercially available. The current license means that FAc implant can be used once an insufficient response to a first-line therapy, predominantly the injection of anti-VEGF drugs,³ has been established. This means that the clinician can decide whether to switch directly from a first-line therapy to FAc implant or whether they want to confirm the patient is responding to a short-acting steroid before administering the long-acting steroid, FAc.

Ethics

This article does not contain any new studies with human or animal subjects performed by any of the authors. Written informed consent has been provided by the patient to have the case details published.

Acknowledgment

The publication of this article was supported by Alimera Sciences Ltd.

Disclosure

M Müller, A Chedid, and SK Deuchler have no conflicts of interest relating to this publication. FH Koch, P Singh, and T Kohnen, have attended advisory boards and speaker engagements and have been remunerated for these by Alimera Sciences. The authors report no other conflicts of interest in this work.

References

- Hernández C, Simó-Servat A, Bogdanov P, Simó R. Diabetic retinopathy: new therapeutic perspectives based on pathogenic mechanisms. *J Endocrinol Invest*. 2017;40(9):925–935.
- Quhill F, Beiderbeck A. Cost advantage of fluocinolone acetonide implant (LUVIEN®) versus ranibizumab in the treatment of chronic diabetic macular oedema. *Glob Reg Health Technol Assess*. 2017;4(1):e155–e164.
- Bailey C, Chakravarthy U, Lotery A, Menon G, Talks J; Medisoft Audit Group. Real-world experience with 0.2 µg/day fluocinolone acetonide intravitreal implant (LUVIEN) in the United Kingdom. *Eye*. 2017;31(12):1707–1715.
- Mathew C, Yunirakasiwi A, Sanjay S. Updates in the management of diabetic macular edema. *J Diabetes Res*. 2015;2015:794036.

5. Nguyen QD, Brown DM, Marcus DM, et al. Ranibizumab for diabetic macular edema: results from 2 phase III randomized trials: RISE and RIDE. *Ophthalmology*. 2012;119(4):789–801.
6. EMC. ILUVIEN 190 micrograms intravitreal implant in applicator – Summary of Product Characteristics (SPC). Available from: <https://www.medicines.org.uk/emc/medicine/27636>. Accessed September 21, 2017.
7. Campochiaro PA, Brown DM, Pearson A, et al. Sustained delivery fluocinolone acetonide vitreous inserts provide benefit for at least 3 years in patients with diabetic macular edema. *Ophthalmology*. 2012;119(10):2125–2132.
8. Augustin AJ, Atorf J. The first European report of real-life clinical outcomes after 3 years of treatment with ILUVIEN® (fluocinolone acetonide) in patients with chronic diabetic macular edema (DME). *Invest Ophthalmol Vis Sci*. 2017;58(8):928.
9. Singh P, Chedid A, Deuchler S, Kohnen T, Mueller M, Koch FHJ. The use of intravitreal implant ILUVIEN® (fluocinolone acetonide) after prior OZURDEX® implant (DEX) (dexamethasone) in patients with diabetic macular edema (DME)-efficacy and safety outcomes from the University Eye Clinic in Frankfurt, Germany. *Invest Ophthalmol Vis Sci*. 2017;58(8):2818.
10. Gregori NZ, Feuer W, Rosenfeld PJ. Novel method for analyzing snellen visual acuity measurements. *Retina*. 2010;30(7):1046–1050.
11. Habib MS. ILUVIEN® technology in the treatment of center-involving diabetic macular edema: a review of the literature. *Ther Deliv*. Epub 2018 Jun 26.

International Medical Case Reports Journal

Publish your work in this journal

The International Medical Case Reports Journal is an international, peer-reviewed open-access journal publishing original case reports from all medical specialties. Previously unpublished medical posters are also accepted relating to any area of clinical or preclinical science. Submissions should not normally exceed 2,000 words or

4 published pages including figures, diagrams and references. The manuscript management system is completely online and includes a very quick and fair peer-review system, which is all easy to use. Visit <http://www.dovepress.com/testimonials.php> to read real quotes from published authors.

Submit your manuscript here: <https://www.dovepress.com/international-medical-case-reports-journal-journal>

Dovepress