

[ CASE REPORT ]

## Aortic Regurgitation Presenting with Recurrent Detachment of a Prosthetic Valve, as the First Presenting Symptom of Cardiovascular Behçet's Disease

Tsugumi Takayama<sup>1</sup>, Takuya Ozawa<sup>1</sup>, Akiko Sanada<sup>1</sup>, Tohru Watanabe<sup>1</sup>, Masahiro Ito<sup>1</sup>, Satoru Hirono<sup>2</sup>, Yoshifusa Aizawa<sup>3</sup> and Tohru Minamino<sup>1</sup>

### Abstract:

A 33-year-old man with severe aortic regurgitation underwent initial aortic valve replacement (AVR). During the 2 years after AVR, 3 reoperations for prosthetic valve detachment were required. During hospitalization, he had no typical clinical findings, with the exception of a persistent inflammatory reaction; a pseudo-aneurysm around the Bentall graft developed 27 days after the 4th operation. This unique clinical course suggested the possibility of Behçet's disease. In the 8 years of follow-up after the administration of prednisolone, the pseudo-aneurysm did not become enlarged and the detachment of the prosthetic valve was not observed. We herein present a case of cardiovascular Behçet's disease, with a review of the literature.

**Key words:** aortic regurgitation, Behçet's disease, recurrent detachment of prosthetic valve

(Intern Med 57: 823-827, 2018)

(DOI: 10.2169/internalmedicine.9603-17)

### Introduction

Cardiac involvement is rare in patients with Behçet's disease; however, late valve detachment and pseudo-aneurysm of the aortic root after valve surgery have been reported, and the prognoses of these complications are very poor. However, in patients with aortic regurgitation (AR) presenting as the first symptom of Behçet's disease, it is often difficult to diagnose cardiovascular Behçet's disease before the first aortic valve replacement. We herein present a case of AR due to Behçet's disease presenting with no typical symptoms before aortic valve surgery. The patient required 4 surgical operations due to repeated anastomotic leakage.

### Case Report

In May 2006, a 33-year-old Japanese man developed chest oppression on exertion. He had no relevant medical history or family history of coronary artery disease or collagen disease. He was diagnosed with severe AR, with the en-

largement of the left ventricle (left ventricular systolic/diastolic dimension: 6.3/4.7 cm), and left ventricular dysfunction (left ventricular ejection fraction: 49%); however, neither aortic enlargement nor a bicuspid valve were observed on transthoracic echocardiography.

In November 2007, he underwent aortic valve replacement (SJM<sup>®</sup> 23 mm; St Jude Medical, St Paul, USA). On postoperative day 12, he developed fever, and was diagnosed with left lung pneumonia. Antibiotic therapy was effective, and he was discharged after the improvement of his symptoms. In March 2008, echocardiography identified paravalvular leakage of the prosthetic aortic valve (Fig. 1).

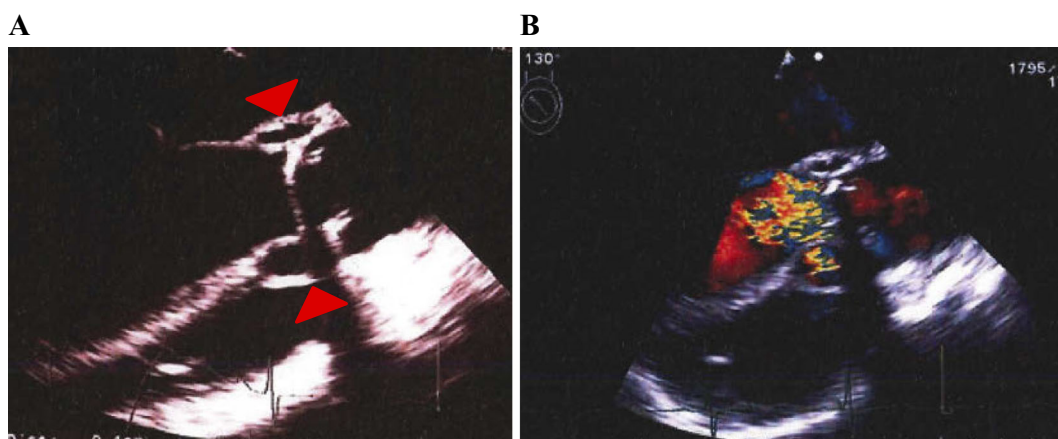
In April 2008, he underwent a second aortic valve replacement (SJM<sup>®</sup> 23 mm). The prosthetic valve was detached at the right coronary cusp and non-coronary cusp.

In July 2008, he developed congestive heart failure, and echocardiography identified the detachment of the prosthetic valve. He underwent Bentall-type aortic root replacement (ARR) with a bioprosthesis. During ARR surgery - when the prosthetic valve was sutured to the annulus - he developed complete atrioventricular block as a surgical complication,

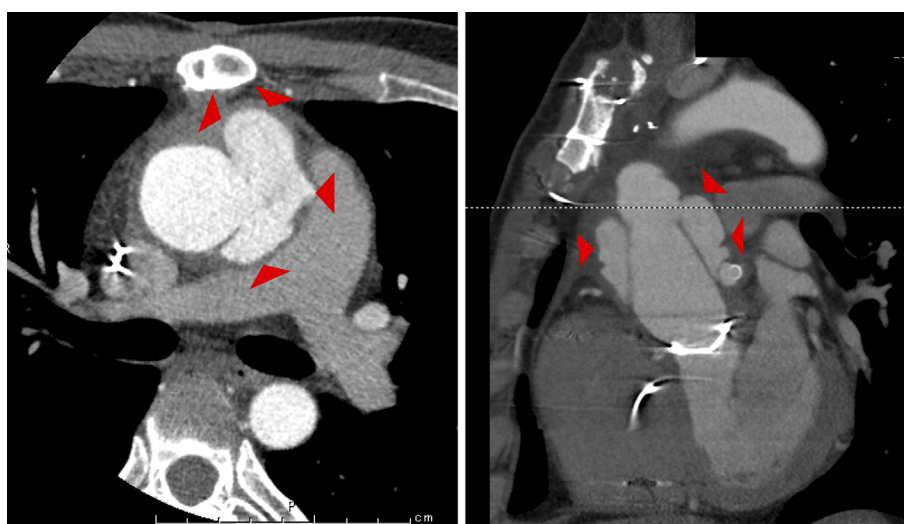
<sup>1</sup>Department of Cardiovascular Biology and Medicine, Niigata University Graduate School of Medical and Dental Sciences, Japan, <sup>2</sup>Division of Cardiology, Uonuma Kikan Hospital, Japan and <sup>3</sup>Division of Cardiology, Tachikawa Medical Center, Japan

Received: June 1, 2017; Accepted: July 17, 2017; Advance Publication by J-STAGE: December 8, 2017

Correspondence to Dr. Takuya Ozawa, takuya-o@med.niigata-u.ac.jp



**Figure 1.** Transesophageal echocardiography before the 2nd operation. A: The prosthetic valve was detached at the right coronary cusp and non-coronary cusp (red triangle) and was shifted to the left ventricle side. B: Severe aortic regurgitation was observed as jet from the space of the peri-prosthetic valve.

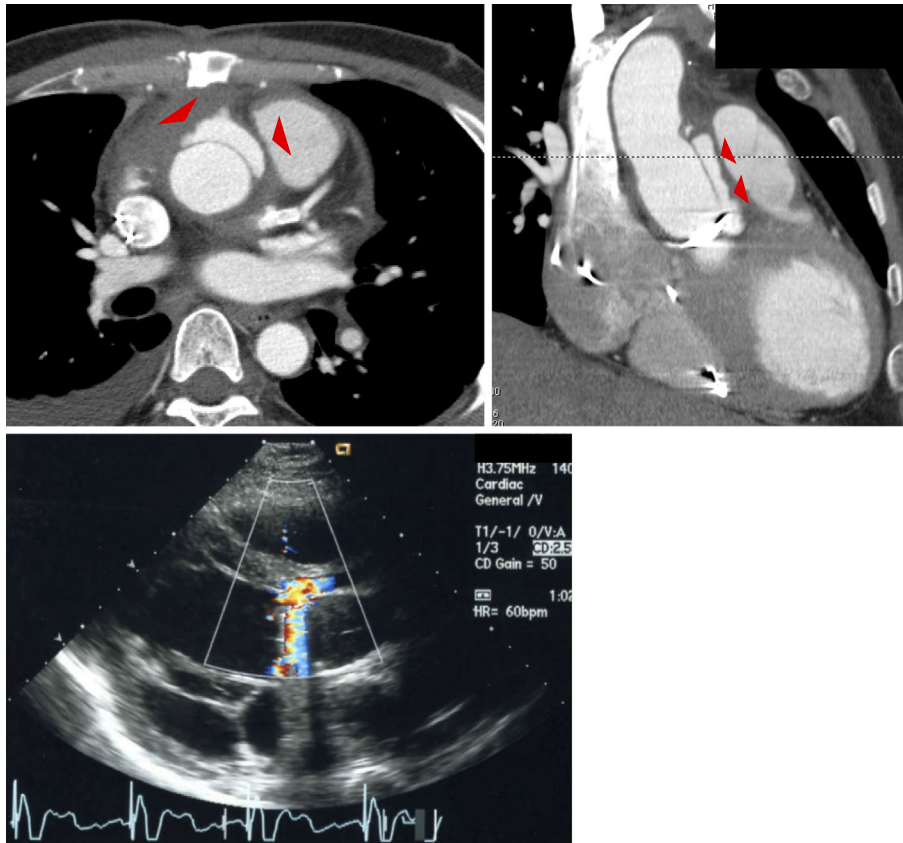


**Figure 2.** Contrast-enhanced computed tomography (CT) of the chest before the 4th operation. Contrast-enhanced CT revealed a pseudo-aneurysm around the Bentall graft (red triangle). CT: computed tomography

and underwent the implantation of a permanent pacemaker. In January 2009, he was admitted with chest pain due to acute coronary syndrome. Emergent coronary angiography revealed severe stenosis with delayed flow at the anastomotic site between the left main trunk and the Bentall graft. We performed percutaneous coronary intervention for anastomotic stenosis using a bare metal stent (Driver stent, 4.0×18 mm, Medtronic, Minneapolis, USA), which resulted in TIMI-III flow on angiography. In June 2009, he experienced sudden left upper limb paralysis, and was hospitalized with a diagnosis of suspected transient ischemic attack.

On admission, a physical examination revealed normal vital signs and normal neurological findings. Blood tests showed the following: white blood cell count, 8,760/ $\mu$ L (neutrophils, 70.7%); C-reactive protein (CRP), 4.9 mg/dL; serum amyloid A (SAA), 179.0  $\mu$ g/mL; erythrocyte sedimentation rate (ESR), 54 mm at 1 hour, and 20 mm at 30

minutes; and brain natriuretic peptide level, 156.4 pg/mL. Blood cultures (performed three times) were negative. Transthoracic echocardiography revealed diffuse left ventricular dysfunction and left ventricular dilatation with an ejection fraction of 33% and a left ventricular end-diastolic dimension of 64 mm. There was no aortic regurgitation and no vegetation around the prosthetic valve. Brain computed tomography (CT) revealed no abnormal findings, but chest contrast CT revealed pseudo-aneurysm around the Bentall graft (Fig. 2). During hospitalization, his fever and inflammatory reaction continued and we assumed the presence of anastomotic leakage due to graft infection. Antibiotic therapy was not effective, and he underwent a 4th operation for re-anastomosis of the ascending aorta and Bentall graft. The intraoperative findings showed no signs of graft infection. During the early postoperative period, contrast CT revealed no abnormalities. On postoperative day 27, echocardiogra-



**Figure 3.** Contrast-enhanced computed tomography (CT) of the chest and transthoracic echocardiography on postoperative day 27. Contrast-enhanced CT and echocardiography revealed a small amount of leakage at the anastomotic site between the left ventricle and the Bentall graft (red triangle). CT: computed tomography

phy and contrast CT revealed a small amount of leakage at the anastomotic site between the left ventricle and Bentall graft (Fig. 3).

During the 2 years after the 1st operation, 3 reoperations were required due to prosthetic valve detachment. This clinical course suggested the presence of inflammatory disease. Infectious endocarditis was excluded based on negative blood cultures and echocardiography. Connective tissue disease (*i.e.*, Marfan syndrome) was excluded based on a physical examination.

Next, we considered the possibility of collagen disease, because the levels of inflammatory markers (CRP, SAA, ESR) remained high after the 1st operation. However, the patient was negative for antinuclear antibodies. We then focused on the possibility of vasculitis, such as Takayasu arteritis or Behçet's disease. He did not show any macrovascular abnormality, genital ulcer, eye involvement, or skin involvement, and as pathergy test was negative. He did have a recurrent oral ulcer; furthermore, he was positive for human leukocyte antigen (HLA)-B52, and his level of IgD was high. We reconfirmed the pathological findings of the ascending aorta when he underwent the 4th operation in 2009. In the aortic wall, we observed the disappearance of elastic fibers at the media and a small amount of endothelium with fibrin deposition. In the mediastinal tissues around the as-

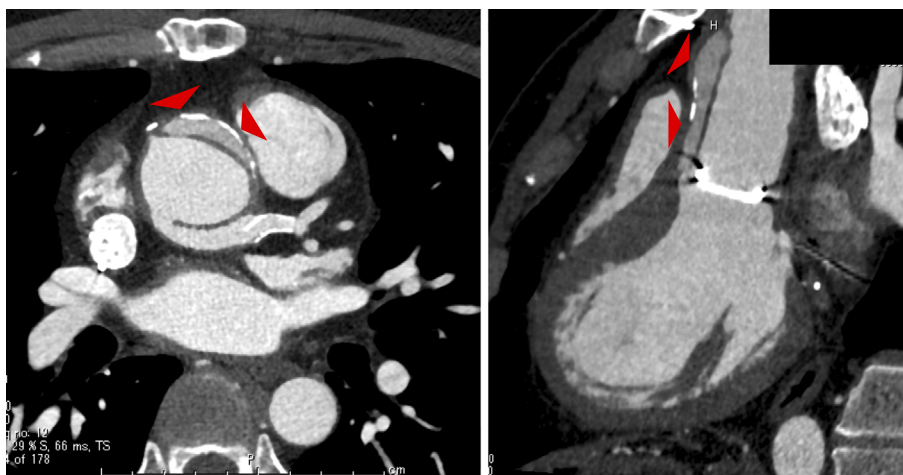
ending aorta, the proliferation of blood vessels and the infiltration of chronic inflammatory cells and macrophages that were phagocytosing hemosiderin were observed; however there were no specific findings to suggest any vasculitis syndromes.

Based on these clinical findings and the unique clinical course, we finally diagnosed the patient with Behçet's disease, and immunosuppressive therapy was initiated. The levels of inflammatory markers quickly decreased after the oral administration of prednisolone (40 mg/day). The dosage of prednisolone was gradually tapered to a maintenance dose of 10 mg. We planned the treatment strategy to avoid the enlargement of the pseudo-aneurysm or the recurrent detachment of the prosthetic valve, in order to avoid a 5th operation.

In the 8 years of follow-up (to date) the pseudo-aneurysm has not become enlarged and there the detachment of the prosthetic valve has not recurred (Fig. 4). The patient has continued to receive treatment with a maintenance dose of prednisolone, and his CRP and ESR levels have remained within the normal range without any cardiovascular events.

## Discussion

Behçet's disease is a chronic inflammatory disorder, the



**Figure 4.** Chest contrast computed tomography (CT) after 8-year follow-up period. Neither the enlargement of the pseudo-aneurysm nor the recurrent detachment of the prosthetic valve occurred during the 8-year follow-up period (red triangle). CT: computed tomography

predominant clinical findings of which include recurrent oral and genital ulceration, uveitis, and erythema nodosum (1). Behçet's disease is more common in the Middle East, the Mediterranean littoral region, and Asia, and is called, "silk road disease" (2). The etiology and pathogenicity of Behçet's disease are still unknown; the onset of the disease is suggested to be associated with HLA-B51. Some reports have shown cases of HLA-B52(+) Behçet's disease (3). Furthermore, various systemic manifestations can occur, including arthritis, gastrointestinal lesions, neurologic symptoms, and cardiovascular complications. Cardiovascular involvement is one of the most severe complications of Behçet's disease (4-7), and is more clinically relevant in Asia as a cause of AR than it is in the West. AR is less common in patients with Behçet's disease; however, the surgical outcome is still very poor (2, 7), because prosthetic valve detachment and pseudo-aneurysm are more frequent after the surgical repair of AR due to Behçet's disease (8, 9). Rather than classical aortic valve replacement, the Bentall procedure is recommended. Although some suture techniques are reported to avoid anastomotic failure (10-12), repeated surgical repairs are often required, and the indications for surgery should be decided carefully. It has been reported that immunosuppressive therapy may improve the surgical outcome, and should be started before surgery (13). In this case, steroid therapy was effective, and the 5th operation was avoided. However, a small pseudo-aneurysm around the Bentall graft was detected, and it was controversial as to whether 5th aortic root repair should be performed.

In conclusion, in patients with AR as the first symptom of Behçet's disease, it is often difficult to diagnose cardiovascular Behçet's disease before the 1st aortic valve replacement (14). We must be aware of the possibility of cardiovascular Behçet's disease in young patients with AR of unknown etiology before performing the 1st aortic valve replacement, and in cases of prosthetic valve detachment and pseudo-aneurysm after aortic valve replacement.

The authors state that they have no Conflict of Interest (COI).

## References

- Mendes D, Correia M, Barbedo M, et al. Behçet's disease - a contemporary review. *J Autoimmunity* **32**: 178-188, 2009.
- Yurdakul S, Yazici H. Behçet's syndrome. *Best Pract Res Clin Rheumatol* **22**: 793-809, 2008.
- Sugisaki K, Saito R, Takagi T, et al. HLA-B52-positive vasculo-Behçet disease: usefulness of magnetic resonance angiography, ultrasound study, and computed tomographic angiography for the early evaluation of multiarterial lesions. *Mod Rheumatol* **15**: 56-61, 2005.
- Lie JT. Vascular involvement in Behçet's disease: arterial and venous and vessels of all sizes. *J Rheumatol* **19**: 341-343, 1992.
- Mogulkoc N, Burgess MI, Bishop PW. Intracardiac thrombus in Behçet's disease: a systematic review. *Chest* **118**: 479-487, 2000.
- Kusuyama T, Nakamura Y, Yamagishi H, et al. Unruptured aneurysm of the sinus of Valsalva with Behçet's disease. *Circ J* **66**: 107-108, 2002.
- Koc Y, Gullu I, Akpek G, et al. Vascular involvement in Behçet's disease. *J Rheumatol* **19**: 402-410, 1992.
- Yuan SM. Cardiothoracic interventions in Behçet's disease. *Clin Exp Rheumatol* **32** (4 Suppl 84): S130-S139, 2014.
- Park SJ, Lee JW, Kim JB. Emergency Quadrifid-Bentall procedure for aortic rupture in a patient with Behçet's disease. *Korean J Thorac Cardiovasc Surg* **48**: 364-367, 2015.
- Azuma T, Yamazaki K, Saito S, Kurosawa H. Aortic valve replacement in Behçet's disease: surgical modification to prevent valve detachment. *Euro J Cardio-thoracic Surg* **36**: 771-772, 2009.
- Ando A, Kosakai Y, Okita Y, Nakano K, Kitamura S. Surgical treatment of Behçet's disease involving aortic regurgitation. *Ann Thorac Surg* **68**: 2136-2140, 1999.
- Chen LW, Wu XJ, Cao H, Dai XF. Valved conduit attached to left ventricular outflow tract for valve detachment in Behçet's disease. *Ann Thorac Surg* **103**: e301-e303, 2017.
- Jeong DS, Kim KH, Kim JS, Ahn H. Long-term experience of surgical treatment for aortic regurgitation attributable to Behçet's disease. *Ann Thorac Surg* **87**: 1775-1782, 2009.
- Han JK, Kim HK, Kim YJ, et al. Behçet's disease as a frequently unrecognized cause of aortic regurgitation: suggestive and misleading echocardiography findings. *J Am Soc Echocardiogr* **22**: 1269-1274, 2009.

The Internal Medicine is an Open Access article distributed under the Creative Commons Attribution-NonCommercial-NoDerivatives 4.0 International License. To view the details of this license, please visit (<https://creativecommons.org/licenses/by-nc-nd/4.0/>).

---

© 2018 The Japanese Society of Internal Medicine  
*Intern Med 57: 823-827, 2018*