

A Case of Adrenoleukodystrophy Presenting as Progressive Cerebellar Dysfunction

Seunguk Jung^a
Jong Won Chung^b
Ji Young Yun^b
Han-Joon Kim^b
Beom Seok Jeon^b

^aDepartment of Neurology,
Gyeongsang National University
School of Medicine, Jinju, Korea

^bDepartment of Neurology,
Seoul National University,
College of Medicine,
Seoul, Korea

X-linked adrenoleukodystrophy (X-ALD) is a hereditary neurological disorder affecting the nervous system and adrenal cortex. The phenotype of X-ALD ranges from the rapidly progressive cerebral form to milder adrenomyeloneuropathy. However, cerebellar manifestations are rare. We report a case of adrenoleukodystrophy presenting as progressive cerebellar dysfunction resembling olivopontocerebellar degeneration, with a review of the literature

Journal of Movement Disorders 2009;2:91-94

Key Words: X-linked adrenoleukodystrophy, Phenotype, Olivopontocerebellar degeneration.

Adrenoleukodystrophy (ALD) is an X-linked hereditary disorder caused by a genetic problem in Xq28 affecting the peroxisomal membrane. The resulting peroxisomal dysfunction causes very long-chain fatty acids (VLCFA) with more than 22 carbons to accumulate in various tissues, including the nervous system, adrenal cortex, and testis. Depending on the areas involved, this results in a variety of symptoms. The most common types of ALD are cerebral ALD and adrenomyeloneuropathy (AMN). Although adult-onset ALD takes the form of AMN in most cases, several studies have reported progressive cerebellar dysfunction such as olivopontocerebellar degeneration.¹ We report a case of ALD presenting as progressive cerebellar dysfunction, with a review of the literature.

Case Report

A 39-year-old man presented with dizziness and gait disturbance of 2-years duration. The onset and progression were gradual. Over the past year, dysarthria and liquid dysphagia developed and progressed. He had been a problem alcohol drinker for the past 7 years. Over the past 3 years, he had become impatient and was easily angered. One year earlier, he was admitted to a local psychiatric hospital because of abnormal behavior, such as stealing alcohol from a store. He was told that the results of brain magnetic resonance imaging (MRI) performed during that admission were abnormal, but this was not followed up. He continued to drink after discharge. In his family history, his elder brother had alopecia and a similar neurological condition, and died at the age of 46 years.

The physical examination revealed near-total alopecia. On neurological examination, he was alert and oriented. Gaze-evoked nystagmus was observed in both directions and was worse when looking to the right. He also had dysarthria and dysphagia. His motor strength was normal, as were the results of the sensory examination. The deep tendon reflexes were decreased slightly in both the lower and upper limbs. There was no Babinski's sign or ankle clonus. He had marked dysmetria in both upper limbs that was worse on the right. He was barely able to walk, with a broad-based gait.

A review of the previous brain MRI results showed mild brainstem and cerebellar atrophy, with a subtly increased signal intensity in the right middle cerebellar peduncle on fluid attenuated inversion-recovery (FLAIR) imaging. Cerebral cortical atrophy was also present. The MRI was repeated and showed worsening of the brainstem and cerebellar atrophy. The FLAIR images showed symmetric high-intensity signals in the posterior limbs of the

Received October 7, 2009
Revised October 22, 2009
Accepted November 16, 2009

Corresponding author

Beom Seok Jeon, MD
Department of Neurology,
Seoul National University,
College of Medicine,
101 Daehak-ro, Jongno-gu,
Seoul 110-744, Korea
Tel +82-2-2072-2876
Fax +82-2-2072-0839
E-mail brain@snu.ac.kr

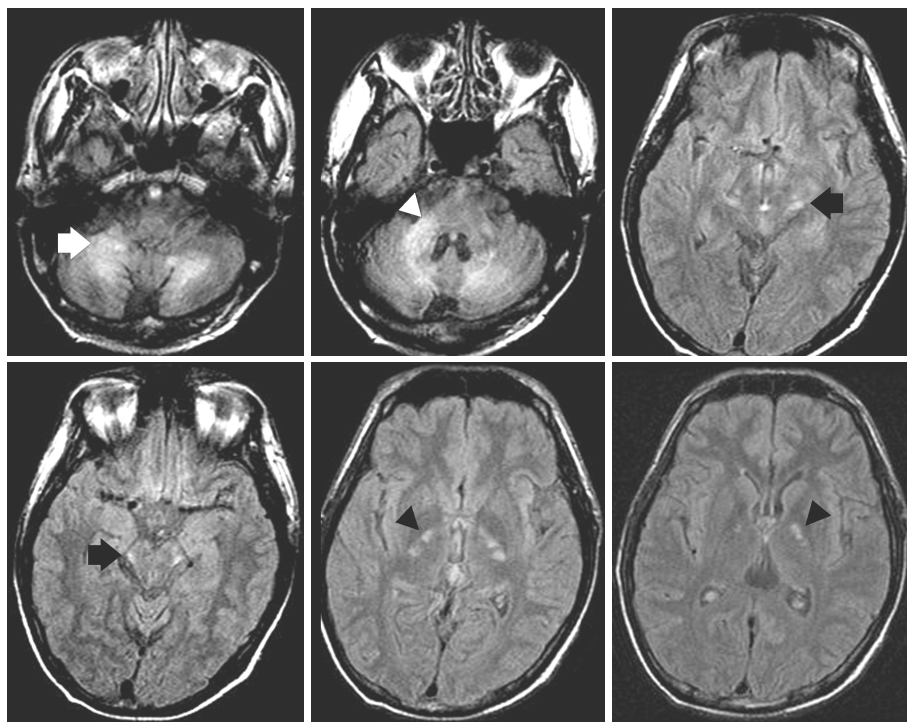


Figure 1. FLAIR brain MRI. Cerebellar and brainstem atrophy are seen. Bilateral symmetric high-intensity signals are observed in the posterior limbs of the internal capsules (black arrowhead), auditory pathway of the midbrain (black arrow), and dentate nuclei of the cerebellum (white arrow). Additional high-intensity signals are seen in the right middle cerebellar peduncle (white arrowhead). FLAIR: fluid attenuated inversion-recovery.

internal capsule, right middle cerebellar peduncle, and brachia of the inferior colliculus where it joins the medial geniculate body (Figure 1).

Complete blood counts, erythrocyte sedimentation rate (ESR), urinalysis, plasma electrolytes, and kidney, liver, and thyroid function tests were normal. Vitamin B₁₂ was somewhat low at 196 pg/mL (normal range, 200-1,000 pg/mL), and the folate level was low at 1.3 ng/mL (normal range, 3-15 ng/mL). An intramuscular vitamin B₁₂ injection and oral folate did not improve his condition. A Venereal Disease Research Lab oratory (VDRL) test for syphilis was negative. An electrocardiogram and a chest X-ray were normal. Gene tests for spinocerebellar ataxia types 1-3, 6, 7, and 17; dentatorubropallidolusian atrophy; fragile X syndrome; and Friedreich's ataxia were all negative. The plasma levels of pyruvate, lactic acid, homocysteine, and tumor markers were all normal. The adrenocorticotrophic hormone (ACTH) level at 8 a.m. was 90 pg/mL (normal range, 0-60 pg/mL) and the cortisol level was normal at 10.2 µg/dL (normal range, 5-25 µg/dL). An adrenocorticotrophic hormone (ACTH) stimulation test resulted in a defective rise in the cortisol level. A very long-chain fatty acid assay showed a C22 : 0 of 2.565 µM/L (normal, <1.310 µM/L), C24 : 0/C22 : 0 of 1.785 (normal, <1.390), and C26 : 0/C22 : 0 of 0.114 (normal, <0.023).

Discussion

ALD has various clinical symptoms depending on the areas involved. A published classification divides the condition into

child-onset cerebral, adolescent-onset cerebral, AMN, adult-onset cerebral, Addison's disease only, and non-symptomatic ALD, based on the onset time and organs involved.¹ The most common adult-onset ALD is AMN. However, rare cases presenting as progressive cerebellar dysfunction have been reported.²⁻¹⁰

One study analyzed the MRI scans of 164 adult-onset ALD patients who were classified into four subgroups based on their symptoms and patterns of brain involvement: AMN with normal brain, AMN with brain abnormalities limited to the long tract (ALMN I), AMN with diffuse lobar cerebral involvement (ALMN II), and adult-onset cerebral ALD.¹¹ Our patient had progressive cerebellar ataxia. On MRI, demyelination lesions were observed in the cerebellar white matter, including the dentate nuclei and right cerebellar peduncle, posterior limbs of both internal capsules, and auditory pathway. There is a report of a patient who had clinical symptoms similar to our case, and that patient was classified as ALMN I, or somewhere between ALMN I and II.⁹ In another case of adult-onset ALD showing slowly developing gait ataxia over 7 years, demyelination lesions were observed in the dentate nucleus, middle cerebellar peduncle, decussation of the superior cerebellar peduncles, and posterior limbs of both internal capsules on brain MRI; two years later, new white matter lesions were seen in the right frontal lobe, left occipital lobe, and both temporal lobes on brain MRI.² The brain MRI findings in other cases of ALD presenting as progressive cerebellar dysfunction are summarized in Table 1.

Our patient had a history of alcohol abuse, aggression, and

Table 1. Reported cases of adult-onset adrenoleukodystrophy with cerebellar ataxia

Study	Age/ gender	Onset age, y	Neurologic findings	Adrenal involvement	Neuroimaging
Kusaka and Imai ²	28/M	21	Dysarthria, gait disturbance and postural instability, ataxia	Elevated ACTH level	MRI: brainstem and cerebellar atrophy, hyperintense lesions in the central nucleus of the cerebellum bilaterally, posterior limbs of the IC
Miyai, et al. ³	29/M	26	Dysarthria, ataxic gait, impotent, urinary incontinence, euphoria	Elevated ACTH level, mild hyperpigmentation	MRI: brainstem and cerebellar atrophy, hyperintense lesions in both CR, IC, cerebral peduncles, white matter around the dentate nuclei of the cerebellum
Kobayashi, et al. ⁴	27/M	27	Progressive dysarthria, unsteadiness walking	Hyperpigmentation, but normal ACTH level	CT: atrophy of the pons and cerebellum
	27/M	22	Spastic-ataxic gait, scanning speech, limb and truncal ataxia	Normal ACTH level	CT: atrophy of the pons and cerebellum
Tan, et al. ⁵	24/M	22.5	Progressive slurred speech, unsteady gait, memory deterioration	Addison's disease, hyperpigmentation	MRI: cerebellar atrophy, hyperintense lesions in the dentate nuclei and adjacent white matter, MCP and pons
Mishra, et al. ⁶	29/M	20	Urinary incontinence, fecal incontinence, erectile dysfunction, ataxic gait, slurred speech	Addison's disease, hyperpigmentation	MRI: hyperintensities in the bilateral posterior parieto-occipital white matter, splenium, cerebellar white matter, IC, MCP, midbrain, and pons
Ohno, et al. ⁷	54/M	52	Gait disturbance, dysarthria, bladder disturbance	Addison's disease, hyperpigmentation	CT: atrophy of the pons and cerebellum
Vianello, et al. ⁸	29/M	21	Progressive ataxic gait, mental retardation, dysarthria, uninhibited behavior	Addison's disease	MRI: cerebellar, brainstem, and cervical cord atrophy
Waragai, et al. ⁹	30/M	29	Difficulty walking, postural instability, dysarthria	Mild adrenal insufficiency	MRI: atrophy of the cerebellum and brainstem, high-signal lesions in the bilateral dentate nuclei, corticospinal tracts
Suda, et al. ¹⁰	29/M	6MA	Progressive gait disturbance and dysarthria	Addison's disease, hyperpigmentation	MRI: hyperintense lesions in both dentate nuclei and red nuclei, pontine portion of the left corticospinal tract

ACTH: adrenocorticotrophic hormone, CT: computed tomography, IC: internal capsule, CR: corona radiata, MCP: middle cerebellar peduncle.

abnormal behavior before the onset of cerebellar ataxia. Preceding psychiatric symptoms have often been reported in adult-onset ALD. In a review of 109 cases of ALD, six cases presented after the age of 20 years, and four patients had psychiatric symptoms at the time of presentation.¹² Among 34 adult-onset ALD cases, 19 (56%) were reported to have psychiatric symptoms.¹³ In 13 of these cases, the psychiatric symptoms were assessed relatively thoroughly, and eight cases showed changes in behavior and character. These symptoms appeared between 2 months and 8 years before the onset of other neurological symptoms. Of the 13 patients, 12 were reported to have bipolar disorder, including disinhibition and emotional lability, with two of them reported to abuse alcohol or other substances.¹³

When brain MRI shows brainstem and cerebellar atrophy and demyelination lesions along the long tracts, the possibility of ALD should be considered. Accompanying adrenal

insufficiency may be an important clue, but 30% of adult-onset ALD cases have normal adrenal function.¹⁴ Hyperpigmentation of the skin, alopecia, and prior psychotic symptoms are further clues to the diagnosis of ALD.

REFERENCES

1. Moser HW. Adrenoleukodystrophy: phenotype, genetics, pathogenesis and therapy. *Brain* 1997;120:1485-1508.
2. Kusaka H, Imai T. Ataxic variant of adrenoleukodystrophy: MRI and CT findings. *J Neurol* 1992;239:307-310.
3. Miyai I, Fujimura H, Umekage T, Watase K, Ueno S, Yorifuji S, et al. Magnetic resonance imaging in adrenoleukodystrophy presenting as spinocerebellar degeneration. *J Neurol Neurosurg Psychiatry* 1990;53:623-624.
4. Kobayashi T, Noda S, Umezaki H, Goto I, Suzuki S, Kitaguchi T, et al. Familial spinocerebellar degeneration as an expression of adrenoleukodystrophy. *J Neurol Neurosurg Psychiatry* 1986;49:1438-1440.
5. Tan EK, Lim SH, Chan LL, Wong MC, Tan KP. X-linked adrenoleukodystrophy: spinocerebellar variant. *Clin Neurol Neurosurg* 1999;101:137-140.

6. Mishra S, Modi M, Das CP, Prabhakar S. Adrenoleukodystrophy manifesting as spinocerebellar degeneration. *Neurol India* 2006;54:195-196.
7. Ohno T, Tsuchida H, Fukuhara N, Yuasa T, Harayama H, Tsuji S, et al. Adrenoleukodystrophy: a clinical variant presenting as olivopontocerebellar atrophy. *J Neurol* 1984;231:167-169.
8. Vianello M, Manara R, Betterle C, Tavolato B, Mariniello B, Giometto B. X-linked adrenoleukodystrophy with olivopontocerebellar atrophy. *Eur J Neurol* 2005;12:912-914.
9. Waragai M, Takaya Y, Hayashi M, Shibata N, Kobayashi M. MRI of adrenoleukodystrophy involving predominantly the cerebellum and brain stem. *Neuroradiology* 1996;38:788-791.
10. Suda S, Komaba Y, Kumagai T, Yamazaki M, Katsumata T, Kamiya T, et al. Progression of the olivopontocerebellar form of adrenoleukodystrophy as shown by MRI. *Neurology* 2006;66:144-145.
11. Kumar AJ, Köhler W, Kruse B, Naidu S, Bergin A, Edwin D, et al. MR findings in adult-onset adrenoleukodystrophy. *AJNR AM J Neuroradiol* 1995;16:1227-1237.
12. Kitchin W, Cohen-Cole SA, Mickel SF. Adrenoleukodystrophy: frequency of presentation as a psychiatric disorder. *Biol Psychiatry* 1987;22:1375-1387.
13. Rosebush PI, Garside S, Levinson AJ, Mazurek MF. The neuropsychiatry of adult-onset adrenoleukodystrophy. *J Neuropsychiatry Clin Neurosci* 1999;11:315-327.
14. Aubourg P, Chaussain JL. Adrenoleukodystrophy presenting as Addison's disease in children and adults. *Trends Endocrinol Metab* 1991;2:49-52.