

[ ORIGINAL ARTICLE ]

## EUS-guided Biliary Drainage for Malignant Perihilar Biliary Strictures after Further Transpapillary Intervention Has Been Judged to Be Impossible or Ineffective

Yoshihide Kanno<sup>1</sup>, Kei Ito<sup>1</sup>, Shinsuke Koshita<sup>1</sup>, Takahisa Ogawa<sup>1</sup>, Kaori Masu<sup>1</sup>, Hiroaki Kusunose<sup>1</sup>, Toshitaka Sakai<sup>1</sup>, Yoshiharu Masaki<sup>1</sup>, Toji Murabayashi<sup>1</sup>, Sho Hasegawa<sup>1</sup>, Fumisato Kozakai<sup>1</sup>, Jun Horaguchi<sup>1,2</sup>, Hidenori Matsuo<sup>3</sup> and Yutaka Noda<sup>1</sup>

### Abstract:

**Objective** Patients with perihilar malignancy often develop recurrence of infectious cholangitis, which makes further transpapillary intervention extremely difficult. As endoscopic ultrasound (EUS)-guided biliary drainage (EUS-BD) of an intrahepatic bile duct is a possible option for additional intervention, the aim of this study was to estimate the feasibility of such intervention.

**Methods and Patients** Patients who had undergone EUS-BD after further transpapillary intervention was deemed impossible or ineffective were investigated in this study. Those who had not received previous interventions via the papilla were excluded. Procedure-related adverse events, clinical efficacy, and time to recurrence of jaundice or infectious cholangitis transthyretin (TTR) were evaluated.

**Results** Seven patients were eligible for the study between 2007 and 2016 (7 men; mean age, 77 years; 4 with perihilar cholangiocarcinoma and 3 with intrahepatic cholangiocarcinoma). No procedure-related adverse events were observed. EUS-BD was clinically effective and enabled hospital discharge in 4 patients (57%). The TTR in these 4 clinically effective patients was 43, 105, 118, and 147 days after the procedure (median, 112 days).

**Conclusion** EUS-BD was found to be safe and often effective in patients in whom additional transpapillary intervention had become difficult, although its efficacy was limited to a short period.

**Key words:** endosonography, Bismuth, hilar, reintervention, percutaneous, hepaticogastrostomy

(Intern Med 56: 3145-3151, 2017)

(DOI: 10.2169/internalmedicine.9001-17)

### Introduction

Transpapillary drainage has long been the standard approach for palliation of malignant biliary obstruction (1, 2). However, in the setting of the perihilar region, no detailed strategy has been established, despite the recent development of various devices (1, 3-7). In cases of perihilar malignancy, which separates the biliary system into multiple cavities, several difficult questions must be answered. Should biliary drainage be performed for one cavity or multiple cavi-

ties? (3, 6) Are plastic stents or metal stents more suitable? (1, 3) Should stents be deployed above the papilla? (8-11) Such clinical questions arise from the extreme technical complexity and difficulty in treating perihilar disease. As is typical of such complexity, the use of metal stents for perihilar lesions presents a great dilemma between a proven longer expected patency period and extreme difficulty in resolution after the stents become dysfunctional due to their non-removability in contrast to plastic stents. While endoscopists try to avoid to use of irremovable metal stents, there are a large number of patients in whom plastic stents

<sup>1</sup>Sendai City Medical Center, Japan, <sup>2</sup>Natori Chuo Clinic, Japan and <sup>3</sup>Kurokawa Hospital, Japan

Received: February 7, 2017; Accepted: April 10, 2017; Advance Publication by J-STAGE: October 11, 2017

Correspondence to Dr. Yoshihide Kanno, yoshi-hk@openhp.or.jp

are insufficient, and metal stents must be used to palliate biliary obstruction, some of which ultimately cannot undergo transpapillary intervention. Perihilar obstructions are difficult to treat because the available interventional techniques are imperfect at present and require further imperfect interventions.

Endoscopic ultrasound (EUS)-guided transmural stenting has recently become available, enabling biliary drainage via a route apart from the tumor. Because the technique of EUS-guided biliary drainage (EUS-BD) has not been completely established, it is not performed as the first option for palliation of perihilar obstructions. However, it could be an alternative to percutaneous drainage associated with frequent adverse events after transpapillary drainage has become ineffective or technically impossible.

In general, the targets of intrahepatic bile ducts are more limited with EUS-BD than percutaneous drainage. However, EUS-BD has an advantage over percutaneous drainage in that it can be clinically successful, since it can be used for internal drainage in contrast to the percutaneous approach, which requires external drainage via the skin. External tubes reduce the quality of life (QOL) in debilitated patients in the latest stages of malignancy.

We analyzed patients who had undergone EUS-BD to palliate infectious cholangitis after transpapillary drainage had become impossible or ineffective and report the results herein.

## Materials and Methods

### Patients

Among patients who had previously undergone transpapillary stent placement for a malignant perihilar stricture in the 10-year period from January 2007 to December 2016, all patients who had undergone EUS-BD after further transpapillary intervention had been judged impossible or ineffective were included in this study. EUS-BD patients who had not undergone previous transpapillary stent placement were excluded.

Because the aim of this study was to evaluate the efficacy of EUS-BD in patients in whom transpapillary drainage was no longer an option due to its ineffectiveness or technical difficulty, those who received EUS-BD without previous repetitive transpapillary drainage were excluded. Those who underwent EUS-BD as the first intervention because of inaccessibility of the papilla or the bile duct, those who underwent EUS-BD because endoscopic access might be difficult due to surgically altered anatomy, and those who preferred or requested to be treated with EUS-BD were excluded. Ultimately, only those patients who had undergone transpapillary treatment and eventually became impossible to treat transpapillary were analyzed.

Similar to other ordinary endoscopic interventions such as endoscopic hemostasis and transpapillary biliary drainage, patients with a low performance status are potential candi-

dates for EUS-BD. However, those in whom the performance of endoscopy seemed inappropriate were excluded (e.g. patients with unstable vital signs, who could not tolerate sedatives, and who could not sufficiently open their mouths).

### Outcome measurements and definitions

After identification of the patients' characteristics, such as age, sex, etiology of biliary obstruction, and Bismuth classification at the first transpapillary intervention, analyses of safety and efficacy of EUS-BD were performed. The analyses were conducted with respect to early adverse events, the clinical efficacy, and the length of the period without recurrence of jaundice or infectious cholangitis [time to recurrence (TTR)].

Early adverse events were defined as clinically important complications considered to be definitely or probably related to the EUS-BD procedure. Hemorrhaging was defined as the need for a blood transfusion or a decrease in the blood hemoglobin level of more than 2 g/dL that could not be explained by simple attenuation by infusion. Peritonitis was defined as newly emerged abdominal pain after the procedure that was considered to be related to leakage of bile or intestinal fluid.

The clinical effectiveness was defined as the successful recovery from jaundice and relief of infectious cholangitis. Successful recovery from jaundice was defined as a decrease in the serum total bilirubin level to the normal range ( $\leq 1.2$  mg/dL) or less than twice the upper normal limit. Relief of infectious cholangitis was defined as a decrease in the serum C-reactive protein (CRP) level to  $< 5.0$  mg/dL and maintenance of this condition without antibiotics and additional interventions for more than 7 days. Infectious cholangitis was defined as a condition with infectious inflammation accompanied by increasing levels of both CRP ( $\geq 5.0$  mg/dL) and biliary enzymes, such as alkaline phosphatase (ALP) and gamma-glutamyl transpeptidase (GTP).

TTR was defined as the period from the EUS-BD procedure to recurrence of stent function insufficiency (SFI) that could not be improved without additional intervention in clinically effective cases. SFI was defined as the recurrence of jaundice or the development of segmental cholangitis that required intervention to improve the condition. Temporary regression that improved without intervention was not defined as SFI, regardless of deterioration of any laboratory values. Regression that did not improve without intervention was defined as SFI, regardless of whether or not further intervention was performed. Recurrence of jaundice was defined as re-elevation of the serum total bilirubin level to more than twice the upper normal limit if the level had decreased to the normal range. If the total bilirubin level had not decreased to the normal range after the procedure, it was defined as elevation of more than 3.0 mg/dL compared to the lowest level in the patient or as clinically significant prolongation of severe jaundice. In this article, 'stent occlusion' and 'stent dysfunction' are used with the same meaning as

SFI, and ‘stent patency’ refers to the stents not developing such a condition.

### EUS-BD procedure

EUS-guided hepaticogastrostomy was performed as follows: With an echoendoscope (GF-UCT260; Olympus, Tokyo, Japan), intrahepatic bile ducts in the left lobe were visualized from the stomach. A 19-gauge needle for EUS-guided fine needle aspiration (Expect, slim line, flex type; Boston Scientific Japan, Tokyo, Japan) was inserted into a B3 duct with great caution to avoid puncturing vessels. When a safe puncture route into a B3 duct was not found, the B2 ducts were candidates for a puncture target. After verification of successful insertion of the needle by aspiration of bile and injection of contrast, a guidewire was advanced into the bile duct. The punctured tract was dilated with a bougie dilator (ES Dilator; Zeon Medical, Tokyo, Japan), and dilation with a balloon dilator (Hurricane, 4-mm in diameter; Boston Scientific Japan) was added when required. Finally, a metal stent (Niti-S, covered type with a 10-mm uncovered distal portion; Century Medical, Tokyo, Japan; ZeoStent, fully covered, Zeon Medical) was deployed at the punctured tract bridging the intrahepatic bile duct and the stomach.

### Ethics

Fully informed consent was obtained from all patients before the procedure. This study was approved by Sendai City Medical Center Institutional Review Board (Registration No. 20160047). The registration ID issued by UMIN was UMIN 000025539. All authors had access to the study data and reviewed and approved the final manuscript.

## Results

Among 112 patients who had undergone transpapillary stent placement for malignant perihilar strictures between January 2007 and December 2016, 7 received EUS-BD after transpapillary intervention was deemed impossible or ineffective. All EUS-BD procedures were performed by hepaticogastrostomy from the stomach to a left intrahepatic bile duct. During this period, 41 cases of EUS-guided hepaticogastrostomy, including these 7 patients, were encountered at our center. Two cases are shown in Figs. 1 and 2.

The detailed results of the 7 patients are shown in Table. The reason why transpapillary intervention was abandoned was lack of recovery due to SFI by transpapillary intervention in four patients, inaccessibility of the papilla by duodenoscopes due to gastrointestinal deformity in two patients, and inaccessibility of the intended hepatic duct via the papilla in one patient. No patients had surgically altered anatomy.

No adverse events, including hemorrhaging and symptomatic peritonitis, were observed in any patients.

The EUS-BD intervention was clinically effective in 4 patients (57%). All patients in whom clinical effectiveness had not been achieved with or without any further interventions,

such as percutaneous drainage, succumbed earlier (6, 14, and 29 days after intervention). In one patient (No. 1 in Table), additional drainage of a right hepatic duct via a percutaneous route was performed the day after EUS-BD but was not clinically effective.

The median time to recurrence after the procedure in the 4 clinically effective cases was 112 days (43-147 days). The QOL was found to be improved in these four patients due to the efficacy of EUS-BD; three patients were able to return home after long hospitalization (No. 4, 5, and 6 in Table), and one patient was able to spend a longer time away from hospital than prior to the EUS-BD procedure (No. 7 in Table). Three patients underwent additional intervention via hepaticogastrostomy for recurrence of biliary infection. The median survival period after EUS-BD in the clinically effective patients was 179 days (99-273 days).

## Discussion

Since Giovannini reported on EUS-guided drainage in 2001 (12), interventional EUS has rapidly developed with expansion of its range of application (13-15). EUS-guided anastomosis can be performed for most targets in which a safe puncturing tract has been confirmed by a linear echoendoscope. However, the efficacy of drainage in some complicated settings has remained an unresolved question. Perihilar malignancy, which expands into multiple branches, is one such difficult setting. Only a few cases of EUS-BD for perihilar malignancy have been reported in some published articles with highly heterogeneous settings (16, 17).

The standard technique for palliation of malignant perihilar biliary obstruction is endoscopic transpapillary stenting. Although the EUS-guided approach has not been established as the first option, it can be considered an option after transpapillary drainage is not found to be beneficial. When transpapillary intervention is abandoned, in most of cases, metal stents will have been transpapillary placed at the hilum, as these have a longer expected patency than plastic stents (1, 3). Although better outcomes of suprapapillary placement of plastic stents have been reported (8-11), once they become insufficient, they are replaced by irremovable metal stents. The subjects of this study were patients in such a situation.

After transpapillary intervention is no longer a treatment option, biliary decompression can be achieved with a percutaneous procedure or an EUS-guided procedure, but surgical approaches can never be performed in debilitated patients who have dysfunctional metal stents at the liver hilum. EUS-BD has the advantage of internal drainage, which can avoid QOL deterioration due to troublesome external drainage tubes via the skin or nose. In addition, the route created with the EUS-guided technique remains available as a route for reintervention after recurrence of biliary infection. Although percutaneous tubes can generally be replaced by internal stents, it is extremely difficult to insert any devices through the perihilar obstructions in patients such as those

**Table. Summary of Characteristics and Clinical Outcomes of the Patients.**

	Age	Sex	Etiology	Bismuth level	No. of previous transpapillary interventions	Previously deployed stents	Reason for performance of EUS-BD
1	89	F	Hilar CC	II	2	2 MSs	Duodenal stenosis
2	78	M	Hilar CC	IV	5	2 MSs+2 PSs	Inaccessibility to the left HD via the papilla
3	66	M	ICC	IV	3	3 MSs	Ineffective EBS
4	70	M	ICC	IV	4	5 MSs+2 PSs	Ineffective EBS
5	75	M	Hilar CC	IV	3	3 MSs	Ineffective EBS
6	78	F	ICC	IV	3	4 MSs	Duodenal stenosis
7	86	M	Hilar CC	IV	6	7 MSs+1 PS	Ineffective EBS

(Continued)

	Punctured duct	Deployed stent	Length of the stent	Adverse events	Clinical effectiveness	Time to recurrence (days)	Reintervention
1	B2	Niti-S	10 cm	None	Failed	N/A	Not performed
2	B3	Niti-S	10 cm	None	Failed	N/A	Not performed
3	B3	Niti-S	10 cm	None	Failed	N/A	Not performed
4	B3	Niti-S	10 cm	None	Succeeded	43	Additional PS at HGS
5	B3	Zeo	8 cm	None	Succeeded	105	Additional PS at HGS
6	B3	Niti-S	8 cm	None	Succeeded	118	PTBD
7	B3	Niti-S	10 cm	None	Succeeded	147	EBS, additional PS at HGS, additional HGS

(Continued)

	No. of reinter-ventions	Favorable change in the patients' lives after EUS-BD	Survival period after EUS-BD (days)
1	0	No evident change	6
2	0	No evident change	14
3	0	No evident change	29
4	2	Discharge	99
5	4	Discharge	273
6	1	Discharge	206
7	2	Discharge and longer stay at home	152

F: female, M: male, Hilar CC: perihilar cholangiocarcinoma, ICC: intrahepatic cholangiocarcinoma, MS: metal stent, PS: plastic stent, EUS-BD: EUS-guided biliary drainage, EBS: endoscopic transpapillary biliary stenting, HD: hepatic duct, Niti-S: partially covered Niti-S with a 10-mm uncovered distal portion, Zeo: fully covered ZeoStent, N/A: not applicable, HGS: hepaticogastrostomy, PTBD: percutaneous transhepatic biliary drainage

Discharge: The patients could not be discharged before EUS-BD, but could be discharged after improvement with EUS-BD.

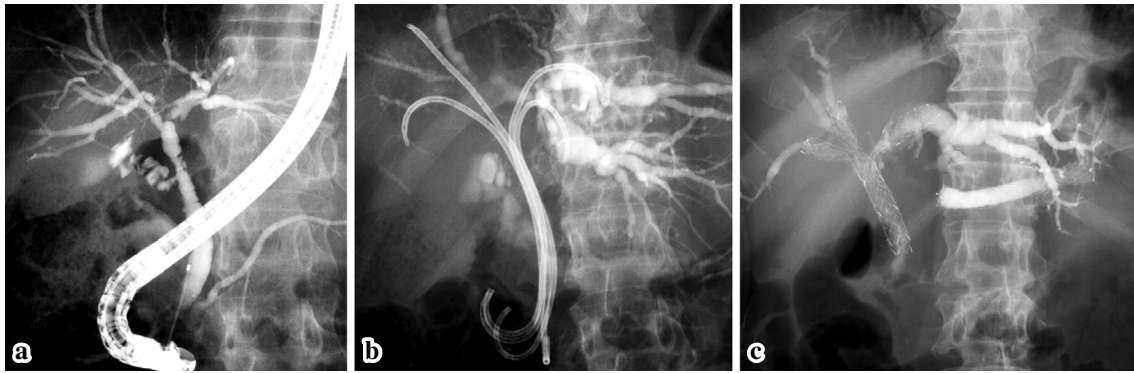
Discharge and longer stay at home: The patient could not stay home for a time longer than 2 weeks because of repetitive recurrence of infectious cholangitis before EUS-BD, but could stay home for 4 months after EUS-BD.

in this study, in whom multiple metal stents have already been deployed. If exchanging external tubes for internal ones is unsuccessful, they must be deployed permanently via the skin. Adding more percutaneous tubes when the previous ones prove ineffective would be required, further reducing the QOL by multiple external drainage tubes. In contrast, external drainage tubes can be easily maintained with water perfusion to prevent tube occlusion. They can also be reopened with water and guidewires or replaced by new tubes when occluded with procedures less invasive than endoscopy.

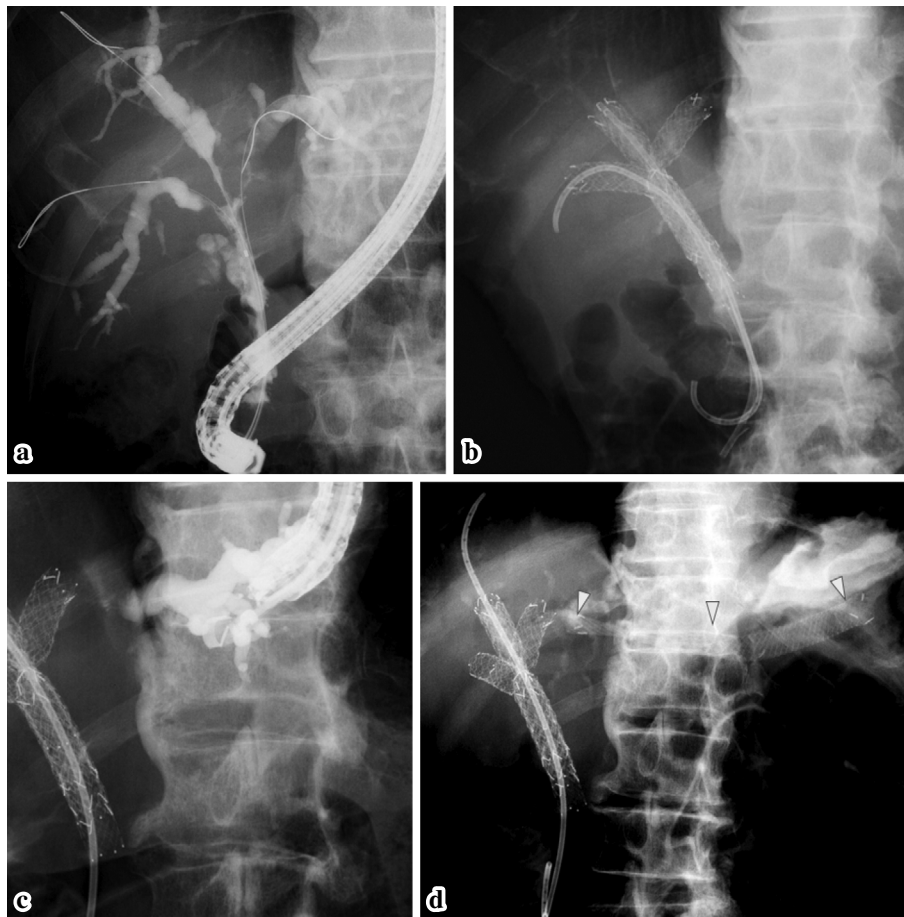
The present study showed that EUS-BD was effective in

some patients with perihilar malignancy that severely divided the biliary system (Bismuth level IV) after transpapillary intervention had become difficult. In addition, the procedures in this study were safely performed, although the population size was relatively small, indicating that EUS-BD is a viable alternative to percutaneous drainage, which is associated with a high rate of adverse events (18, 19).

The three patients who could not be effectively treated by EUS-BD in this study had severely limited prognoses (6, 14, and 29 days, respectively), whereas the prognoses of the effectively treated patients were longer (99, 152, 206, and 273 days). EUS-BD might be effective if the expected prognosis



**Figure 1.** Case of hilar cholangiocarcinoma (patient 5 in Table 1). Bismuth level IV cholangiocarcinoma broadly expanded into multiple hepatic ducts (a). Four plastic stents were deployed as the initial intervention (b). Although stent exchange was performed two times during a two-month hospitalization period because previously deployed plastic stents had not been fully effective, transpapillary drainage was judged to be insufficient for maintaining an infection-free status for a longer period. EUS-guided hepaticogastrostomy bridging a B3 duct and the stomach was performed (c), enabling discharge and functioning for 105 days.



**Figure 2.** Case of hilar cholangiocarcinoma (patient 7 in Table 1). Bismuth level IV cholangiocarcinoma broadly expanded into multiple hepatic ducts (a). Transpapillary drainage was repeated seven times in the first six months (b). From the 7th month to the 14th month after the initial intervention, he was hospitalized 11 times for treatment with medication alone, as his intrahepatic bile ducts were not dilated and EUS-guided drainage could not be performed. After confirmation of dilated hepatic ducts, EUS-guided hepaticogastrostomy bridging a B3 duct and the stomach was performed (c) (d), enabling discharge and a longer stay at home for three months (the maximum period of staying home in the previous eight months before the procedure had been just two weeks).

is better, as more time is needed for successful recovery from jaundice and relief of infectious cholangitis. Alternatively, the clinical failure may not have been due solely to the incapability of EUS-BD but also to a deficiency in the patients' stamina to combat the diseases due to severe emaciation related to malignancy and repetitive cholangitis. Park et al. reported three cases of malignant perihilar obstruction that underwent EUS-BD after transpapillary deployed metal stents had become dysfunctional (16). They observed neither adverse events nor stent dysfunction during the follow-up periods of 91, 152, and 183 days. Although the definite reason for the difference in the results between their study and ours is unknown, in their study, a duodenoscope could not reach the ampulla in two patients, and a guidewire could not pass through the mesh of the previously deployed stent in one patient, so the level of disease progression in the included patients at baseline might be different. However, a similar level of safety may justify performing this intervention for highly complicated patients. Furthermore, it can be said that EUS-BD is a reasonable option for patients with sufficient power to recover.

The target in all patients included in this study was a lateral hepatic duct, i.e. B2 or B3. Although drainage for the right lobe was not attempted, the outcome would have been more favorable if it had been attempted. Such a technique is challenging but possible in some patients, as shown by previous reports (20-22). However, the occurrence of a puncture of the right hepatic ducts seems to have been limited to relatively few cases so far.

As a possible rebuttal to the favorable outcome of this study, the cases included in the study might have been diagnosed with an infection in the left side, and those suffering from infection on the right side might have been excluded, resulting in selection bias. However, the focus of infection is frequently unidentified in actual clinical practice, so clinicians often take a chance on either hepatic duct. Therefore, the results of this study are not considered to be completely meaningless. Furthermore, even in cases with perihilar malignancy, communication between the right and left ducts is confirmed with contrast injection. In such cases, the important factor for successful drainage and infection control is not the choice of the right or left duct but the creation of a drainage route separate from the malignant stricture. Although the results of this study cannot justify habitual performance of EUS-BD, the feasibility of EUS-BD as an option is indicated.

Several limitations associated with the present study warrant mention, including its extremely small sample size and retrospective setting. Because an EUS-guided approach to intrahepatic bile ducts is not considered to have priority over transpapillary approaches at present, such an approach should be adopted only in exceptional settings, such as cases in which palliation with transpapillary interventions has become impossible or those in which percutaneous tubes carry an excessive risk of accidental withdrawal due to confusion or non-cooperation. A study with a larger sample size would

therefore be ethically questionable and could not be conducted. Once the efficacy and safety of the procedure have been confirmed in a small population, as in the present study, larger studies can be designed. Comparative studies with the percutaneous approach, which is said to be associated with a lower rate of clinical effectiveness and a higher rate of adverse events than transpapillary drainage (18), are desired.

In conclusion, EUS-guided hepaticogastrostomy was found to be safe and effective in some patients with infectious cholangitis that could no longer be controlled with transpapillary interventions. EUS-guided hepaticogastrostomy may therefore be a reasonable alternative to the percutaneous approach, which is related to frequent adverse events and requires external drainage via the skin, resulting in a decreased QOL in highly debilitated patients in the latest stage of malignancy. The accumulation of further such cases and the conduct of prospective studies, including randomized ones, are warranted.

**The authors state that they have no Conflict of Interest (COI).**

## References

1. Kanno Y, Ito K, Fujita N, et al. Single-session endoscopic bilateral Y-configured placement of metal stents for hilar malignant biliary obstruction. *Dig Endosc* **23**: 91-96, 2011.
2. Kato H, Tsutsumi K, Kawamoto H, Okada H. Current status of endoscopic biliary drainage for unresectable malignant hilar biliary strictures. *World J Gastrointest Endosc* **7**: 1032-1038, 2015.
3. Mukai T, Yasuda I, Nakashima M, et al. Metallic stents are more efficacious than plastic stents in unresectable malignant hilar biliary strictures: a randomized controlled trial. *J Hepatobiliary Pancreat Sci* **20**: 214-222, 2013.
4. Miura S, Kanno A, Masamune A, et al. Risk factors for recurrent biliary obstruction following placement of self-expandable metallic stents in patients with malignant perihilar biliary stricture. *Endoscopy* **48**: 536-545, 2016.
5. Kogure H, Isayama H, Kawakubo K, et al. Endoscopic bilateral metallic stenting for malignant hilar obstruction using newly designed stents. *J Hepatobiliary Pancreat Sci* **18**: 653-657, 2011.
6. Iwano H, Ryozaawa S, Ishigaki N, et al. Unilateral versus bilateral drainage using self-expandable metallic stent for unresectable hilar biliary obstruction. *Dig Endosc* **23**: 43-48, 2011.
7. Naitoh I, Hayashi K, Nakazawa T, et al. Side-by-side versus stent-in-stent deployment in bilateral endoscopic metal stenting for malignant hilar biliary obstruction. *Dig Dis Sci* **57**: 3279-3285, 2012.
8. Pedersen FM, Lassen AT, Schaffalitzky de Muckadell OB. Randomized trial of stent placed above and across the sphincter of Oddi in malignant bile duct obstruction. *Gastrointest Endosc* **48**: 574-579, 1998.
9. Ishiwatari H, Hayashi T, Ono M, Sato T, Kato J. Newly designed plastic stent for endoscopic placement above the sphincter of Oddi in patients with malignant hilar biliary obstruction. *Dig Endosc* **25** (Suppl 2): 94-99, 2013.
10. Kaneko T, Sugimori K, Shimizu Y, et al. Efficacy of plastic stent placement inside bile ducts for the treatment of unresectable malignant hilar obstruction (with videos). *J Hepatobiliary Pancreat Sci* **21**: 349-355, 2014.
11. Inatomi O, Bamba S, Shioya M, et al. Threaded biliary inside stents are a safe and effective therapeutic option in cases of malignant hilar obstruction. *BMC Gastroenterol* **13**: 31, 2013.

12. Giovannini M, Moutardier V, Pesenti C, Bories E, Lelong B, Delpero JR. Endoscopic ultrasound-guided bilioduodenal anastomosis: a new technique for biliary drainage. *Endoscopy* **33**: 898-900, 2001.
13. Horaguchi J, Fujita N, Noda Y, et al. Endosonography-guided biliary drainage in cases with difficult transpapillary endoscopic biliary drainage. *Dig Endosc* **21**: 239-244, 2009.
14. Kawakubo K, Isayama H, Kato H, et al. Multicenter retrospective study of endoscopic ultrasound-guided biliary drainage for malignant biliary obstruction in Japan. *J Hepatobiliary Pancreat Sci* **21**: 328-334, 2014.
15. Dhir V, Itoi T, Khashab MA, et al. Multicenter comparative evaluation of endoscopic placement of expandable metal stents for malignant distal common bile duct obstruction by ERCP or EUS-guided approach. *Gastrointest Endosc* **81**: 913-923, 2015.
16. Park DH, Jang JW, Lee SS, Seo DW, Lee SK, Kim MH. EUS-guided biliary drainage with transluminal stenting after failed ERCP: predictors of adverse events and long-term results. *Gastrointest Endosc* **74**: 1276-1284, 2011.
17. Bories E, Pesenti C, Caillol F, Lopes C, Giovannini M. Transgastric endoscopic ultrasonography-guided biliary drainage: results of a pilot study. *Endoscopy* **39**: 287-291, 2007.
18. Moole H, Dharmapuri S, Duvvuri A, et al. Endoscopic versus percutaneous biliary drainage in palliation of advanced malignant hilar obstruction: a meta-analysis and systematic review. *Canadian J Gastroenterol Hep* 2016 (Epub ahead of print).
19. Park DH. Endoscopic ultrasound-guided biliary drainage of hilar biliary obstruction. *H Hepatobiliary Pancreat Sci* **22**: 664-668, 2015.
20. Ogura T, Sano T, Onda S, et al. Endoscopic ultrasound-guided biliary drainage for right hepatic duct obstruction: novel technical tips. *Endoscopy* **47**: 72-75, 2015.
21. Park SJ, Choi JH, Park DH, et al. Expanding indication: EUS-guided hepaticoduodenostomy for isolated right intrahepatic duct obstruction (with video). *Gastrointest Endosc* **78**: 374-380, 2013.
22. Kozakai F, Kanno Y, Ito K, et al. Endoscopic-ultrasonography-guided biliary drainage for repetitive acute cholangitis of the accessory hepatic duct by clip ligation during laparoscopic cholecystectomy. *Nihon Shokakibyō Gakkai Zasshi* **114**: 683-690, 2017.

The Internal Medicine is an Open Access article distributed under the Creative Commons Attribution-NonCommercial-NoDerivatives 4.0 International License. To view the details of this license, please visit (<https://creativecommons.org/licenses/by-nc-nd/4.0/>).