

Trans-Tubular Translaminar Microscopic-Assisted Nucleotomy for Lumbar Disc Herniations in the Hidden Zone

Hamdan Abdelrahman, MD¹, Sadat Seyed-Emadaldin, MD¹ , Branko Krajnovic, MD¹, Ali Ezzati, MD¹, and Ahmed Shawky Abdelgawaad, MD, MHBA^{1,2} 

Global Spine Journal
2022, Vol. 12(7) 1420–1427
© The Author(s) 2022
Article reuse guidelines:
sagepub.com/journals-permissions
DOI: 10.1177/2192568221990421
journals.sagepub.com/home/gsj



Abstract

Study Design: A prospective cohort study in a high-flow spine center in Germany.

Objectives: This study aimed to evaluate clinical outcomes and complications of the trans-tubular translaminar microscopic-assisted percutaneous nucleotomy in cases of cranially migrated lumbar disc herniations (LDH).

Methods: Between January 2013 and January 2018, 66 consecutive patients with cranio-laterally migrated LDH were operated upon. The following outcome measures were evaluated: (1) Visual Analog Scale (VAS) for leg and back pain; (2) Oswestry Disability Index (ODI) and Macnab's criteria. All patients were operated upon with trans-tubular Translaminar Microscopic-assisted Percutaneous Nucleotomy (TL-MAPN). Perioperative radiographic and clinical evaluations were reported. The mean follow-up period was 32 months.

Results: The mean age was 59 years. L4/L5 was the commonest affected level (27 patients). The mean preoperative VAS for leg pain was 6.44 (± 2.06), improved to 0.35 (± 0.59) postoperatively. Dural injury occurred in 1 patient, treated with dural patch. Improved neurological function was reported in 41/44 Patients (neurological improvement rate of 93%) at the final follow up. There was a significant improvement in the mean ODI values, from 50.19 \pm 4.92 preoperatively to 10.14 \pm 2.22 postoperatively ($P < 0.001$). Sixty four out of 66 patients (96%) showed an excellent or good functional outcome according to Macnab's criteria. No recurrent herniations were observed.

Conclusion: The translaminar approach is a viable minimal invasive technique for cranially migrated LDH. The preservation of the flavum ligament is one of the main advantages of this technique. It is an effective, safe and reproducible minimally invasive surgical alternative in treatment of cranially migrated LDHs.

Keywords

lumbar disc herniation, cranially migrated disc, minimal invasive, trans-laminar trans-tubular, discectomy

Introduction

In approximately 10% of patients presenting with extruded LDH, the fragment is migrated cranially at the level of the posterior aspect of the vertebral body.¹⁻³ This zone of migration is called the *hidden zone* and was described in 1971 by *Macnab*.⁴ Migration of the LDH in the hidden zone may result in symptoms related to both the exiting and the traversing nerve roots. In cases of extruded LDH, exposure of the intervertebral disc may not be required. Removal of the extruded fragment alone without discectomy is sufficient to improve patients' symptoms.⁵ The approach for lumbar cranially sequestered disc herniation is controversial. The standard surgical treatment

usually consists of an interlaminar approach as described by Caspar et al,⁶ which is performed either with laminotomy or inter-laminectomy and, when required, with a facetectomy. In

¹ Spine Center, Helios Hospitals Erfurt, Germany

² Department of Orthopaedics and Trauma, Assiut University Medical School, Egypt

Corresponding Author:

Ahmed Shawky Abdelgawaad, Spine Center, Helios Klinikum Erfurt, Nordhaeuser street 74, 99089 Erfurt, Germany.

Email: ahmed.shawky@aun.edu.eg, ahmed.shawky@helios-gesundheit.de, ahsh313@yahoo.com



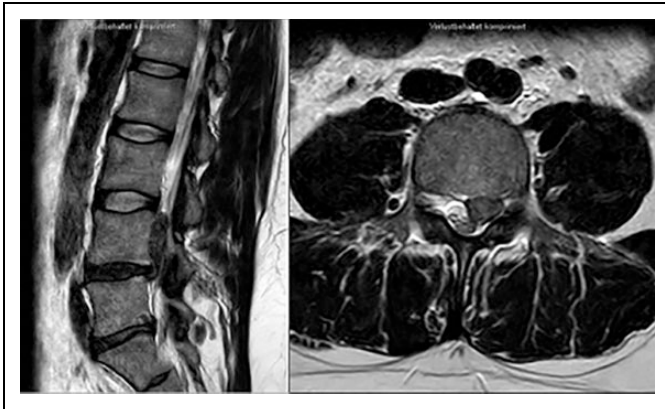


Figure 1. Preoperative MRI of a 45 year-old man, showing cranially migrated sequestration L4/5 on the left side.

some cases, this surgical approach may produce iatrogenic spinal instability depending on the extent of bony resections,⁷ For this reason, in 1998, Di Lorenzo et al⁸ described an approach targeting exposure of Macnab's hidden zone. The approach was based on unroofing the posterior wall of the hidden zone through fenestration of the pars interarticularis. This approach is called a translaminar (TL) approach and allows removal of the extruded fragment without extensive bone removal.

To reduce the surgical trauma and to prevent postoperative instability, Greiner-Perth et al described the muscle-splitting approach through a tubular working canal in 2003.⁹

The aim of this study is to evaluate clinical and functional outcomes as well as complications of trans-tubular translaminar microscopic assisted percutaneous nucleotomy (TL-MAPN). The study compares these outcomes to the published alternatives and also highlights the technical steps and difficulties of this procedure.

Patients and Methods

This is a retrospective analysis of prospectively collected data in a single institution. Between January 2013 and January 2018, a total of 66 patients (37 men and 29 women, with a mean age of 59 ± 12.40 years) were operated upon for cranially migrated LDH in the pre-foraminal and foraminal zones using the TL-MAPN technique as the standard of treatment in our institution. The total number of trans-tubular MAPN procedures—for various indications—done in that period was 1155.

Inclusion Criteria

1. Failure of conservative treatment with persistent (> 6 weeks) or intractable leg pain despite adequate analgesia and/or
2. Significant or progressive neurologic deficit due to compressive radiculopathy, and
3. Corresponding MRI findings of LDH in the hidden zone from L1 to S1.

Table 1. Distribution of Patients' Functional Outcome According to Macnab's Criteria (N = Number of Patients).

Grade	Outcome	Criteria	N
I	Excellent	Complete resolution of symptoms	52
II	Good	Marked improvement but occasional pain	12
III	Fair	Some improvement with a need for pain medications and significant functional restrictions	2
IV	Poor	No change of symptoms or worsening	0

Exclusion Criteria

1. Associated extraforaminal pathology or canal stenosis caused by hypertrophied facet or osteophytes, and/or
2. Associated instability of the affected segment.

All patients demonstrated signs of nerve root compression with radicular pain and hypoesthesia. Motor weakness at least 1 grade (mostly affecting the exiting nerve root) was found in 44 patients (67%) confirmed by neurologist preoperatively.

The most commonly affected level was L4/5 in 27 patients (41%), L3/4 in 20, L5/S1 in 12, L2/3 in 6 and 1 case with L1/2. All patients underwent magnetic resonance imaging (MRI) (Figure 1) of the lumbar spine demonstrating pre-foraminal LDH in 18 cases, foraminal in 27 and both in 21 patients. Two patients were already operated via interlaminar approach at the same level for posterolateral disc herniations. Patients were assessed pre-, postoperatively, and at final follow-up using the German validated Oswestry Disability Index (ODI) and the Visual Analog Scale (VAS) for leg and back pain. In addition, Macnab's criteria⁴ have been used to evaluate patients' satisfaction in 4 grades: excellent, good, fair, and poor (Table 1).

Preoperative diagnostic workup included standing plain radiographs of the lumbar spine anteroposterior, lateral, and dynamic views, and MRI. The mean follow-up period was 32 months (12 -51 months). All patients were counseled about treatment options and possible complications.

Surgical Technique

All operations were performed by 3 senior surgeons (HA, BK, and ASA) with more than 10 years' experience performing this technique.

All operations were performed under general anesthesia in the prone position. The level of interest was identified using an image intensifier (antero-posterior view). A 1.5 cm paramedian stab incision was performed, followed by sequential trans-muscular dilatation of the paravertebral muscles. The docking site is the lamina cranial to the target disc space. The 16 mm working tube was docked on the lamina that covers the disc herniation and fixed by a flexible-arm retractor. After removing the remaining soft tissue from the bony surface, the lateral border of the lamina was visualized.

A high-speed 1.8 mm diamond burr was used to identify the optimal position to drill the bony window (Figure 2). The final

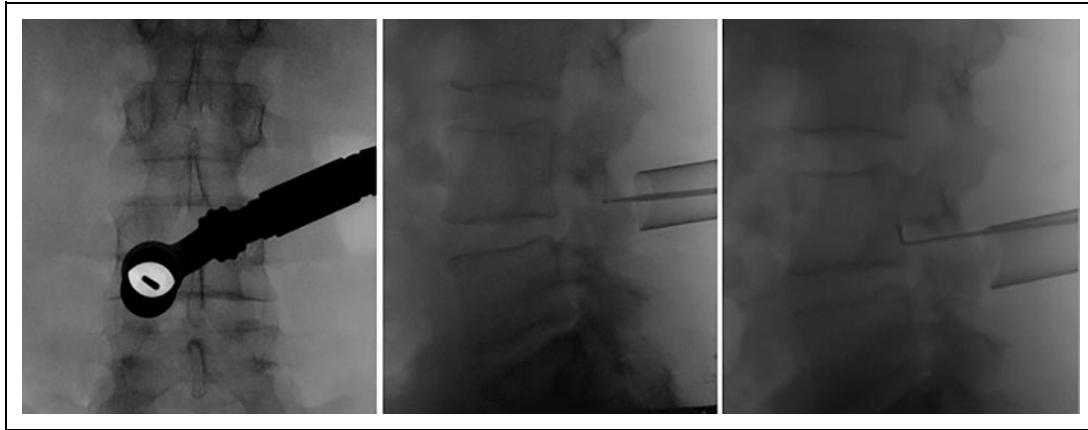


Figure 2. Intraoperative images on the image intensifier showing localization of the level in antero-posterior and lateral view using a 1.5 mm high speed burr just penetrating the outer cortex of the lamina and then the 90-degree hook introduced through the fully prepared laminotomy hole. The hook is placed lateral to the dural sac and behind the vertebral body cranial to the disc space.

position was verified again by the image intensifier AP and lateral. Then, the surgical microscope was used. Proper positioning of the hole depends on 2 factors; level of the lamina, site of the disc herniation and diameter of the pars interarticularis.¹⁰ A 4 mm diamond burr was used to cut an ovoid window into the hemi-lamina cranio-medially to the facet joint. The epidural space is often reached directly as the ligamentum flavum is deficient under the upper half of the lamina. A 3 mm rim of bone in all directions should be preserved to prevent iatrogenic fractures of the pars interarticularis. The epidural exploration begins at the lateral border of the dural sac. Bayoneted instruments were preferably used. Further careful dissection is directed toward the herniated disc fragment. Finally, the fragment is removed with small hooks and rongeurs. After hemostasis and careful control on epidural bleeding, the working channel is removed, and 1 or 2 subcutaneous sutures are performed. The skin closure is done by strips (Figures 3 and 4). Postoperatively, patients were allowed to ambulate from the first day without spinal orthosis. (Figure 5)

Statistical Analysis

The statistical analysis was performed using SPSS version 22.0 (SPSS Inc, IBM Corp, Armonk, NY). A P -value of < 0.05 indicated statistical significance. For the descriptive presentation of results, the absolute and percentage frequency were calculated for categorical variables, while the median, mean, minimum and maximum were calculated for ordinal and quantitative variables. The data showed normal distribution and the paired samples T-test was used to compare means before and after the intervention.

Results

The mean body mass index was 27.5 (range 18–36). The mean duration of symptoms was 24 days (range 1–90 days) (Table 2). Intraoperatively, 1 dural injury had been encountered. The

average operating time was 61 ± 16.59 minutes. Blood loss was minimal in all cases (mean of 31 ± 24.84 ml).

Patients had an average VAS score of 6.44 ± 2.06 (range 2–9) for radicular pain and 3.8 ± 2.19 (range 0–8) for low-back pain before surgery. At the day of discharge from the hospital, the VAS score had decreased to 0.35 ± 0.59 (range 0–2) for radicular pain and 1.29 ± 0.87 (range 0–3) for low-back pain. The improvements in radicular and low-back pain were statistically significant (both $P < 0.001$). Regarding the patients' functional status, there was a significant improvement in the mean ODI values, from 50.19 ± 4.92 preoperatively to 10.14 ± 2.22 at the final follow-up (FU) ($P < .001$). At the final FU, this improvement was maintained, with a mean VAS of 0.12 ± 0.47 (0–3) of leg pain and 1 ± 0.80 (0–4) of back pain. Compared with immediate postoperative values, the change was not statistically significant. The preoperative motor weakness improved at least 1 grade in 41/44 patients (neurological improvement rate (NIR) of 93%) (Table 3). One patient had persistent dysesthesia that improved during the first postoperative 3 months. Another patient had instability above the level of herniation and had to be fused 14 months later and showed a fair outcome. No recurrent herniations were observed.

Sixty four out of 66 patients (96%) showed an excellent or good outcome and fair outcome in 2 Cases with respect to the functional grade according to Macnab (Table 1).

Discussion

The frequency of cranio-laterally extruded disc fragments as reported by Ebleling and Reulen was 7%.¹¹ In our own patient population, 5.7% of all disc herniations were operated on by the trans-tubular TL-MAPN, which clearly indicates the familiarity with the technique. Removal of the fragment without disc excision is supported by several publications. Some authors even found it superior to conventional disc removal because of the lower rate of postoperative spinal instability and lower rate of re-herniations.^{5,12-14} Many studies^{1,8,15,16} reported similar trans-laminar approaches, however, through a normal open

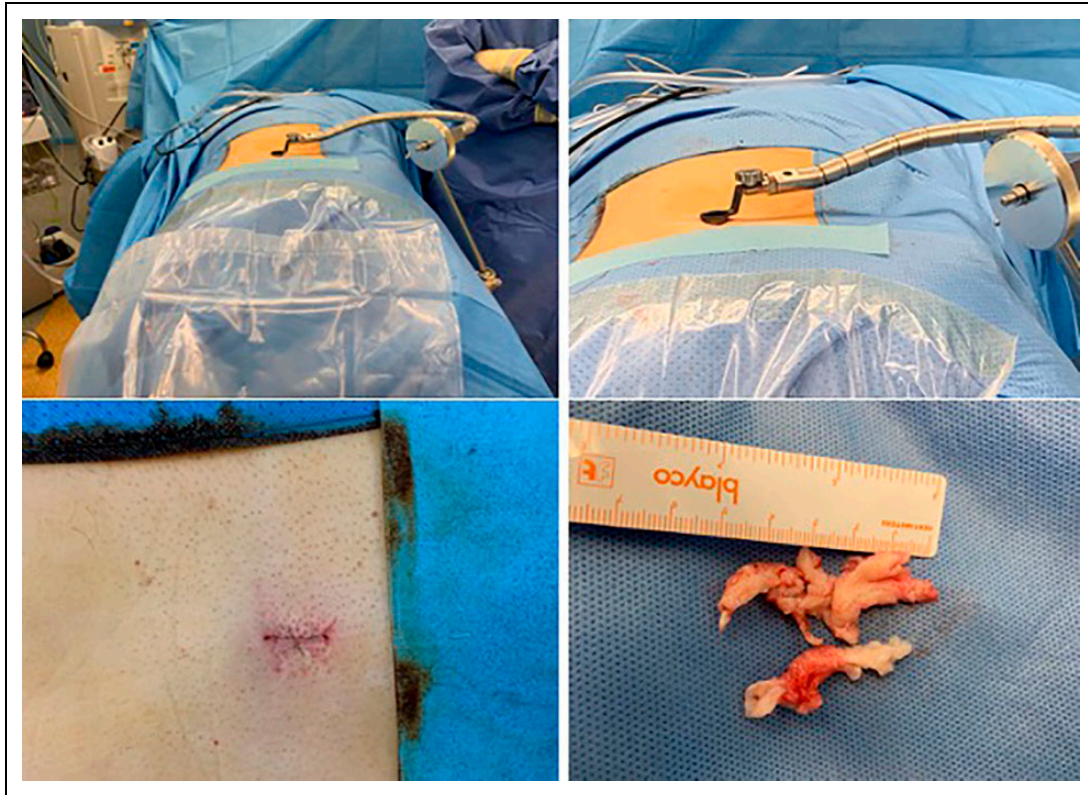


Figure 3. Intraoperative images showing the tube system used fixed to the operative table. The incision after closure and the fragment removed are also shown.

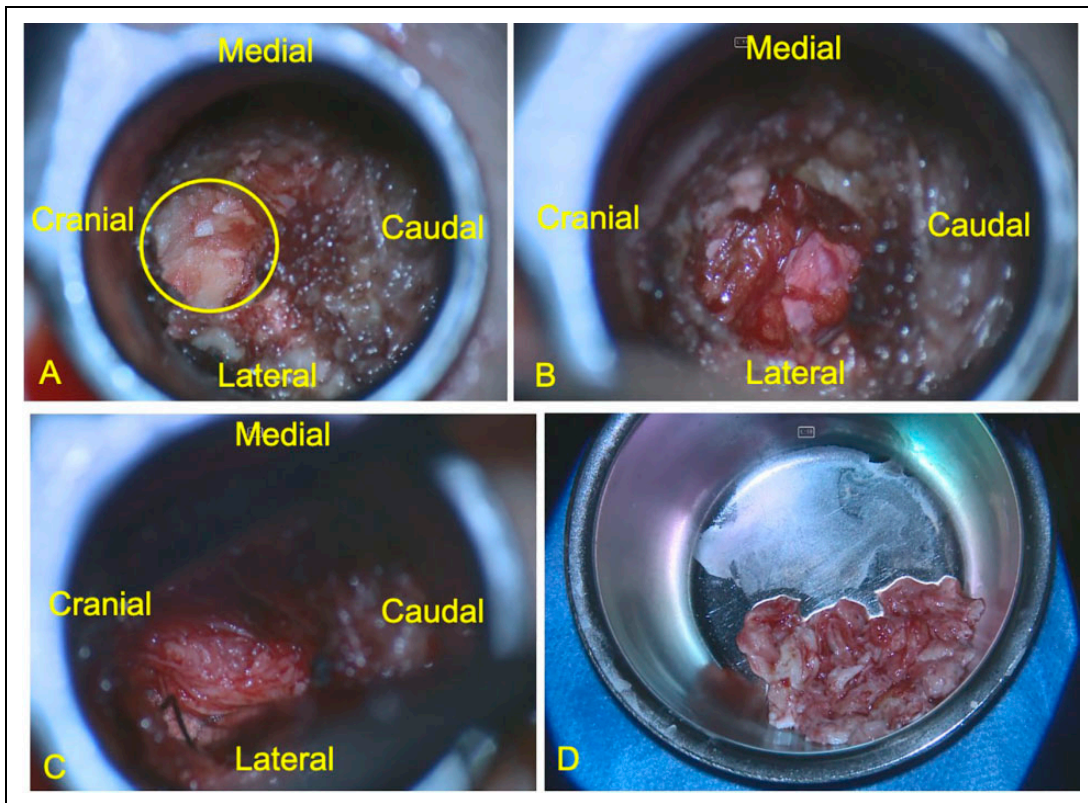


Figure 4. A) The operative field under microscope with the yellow circle encircles the laminotomy hole, while the ligamentum flavum is still in place. B) The dural sac is seen after removal of the ligamentum flavum. C) Part of the sequestered fragment can be seen after medial retraction of the dural sac and hemostasis using a cottonoid patty laterally. D) The removed sequestered fragments.

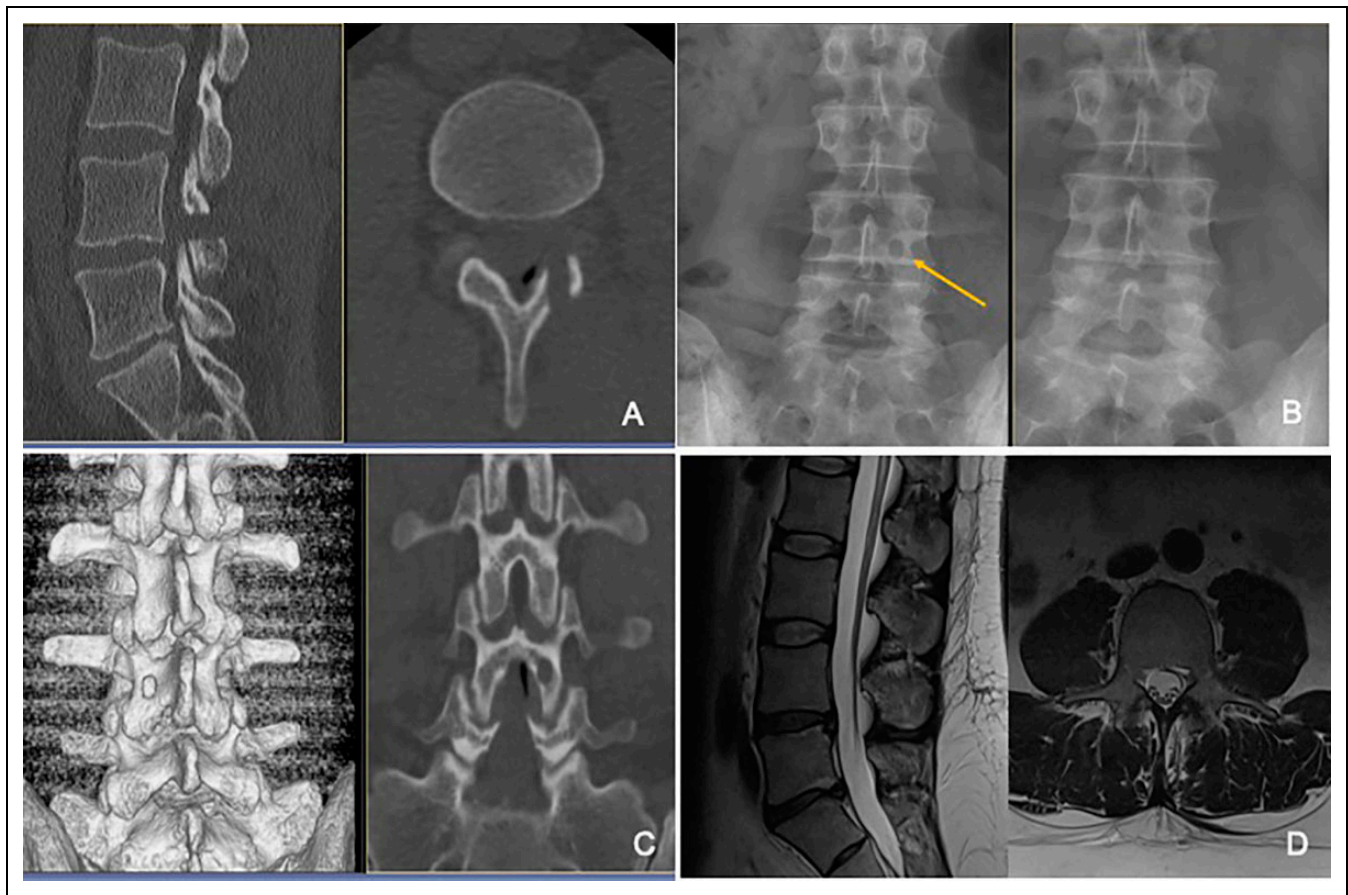


Figure 5. A) Postoperative CT sagittal and axial reconstructions showing the drilled hole in the lamina of L4. B) The pre- and postoperative plain x-ray showing the hole in the lamina on the left image. C) The 3D and coronal reconstruction of the postoperative CT showing clearly the preserved upper and lower border of the lamina and the intact pars interarticularis. D) Postoperative MRI shows the complete removal of the sequestered disc and the minimal muscle trauma.

Table 2. The Main Demographic Data of the Study Patients.

Number of patients	66
Sex	
female	29
male	37
Age (range)	59 ± 12.4 years (range 35-85)
Body Mass Index (BMI)	27.5 (range 18-36)
Duration of symptoms	24 days (range 1-90)
Affected Level:	
L1/2	1
L2/3	6
L3/4	20
L4/5	27
L5/S1	12
Site of disc prolapse:	
preforaminal	18
forminal	27
combined	21

approach. The possibility of using a tubular retractor system in combination to minimize approach-related trauma was also reported.^{3,17,18} The standard interlaminar exposures with

Table 3. Number of Improved Patients According to Clinical Outcome at Final Follow-Up (* LBP = Low Back Pain).

	LBP*	Radicular pain	Motor disturbance	Sensory disturbance
Improved	48	66	41	61
Unchanged	17	0	3	4
Deteriorated	1	0	0	1

upward² or downward laminotomy¹⁹ for the foraminal LDH in the hidden zone were also described.

Placement of the bony fenestration should be planned depending on the localization of the herniation.²⁰ Crossover translaminar approach was recently described by Reinshagen et al.²¹ The entry point was through the medial portion of the contralateral lamina, just at the base of the spinous process. This approach was recommended for recurrent LDH to avoid operating directly through scar tissue.

Vanni et al²² stressed on the possibility to spare the flavum ligament as one of the main advantages of trans-laminar technique. They used the technique for LDH in the pre-foraminal

Table 4. Previous Studies Reporting on Different Techniques Treating LDH in the Hidden Zone Using TL-Approach.

Study	Technique	Retractor used/ incision	Patients	Intraop. complications	Postop. complications	Recurrence	Re-operation
Di Lorenzo 1998⁸	transpars	open (6cm)	28	no	No	no	no
Soldner 2002¹	translaminar	-microsurgical (3-5 cm) - Self-retaining retractor	30	epidural bleeding (5)	2 Remnant symptom	no	1 translaminar
Vogelsang 2007¹⁸	translaminar	tubular	15	no	No	no	1 (Fusion)
Bernucci and Giovanelli 2007²	translaminar	-microsurgical -Casper retractor (3cm)	24	no	No	no	no
Papavero 2008³	translaminar	- Casper retractor - tubular	104	no	Back pain (12) 1 spondylodiscitis	8	8
Westermaier 2008¹⁵	translaminar	not reported	1	no	No	no	no
Schulz 2012²⁰	translaminar	microsurgical (2,5 cm)	35	no	No	no	no
Schulz 2014²⁶	translaminar (comperative study)	microsurgical (2-4 cm)	22 (total 69)	no	1	no	1 (re-exploration)
Reinshagen 2015²¹	translaminar (crossover)	microsurgical (3 cm)	8	no	No	no	no
Morrison 2015³¹	translaminar	microsurgical (1.5-2 cm)	1	no	No	no	no
Vanni 2015²²	translaminar	-Casper retractor - tubular retractor	38	Bleeding in 5%	No	no	no
De Bonis 2017²⁴	transpars (modified-Lateral border)	-Casper retractor -tubular	47	no	No	no	no
Cossandi 2018¹⁶	translaminar	microsurgical (3cm)	32	insufficient exposure (2)	back pain (7)	no	1 patient
Son 2018²⁵	translaminar	-Casper Retractor -tubular	20 (total 48)	no	leg pain in (2)	no	no
Dezawa 2012³²	translaminar	endoscopic	9	no	No	no	no
Ikuta 2013³³	translaminar	endoscopic	7	no	No	no	no
Du 2016²³	translaminar -local anesthesia	endoscopic (8mm)	7	no	No	no	no
Xin 2017³⁴	translaminar - epidural anesthesia	endoscopic	11	no	No	no	no

zones, for the levels above L2–L3, and in the pre-foraminal and foraminal zones, for the levels below L3–L4. Recently, percutaneous translaminar endoscopic approach was described for down-migrated LDH under local anesthesia without any dural or neural injuries.²³ For the treatment of purely foraminal LDH, De Bonis et al²⁴ reported on 47 patients using trans-pars microscopic approach with drilling the lateral border of the pars interarticularis. There were no cases of spinal instability and no recurrence at the follow-up. Compared to interlaminar approach, trans-laminar approach

provided more relief from back pain and improved quality of life better than the conventional interlaminar approach.²⁵ Comparing interlaminar, translaminar and endoscopic transforaminal surgical approaches in the treatment of LDH in the hidden zone. It was found that all 3 surgical approaches led to a significant reduction of preoperative pain. The interlaminar and translaminar techniques were the safest and fastest ways of gaining access to cranially migrated disc material and also proved to be the most effective approaches over a period of 6 weeks and the most successful in relieving pain. The

endoscopic transforaminal approach was relatively unsuitable for the removal of cranially displaced disc fragments. By contrast, endoscopic translaminar and endoscopic interlaminar approaches may lead to better results in the future.²⁶ To reduce the surgical trauma, we combined the TL approach with the use of a working tube

(trans-tubular) that is inserted after blunt dilatation of the paraspinal muscles, followed by use of surgical microscope. This technique has been described by several authors for use in lumbar discectomy and decompression procedures.^{27,28} It preserves as many normal muscular and ligamentous attachments to the spine as possible and accordingly, beneficial for the long-term maintenance of spinal stability and alignment.²⁹ This becomes more relevant as the cranial sequestration is strongly correlated with increased age.³⁰ The mean age in our study was 59 years. Such patients are more likely to suffer from osteoporosis and degenerative spinal disorders such as facet joint hypertrophy, which may manifest segmental instability.

Radicular motor weakness is commonly encountered in this group of patients. It may be due to location of the herniation with less space available for nerve root and also because of the vulnerability of neural elements in elderly patients.

The use of microscope is easy and familiar to most spine surgeons. In contrast to endoscopy, it offers the benefits of a 3-dimensional perspective. The use of endoscopy is a valuable alternative; however, it is difficult to reach these cranially migrated fragments and it entails a long learning curve.

The main strengths of this study are the number of patients, homogenous pathology, and technique. However, the absence of a control group and randomization are the main weaknesses. The authors tried to overcome this comparing our results to the published results using different techniques for such pathology (Table 4).

Conclusion

In conclusion, access to the hidden zone remains surgically challenging. TL-MAPN represents a valuable reproducible alternative in treatment of LDH in this zone. It is a tissue-preserving minimal invasive technique in such cases. The ligamentum flavum, the pars interarticularis and the facet joint are preserved. It is a minimal invasive technique with minimal morbidity. Clinical outcomes, complications, recurrence, and re-operation rate are comparable with other techniques. The approach allows access to the extruded cranial migrated disc fragment and intervertebral disc space comparable to classical approaches.

Declaration of Conflicting Interests


The author(s) declared no potential conflicts of interest with respect to the research, authorship, and/or publication of this article.

Funding

The author(s) received no financial support for the research, authorship, and/or publication of this article.

ORCID iD

Sadat Seyed-Emadaldin, MD  <https://orcid.org/0000-0002-3414-4040>

Ahmed Shawky Abdelgawaad, MD, MHBA  <https://orcid.org/0000-0003-2083-7265>

References

1. Soldner F, Hoelper B, Wallenfang T, Behr R. The translaminar approach to canalicular and cranio-dorsolateral lumbar disc herniations. *Acta Neurochir.* 2002;144(4):315-320.
2. Bernucci C, Giovanelli M. Translaminar microsurgical approach for lumbar herniated nucleus pulposus (HNP) in the "hidden zone": clinical and radiologic results in a series of 24 patients. *Spine.* 2007;32(2):281-284.
3. Papavero L, Langer N, Fritzsche E, Emami P, Westphal M, Kothe R. The translaminar approach to lumbar disc herniations impinging the exiting root. *Operative Neurosurgery.* 2008;62(suppl_1):ONS173-ONS178.
4. Macnab I. Negative disc exploration: an analysis of the causes of nerve-root involvement in sixty-eight patients. *J Bone Joint Surg Am.* 1971;53(5):891-903.
5. Faulhauer K, Manicke C. Fragment excision versus conventional disc removal in the microsurgical treatment of herniated lumbar disc. *Acta Neurochir (Wien).* 1995;133(3-4):107-111.
6. Caspar W, Campbell B, Barbier DD, Kretschmmer R, Gotfried Y. The Caspar microsurgical discectomy and comparison with a conventional standard lumbar disc procedure. *Neurosurgery.* 1991;28(1):78-87.
7. Garrido E, Connaughton PN. Unilateral facetectomy approach for lateral lumbar disc herniation. *J Neurosurgery.* 1991;74(5):754-756.
8. Di Lorenzo N, Porta F, Onnis G, Cannas A, Arbau G, Maleci A. Pars interarticularis fenestration in the treatment of foraminal lumbar disc herniation: a further surgical approach. *Neurosurgery.* 1998;42(1):87-89; discussion 89-90.
9. Greiner-Perth R, Böhm H, Allam Y. A new technique for the treatment of lumbar far lateral disc herniation: technical note and preliminary results. *Eur Spine J.* 2003;12(3):320-324.
10. Reulen H-J, Muller A, Ebeling U. Microsurgical anatomy of the lateral approach to extraforaminal lumbar disc herniations. *Neurosurgery.* 1996;39(2):345-351.
11. Ebeling U, Reulen H. Are there typical localisations of lumbar disc herniations? A prospective study. *Acta Neurochir.* 1992;117(3-4):143-148.
12. Wenger M, Mariani L, Kalbarczyk A, Gröger U. Long-term outcome of 104 patients after lumbar sequestrectomy according to Williams. *Neurosurgery.* 2001;49(2):329-335.
13. Thomé C, Barth M, Scharf J, Schmiedek P. Outcome after lumbar sequestrectomy compared with microdiscectomy: a prospective randomized study. *J Neurosurgery: Spine.* 2005;2(3):271-278.
14. Kast E, Mohr K, Richter H, Börm W. Results of simple fragment excision in lumbar disc surgery. *Der Orthopäde.* 2005;34(9):931-937.
15. Westermaier TL, Meinhardt M, Vince G, Roosen K, Ernestus R. Translaminar approach to herniated lumbar discs in old

- patients with degenerative spondylolisthesis. *Int J Spine Surg.* 2008;5(1).
16. Cossandi C, Fanti A, Gerosa A, et al. Translaminar approach for treatment of hidden zone foraminal lumbar disc herniations: surgical technique and preoperative selection of patients with long-term follow-up. *World Neurosurg.* 2018;116:182-187.
 17. Kulkarni AG, Kantharajanna SB, Dhruv AN. The use of tubular retractors for translaminar discectomy for cranially and caudally extruded discs. *Indian J Orthop.* 2018;52(3):328-333.
 18. Vogelsang JP. The translaminar approach in combination with a tubular retractor system for the treatment of far cranio-laterally and foraminal extruded lumbar disc herniations. *Zentralb für Neuro-Central Eur Neuros.* 2007;68(01):24-28.
 19. Naderi S, Onen MR. Downward laminotomy technique for hidden zone foraminal disk herniations: technical notes and preliminary results. *Clin Spine Surg.* 2018;31(4):152-155.
 20. Schulz C, Abdeltawab A, Mauer U. Translaminar approach to cranio-laterally herniated lumbar disc prolapse. *Acta Neurochir (Wien).* 2012;154(4):711-714.
 21. Reinshagen C, Ruess D, Molcanyi M, et al. A novel translaminar crossover approach for pathologies in the lumbar hidden zone. *J Clin Neuro.* 2015;22(6):1030-1035.
 22. Vanni D, Sirabella FS, Guelfi M, et al. Microdiscectomy and translaminar approach: minimal invasiveness and flavum ligament preservation. *Global Spine J.* 2015;5(02):084-092.
 23. Du J, Tang X, Jing X, Li N, Wang Y, Zhang X. Outcomes of percutaneous endoscopic lumbar discectomy via a translaminar approach, especially for soft, highly down-migrated lumbar disc herniation. *Int Ortho.* 2016;40(6):1247-1252.
 24. De Bonis P, Mongardi L, Pompucci A, et al. Transpars microscopic approach for the treatment of purely foraminal herniated lumbar disc: a clinical, radiological, two-center study. *Spine.* 2017;42(6):E371-E378.
 25. Son S, Lee SG, Kim WK, Ahn Y. Advantages of a microsurgical translaminar approach (keyhole laminotomy) for upper lumbar disc herniation. *World Neuro.* 2018;119: e16-e22.
 26. Schulz C, Kunz U, Mauer U, Mathieu R. Early postoperative results after removal of cranially migrated lumbar disc prolapse: retrospective comparison of three different surgical strategies. *Adv ortho.* 2014;2014.
 27. Palmer S. Use of a tubular retractor system in microscopic lumbar discectomy: 1 year prospective results in 135 patients. *Neuro Focus.* 2002;13(2):1-4.
 28. Greiner-Perth R, Boehm H, El Saghir H. Microscopically assisted percutaneous technique as a minimally invasive approach to the posterior spine. In: Mayer HM, ed. *Minimally Invasive Spine Surgery.* Berlin, Heidelberg: Springer; 2006. doi:10.1007/3-540-29490-2_36
 29. Fessler RG. Minimally invasive spine surgery. *Neurosurgery.* 2002;51(5 suppl):Siii-iv.
 30. Daghighi MH, Pouriesha M, Maleki M, et al. Migration patterns of herniated disc fragments: a study on 1,020 patients with extruded lumbar disc herniation. *Spine J.* 2014;14(9):1970-1977.
 31. Morrison R, Schnake KJ. Lumbar sequestrectomy via a translaminar approach. *Eur Spine J.* 2015;24(Suppl 8):S957-S958. doi: 10.1007/s00586-015-4331-1
 32. Dezawa A, Mikami H, Sairyo K. Percutaneous endoscopic translaminar approach for herniated nucleus pulposus in the hidden zone of the lumbar spine. *Asian J Endosc Surg.* 2012;5(4): 200-203. doi:10.1111/j.1758-5910.2012.00142.x
 33. Ikuta K, Tono O, Senba H, Kitamura T, Komiya N, Oga M, Shidahara S. Translaminar microendoscopic herniotomy for cranially migrated lumbar disc herniations encroaching on the exiting nerve root in the preforaminal and foraminal zones. *Asian Spine J.* 2013;7(3):190-195. doi:10.4184/asj.2013.7.3. 190
 34. Xin Z, Liao W, Ao J, Qin J, Chen F, Ye Z, Cai Y. A modified translaminar osseous channel-assisted percutaneous endoscopic lumbar discectomy for highly migrated and sequestered disc herniations of the upper lumbar: Clinical outcomes, surgical indications, and technical considerations. *Biomed Res Int.* 2017;2017: 3069575. doi:10.1155/2017/3069575