

CASE REPORT

Interdisciplinary management of a partially dentate adult patient with a complex malocclusion

Chui Yi Sarah Low^{1,2}  | Desmond Cheer-Vern Ong^{3,4}  | Elissa Freer⁴ 

¹Private Practice, Singapore City, Singapore

²School of Dentistry, The University of Queensland, Herston, QLD, Australia

³Private Practice, Townsville, QLD, Australia

⁴Discipline of Orthodontics, The University of Queensland, Herston, QLD, Australia

Correspondence

Chui Yi Sarah Low, Private Practice, Singapore City, Singapore; School of Dentistry, The University of Queensland, Herston, QLD, Australia.
Email: sarah.low@uq.edu.au

Abstract

Adult patients may present with complex malocclusions requiring extensive oral rehabilitation. This case report demonstrates how carefully planned interdisciplinary management can provide pleasing outcomes despite the considerable initial clinical challenges.

KEYWORDS

adult patient, complex malocclusion, interdisciplinary management, partially edentulous

1 | INTRODUCTION

Implants can be used to facilitate the prosthetic rehabilitation of a long edentulous anterior span and ultimately avoid the need for a removable partial denture. Comprehensive diagnosis and appropriately coordinated interdisciplinary treatment are central requirements to successfully manage complex cases. This case report demonstrates a pleasing treatment outcome for a patient with a challenging Class III malocclusion, complicated by atrophic changes in the anterior maxilla resulting from the historical loss of anterior teeth. A combination of orthodontic treatment, bimaxillary orthognathic surgery, bone grafting, restorative implant placement and prosthodontic procedures were provided in a meticulously planned sequence to achieve the desired outcome.

Studies have reported that tooth loss, particularly anterior tooth loss, is linked to a lower oral health-related quality of life.^{1–3} Patients with unsatisfactory esthetics relating to an anterior edentulous condition may also negatively impact upon social interactions and employment prospects.¹ Removable

dentures may reduce the undesirable effects associated with edentulism, however, their removable nature may not be universally accepted by patients. It has been reported that 27% of patients considered wearing a partial denture to be upsetting⁴ and that functional and psychological compromises may still occur even despite the provision of a partial denture.⁵ Several studies have reported that patients who received implant-supported appliances benefit from improved psychosocial outcomes⁶ and quality of life,^{7,8} through improvements in chewing function, bite force, esthetics, and dental health^{7–10} when compared to patients who received conventional removable dentures.

Following tooth extraction, the alveolar ridge undergoes residual ridge resorption. There are several factors influencing the rate and pattern of resorption of the residual ridge, including mechanical forces placed on the ridge, the presence of dentures and/or muscle tone.¹¹ The residual ridges of denture wearers are reported to be shorter¹² and narrower¹³ than the ridges of non-denture wearers. The anterior region was observed to resorb four times more than posterior region

This is an open access article under the terms of the Creative Commons Attribution-NonCommercial-NoDerivs License, which permits use and distribution in any medium, provided the original work is properly cited, the use is non-commercial and no modifications or adaptations are made.

© 2021 The Authors. *Clinical Case Reports* published by John Wiley & Sons Ltd.

in the vertical dimension,¹¹ with residual ridge resorption and atrophy of the alveolar bone in the anterior maxilla expected following prolonged tooth loss and denture wear. As the anterior maxilla tends to resorb posteriorly and superiorly following tooth loss,¹⁴ this may result in a previously unforeseen skeletal Class III discrepancy,¹⁵ particularly following prolonged tooth loss and denture wear. Therefore, a significantly atrophic maxilla will often present additional challenges which may complicate the proposed future management with dental implant-supported prostheses in this region of the mouth.

Severe Class III malocclusions generally require orthognathic surgical correction, which may involve maxillary advancement, mandibular setback, or bimaxillary surgery.¹⁶ Orthodontic decompensation is conventionally performed prior to orthognathic surgery to ensure maximum predictability and appropriate dimension of the surgical movements.¹⁶ Bimaxillary surgery has greater potential to simultaneously correct anteroposterior and vertical skeletal discrepancies¹⁷ and has been demonstrated to have favorable post-operative occlusal stability when performed in combination with post-surgical orthodontic finishing and detailing.¹⁸

This case report details the management of a patient with a partially dentate and atrophic maxilla, which manifested as a skeletal Class III malocclusion, through a combination of orthodontic treatment, bimaxillary orthognathic surgery, bone grafting, restorative implant placement and subsequent prosthodontic procedures.

2 | CASE REPORT

A 37-year-old patient presented to a general dental practitioner to investigate the possibility of replacing the removable partial denture with a fixed prosthesis (Figure 1). The medical history was not significant. A prioritized problem list was developed (Table 1). Initial carious lesions were noted in the 17, 15, 27, 37, 35, 33, 44, 45, 47. The margins of the amalgam restoration in the 16 were also deteriorating. The panoramic radiograph demonstrated that the 13, 12, 11, 21, 22, 23, 27, 36, 46 had been previously removed (Figure 2). A maxillary partial denture was currently being worn to replace the missing 13, 12, 11, 21, 22, 23, which were removed due to caries approximately 20 years previously. At the initial consultation, the patient communicated a specific dissatisfaction with the removable partial denture. The patient indicated a willingness to undergo extensive interdisciplinary treatment to achieve the ultimate objective of fixed prosthodontic rehabilitation of the edentulous anterior maxilla with osseointegrated titanium implants.

The patient was subsequently referred to an orthodontist and oral maxillofacial surgeon to determine the extent of interdisciplinary management required to achieve the desired treatment objectives (Table 2). Although the fixed prosthodontic rehabilitation was the primary request, all of the involved practitioners held the opinion that addressing the caries and improving the patient's oral hygiene was of the highest priority.

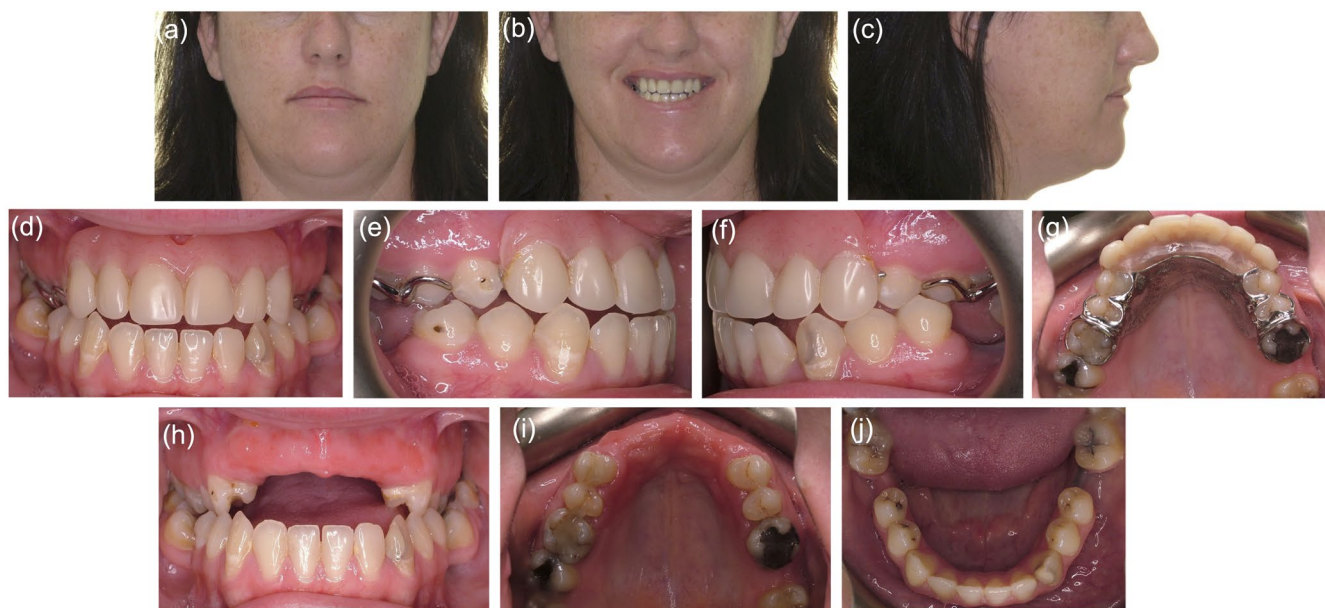


FIGURE 1 A-C, Pre-treatment extra-oral photographs of a 37-year-old patient with the maxillary partial denture in situ. Note the favorable pre-existing upper lip position. D-G, Pre-treatment intra-oral photographs with the maxillary partial denture in situ. H-J, Pre-treatment intra-oral photographs with the maxillary partial denture removed

2.1 | Orthodontic diagnosis

The orthodontic diagnostic assessment revealed a Class I malocclusion with a 1.5 mm anterior open bite and minimal anterior overjet with the removable partial denture in situ. Bilateral posterior lingual crossbites in the premolar and molar regions were also noted. The tooth alignment in the maxillary and mandibular arches was satisfactory, except for the mesial tipping of the 37 and 47, which had occurred secondary to previous extraction of the 36 and 46. Residual extraction space was also noted in the 27 location.

Without the removable partial denture in place, significant loss of maxillary lip support is evident. During the 20 years since the removal of the maxillary anterior teeth, significant alveolar ridge resorption has occurred, which resulted in the retrusive position of the anterior maxilla. Cephalometric analysis revealed a severe skeletal Class III base relationship with dolichofacial vertical proportions (Figure 2).

TABLE 1 Prioritized problem list

1. Caries noted in 17, 15, 27, 37, 35, 33, 44, 45, 47
2. Class III skeletal base relationship due to atrophic anterior alveolar bone associated with long-standing maxillary anterior edentulism
3. Missing 27, mesially tilted 37 and 47 and retroclined mandibular anterior teeth
4. Relatively narrow posterior maxillary archform

2.2 | Interdisciplinary treatment plan

The general dental practitioner, oral and maxillofacial surgeon, prosthodontist and orthodontist staged several interdisciplinary meetings to develop a comprehensive treatment plan. The final interdisciplinary treatment plan was determined to involve a carefully sequenced combination of preventative care followed by orthodontic treatment, bimaxillary orthognathic surgery, bone grafting, restorative implant placement and subsequent fixed prosthodontic procedures. The relevant benefits, costs and risks of all aspects of this

TABLE 2 Treatment objectives

1. Restore all carious lesions and stabilize the caries risk. Oral hygiene instruction, preventative strategies and dietary advice are required to effectively manage the increased caries risk. Periodic reassessment of the patient's caries risk throughout and following orthodontic treatment is also indicated.
2. Orthodontic treatment in conjunction with bimaxillary orthognathic surgery and bone grafts in the maxillary anterior region are required for subsequent implant placement. Permanently restore the partially dentate anterior region with three implants and one six-unit bridge to optimize the esthetic and functional outcomes.
3. Orthodontically close the residual 27 extraction space and provide appropriate decompensation to facilitate the bimaxillary orthognathic surgery
4. Non-surgical orthodontic maxillary expansion to improve the maxillary and mandibular arch coordination

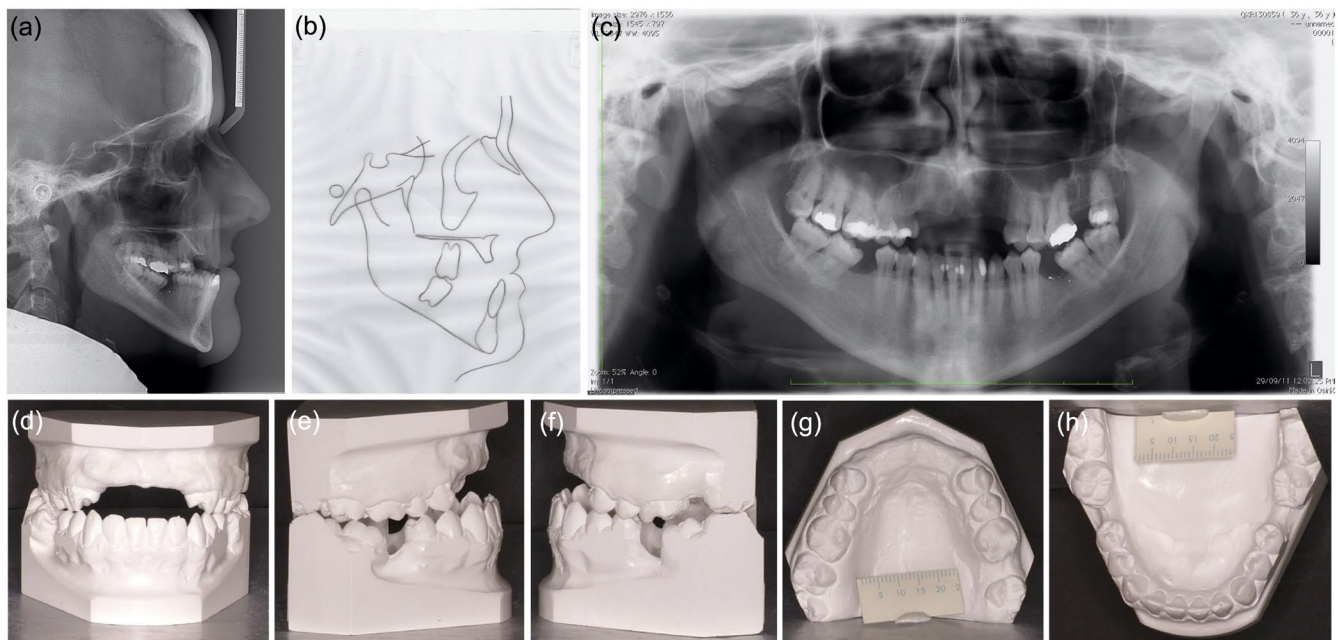


FIGURE 2 A, Pre-treatment cephalometric radiograph and tracing with the maxillary partial denture removed demonstrates a severe skeletal Class III base relationship due to the significant alveolar bone loss in the anterior maxilla. C, Pre-treatment panoramic radiograph demonstrates the significant alveolar bone loss in the anterior maxilla, mesial tipping of the 37,47 and various large pre-existing restorations. D-H, Pre-treatment diagnostic study models reveal the extent of the atypical malocclusion and was used to facilitate the planning of the required interdisciplinary treatment

complex treatment plan were clearly communicated to the patient prior to and throughout the overall treatment, as ongoing informed consent was vitally important. The structured interdisciplinary communication greatly facilitated the informed consent process for the patient and ensured that every practitioner was cognizant of their role and also the timing and order of the required procedures. Alternative treatment options (Table 3) were also discussed, however, were subsequently deemed to be inappropriate as the primary concern would not be effectively addressed.

Understandably, the patient had reservations regarding the expected absence of maxillary anterior teeth for any significant length of time during treatment for cosmetic and social reasons. A significant amount of lateral thinking was required to overcome this particular patient concern. A combination of partial dentures during the pre-surgical orthodontic preparation, fabrication of tooth replica pontics for attachment to the orthodontic archwire for the post-surgical orthodontic management, a temporary vacuum-formed clear retainer and an acrylic partial denture following orthodontic treatment were all planned to provide temporary cosmetic solutions until the definitive prosthodontic procedures could be performed.

In the mandibular arch, the mesially tilted 37 and 47 required orthodontic uprighting due to the previous loss of the 36 and 46. It was decided to upright the 37 and 47 through re-opening the 36 and 46 extraction spaces as the orthodontic biomechanics implemented for this planned tooth movement would also facilitate the pre-surgical orthodontic decompensation of the mandibular anterior teeth.

TABLE 3 Alternative treatment options

<p>. No treatment</p> <ul style="list-style-type: none"> • This treatment option was not recommended due to the pre-existing caries • Restoration of all carious lesions and stabilization of the caries risk is required for ongoing dental health • The patient expressed a strong desire to proceed with the required interdisciplinary treatment to achieve pleasing anterior smile esthetics and improve occlusal function without a removable partial denture
<p>. Removable Prosthodontic Treatment (accepting the current maxillary partial denture)</p> <ul style="list-style-type: none"> • Reduces the associated biological risks, financial and opportunity costs • This option was declined by the patient
<p>. Fixed Prosthodontic Treatment (in isolation without pre-prosthodontic surgical orthodontic treatment)</p> <ul style="list-style-type: none"> • Without combined surgical orthodontic management to address the atrophic maxilla and skeletal Class III skeletal base relationship, restorative implants cannot be placed appropriately in the anterior maxilla to provide a final prosthodontic restoration with positive anterior overjet and overbite • This option was not deemed to be inappropriate by both the patient and the involved clinicians

General dental reviews were recommended at six-monthly intervals throughout the orthodontic treatment to reassess the caries risk and oral hygiene.

2.3 | General dental management and reassessment

The general dentist provided the required restorations prior to the commencement of orthodontic treatment. All carious surfaces were restored with composite resin. Professional application of topical fluoride was performed and use of NeutraFluor® 5000 Toothpaste (Colgate Oral Pharmaceuticals) was recommended for use leading up to and throughout the proposed orthodontic treatment.

The patient was seen periodically during her orthodontic treatment to reassess the restorations and caries risk, to perform subsequent professional topical fluoride application and removal of calculus. Six-monthly general dental reviews have been recommended for this patient indefinitely.

2.4 | Orthodontic and orthognathic surgical management

2.4.1 | Placement of fixed appliances

Fixed orthodontic appliances were placed in the mandibular arch to provide an improvement in alignment and the mandibular incisor angulation in preparation for orthognathic surgery. The patient continued to wear the maxillary partial denture.

2.4.2 | 6 months

Following preliminary alignment of the mandibular arch, study models were obtained to plan for placement of the maxillary fixed appliances (Figure 2). It was subsequently noted that the posterior maxillary arch was slightly insufficient in the transverse dimension as the mandibular posterior teeth had also uprighted in the bucco-lingual dimension. The orthodontist and maxillofacial surgeon determined that the posterior maxillary arch width dimension required an increase of approximately 4 mm for optimal antagonistic occlusion with the mandibular arch. Given the complexity of the planned bimaxillary orthognathic surgery and the relatively small amount of expansion required, a surgically assisted maxillary expansion was not recommended due to the expected increase in surgical morbidity. A banded rapid maxillary expander with a Hyrax expansion screw component was determined to be the appliance of choice (Figure 3).

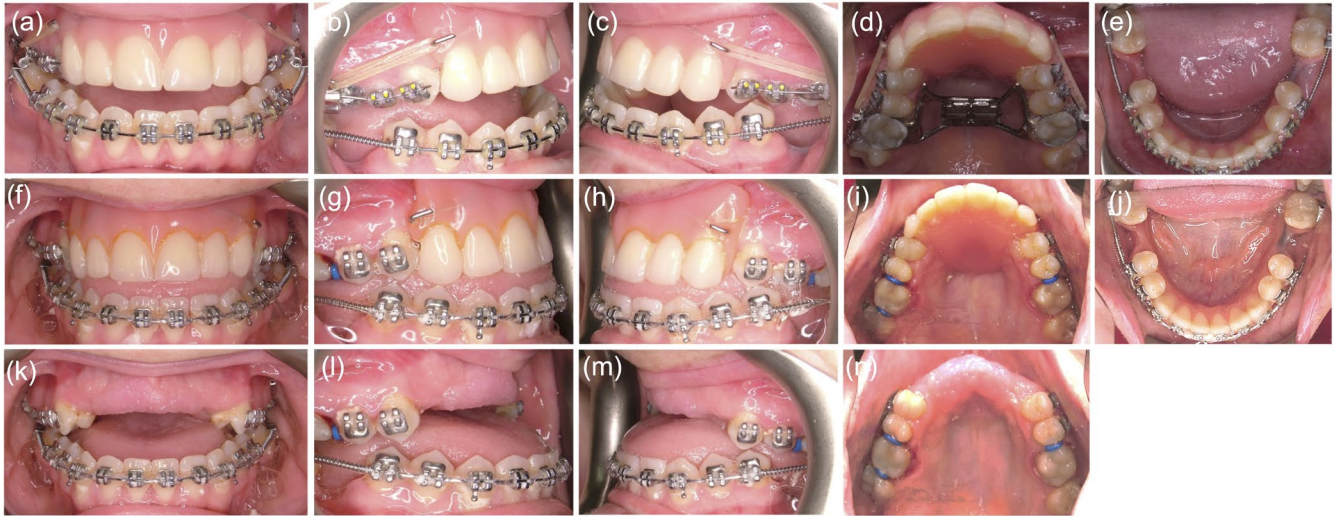


FIGURE 3 A-E, Intraoral photographs obtained 9 months into active treatment. A maxillary expansion appliance was placed at this time along with sectional fixed orthodontic appliances to improve the transverse arch dimension. With these maxillary fixed appliances in situ, the pre-existing maxillary partial denture could no longer be worn. Therefore a temporary acrylic partial denture was issued with stainless steel attachment hooks for daily placement of orthodontic elastics to improve the retention of this removable prosthesis. F-N, Intraoral photographs obtained at 14 months into treatment with and without the patient's denture in situ. Note the increase in the transverse dimension of the maxillary arch and successful uprighting of the mandibular second molars

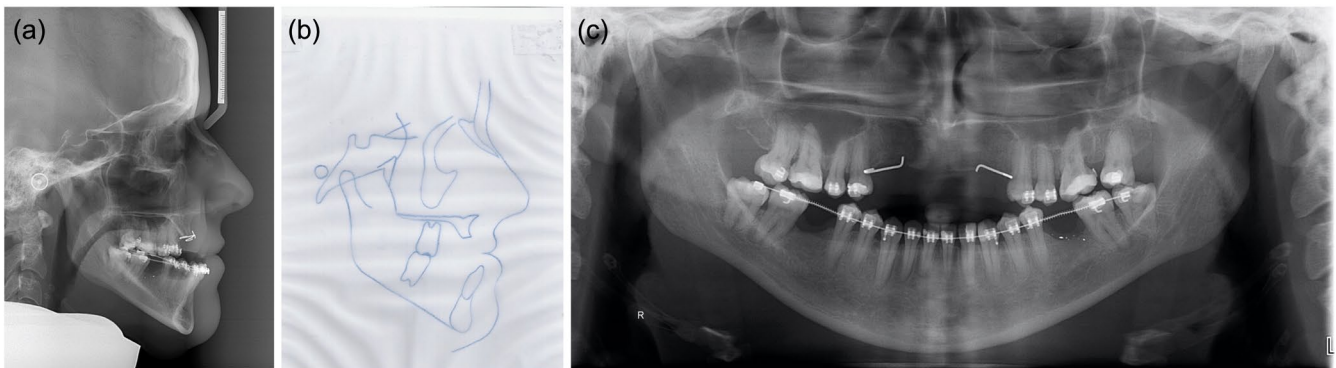


FIGURE 4 A-B, The progress lateral cephalograph and tracing obtained at 14 months demonstrated successful pre-surgical orthodontic decomensation of the mandibular incisor angulation and confirmed the extent of orthognathic surgical movements needed in the anteroposterior dimension. C, The progress panoramic radiograph obtained at 14 months confirmed the successful uprighting of the 37 and 47 and satisfactory root parallelism of the overall dentition

2.4.3 | 8 months

Fixed orthodontic appliances were placed in the maxillary arch in conjunction with a banded rapid maxillary expander. It was correctly anticipated that the maxillary partial denture would no longer fit following the placement of the orthodontic appliances, therefore an acrylic denture was constructed and issued at this appointment for cosmetic reasons. The orthodontist also designed the acrylic denture with metal attachment hooks to help secure the acrylic denture with orthodontic elastics (Figure 3). The patient was advised to perform a turn of the midline expansion screw every day, with each turn equating to

0.25 mm of expansion. A total of 19 turns were performed and at this point, the maxillary arch width was determined to be adequate.

The primary objective of the orthodontic treatment in the maxillary arch was to improve the arch coordination with the mandibular arch through an increase in transverse intermolar dimension and levelling the curve of Spee.

2.4.4 | 14 months

Intraoral photographs and progress radiographs were obtained to assess the treatment. The progress panoramic

radiograph demonstrated successful uprighting of the 37 and 47 and satisfactory root parallelism. The lateral cephalograph demonstrated ideal pre-surgical mandibular incisor angulation and confirmed the extent of the orthognathic surgical movements that were required in the anteroposterior dimension (Figure 4).

2.4.5 | 18 months

Pre-surgical photographs and study models were taken to finalize the orthognathic surgical planning. A facebow record was taken and the study models were mounted. It was determined that the maxilla required an advancement of 5.0 mm on the right side and 6.0 mm on the left side and the mandible required a setback of 5.5 mm on the right side and 5.0 mm on the left side (Figure 5). An autogenous bone graft in the anterior maxilla was also planned in conjunction with the orthognathic surgery. As no functional pressure could be applied onto the anterior bone graft for at least 3 months, the current acrylic denture would become redundant. An alternate cosmetic appliance was required as the patient was not prepared to be without anterior teeth for this extended

timeframe. Interdisciplinary discussion provided a solution, with a Luxatemp® (DMG Chemisch-Pharmazeutische) multi-tooth pontic constructed and subsequently attached to an orthodontic archwire with ligature wire (Figure 6).

2.4.6 | 20 months

Bimaxillary orthognathic surgery was performed as previously planned, with a combination of maxillary advancement and mandibular setback osteotomies. Mid-face and mandibular screws and plates were placed as appropriate (Synthes®). A bone graft was also placed in the anterior maxilla simultaneously under the same general anesthetic to facilitate future implant placement in this region. Autogenous bone was harvested from the mandibular sagittal split osteotomy site (i.e. lateral cortex of the mandibular body). The bone was transferred to the anterior maxilla after the Le Fort 1 advancement was performed and augmented with BondBone® (MIS Implants Technologies Ltd.). At 2 weeks post-surgery the Luxatemp® multi-tooth pontic was trimmed appropriately to avoid any contact onto the anterior maxilla and provided satisfactory esthetics for the patient. (Figure 6)

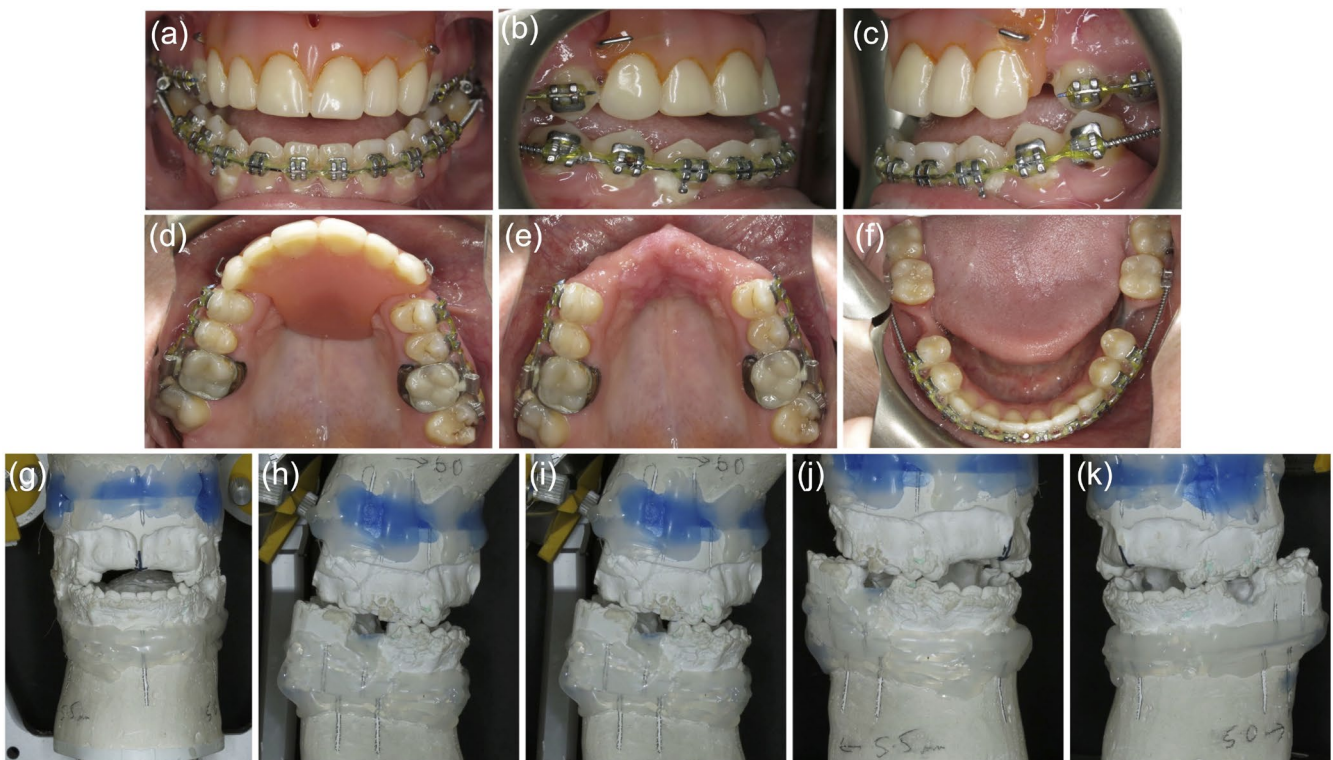


FIGURE 5 A-F, Pre-surgical progress photographs obtained at 18 months into active treatment with and without the acrylic partial denture in situ. Note the significant reverse anterior overjet which resulted from the pre-surgical orthodontic decompensation of the mandibular incisor angulation. G-K, Pre-surgical study models were taken to confirm and plan the bimaxillary orthognathic surgery. It was determined that the maxilla required an advancement of 5.0 mm on the right side and 6.0 mm on the left side and the mandible required a setback of 5.5 mm on the right side and 5.0 mm on the left side

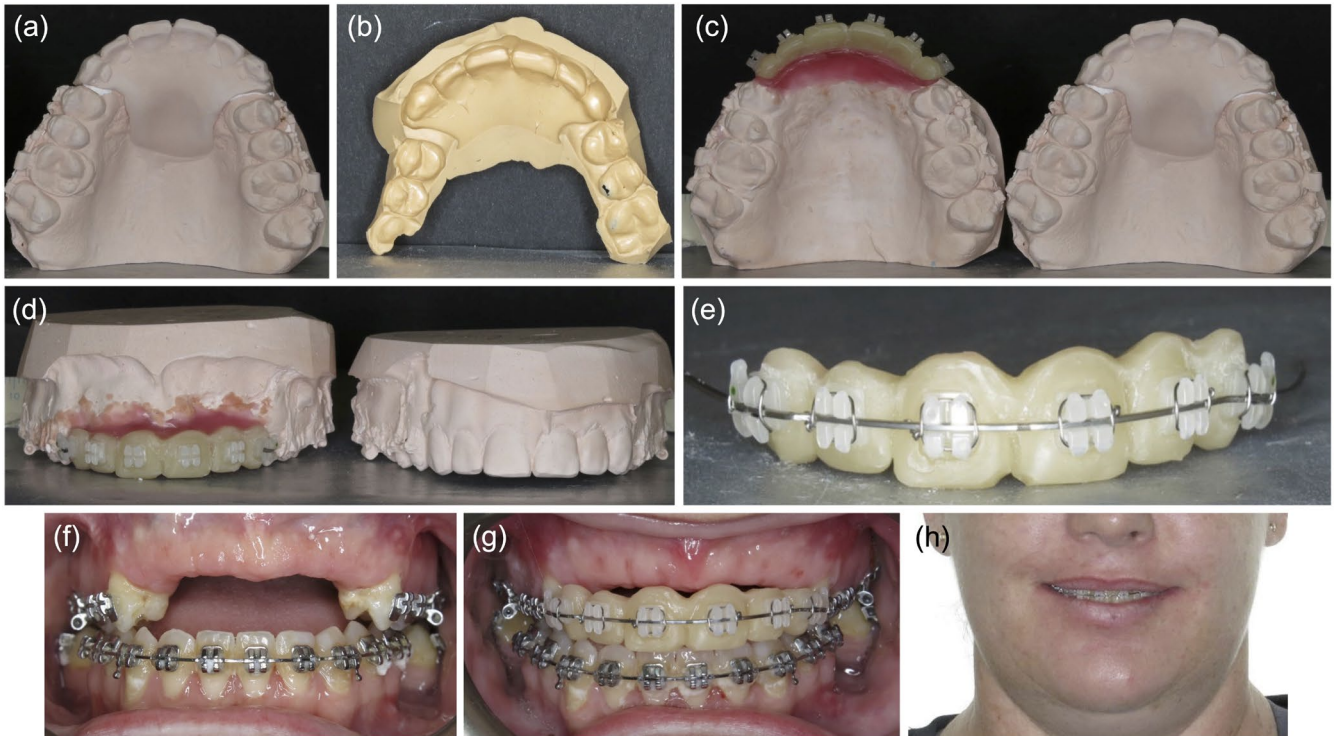


FIGURE 6 A, An alginate impression was taken with the acrylic partial denture in place to produce a working stone model. B, A polyvinyl siloxane putty key was used to record the position and to allow a replicate of the maxillary anterior teeth to be fabricated for cosmetic purposes. Luxatemp[®] was placed into the polyvinyl siloxane putty key to create a multi-tooth replica pontic. C-D, Wax was used to position the multi-tooth pontic into the correct horizontal and vertical position. E, The pontic was trimmed to avoid contact with the anterior maxilla, which had undergone an autogenous bone graft at the time of orthognathic surgery. F-G, The multi-tooth pontic was attached to the maxillary orthodontic archwire at 2 weeks post-surgery. H, This multi-tooth pontic provided satisfactory esthetics for the patient at this interim stage, as the acrylic partial denture could no longer be worn due to the recent autogenous bone graft in the anterior maxilla

2.4.7 | 23 months

The upper and lower fixed orthodontic appliances were removed. A mandibular fixed lingual retainer was bonded to the anterior teeth. The patient was also provided with a maxillary vacuum-formed retainer with the Luxatemp[®] multi-tooth pontic secured within the retainer with ceramic brackets for cosmetic reasons while a temporary acrylic maxillary denture was constructed (Figure 7).

2.4.8 | 31 months

Three implants (Nobel Replace Tapered Groovy[®]; Nobel Biocare) were placed in the 13 (4.3 × 10 mm), 21 (3.5 × 13 mm) and 23 (4.3 × 10 mm) sites and intentionally submerged to ensure optimal healing (Figure 8). Nobel Replace Tapered Groovy[®] implants are tapered implants designed to provide increased initial stability compared with a parallel implant.¹⁹ Additional alveolar ridge augmentation was also performed with BondBone[®]. The patient was instructed to not wear the maxillary acrylic partial denture for one week and to have this denture adjusted appropriately by the prosthodontist.

2.4.9 | 34 months

After detailed discussion with the patient, a fixed prosthesis consisting of a titanium cylinder cobalt chrome framework was chosen to support a six-unit acrylic bridge (Figure 9). This prosthesis was intended as a long-term provisional prosthesis. The ideal definitive prosthesis would be a fixed porcelain bridge, however, financial constraints prevented the patient from choosing this material. Despite the inherent challenges, the post-treatment maxillary lip fullness and facial profile change were determined to be pleasing (Figure 10). It was not possible to re-create the soft tissue papillae or gingival margins around the final implant-supported restorations, therefore gingival-colored acrylic was utilized to improve the anterior smile esthetics (Figure 9).

3 | DISCUSSION

Several challenges and dilemmas became apparent in the planning of the procedures and these were communicated clearly with the patient prior to the commencement of the comprehensive interdisciplinary treatment. In particular, it was clear that a substantial amount of time, effort and

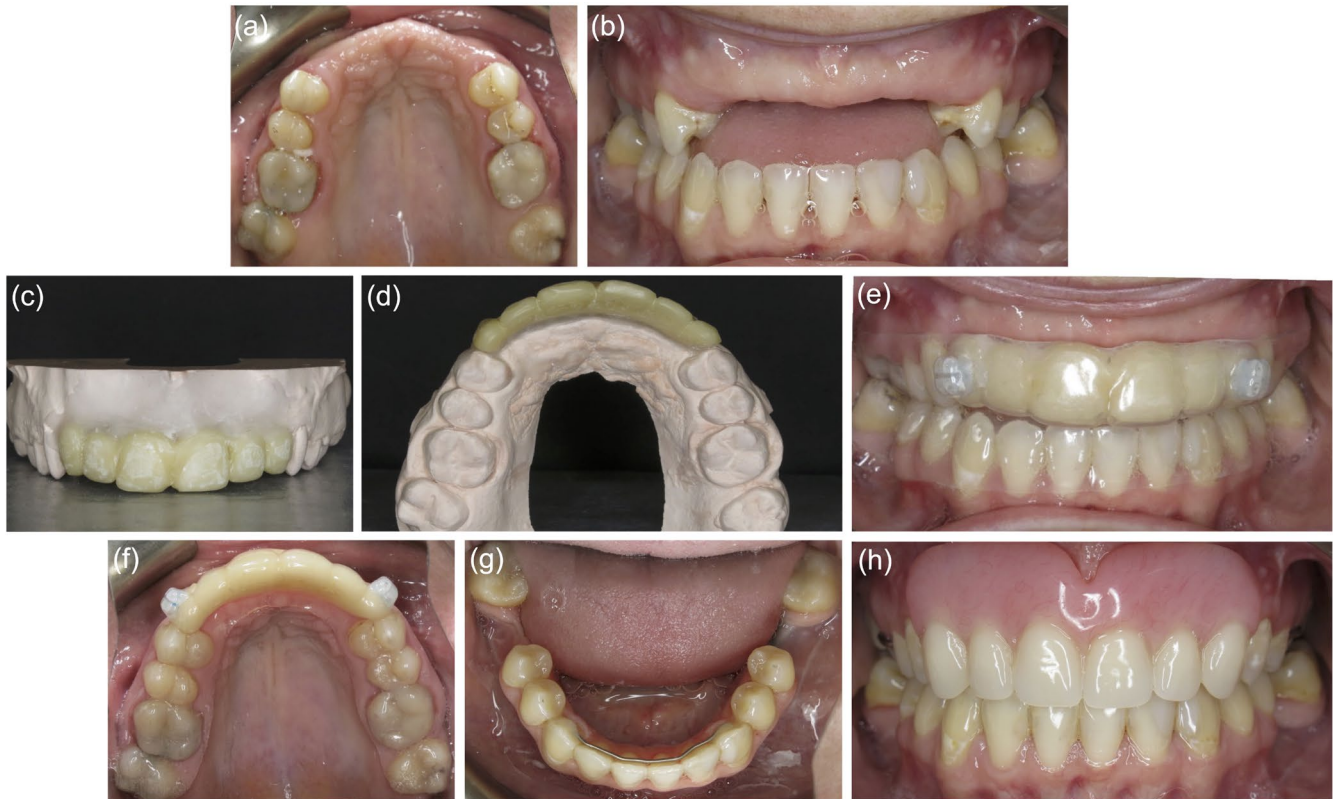


FIGURE 7 A-B, The fixed orthodontic appliances were removed following 23 months of active treatment. C-D, The Luxatemp® multi-tooth pontic was positioned with wax on the working stone model at the correct horizontal and vertical dimension. Ceramic brackets were bonded to the pontic in the 13 and 23 positions to hold the pontic more securely in the maxillary retainer prior to the fabrication of the maxillary vacuum-formed Essix® retainer. E, This maxillary vacuum-formed retainer provided a temporary cosmetic solution until another maxillary acrylic partial denture could be made. A mandibular vacuum-formed retainer was also issued. G, A mandibular fixed retainer bonded to the canines was also placed. The mandibular vacuum-formed retainer was worn nocturnally to maintain the uprighted positions of the 37 and 37

resources would be required to facilitate the fixed prosthodontic rehabilitation due to the significant atrophic alveolar bone changes. Given the retrusive maxillary position, osseointegrated implants could only be appropriately placed in the anterior maxilla following a maxillary advancement orthognathic surgical procedure and a significant increase in alveolar bone volume from a graft.

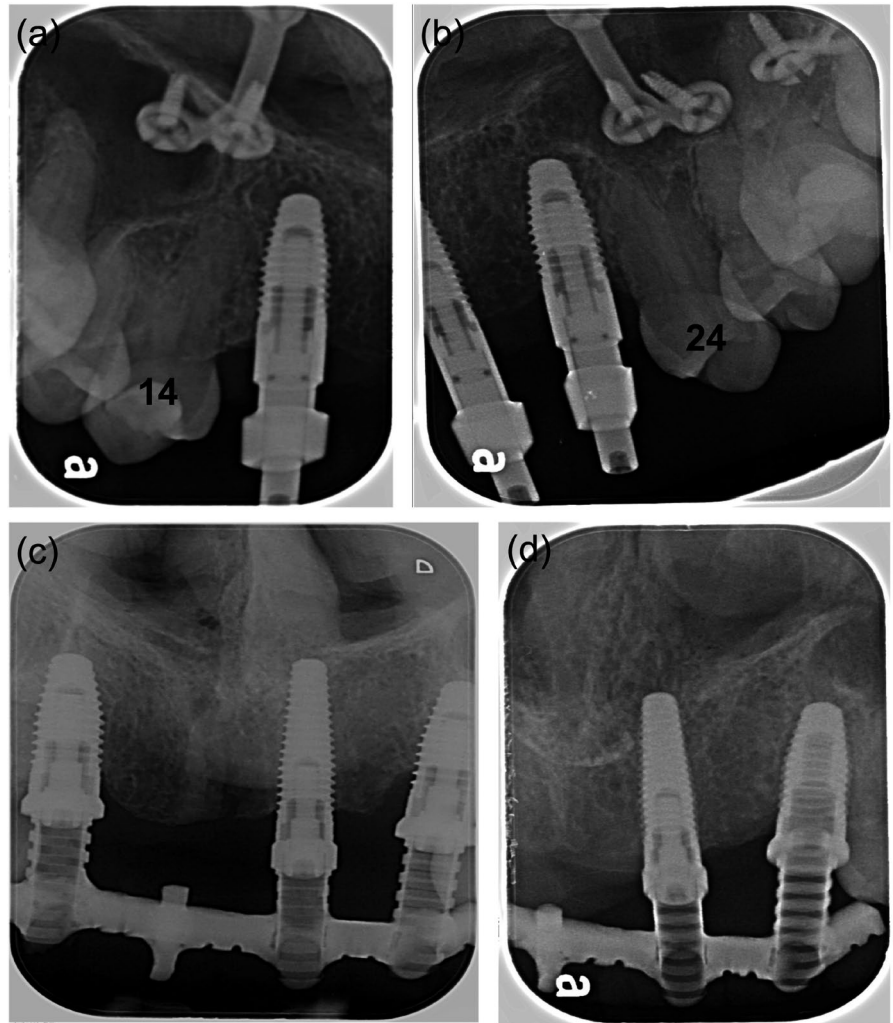
In addition to this, the pre-existing removable partial denture was able to provide favorable upper lip support due to the size of the acrylic flange. Fixed prosthodontic rehabilitation would not be able to provide comparable upper lip support, although a maxillary advancement would be expected to provide an increase in upper lip projection. This potential post-treatment reduction in upper lip fullness was communicated to the patient by all involved clinicians. Another concern for the maxillofacial surgeon and prosthodontist was that re-creation of the soft tissue papillae and gingival margins around the final implant-supported restorations would not be possible, therefore gingival-colored acrylic would be necessary to disguise this inevitable outcome. Despite these clearly communicated therapeutic limitations, the patient

remained determined to proceed with the proposed treatment plan.

The desire for implant-supported prostheses may vary between individual patients. It has been reported that despite being unhappy with certain aspects of their current denture, some patients still prefer not to have implants.²⁰ This suggests that denture dissatisfaction does not always correlate with desire for an implant prosthesis. The potential benefits of implant prostheses must be balanced with the risks of surgery, post-operative pain, financial and opportunity costs.²¹ This highlights the need for comprehensive and ongoing informed consent.

It has been reported that no significant change in self-esteem occurred for patients treated with either dentures or implants,²² which suggests that an individual's self-esteem may be affected by factors unrelated to the type of appliance. This highlights the individual variation between patients that influences treatment decisions, such as personality. Although the type of appliance may be less important, patients with Kennedy Class IV issues resulting in severe anterior edentulism have demonstrated greater self-esteem changes

FIGURE 8 A-B, Periapical radiographs at 31 months showing the three restorative implants placed in the anterior maxilla (Nobel Replace Tapered Groovy®). The restorative implants were placed in the 11, 13, 21 and 23 locations in the maxillary arch. C-D, 34 months after the commencement of the interdisciplinary treatment, one six-unit bridge was placed in the anterior maxillary region



following implant rehabilitation.¹ This case report has detailed the complex interdisciplinary treatment required for a patient determined to achieve a fixed prosthodontic outcome despite having a well-functioning and esthetic removable partial denture.

There are many potential challenges when planning multiple implant placement in an edentulous and atrophic anterior maxillary region. Bone grafting is generally required to provide sufficient available bone in all three dimensions²³, followed by period of healing and subsequent implant placement. However, it should be noted that the survival rates of implants placed in grafted jaws are lower than implants placed in native bone.²⁴ Further challenges to multiple implant placement in the anterior maxilla include achieving satisfactory esthetics from both the dental, soft tissue and facial perspectives. This includes the attempt to provide natural appearing sulcular and papillary anatomy.²⁵ Due to the substantial osseous defects from prolonged tooth loss and denture wear for this patient, gingival-colored acrylic was required to provide satisfactory dental proportions and to avoid significant black triangular spaces between adjacent implants due to the absence of natural interdental papillae.²⁶

4 | CONCLUSION

This case report demonstrates the paramount importance of structured interdisciplinary consultation and management for a patient with advanced dental needs. Complex cases require particular attention to the informed consent process and often a degree of lateral thinking to address the various clinical challenges which may be encountered.

ACKNOWLEDGEMENTS

The authors wish to sincerely thank and acknowledge the following clinicians for their involvement in the overall management for this case: Dr Desmond Ong (Orthodontist), Dr Geoffrey Dance (Oral and Maxillofacial Surgeon), Dr Anders Blomberg (Prosthodontist) and Dr Brendan Mudge (General Dentist). The authors also wish to sincerely thank the patient for kindly granting permission to use the clinical records and photographs for the purpose of continuing professional development. The authors also express their gratitude to Dr Brendan Mudge and Dr Ambereen Khan for kindly reviewing the manuscript and peer reviewer comments. Published with written consent of the patient.

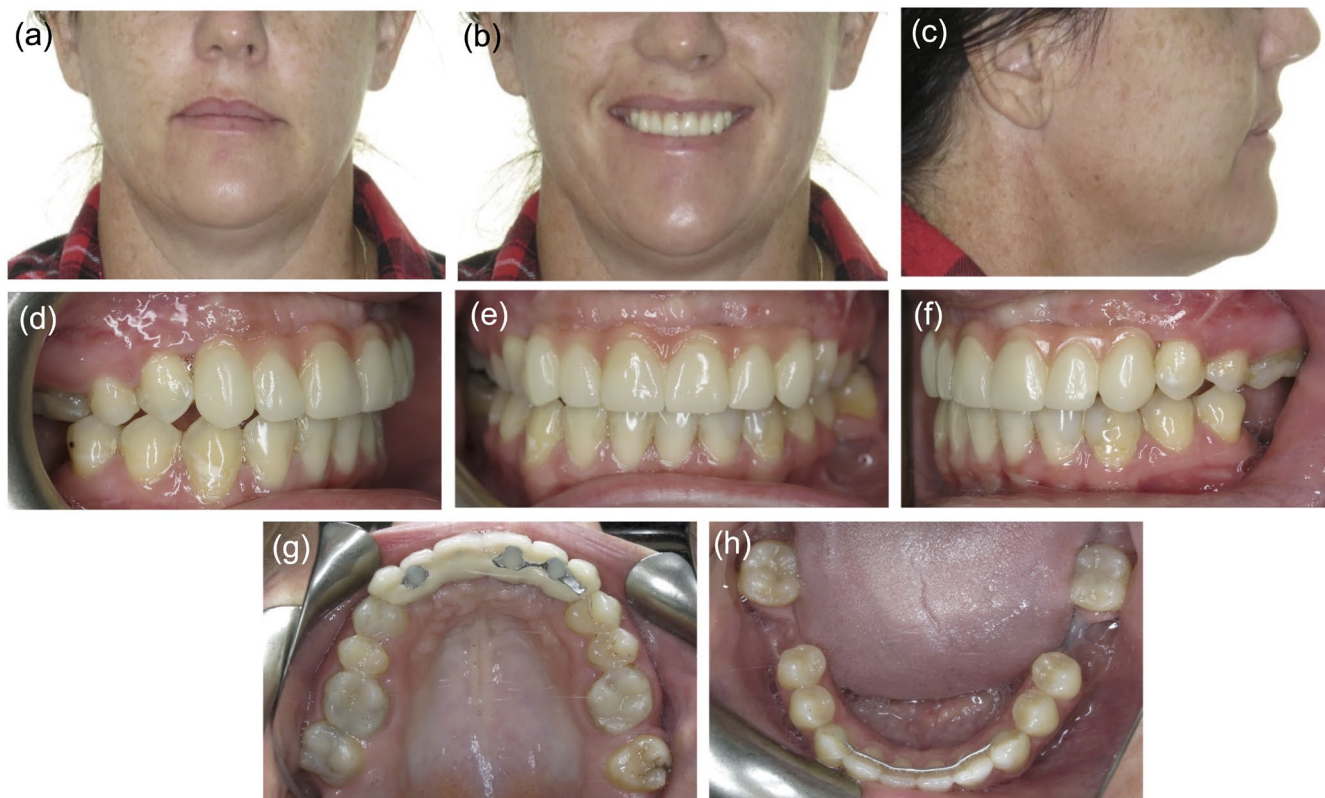

FIGURE 9 A-C, The post-treatment maxillary lip fullness and profile was pleasing. D-F, The fixed acrylic restoration was tinted to mimic the absent gingival papillae to improve the anterior smile esthetics of the implant restorations. G-H, An esthetically pleasing and functional outcome was achieved for this challenging case

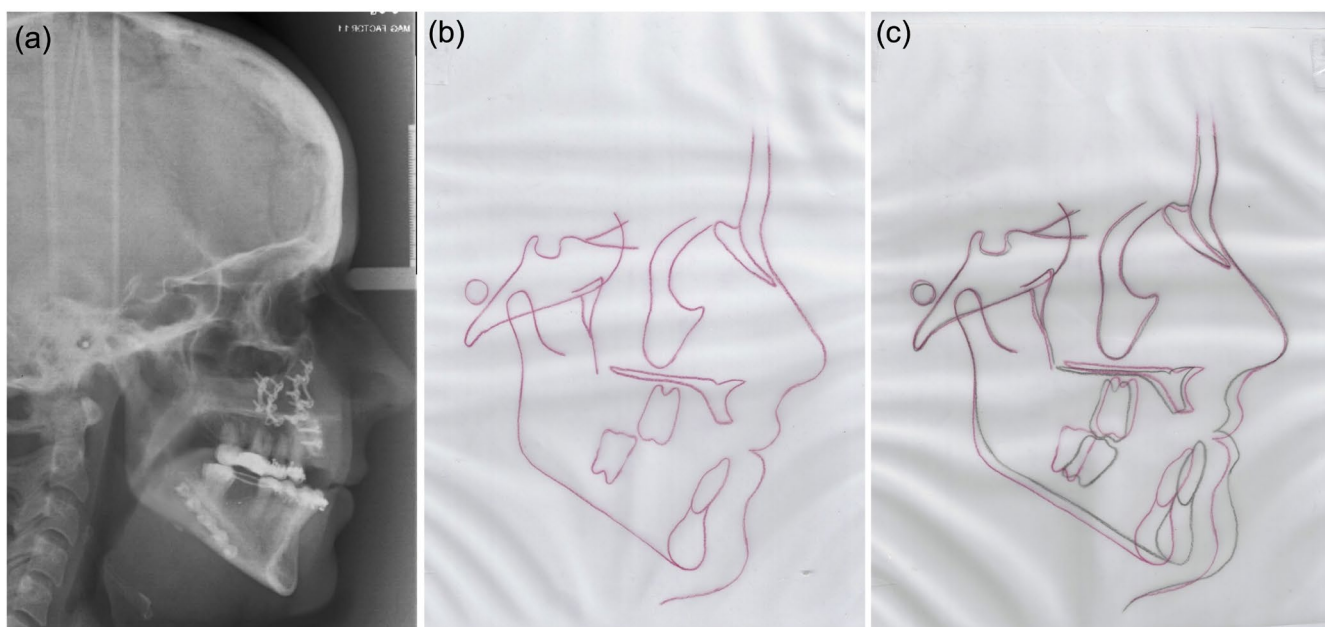


FIGURE 10 A, Post-surgical cephalometric radiograph taken prior to placement of the maxillary anterior restorative implants. B, Post-surgical cephalometric tracing (C) Superimposition of the pre-treatment cephalometric tracing (black lines) and the post-surgical cephalometric tracing (red lines) demonstrates the extent of facial profile changes achieved

CONFLICT OF INTEREST

None declared.

AUTHOR CONTRIBUTIONS

CYSL and EF were the authors and collaborators. DO was the clinician, author and involved in data collection and analysis.

ETHICAL STATEMENT

Written informed consent was obtained from the patient for publication of this case report and any accompanying images.

DATA AVAILABILITY STATEMENT

The data that support the findings of this study are available on request from the corresponding author. The data are not publicly available due to privacy or ethical restrictions.

ORCID

Chui Yi Sarah Low  <https://orcid.org/0000-0002-3798-4539>

Desmond Cheer-Vern Ong  <https://orcid.org/0000-0002-0557-0657>

Elissa Freer  <https://orcid.org/0000-0003-2692-9064>

REFERENCES

- Bramanti E, Maticena G, Cecchetti F, Arcuri C, Cicciù M. Oral health-related quality of life in partially edentulous patients before and after implant therapy: a 2-year longitudinal study. *Oral Implantol.* 2013;6:37-42.
- Craddock HL. Consequences of tooth loss: 1. The patient perspective—esthetic and functional implications. *Dent Update.* 2009;36:616-619.
- AL-Omiri MK, Karasneh JA, Lynch E, Lamey P-J, Clifford TJ. Impacts of missing upper anterior teeth on daily living. *Int Dent J.* 2009;59:127-132.
- Steele JG, Treasure E, Pitts NB, Morris J, Bradnock G. Total tooth loss in the United Kingdom in 1998 and implications for the future. *Br Dent J.* 2000;189:598-603.
- Brennan DS, Spencer AJ, Roberts-Thomson KF. Tooth loss, chewing ability and quality of life. *Qual Life Res.* 2008;17:227-235.
- Torabinejad M, Anderson P, Bader J, et al. Outcomes of root canal treatment and restoration, implant-supported single crowns, fixed partial dentures, and extraction without replacement: a systematic review. *J Prosthet Dent.* 2007;98(4):285-311.
- Heydecke G, Locker D, Awad MA, Lund JP, Feine JS. Oral and general health-related quality of life with conventional and implant dentures. *Commun Dent Oral Epidemiol.* 2003;31:161-168.
- Allen PF, McMillan AS. A longitudinal study of quality of life outcomes in older adults requesting implant prostheses and complete removable dentures. *Clin Oral Implant Res.* 2003;14:173-179.
- Awad MA, Locker D, Korner-Bitensky N, Feine JS. Measuring the effect of intra-oral implant rehabilitation on health-related quality of life in a randomized controlled clinical trial. *J Dent Res.* 2000;79:1659-1663.
- Blomberg S, Lindquist LW. Psychological reactions to edentulousness and treatment with jawbone-anchored bridges. *Acta Psychiatr Scand.* 1983;68:251-262.
- Canger EM, Çelenk P. Radiographic evaluation of alveolar ridge heights of dentate and edentulous patients. *Gerodontology.* 2012;29:17-23.
- Campbell RL. A comparative study of the resorption of the alveolar ridges in denture-wearers and non-denture-wearers. *J Am Dent Assoc.* 1960;60(2):143-153.
- Petrokovski J, Harfin J, Levy F. The influence of age and denture wear on the size of edentulous structures. *Gerodontology.* 2003;20:100-105.
- Drago C, Carpentieri J. Treatment of maxillary jaws with dental implants: guidelines for treatment. *J Prosthodont.* 2011;20:336-347.
- Angle EH. Classification of malocclusion. 1899;248-264.
- Ngan P, Moon W. Evolution of Class III treatment in orthodontics. *Am J Orthod Dentofacial Orthop.* 2015;148(1):22-36.
- Johnston C, Burden D, Kennedy D, Harradine N, Stevenson M. Class III surgical-orthodontic treatment: a cephalometric study. *Am J Orthod Dentofacial Orthop.* 2006;130:300-309.
- Jakobsone G, Stenvik A, Sandvik L, Espeland L. Three-year follow-up of bimaxillary surgery to correct skeletal Class III malocclusion: stability and risk factors for relapse. *Am J Orthod Dentofacial Orthop.* 2011;139:80-89.
- Nobel Biocare. Nobel Replace Tapered Groovy, Replace Select Tapered TiUnite, Replace Select Tapered Partially Machined Collar (PMC) Instructions for Use. p. 1.
- Akagawa Y, Rachi Y, Matsumoto T, Tsuru H. Attitudes of removable denture patients toward dental implants. *J Prosthet Dent.* 1988;60:362-364.
- Kent G. Effects of osseointegrated implants on psychological and social well-being: a literature review. *J Prosthet Dent.* 1992;68:515-518.
- Kiyak HA, Beach BH, Worthington P, Taylor T, Bolender C, Evans J. Psychological impact of osseointegrated dental implants. *Int J Oral Maxillofac Implants.* 1990;5:61-69.
- Bashutski JD, Wang HL. Common implant esthetic complications. *Implant Dentistry.* 2007;16:340-348.
- Ali SA, Karthigeyan S, Deivanai M, Kumar A. Implant rehabilitation for atrophic maxilla: a review. *J Indian Prosthodont Soc.* 2014;14:196-207.
- Priest GF. The esthetic challenge of adjacent implants. *J Oral Maxillofac Surg.* 2007;65(7 Suppl 1):2-12.
- Misch CE, Goodacre CJ, Finley JM, et al. Consensus conference panel report: crown-height space guidelines for implant dentistry-part 2. *Implant Dent.* 2006;15(2):113-121.

How to cite this article: Low CYS, Ong DC-V, Freer E. Interdisciplinary management of a partially dentate adult patient with a complex malocclusion. *Clin Case Rep.* 2021;9:e04586. <https://doi.org/10.1002/ccr3.4586>