

Histological evaluation of two different anorganic bovine bone matrixes in lateral wall sinus elevation procedure: A retrospective study

ABSTRACT

Introduction: Grafting in oral implantology involves bone augmentation procedures with various bone graft materials. Success of such procedures is evaluated through the amount of bone volume and bone formed at the grafted site. The primary aim of this prospective study was to histomorphometrically evaluate and compare the new bone formation with Bio Oss or Cerabone in the lateral approach sinus augmentation procedure.

Materials and Methods: The research targeted 22 patients who were either partially or completely edentulous posterior maxilla with residual alveolar height 3 mm at the site of implantation and underwent a two staged surgical protocol, with a lateral approach sinus grafting with either Bio Oss or Cerabone. Bone trephine biopsies for histological analysis were harvested 6 months after augmentation while preparing the osteotomies for implant placement trephine. The histologic evaluation was performed comparing the newly formed bone, marrow spaces, biomaterial particles remnants, and presence of osteocytes embedded in both trabecular bone and bone tissue near the anorganic bovine bone.

Results: The present study showed that neither of the graft material showed any active osteoclasts and host inflammatory reaction. From sites grafted with Cerabone, an ample amount of mature lamellated bone formation was seen, also host inflammatory response was indicative of minimal reactive inflammatory response suggestive of good acceptability of the graft material by the host. No significant differences between the groups could be detected with regard to new bone formation and residual bone substitute.

Conclusion: The results of the study illustrates that both the bone substitute materials allow predictable new bone formation in sinus augmentation procedures.

Keywords: Anorganic bovine bone matrix, histomorphometric, retrospective study, sinus augmentation

INTRODUCTION

A common drawback encountered in the rehabilitation of posterior jaw with implant-supported prosthesis is the lack of adequate bone volume. The presence of maxillary sinus in conjunction with loss of alveolar bone height limits the bone available for implant placement.^[1,2] Maxillary sinus graft is a common and predictable procedure used to increase the bone height. Boyne and James first described maxillary sinus graft using autogenous bone from the iliac crest.^[3] Due to its osteogenic, osteoinductive, and osteoconductive properties, autogenous bone is considered the gold standard for maxillary sinus grafting.^[4,5]

Unfortunately, procuring autogenous bone can increase the risk of morbidity, cause discomfort, and increase the intraoral

**LANKA MAHESH, GLENN MASCARENHAS¹,
MEENU TANEJA BHASIN², CALVO GUIRADO³,
SAURABH JUNEJA⁴**

Private Practitioner, The Specialist Clinic, Saket, New Delhi,

¹Private Practitioner, Mclin Dent, Mumbai, Maharashtra,

²Department of Periodontics, Santosh Dental College, Santosh

University, Ghaziabad, Uttar Pradesh, ⁴Department of Oral

Pathology, ITS Centre for Dental Studies and Research,

Ghaziabad, Uttar Pradesh, India, ³Department of Oral Surgery,

UCAM, Murcia, Spain

Address for correspondence: Dr. Meenu Taneja Bhasin,
C-1, Shakti Nagar Extension, Delhi - 110 052, India.
E-mail: drmeenu2005@gmail.com

Received: 16 November 2019, **Revised:** 08 May 2020,
Accepted: 22 July 2020, **Published:** 16 December 2020

This is an open access journal, and articles are distributed under the terms of the Creative Commons Attribution-NonCommercial-ShareAlike 4.0 License, which allows others to remix, tweak, and build upon the work non-commercially, as long as appropriate credit is given and the new creations are licensed under the identical terms.

For reprints contact: WKHLRPMedknow_reprints@wolterskluwer.com

How to cite this article: Mahesh L, Mascarenhas G, Bhasin MT, Guirado C, Juneja S. Histological evaluation of two different anorganic bovine bone matrixes in lateral wall sinus elevation procedure: A retrospective study. *Natl J Maxillofac Surg* 2020;11:258-62.

Access this article online

Website:
www.njms.in

DOI:
10.4103/njms.NJMS_81_19

Quick Response Code



time of surgery, the tendency for partial resorption, and excessive graft shrinkage.^[6,7]

To overcome these disadvantages, a large number of biomaterials have been used alone or in combination with autografts in maxillary sinus augmentation procedures.^[8] Xenografts, especially anorganic bovine bone matrix (ABBM), is one of the most suited nonautogenous bone graft materials for maxillary sinus grafting, both histologically and histometrically, due to its osteoconductive nature and well integration into newly formed bone.^[9]

The two-stage sinus augmentation with delayed implant insertion was thought of as a decent clinical model to gauge the performance of graft materials because bone formation happens within an enclosed cavity and with minimal interference from external factors. It also allows collecting bone biopsy specimens during implant insertion, avoiding any additional discomfort for the patients.^[10]

Comparing new bone formation through histomorphometric analysis using totally different bone graft materials could assist the practitioner in deciding the graft materials to be used for sinus graft procedure.

Thus, the primary aim of this study is to evaluate and compare the bone formation overtime following maxillary sinus augmentation with either of the two ABBM, BioOss or Cerabone by retrospective assessment of histomorphometric data in cases with severe atrophy of the residual maxillary bone (bone height ≤ 3 mm).

MATERIALS AND METHODS

Research objective and data collection

Clinical records were selected among those who were either partially or completely edentulous posterior maxilla with residual alveolar height ≤ 3 mm, who underwent implant-supported rehabilitation between the period of June 2013 and July 2018. The study involved 26 patients (6 female and 15 male) with a mean age of 54 ± 9.1 years. For the present retrospective analysis, patients who underwent a two-staged surgical protocol followed with sinus grafting procedure through the lateral window at stage one and trephine biopsy obtained at stage two with implant placement, i.e., 6 months after sinus augmentation procedure with either Bio-Oss (Geislich, Switzerland) or Cerabone (Botiss biomaterials) as bone grafting materials were selected. Patients with compromised medical condition, maxillary sinus disease, smoking habits, poor oral hygiene, and maxillary sinus infection developed after surgery were

excluded from the study. Data regarding a 5-year implant survival follow-up was also assessed simultaneously. The study was approved by the Institutional Ethical Review Board and ethical clearance was obtained for the study (reference number L/2019/173).

Research methods

Surgical procedure

And sinus depth was measured buccopalatally at a distance from the ridge crest. For all, the surgery was performed after adequate local anesthesia. The full-thickness mucoperiosteal flap was raised and the lateral window was prepared using a round bur on the anterior wall of the maxillary sinus. Then, a series of sinus elevators were used to lift the sinus lining and either of the xenografts was used to graft the cavity and the Ossix membrane™ was used to cover the defect. Primary closure was achieved using a 3-0 cytoplast sutures suture. Appropriate antibiotics and analgesics were prescribed. Patients were asked to rinse with 0.2% chlorhexidine gluconate for 2 weeks.

Harvesting bone core was done 4 months post sinus grafting procedure, Stage 2 was performed, i.e., implant placement. A full-thickness mucoperiosteal flap was reflected, and the previous surgical site was exposed. The previous surgical site was marked with India ink. One bone core biopsy per sinus was obtained using 3.2 mm Trephine (KOINE-ITALY), the base of the core represented the native bone and the top represented the grafted part that was clearly visible. The bone core biopsy was stored in 10% buffered formalin and sent to a laboratory for histological and histomorphometric analysis. Titanium implants, 4.0–5.0 wide and length 10 mm long, were placed at the biopsy site.

Histomorphometric analysis

The trephine core biopsy specimens were fixed in fixative (4% paraformaldehyde in 0.1 M phosphate buffer, pH 7.2) for at least 24 h. The specimens were then decalcified in a mild decalcifying agent (10% ethylenediaminetetraacetic acid). The specimens were then processed following standard tissue processing protocols for hard-tissue processing. Each sample was dehydrated in ascending grades of ethyl alcohol (50%, 70%, 80%, 95%, and absolute alcohol) followed by a step of clearing in three changes of clearing agent (xylene). The biopsy specimens were infiltrated and embedded in paraffin wax and blocks were obtained. Thin 3 μ m sections were obtained using semi-automatic microtome and stained with hamatoxylin and eosin stain. The sections were observed under transmitted light using a research microscope (Olympus BX53) at low and high magnifications.^[11]

Digital photomicrographs were obtained by the camera (Olympus EPL3) and images were transferred to

the computer for histomorphometric analysis using image analysis software. Areas of new bone formation, remnant graft material, and unmineralized tissue were measured and compared in the two study groups.

Statistical analysis

Data were analyzed using computer statistical program software (Magnus Pro by Olympus). Changes in graft volume at different time intervals were analyzed using Student's paired *t*-test to compare the mean data between the groups.

RESULTS

The decalcified sections of cores obtained from sites grafted with Bio-Oss showed mature bone formation along with focal areas of remnant graft particles. The bony trabeculae showed lamellations with osteocytes lying within the osteocytic lacunae and lined by osteoblasts at the periphery. At some areas, the bone was seen to be apposed to the graft material. Areas of bone apposition with varying degrees of mineralization were evident at the graft bone interface suggestive of osteoconductive properties of the graft material in bone formation. The surrounding stroma was unremarkable with minimal inflammatory response suggestive of good acceptability of the material by the host. Focal areas showed graft material surrounded by fibrous connective tissue with minimal host inflammatory reaction [Figure 1].

The decalcified sections obtained from trephine cores obtained from sites grafted with Cerabone showed multiple foci of mature bone formation. The bony trabeculae showed mature osteocytes within the osteocytic lacunae and rimming by plump cuboidal osteoblasts. The mature bony trabeculae also showed prominent basophilic cement lines suggestive of active remodeling process. The presence of areas of new

bone formation was also seen in close approximation to the remnant graft material. Few focal areas also showed the focal presence of osteocytes within osteocytic lacunae suggestive of an active role of graft particles in new bone formation and bone tissue ingrowth. Host inflammatory response was indicative of minimal reactive inflammatory response suggestive of good acceptability of the graft material by the host [Figure 2].

Percent bone formation

The mean % bone formation in Bio OSS group is $41.4\% \pm 2.6\%$, whereas it is $39.23\% \pm 2.8\%$ in Cerabone group [Table 1]. No statistically significant difference in the result was observed among the two groups.

Bone gain

The mean bone gain in Bio-OSS group was 5.35 ± 1.45 mm, whereas it is 4.65 ± 1.15 in Cerabone group. There was no statistically significant difference between the groups.

DISCUSSION

Bone substitutes are used commonly in implant surgical procedures involving sinus augmentation. Desirable properties of these bone substitutes should have specific biological and clinical properties to favor new bone formation with adequate volume. Biologically, it should mediate the recruitment of mesenchymal cells derived from host site and have bioactive effects on ossification (osteinduction). Furthermore, it must be osteoconductive, providing three-dimensional scaffolds for the ingrowth of vessels and osteoprogenitor cells. Finally, it should be resorbable. Clinically, it should be easy to use, cost-effective, and with adequate density to allow easy radiographic recognition during the entire healing process.^[12]

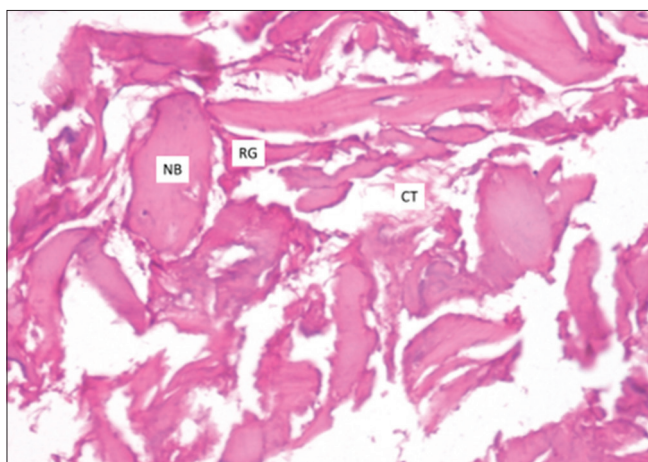


Figure 1: Photomicrograph showing areas of bone apposition with varying degrees of mineralization (Bio-oss) (NB- New bone, RG- residual Graft, CT- Connective tissue)

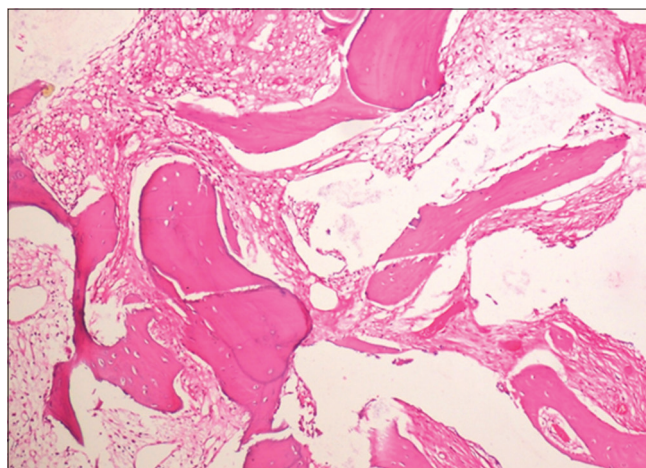


Figure 2: Photomicrograph showing areas of new bone formation in close approximation to remnant graft material (Cerabone)

Table 1: Mean percentage of bone formation in the two groups

Study groups	Mean percentage bone formation	Mean gain in bone height (mm)
Group 1 (Bio-Oss)	41.4±2.6	5.35±1.45
Group 2 (Cerabone)	39.23±2.8	4.65±1.15

Although autogenous bone is considered the gold standard for comparison of any bone substitute, commonly available bone graft materials can be broadly categorized based on their manufacturing properties. One type of graft materials (BioOss-Geistlich Pharma AG, Wolhusen, Switzerland) is produced by deproteinization at a low temperature of around 300°C and treatment with strong alkalis and organic solvents to render in nonantigenic and protein free with a particle size of 0.25–1 mm, whereas the other (Cerabone) (AAP Biomaterials GmbH, Berlin, Germany) is a bovine bone material produced by sintered at high temperature (>1200°C), which retains the inorganic part of the bone (hydroxyapatite) with a particle size of 0.5–1 mm.^[12]

Panagiotou *et al.* showed that Bio-Oss undergoes a low heat (300°C) chemical process that extracts the organic components, while Cerabone deproteinization occurs at a very high temperature (1200°C) that enhances material crystallinity. Since Bio-Oss has a less crystalline structure compared to DBB-2 and might be more prone to degradation, residual Bio-Oss particles might resorb faster. Cerabone is exposed to deproteinization in higher temperatures compared to Bio-Oss. This increases the crystallinity of the material which results in long-term presence after sinus augmentation, which is a clinical advantage.^[13]

Riachi *et al.* performed a study in which direct sinus graft procedure was performed on 22 patients intended for implant placement. Two types of graft materials were used (Bio-Oss and Cerabone) and after 8 months of healing time, the implants were inserted. Radiographic assessment was performed over a period of 4 years. Particle size, rate of calcium release, and size and type of crystal structure of each graft were evaluated. They observed that the average particle size of Bio-Oss (1 mm) was much smaller compared to Cerabone (2.7 mm). The amount of calcium release due to the dissolution of material in water was much higher for Bio-Oss compared to Cerabone. X-ray image analysis revealed that Bio-Oss demonstrated significantly higher volumetric loss (33.4% ± 3.1%) of initial graft size compared to Cerabone (23.4% ± 3.6%). The greatest amount of vertical loss of graft material volume was observed after 1 year of surgery.^[14]

Riachi *et al.* have shown that Bio-Oss has smaller particle size (1 mm average particle size compared to 2.7 mm for Cerabone) resulting in significantly higher surface area,

higher calcium release rate (9.8 mg/g), and smaller crystallite size (41.7 nm at 25.86 diffraction angle) compared to 53.2 nm at 25.95 diffraction angle for Cerabone. These differences were associated with a significantly higher resorption rate of the initial graft volume observed for Bio-Oss material in their study.^[14]

Moon *et al.* compared two xenograft materials prepared by a low-temperature deproteinizing technique (Bio-Oss) or a high-temperature (Cerabone) one and observed a significantly greater volumetric loss of the initial graft size for the nonsintered material. They stated that Bio-Oss has a significantly larger surface area and a smaller crystallite size compared with Cerabone.^[15]

Piattelli *et al.* have shown that Bio-Oss is a resorbable osteoconductive material in the sinus augmentation procedures. The interconnected porous system of Bio-Oss appears to have a size and structure conducive to vessel ingrowth. The interparticle space determines the vascularity and vascular ingrowth into the graft scaffold.^[16]

The results of the present study showed that both Bio-oss and Cerabone were comparable in their results in bone augmentation procedures despite the fact that both Cerabone and Bio-oss differ distinctly in their manufacturing process with regard to heat treatment and have distinct physicochemical properties. This could be explained by the fact that both show a similar healing process involving a long-term nontransient state of minimal inflammation resulting in long-term success, as shown in previous studies. Both the materials allow for partial resorption of graft material and replacement by new bone, allowing for extended bone remodeling and maturation process.^[17]

Berberi *et al.* have shown that although both had a well crystalline particle components, Bio-Oss had least particle size as compared to Cerabone but showed a higher calcium release property as compared to Cerabone. This could attribute to the favorable bone formation process despite smaller particle size and considerable resorption rate and volumetric bone loss.^[12]

CONCLUSION

No significant differences were observed between the groups with regard to new bone formation and residual bone substitute. Predictable new bone formation in sinus augmentation procedure was observed for both bone substitutes.

Financial support and sponsorship

Nil.

Conflicts of interest

There are no conflicts of interest.

REFERENCES

- Pietrokoski J, Massler M. Alveolar ridge resorption following tooth extraction. *J Prosthet Dent* 1967;17:21-7.
- Sharan A, Madjar D. Maxillary sinus pneumatization following extractions: A radiographic study. *Int J Oral Maxillofac Implants* 2008;23:48-56.
- Boyne PJ, James RA. Grafting of the maxillary sinus floor with autogenous marrow and bone. *J Oral Surg* 1980;38:613-6.
- Moy PK, Lundgren S, Holmes RE. Maxillary sinus augmentation: Histomorphometric analysis of graft materials for maxillary sinus floor augmentation. *J Oral Maxillofac Surg* 1993;51:857-62.
- Hallman M, Sennerby L, Lundgren S. A clinical and histologic evaluation of implant integration in the posterior maxilla after sinus floor augmentation with autogenous bone, bovine hydroxyapatite, or a 20:80 mixture. *Int J Oral Maxillofac Implants* 2002;17:635-43.
- Kalk WW, Raghoobar GM, Jansma J, Boering G. Morbidity from iliac crest bone harvesting. *J Oral Maxillofac Surg* 1996;54:1424-9.
- Nkenke E, Schultze-Mosgau S, Radespiel-Tröger M, Kloss F, Neukam FW. Morbidity of harvesting of chin grafts: A prospective study. *Clin Oral Implants Res* 2001;12:495-502.
- Nishimoto M, Kan JK, Rungcharassaeng K, Roe P, Prasad H, Lozada JL. Histomorphometric analysis of maxillary sinus grafts: A pilot study. *Int J Oral Maxillofac Implants* 2019;34:759-67.
- Scarano A, Pecora G, Piattelli M, Piattelli A. Osseointegration in a sinus augmented with bovine porous bone mineral: Histological results in an implant retrieved 4 years after insertion. A case report. *J Periodontol* 2004;75:1161-6.
- La Monaca G, Iezzi G, Cristalli MP, Pranno N, Sfasciotti GL, Vozza I. Comparative histological and histomorphometric results of six biomaterials used in two-stage maxillary sinus augmentation model after 6-month healing. *Biomed Res Int* 2018;2018:1-11.
- Ramírez Fernández MP, Gehrke SA, Pérez Albacete Martínez C, Calvo Guirado JL, de Aza PN. SEM-EDX study of the degradation process of two xenograft materials used in sinus lift procedures. *Materials (Basel)* 2017;10:542.
- Berberi A, Samarani A, Nader N, Noujeim Z, Dagher M, Kanj W, *et al.* Physicochemical characteristics of bone substitutes used in oral surgery in comparison to autogenous bone. *Biomed Res Int* 2014; 2014:320790.
- Panagiotou D, Özkan Karaca E, Dirikan İpçi Ş, Çakar G, Olgaç V, Yılmaz S. Comparison of two different xenografts in bilateral sinus augmentation: radiographic and histologic findings. *Quintessence Int* 2015;46:611-9.
- Riachi F, Naaman N, Tabarani C, Aboelsaad N, Aboushelib MN, Berberi A, *et al.* Influence of material properties on rate of resorption of two bone graft materials after sinus lift using radiographic assessment. *Int J Dent* 2012;2012:737262.
- Moon JW, Sohn DS, Heo JU. Histomorphometric analysis of maxillary sinus augmentation with calcium phosphate nanocrystal-coated xenograft. *Implant Dent*. 2015;24:333-7.
- Piattelli M, Favero GA, Scarano A, Orsini G, Piattelli A. Bone reactions to anorganic bovine bone (Bio-Oss) used in sinus augmentation procedures: A histologic long-term report of 20 cases in humans. *Int J Oral Maxillofac Implants* 1999;14:835-40.
- Perić Kačarević Z, Kavehei F, Houshmand A, Franke J, Smeets R, Rimashevskiy D, *et al.* Purification processes of xenogeneic bone substitutes and their impact on tissue reactions and regeneration. *Int J Artif Organs* 2018;41:789-800.