

# CARE—Placental site trophoblastic tumor presenting with thrombotic microangiopathy

## A case report

Cai-Fu Zhao, MD<sup>a</sup>, Ze-Qing Du, MD<sup>a</sup>, Nan Li, PhD<sup>a</sup>, Yan Wang, PhD<sup>b</sup>, Su-Fen Zhao, PhD<sup>a,\*</sup>

### Abstract

**Rationale:** Placental site trophoblastic tumor (PSTT) is a rare form of gestational trophoblastic neoplasm (GTN).

**Patient concerns:** A 28-year-old Chinese female with initial presentation of thrombotic microangiopathy (TMA) with symptoms of edema of the lower extremities and eyelid, thrombocytopenia and anemia.

**Diagnoses:** The primary diagnosis was chronic glomerulonephritis according to the related laboratory tests and clinical symptoms.

**Interventions:** A total abdominal hysterectomy with a bilateral salpingectomy was performed.

**Outcomes:** The PSTT patient was cured, which contributed to the symptom relief of TMA.

**Lessons:** This case report aims to elucidate the relationship between TMA and PSTT, so as to achieve timely diagnosis and treatment and reduce misdiagnosis.

**Abbreviations:** BP = blood pressure, C-section = cesarean section, GTN = gestational trophoblastic neoplasm, GTNs = gestational trophoblastic neoplasms, hCG = human chorionic gonadotropin, ITs = intermediate trophoblasts, LDH = lactate dehydrogenase, PSTT = Placental site trophoblastic tumor, TMA = thrombotic microangiopathy.

**Keywords:** kidney disease, placental site trophoblastic tumor, thrombotic microangiopathy

## 1. Introduction

Placental site trophoblastic tumor (PSTT) is a gestational trophoblastic disease that arises from placental intermediate trophoblasts (ITs), which are responsible for embryo implantation. It accounts for approximately 1% to 2% of all gestational trophoblastic neoplasms (GTNs). The most common presenting symptom is postmenopausal irregular vaginal bleeding, which may be accompanied by other metastatic symptoms or complications. As suggested by relevant studies, 5 case reports on PSTT associated with kidney disease have been documented,<sup>[1–4]</sup> including one on PSTT combined with thrombotic microangiopathy.<sup>[2]</sup> As for that report, the PSTT patient was cured, which contributed to the symptom relief of TMA.

A patient developing PSTT with TMA as the initial diagnosis recently presented in the Second Hospital of Hebei Medical University with symptoms of thrombotic microangiopathy, including edema of the lower extremities and eyelid edema, thrombocytopenia and anemia. Informed consent was obtained

from the patient for publication of this case report and accompanying images.

## 2. Case report

A 28-year-old gravida 4 para 2, Chinese female underwent a cesarean section (C-section) and gave birth to one healthy full-term girl 10 months ago, followed by breast-feeding for 10 months thereafter with postpartum irregular menstruation. The woman had no previous surgery except for the miscarriage that occurred twice at 3 years prior to presentation. She presented to the Nephrology Department on January 27, 2016 with 1-week history of edema in both double lower extremities and eyelids. On admission, the physical examination revealed a blood pressure (BP) of 142/111 mm Hg and eyelid edema. In addition, moderate pitting edema was noted in the lower extremities. The primary diagnosis was chronic glomerulonephritis.

### 2.1. Related laboratory tests

Routine blood test revealed mild anemia (range: 97–131 g/L; with a sustained decline), thrombocytopenia (range: 69–117 × 10<sup>9</sup>/L; with a sustained decline), and a reticulocyte count of 50.1 × 10<sup>9</sup>/L. In addition, abnormal red blood cell morphology (at different sizes) was observed in peripheral blood. The biochemical tests revealed a continuous increase in creatinine (range: 44.1–89.8 μmol/L), a persistent increase in urea (range: 2.60–6.32 mmol/L), elevated lactate dehydrogenase (LDH; range: 246–314 U/L), and a persistent decrease in albumin (range: 23.6–19.3 g/L). Furthermore, anti-neutrophil antibodies and autoantibodies were negative. The detection of serum complement suggested a decrease in C4 (0.08 g/L), a normal C3, and slightly increased prothrombin activity (128%). Other items were found to be within normal limits. Routine urine test revealed elevated urine protein (4+), urinary occult blood (3+ μL), and urobilinogen (–).

Editor: N/A.

The authors have no conflicts of interest to disclose.

<sup>a</sup> Department of Gynaecology, <sup>b</sup> Department of Nephrology, The Second Hospital of Hebei Medical University, Shijiazhuang, China.

\* Correspondence: Su-Fen Zhao, Department of Gynaecology, The Second Hospital of Hebei Medical University, No. 215 of Heping West Road, Xinhua District, Shijiazhuang 050000, China (e-mail: sufenzhao\_dr@163.com).

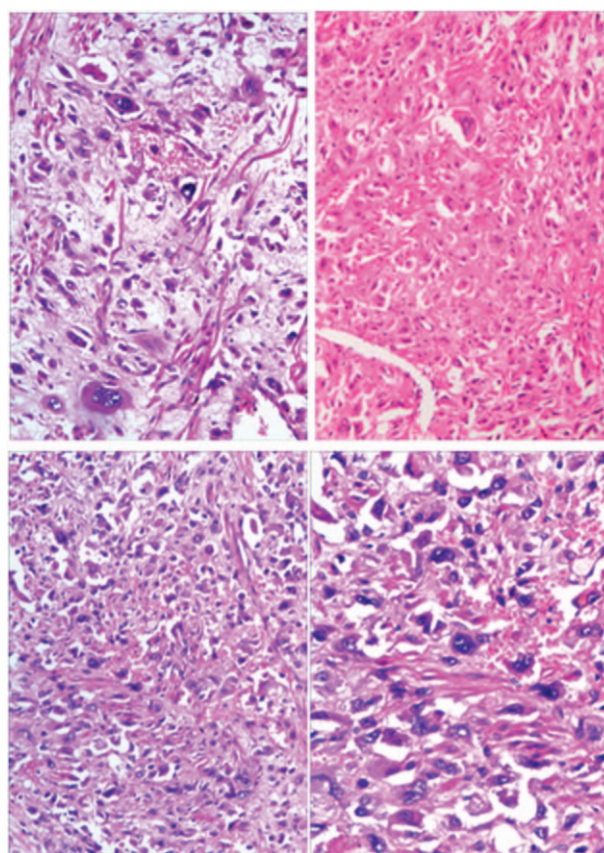
Copyright © 2018 the Author(s). Published by Wolters Kluwer Health, Inc. This is an open access article distributed under the terms of the Creative Commons Attribution-Non Commercial-No Derivatives License 4.0 (CCBY-NC-ND), where it is permissible to download and share the work provided it is properly cited. The work cannot be changed in any way or used commercially without permission from the journal.

Medicine (2018) 97:43(e12698)

Received: 18 May 2018 / Accepted: 11 September 2018

<http://dx.doi.org/10.1097/MD.00000000000012698>

As far as immunoglobulin was concerned, IgG decreased by 3.78 g/L, while IgA slightly decreased by 0.86 g/L. Furthermore, ADAMTS13 was negative. The quantity of 24-hour urine protein was measured, which ranged from 2.05 to 5.71 g/24 hours, showing a sustained increase. In addition, HbsAg (-), HbsAb (-), HbeAg (-), and HbcAb (+) were all negative, and the Coombs test was negative. Renal biopsy was performed. Light microscopy revealed 2 renal cortices (with adequate cyst cavity and inadequate loop cavity), which contained 19 glomeruli, with segmental subendothelial aggregates. In addition, there was deposition of phlogistic red protein in part of the ball subcutaneous endothelium. The tubule epithelial cells were granular and revealed degeneration. The pathological changes in the interstitium were unremarkable. Three interlobular arteries were noted, while no arcuate artery was observed. The examination of the small artery was unremarkable. The immunocytochemistry indicated IgG (-), IgA (+/-), IgM (++), MS+GCM in one globule, C3c (+), granular GCW, segmental growth of the cyst wall, C1q (-), and FRA (-). Immunohistochemical analysis revealed HBsAg (++), MS+GCW, HBcAg (++), and MS+GCW. There was thrombus in the capillary lumen. Pathological diagnosis was pregnancy-induced renal damage and hepatitis B virus antigen deposition. Human chorionic gonadotropin (hCG) was 1099 to 1983 mIU/ml. Gynecological ultrasound indicated that the measurement of the uterus was approximately 8.19 × 10.5 × 6.12 cm in the longitudinal, transverse and antero-posterior axes. Ultrasound revealed a slightly stronger echo of 5.34 × 6.88 × 6.12 cm in size in the uterine cavity. Some dark areas with ill-defined margins were indistinct from the posterior wall of the uterus. Uneven serosal surface of the fundus of uterus and ascites were noted. Pelvic MRI indicated space-occupying lesions in the left posterior wall of the uterus, with undetermined nature and multiple cystic lesions in the right posterior wall of the uterus. Signal intensity at the fundus of the uterus was uneven, and adenomyosis was suspected. The examination revealed abnormal nodules on the left side of the cervix, with an abundant blood supply and a vascular structure. Pelvic effusion was noted, given the enlargement of the lymph nodes and skin edema. Based on the clinical symptom, blood hCG, imaging examination and pathological result, the corrected diagnosis was thrombotic microangiopathy, and choriocarcinoma was suspected. In the Nephrology Department, the patient received various treatments for improving circulation, promoting anticoagulant activity, lowering blood pressure and urine protein, and plasma transfusion. Unfortunately, the above symptoms did not significantly improve. Subsequently, the patient was transferred to the Gynecology Department prior to undergoing a hysteroscopy. A light yellow cheese-like mass was detected in the uterus. Uterine bleeding, similar to arterial bleeding, was observed when the mass was collected. Total abdominal hysterectomy with bilateral salpingectomy was performed with the consent of the patient's family. Approximately 4000 mL of light yellow ascites were observed, as well as an enlarged uterus of approximately the size of that during the 8th week of pregnancy, which had an irregular shape. A mass of approximately 2 cm in diameter was noted at the right horn of the uterus. The absence of a serosa and muscular layer led to rough and fragile surface and bleeding tendency. After surgery, uterotomy was performed, which revealed a placenta-like tissue mass of approximately 5 cm in diameter, which was blue-violet in color, as well as a rough and fragile surface. Postoperative pathological findings strongly suggested PSTT, which invaded the walls of the uterus, and affected the cervical canals and the



**Figure 1.** Placental site trophoblastic tumor cells, hematoxylin-eosin staining dyeing, 200×.

cervix (Fig. 1). Immunohistochemistry results revealed CK (+), HCG (+), Inhibin-a (-), Vimentin (+) and Ki-67 (+30%). Ultimately, postoperative diagnosis was PSTT and thrombotic microangiopathy.

Postoperatively, the laboratory test results improved. In addition, blood pressure returned to normal and ascites decreased, and the general symptoms significantly improved. Considering the high risk factors in the patient, chemotherapy was recommended, which was rejected. The patient has been followed-up for more than 2 years, subsequent follow-up visits revealed no evidence of recurrence, and the laboratory test results were within the normal range.

### 3. Discussion

PSTT is usually difficult to diagnose due to its rarity and nonspecific Clinical presentation.<sup>[5]</sup> Thus, pathological evaluation and immunohistochemistry are necessary for a definite diagnosis of PSTT. PSTT mostly affects women of reproductive age, the time interval between preceding pregnancy and tumor development varies ranging from 0 to 23 years, mostly with a cutoff point of 2 years. PSTT is usually secondary to a term labor, an abortion, ectopic pregnancy or molar pregnancy,<sup>[6]</sup> and often follows a term labor for a female infant.<sup>[7]</sup> As described in the literature, PSTT develops in conjunction with a live twin pregnancy and was successfully resected during a C-section.<sup>[8]</sup> Interestingly, PSTT is reported to be combined with fallopian pregnancy.<sup>[9]</sup> PSTT is also noted in patients with no history of pregnancy or in the ovary of a young child,<sup>[10]</sup> or in

men<sup>[11]</sup>—called “nongestational PSTT.” Metastases occur in a minority of patient with good prognosis but higher mortality. PSTT is insensitive to chemotherapy, so the surgical removal of all lesions along with pelvic lymph node sampling is the primary therapeutic approach.<sup>[12]</sup> As for young patients (premenopausal women), the ovaries can be conserved, whereas for those with fertility requirements, the practice is lesion resection to preserve the fertility. Successful surgical procedure to preserve fertility has been reported. Nonetheless, there is a risk of treatment failure, resulting in reoperation.<sup>[13]</sup> With regard to stage I PSTT patients with high risk factors and those in progressive stage, postoperative adjuvant chemotherapy is recommended. EMA/CO or EMA/CP regimens are optional to improve the prognosis. Serum $\beta$ -hcg may serve as an indicator of prognosis, despite the fact that it cannot reflect the degree of malignancy and that it is disproportionate to tumor load.<sup>[14]</sup> Moreover, the lifelong follow-up is suggested.

#### 4. Conclusions

After hysterectomy in my case, the symptom of thrombotic microangiopathy was quickly relieved. The outcome of this case elucidates the relationship between TMA and PSTT, although the pathogenesis was not yet clear because of its rarity. Renal damage can be the initial clinical symptom of PSTT. In the future, patients who seek medical treatment in the department of nephrology for unknown reasons may consider whether it is caused by gynecological diseases. This case is designed to improve our understanding of the disease which is Renal damage can be a complication of PSTT, to achieve early diagnosis and treatment, and to reduce misdiagnosis.

#### Author contributions

**Conceptualization:** Caifu Zhao.

**Data curation:** Zeqing Du.

**Formal analysis:** Nan Li.

**Resources:** Yan Wang.

**Supervision:** Sufen Zhao.

**Writing – original draft:** Caifu Zhao, Sufen Zhao.

**Writing – review & editing:** Caifu Zhao, Sufen Zhao.

#### References

- [1] Batra V, Kalra OP, Mathur P, et al. Membranous glomerulopathy associated with placental site trophoblastic tumour: a case report. *Nephrol Dial Transplant* 2007;22:1766–8.
- [2] Mazzucco G, Colla L, Monga G. Kidney involvement in a patient affected by placental site trophoblastic tumor. *Am J Kidney Dis* 2011;57:516–20.
- [3] Young RH, Scully RE, McCluskey RT. A distinctive glomerular lesion complicating placental site trophoblastic tumor: report of two cases. *Hum Pathol* 1985;16:35–42.
- [4] Xiao C, Zhao J, Li M, et al. Lupus nephritis associated with placental site trophoblastic tumor: a case report and review of the literature. *Gynecol Oncol Case Rep* 2014;9:26–8.
- [5] Cho FN, Chen SN, Chang YH, et al. Diagnosis and management of a rare case with placental site trophoblastic tumor. *Taiwan J Obstet Gynecol* 2016;55:724–7.
- [6] Niknejadi M, Ahmadi F, Akhbari F. Imaging and clinical data of placental site trophoblastic tumor: a case report. *Iran J Radiol* 2016;13:e18480.
- [7] Hassadia A, Gillespie A, Tidy J, et al. Placental site trophoblastic tumour: clinical features and management. *Gynecol Oncol* 2005;99:603–7.
- [8] Liszka L, Wilk M, Wodolazski A, et al. Successful treatment of placental site trophoblastic tumor in twin pregnancy without hysterectomy. *Tumori* 2009;95:108–11.
- [9] Küçük Z, Ergün Y, Işık H, et al. A rare case of uterine rupture due to a placental site trophoblastic tumour in the rudimentary horn. *J Obstet Gynaecol* 2015;35:97–8.
- [10] Arroyo MR, Podda A, Cao D, et al. Placental site trophoblastic tumor in the ovary of a young child with isosexual precocious puberty. *Pediatr Dev Pathol* 2009;12:73–6.
- [11] Suurmeijer AJ, Gietema JA, Hoekstra HJ. Placental site trophoblastic tumor in a late recurrence of a nonseminomatous germ cell tumor of the testis. *Am J Surg Pathol* 2004;28:830–3.
- [12] Horowitz NS, Goldstein DP, Berkowitz RS. Placental site trophoblastic tumors and epithelioid trophoblastic tumors: Biology, natural history, and treatment modalities. *Gynecol Oncol* 2017;144:208–14.
- [13] Shen X, Xiang Y, Guo L, et al. Fertility-preserving treatment in young patients with placental site trophoblastic tumors. *Int J Gynecol Cancer* 2012;22:869–74.
- [14] Lucas R, Cunha TM, Santos FB. Placental site trophoblastic tumor: a case report and review of the literature. *J Radiol Case Rep* 2015;9:14–22.